

# Hip Ankylosis after Untreated Septic Arthritis by *Escherichia coli*: A Case Report

## *Anquilose do quadril após artrite séptica por Escherichia coli não tratada: Relato de caso*

Sabit Sllamniku<sup>1</sup>  Lul Raka<sup>2,3</sup>  Emir Q. Haxhija<sup>4</sup>  Ardiana Murtezani<sup>5</sup> 

<sup>1</sup> Orthopedics Department, University Clinical Center of Kosovo, Pristina, Kosovo

<sup>2</sup> Microbiology Department, School of Medicine, National Institute for Public Health of Kosovo, Pristina, Kosovo

<sup>3</sup> School of Medicine, University of Pristina, Pristina, Kosovo

<sup>4</sup> Department of Pediatric and Adolescent Surgery, Medical University Graz, Graz, Austria

<sup>5</sup> Physical Medicine and Rehabilitation Department, University Clinical Center of Kosovo, Pristina, Kosovo

Address for correspondence Sabit Sllamniku, PhD, MD, Orthopedics Department, University Clinical Center of Kosovo, 10,000 Pristina, Kosovo (e-mail: [sabit.sllamniku@uni-pr.edu](mailto:sabit.sllamniku@uni-pr.edu)).

Rev Bras Ortop 2024;59(Suppl S1):e22–e25.

### Abstract

Septic arthritis is usually reported in elderly patients with other underlying medical conditions. Septic arthritis by *Escherichia coli* is a rare infection. We are describing the case of a 70-years old patient who presented with a suppurative fistula, limited movements of the right lower limb, and a trauma that occurred at the age of 12. Throughout this time, the fistula had been present, secreting pus. A detailed clinical investigation revealed a pyogenic infection present in the femoral epiphysis followed by an elevated sedimentation rate. After the surgical intervention, *E. coli* was isolated from the clinical samples, and the decision to place gentamicin beads within the surgical wound was taken. The patient was treated with antibiotics. Four months after the intervention, the suppurative fistula was completely healed.

Later on, the patient was no longer interested anymore in continuing with the treatment plan. As he refused to remove the gentamicin chain beads and the hip endoprosthesis, he was subsequently referred to the primary care clinic for conservative management and follow-up. He walked with a limp wearing orthopedic shoes and not using crutches or any other type of walking-aid. Four years after the surgical intervention, the gentamicin chain beads are still within the bone. Septic arthritis caused by *E. coli* can remain active for decades, secreting pus and self-isolating. Prompt diagnosis, adequate surgical intervention, and antimicrobial therapy are essential for the treatment.

### Keywords

- ▶ ankylosis
- ▶ arthritis, infectious
- ▶ hip joint
- ▶ *Escherichia coli*

Study carried out at the Orthopedics Department, University Clinical Center of Kosovo, Pristina, Kosovo.

received  
April 7, 2021  
accepted  
June 15, 2021

DOI <https://doi.org/10.1055/s-0041-1736515>.  
ISSN 0102-3616.

© 2021. The Author(s).

This is an open access article published by Thieme under the terms of the Creative Commons Attribution 4.0 International License, permitting copying and reproduction so long as the original work is given appropriate credit (<https://creativecommons.org/licenses/by/4.0/>).

Thieme Revinter Publicações Ltda., Rua do Matoso 170, Rio de Janeiro, RJ, CEP 20270-135, Brazil

## Resumo

A artrite séptica é geralmente relatada em pacientes idosos com outras condições médicas subjacentes. Artrite séptica por *Escherichia coli* é uma infecção rara. Descrevemos o caso de um paciente de 70 anos que apresentou uma fístula supurativa, movimentos limitados do membro inferior direito, e um trauma ocorrido aos 12 anos de idade. Durante todo esse tempo, a fístula esteve presente, secretando pus. Uma investigação clínica detalhada revelou uma infecção piogênica presente na epífise femoral seguida de uma taxa elevada de sedimentação. Após a intervenção cirúrgica, *E. coli* foi isolada das amostras clínicas, e tomou-se a decisão de colocar pérolas de gentamicina dentro da ferida cirúrgica. O paciente foi tratado com antibióticos. Quatro meses após a intervenção, a fístula supurativa foi completamente curada.

Mais tarde, o paciente não estava mais interessado em continuar com o plano de tratamento. Como ele se recusou a remover as pérolas da cadeia de gentamicina e a endoprótese de quadrile, ele foi posteriormente encaminhado para a clínica de atenção primária para manejo conservador e acompanhamento. Ele andava mancando usando sapatos ortopédicos, mas sem muletas ou qualquer outro tipo de dispositivo de auxílio para caminhar. Quatro anos após a intervenção cirúrgica, as pérolas da cadeia de gentamicina ainda estão inseridas no osso. A artrite séptica causada por *E. coli* pode ficar ativa por décadas, secretando pus e se isolando. Diagnóstico rápido, intervenção cirúrgica adequada, e terapia antimicrobiana são essenciais para o tratamento.

### Palavras-chave

- ▶ anquilose
- ▶ articulação do quadril
- ▶ artrite infecciosa
- ▶ *Escherichia coli*

## Introduction

In adults presenting with acute monoarticular arthritis, septic arthritis, which is usually located in the knee and hip joints, is a key consideration.<sup>1,2</sup> Delays in the prescription of the appropriate antibiotic therapy within the first 48 hours of the onset of symptoms can result in subchondral bone loss and permanent joint dysfunction.<sup>1</sup>

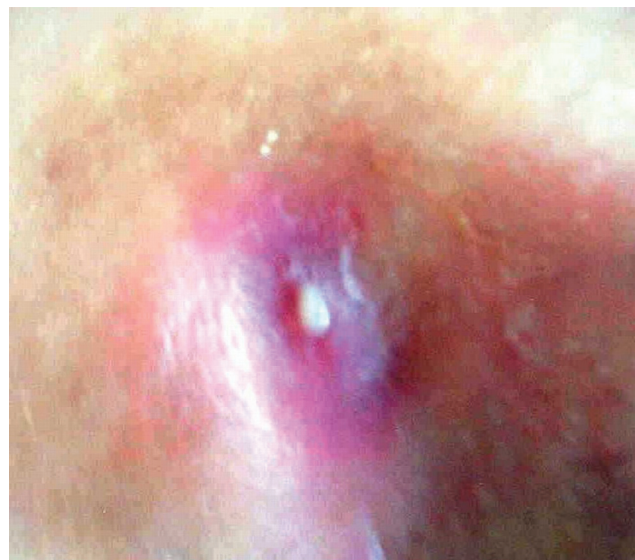
Many bacterial isolates have been reported in the etiology of septic arthritis. The most common etiology is *Staphylococcus aureus*, which is responsible for 37% to 65% of the cases, depending on the geographic distribution, the incidence of comorbid rheumatic disease, and the proportion of infections involving the joints. There has been an increase in joint conditions caused by methicillin-resistant *S. aureus* (MRSA), particularly in the elderly and on patients recently submitted to orthopedic surgery. Gram-negative bacilli account for ~ 5% to 20% of the cases. The most common Gram-negative organisms are *Pseudomonas aeruginosa* and *Escherichia coli*, usually in patients with a history of use of intravenous drugs, neonates, the elderly, and immunocompromised patients.<sup>1-4</sup>

The independent risk factors in cases of infectious arthritis include bacteriuria, hip joint involvement, and use of steroids. Advanced age and frailty, compromised immunity, skin infections, recurrent urinary tract infection, and recent abdominal surgery are previously known risk factors for infectious arthritis. However, the evidence is still unclear.<sup>4,5</sup>

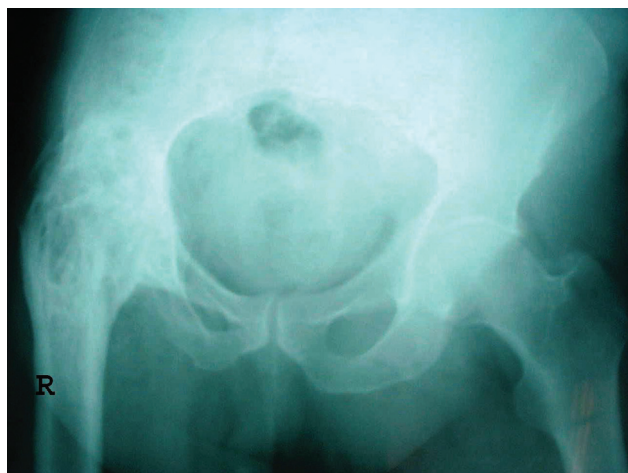The present paper aims to describe a case of a long-lasting fistulous suppurative hip arthritis without previous infections or disease caused by *E. coli*.

## Case Report

A 70-year-old retired man, weighting 80 kg, non-smoker, non-alcoholic, without any concomitant diseases and previous surgeries. He worked as a security guard for an elementary school, and was admitted to the orthopedic and traumatology clinic due to a suppurative fistula and redness around the region of the greater trochanter of the right femur (→ Fig. 1).



**Fig. 1** Suppurative fistula from hip arthritis.

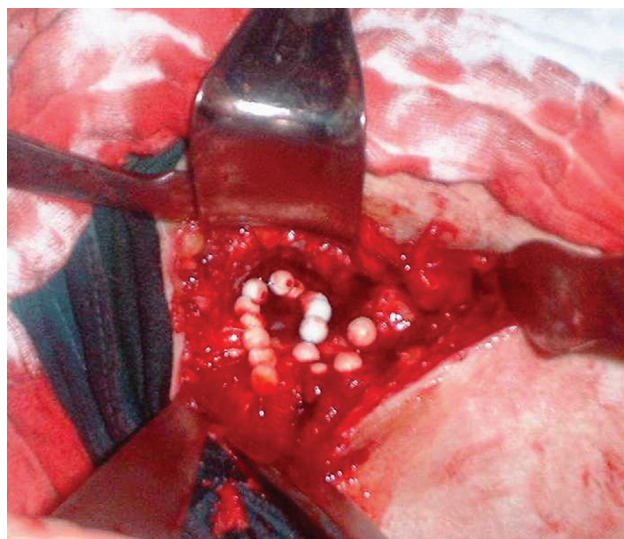


**Fig. 2** Simple radiography of the pelvis, showing ankylosis of the right hip.

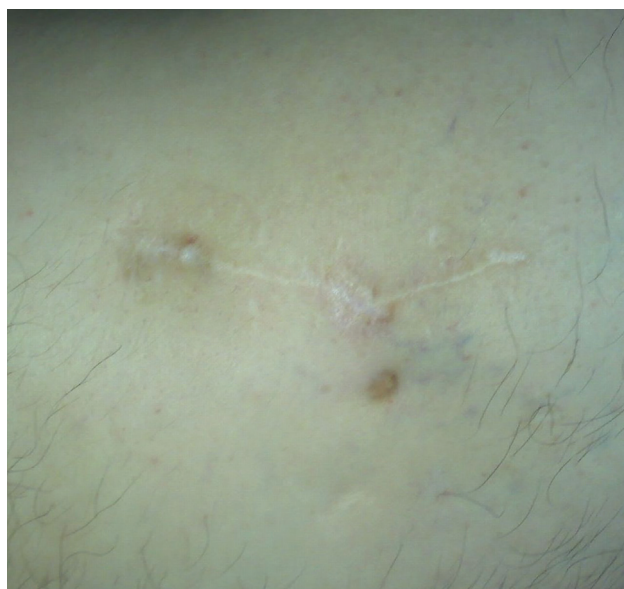He reported having no history of pain and fever. The movements of the right hip joint were limited to 30° of flexion, 10° of abduction, and no rotation. The patient limped while walking due to a shortening of the leg of ~ 5 cm. According to his life history, at the age of 12, he suffered blunt trauma from a crash. For 58 consecutive years, the patient reports that the fistula has been present on his limb, secreting pus. Upon admission to the hospital, plain radiography and X-ray fistulography revealed a focus of infection focus in the femoral epiphysis (► **Fig. 2**).

Laboratory investigations showed a slightly elevated sedimentation rate (22/45), and the result of C-reactive protein (CRP) test was 12 mg/l. The results of further respiratory, digestive, and urinary tract investigations were completely normal, and did not point to any concomitant disease or illness. The urinalysis also presented average values. After a clinical examination and laboratory evaluation, in February 2017, surgical intervention was performed under spinal anesthesia. From the sample taken within the bone cavity by curettage, *E. coli* were isolated from the purulent foci as the causative bacteria. This *E. coli* isolate was sensitive to third-generation cephalosporins, gentamicin, and fluoroquinolones, but resistant to amoxicillin and tetracycline. After removal of the skin and bone fistula and irrigation, a total of 15 gentamicin chain beads were introduced (► **Fig. 3**).

The drain was removed 48 hours after the intervention. The patient was treated with ceftriaxone 2 g during the intervention, ceftriaxone 2 g b.i.d. for the first 3 weeks after the intervention, and ciprofloxacin 750 mg b.i.d. for another 3 weeks. Four months after the intervention, the suppurative fistula was completely healed. Blood sedimentation rates decreased to 18/30, and the CRP test was negative. Nine months after the intervention, sedimentation rates fell to 6/12, and the CRP test was negative. One year after the surgical management, considering the normalization of the laboratory results, plain radiography, clinical condition, and our patient's best interest, we suggested continuing with the treatment plan and removing the gentamicin chain beads and the hip endoprosthesis. The patient refused because of his satisfaction with



**Fig. 3** Enlarged bone fistula filled with 15 gentamicin chain beads.

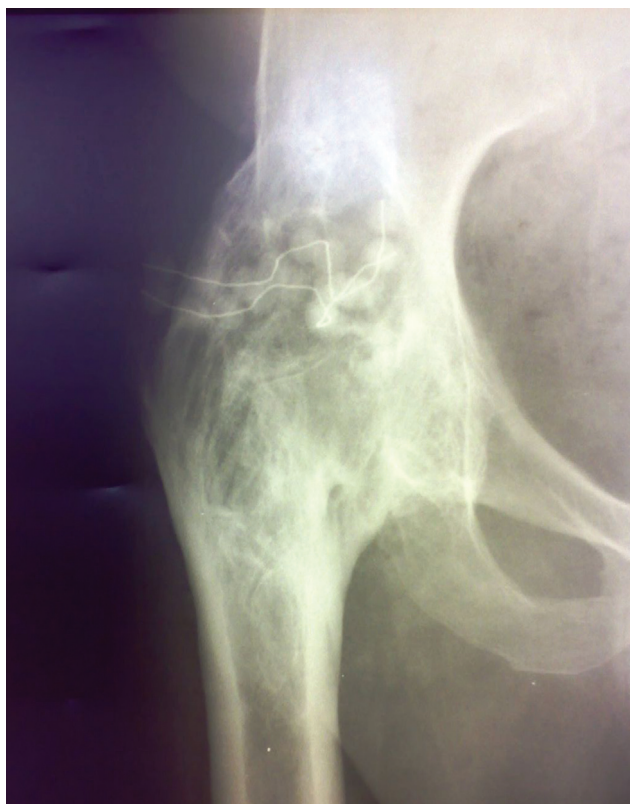

**Fig. 4** Postoperative scar in the region of the great trochanter without fistula and redness.

the results of the intervention. He walked with a limp wearing orthopedic shoes, without using crutches or any other type of walking aid. As we care greatly for our patients, we honored our patient's autonomy to decide, and subsequently referred him for conservative management and follow-up. Four years after the surgical intervention, the gentamicin chain beads are still within the bone (► **Figs. 4** and **5**). No side effects such as redness, swelling, heat, ototoxicity, or nephrotoxicity have been reported.

## Discussion

Septic arthritis is an acute infection of the joint that occurs most commonly in young children; it is mainly monoarticular, and is frequently located in the knee and hip joints.<sup>2</sup> The incidence of septic arthritis ranges widely, between 4 and 29



**Fig. 5** A plain radiograph of the right hip showing the containment of the gentamicin beads.

cases per 100 thousand inhabitants/year. The most common route of entry into the joint is hematogenous spread during bacteremia. Pathogens may also enter through direct inoculation (for example: arthrocentesis, arthroscopy, trauma) or spread continuously due to local infections (such as osteomyelitis, septic bursitis, abscess).<sup>1</sup>

Despite numerous independent risk factors,<sup>4,5</sup> hip infection by *E. coli* can occur without any previous history of disease.

The outcome in patients with septic arthritis due to some of the more virulent organisms, such as superantigen-producing *S. aureus* and certain Gram-negative bacilli, is poor, despite an optimal therapy. Evacuation of purulent material with surgical methods is necessary, and then antibiotics are adjusted based on the results of culture and sensitivity. Adequate drainage of the joint is the preferred method of intervention.<sup>1-3</sup>

In addition to surgery, and the intravenous and oral administration of antibiotics, our treatment method is also

performed with the local application of antibiotics in the form of gentamicin beads.<sup>6</sup>

We did not consider the option of a Girdlestone-type resection during the first procedure because the patient reported no pain. This procedure would have shortened more the length of the leg and increased the asymmetric abnormality of the gait, making walking more difficult and the tendency to limp, more obvious and emphasized.<sup>7</sup>

*E. coli* is rarely the causative organism of acute suppurative arthritis. Many reviews of the literature on acute suppurative arthritis do not mention the role of *E. coli*. Furthermore, even in the nonsuppurative form, arthritis is an uncommon manifestation of *E. coli* septicemia.<sup>8</sup>

Septic arthritis caused by the bacterium *E. coli* can remain active for decades by secreting and self-isolating. Prompt diagnosis, adequate surgical intervention, and antimicrobial therapy are essential in the treatment, even in long-lasting infections. Complications regarding the joint, such as ankylosis, may occur.

#### Financial Support

The present research did not receive any specific grant from funding agencies in the public, private, or non-profit sectors.

#### Conflict of Interests

The authors have no conflict of interests to declare.

#### References

- Horowitz DL, Katzap E, Horowitz S, Barilla-LaBarca ML. Approach to septic arthritis. *Am Fam Physician* 2011;84(06):653-660
- Saavedra-Lozano J, Falup-Pecurariu O, Faust SN, et al. Bone and Joint Infections. *Pediatr Infect Dis J* 2017;36(08):788-799
- Shirliff ME, Mader JT. Acute septic arthritis. *Clin Microbiol Rev* 2002;15(04):527-544
- Lee Y, Cho YS, Sohn YJ, et al. Clinical Characteristics and Causative Pathogens of Infective Arthritis and Risk Factors for Gram-Negative Bacterial Infections. *Infect Chemother* 2020;52(04):503-515
- Lin WT, Tang HJ, Lai CC, Chao CM. Clinical manifestations and bacteriological features of culture-proven Gram-negative bacterial arthritis. *J Microbiol Immunol Infect* 2017;50(04):527-531
- Neut D, van de Belt H, van Horn JR, van der Mei HC, Busscher HJ. Residual gentamicin-release from antibiotic-loaded polymethylmethacrylate beads after 5 years of implantation. *Biomaterials* 2003;24(10):1829-1831
- Vincenten CM, Gosens T, van Susante JC, Somford MP. The Girdlestone situation: a historical essay. *J Bone Jt Infect* 2019;4(05):203-208
- Brandt AA, Leibowitz S, Saphra I. Acute suppurative arthritis due to *Escherichia coli* septicemia. *Ann Intern Med* 1956;44(05):1031-1036