







# Evaluation of the Radiographic Parameters of Sagittal and Spinopelvic Alignment in Patients with Osteoarthritis submitted to Total Hip Arthroplasty\*

## *Avaliação dos parâmetros radiográficos do alinhamento sagital e espinopélvico em pacientes com osteoartrite submetidos à artroplastia total do quadril*

Vanessa da Costa Sousa<sup>1</sup> Jamila Alessandra Perini<sup>1,2</sup> Antônio Eulálio Pedrosa Araújo Junior<sup>1</sup>  
João Antônio Matheus Guimarães<sup>1</sup> Maria Eugenia Leite Duarte<sup>1</sup> Marco Bernardo Cury Fernandes<sup>1</sup>

<sup>1</sup> Research Division, Instituto Nacional de Traumatologia e Ortopedia, Rio de Janeiro, RJ, Brazil

<sup>2</sup> Laboratório de Pesquisa de Ciências Farmacêuticas, Unidade de Farmácia, Centro Universitário Estadual da Zona Oeste (UEZO), Rio de Janeiro, Brazil

Address for correspondence: Vanessa da Costa Sousa, MS, Instituto Nacional de Traumatologia e Ortopedia, Av. Brasil, 500, Caju, Rio de Janeiro, RJ, 20940-070, Brazil  
(e-mail: vanessamedrj@gmail.com).

Rev Bras Ortop 2020;55(5):591–596.

### Abstract

**Objective** To evaluate radiographic parameters of sagittal and spinopelvic alignment in patients with hip osteoarthritis (OA) undergoing primary total hip arthroplasty (THA) to define the primary surgical approach in individuals with concomitant spinal and hip joint disease.

**Methods** Longitudinal, prospective, comparative study with 27 patients undergoing THA and 43 subjects without OA.

**Results** An association between hip and spine degenerative disease in patients with OA was noted. After THA, radiographic parameters of pelvic tilt angle, sagittal vertical axis (EVS) and seventh cervical vertebra/sacrofemoral distance (C7/DSF) ratio were similar to values from volunteers without joint disease. Global coronal alignment (ACG), sagittal alignment, spinopelvic T1 and T9 tilts (IT1EP and IT9EP), sacral tilt (IS), pelvic version (VP), pelvic type and lumbopelvic complex (CLP) did not change after THA.

**Conclusion** Among the sagittal and spinopelvic alignment parameters evaluated, the pelvic tilt angle, the EVS, and the C7/DSF ratio were corrected after THA and can guide the surgeon in the decision-making process for patients with concomitant spinal and hip joint disease. Spinal deformity may compensate for hip changes.

### Keywords

- ▶ sagittal alignment
- ▶ arthroplasty, replacement, hip
- ▶ osteoarthritis
- ▶ spinopelvic parameters

### Resumo

**Objetivo** Avaliar os parâmetros radiográficos do alinhamento sagital e espinopélvico de pacientes com osteoartrite (OA) de quadril submetidos à artroplastia total de

\* Study performed at Instituto Nacional de Traumatologia e Ortopedia (INTO), Rio de Janeiro, RJ, Brazil.



**Palavras-chave**

- ▶ alinhamento sagital
- ▶ artroplastia de quadril
- ▶ osteoartrite
- ▶ parâmetros espinopélvicos

quadril (ATQ) primária, com o intuito de definir a abordagem cirúrgica primária em pacientes com doença concomitante na coluna vertebral e na articulação do quadril.

**Métodos** Estudo longitudinal, prospectivo, comparativo, envolvendo 27 pacientes submetidos à ATQ e 43 indivíduos sem OA.

**Resultados** Foi observada associação entre doença degenerativa no quadril e na coluna nos pacientes com OA. Após a ATQ, os parâmetros radiográficos do ângulo da balsa da bacia, do eixo vertical sagital (EVS) e da razão de C7/DSF (sétima vértebra cervical/distância sacrofemoral) foram semelhantes aos valores dos voluntários sem doença articular. O alinhamento coronal global (ACG), o alinhamento sagital, as inclinações T1 e T9 espinopélvicas (IT1EP e IT9EP), a inclinação sacral (IS), a versão pélvica (VP), e o tipo de pelve e do complexo lombopélvico (CLP) não sofreram alteração depois da ATQ.

**Conclusão** Dentre os parâmetros do alinhamento sagital e espinopélvico avaliados, o ângulo da balsa da bacia, o EVS e a razão C7/DSF foram corrigidos após a ATQ e podem orientar o cirurgião na tomada de decisão para pacientes com doença concomitante na coluna vertebral e na articulação do quadril. A deformidade da coluna pode ser compensatória às alterações do quadril.

## Introduction

The association between hip joint disease and sagittal and spinopelvic alignment changes directly impacts postural balance and the pelvis-spine alignment. However, the mechanisms accounting for this association are not fully known.<sup>1,2</sup> In patients with hip osteoarthritis (OA), the primary pain site is difficult to distinguish because of the interaction between the lumbosacral spine and the pelvis.<sup>3</sup> Age is the main risk factor for the development of OA, and the disease can affect up to 30% of people over 60 years old.<sup>4</sup> Since OA is an aging-related common systemic disease, the spine and the hip can be affected simultaneously; as such, a patient presenting degenerative disease symptoms and radiological signs at both sites (spine-hip syndrome) is a diagnostic challenge.<sup>5-7</sup> In addition, the risk of complications after total hip arthroplasty (THA) is higher, resulting in prosthesis dislocation, need for revision THA, periprosthetic fracture, and infection in patients with spinal disease.<sup>6</sup> Thus, the origin of the pain of the patient, whether the hip or the spine, must be identified to define the treatment priority. Radiographic parameters of sagittal and spinopelvic alignment arise as an important tool to increase diagnostic accuracy and guide the correct treatment.<sup>1-14</sup> However, there is not enough data in the literature about the real contribution to the differential diagnosis of spinal and hip lesions. As such, the present study aimed to describe and evaluate radiographic parameters of sagittal and spinopelvic alignment in hip OA patients before and after primary THA, to define whether the procedure should be the primary approach in individuals with concomitant spine and hip joint disease.

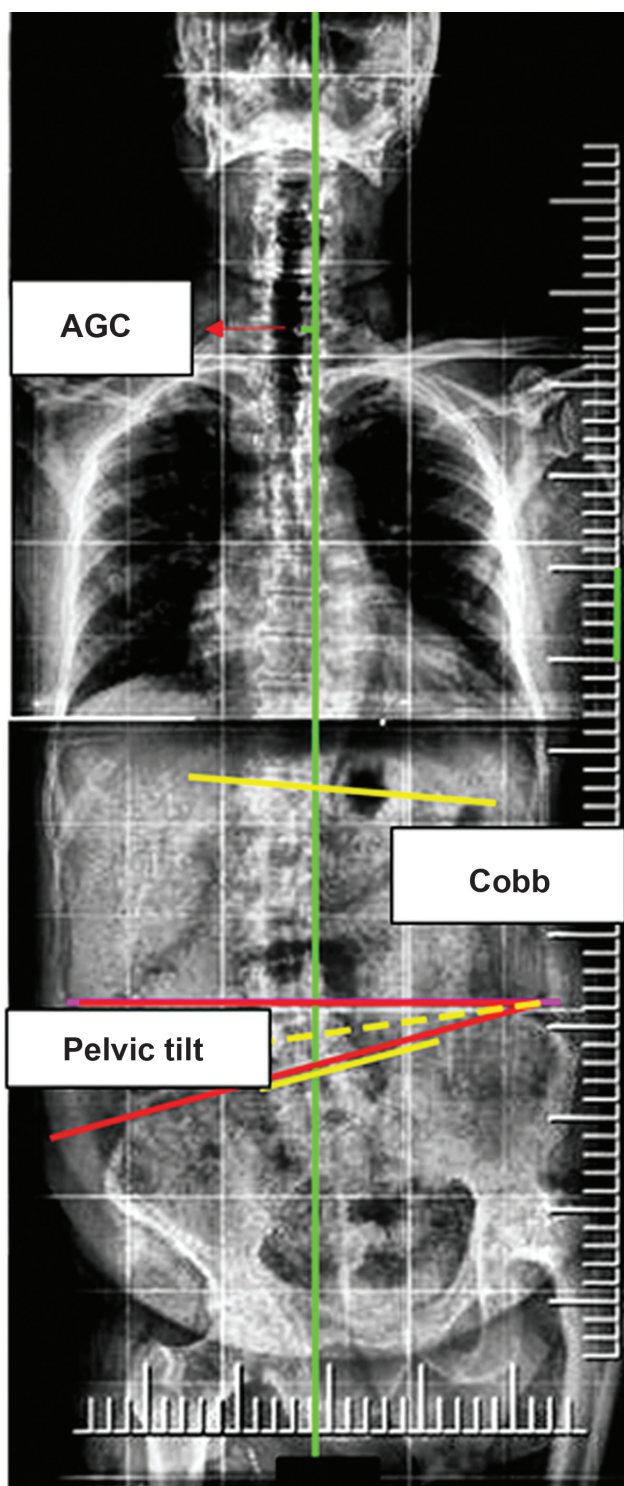
## Materials and Methods

This was a prospective, comparative, longitudinal study involving 27 patients with hip OA undergoing primary

THA and 43 healthy individuals with no hip joint or spine disease. The study protocol was approved by the Research Ethics Committee (58789616.7.0000.5273/2016) and all participants agreed to and signed the Informed Consent Form.

The inclusion criteria were the following: patients with hip OA diagnosis, submitted to primary THA between December 2016 and September 2017; the exclusion criteria were the following: radiological follow-up at < 80 days after THA, poor quality imaging, history of previous surgery, childhood illness or trauma, and patients with neurological conditions. For the control group, the inclusion criteria were the following: age > 18 years old, body mass index (BMI) < 36 kg/m<sup>2</sup> and absence of spine or hip pain or disease; the exclusion criteria were the following: presence of deformities, poor quality imaging, radiological diagnosis of hip or spine disease.

Sociodemographic and clinical information were collected. Panoramic spine radiographs were performed on orthostatic position at anteroposterior (AP) and lateral views, whereas lateral radiographs of lumbar spine-pelvis-hip-proximal femur were obtained in standing and sitting positions. Radiographic parameters (▶ Fig. 1–2 to 3) were measured by two specialist physicians to compare the values obtained before and after THA and with the healthy group. Reference points for radiographic parameters were manually located by steps. At the sagittal view, the femoral heads, the upper plateau of the first sacral vertebra (S1), the upper plateau of the first lumbar vertebra (L1), the upper plateau of the first thoracic vertebra (T1) and the lower plateau of the second cervical vertebra (C2) were identified. At AP view, the midpoint of S1 and the midpoint of the seventh cervical vertebra (C7) were identified. In patients with scoliosis, the vertebrae limits for each curvature (Cobb angle) were identified. In patients with pelvic tilt, the largest iliac wing was identified, and the horizontal measure was obtained manually. The sacrofemoral distance (DSF) was measured manually. The following parameters were automatically calculated by the software: sagittal vertical axis



**Fig. 1** Spinal radiographic parameters in anteroposterior view. Measurements of global coronal alignment (ACG) and Cobb angle are shown in yellow and of pelvic tilt are shown in red.

(EVS), lumbar lordosis (LL), thoracic kyphosis (CT), spinopelvic T1 and T9 tilts (IT1EP, IT9EP), pelvic T1 angle (ATP), global coronal alignment (ACG) and Cobb angle (in orthostatic position, ►Fig. 1 and 2); pelvic version (VP), pelvic incidence (PI), and sacral tilt (IS) (in standing and sitting positions, ►Fig. 3). Pelvis types were classified according to the IP value: type 1 pelvis presented  $< 40^\circ$ , type 2 pelvis

between  $40^\circ$  and  $60^\circ$ , and type 3 pelvis presented an IP  $> 60^\circ$ . The CLP was type 1 if  $\leq 40^\circ$  and type 2 if  $> 40^\circ$ .<sup>10,11</sup> DICOM-encoded digital radiological images were visualized with the eFilm Workstation software (Merge Healthcare, Chicago, IL, USA), version 2.0 in Portuguese, and copied to Surgimap Spine software (Nemaris Inc., New York, NY, USA), version 2.2.13.

Continuous variables were presented as mean  $\pm$  standard deviation (SD) and were evaluated using the Student t-test. Categorical data were expressed as percentages and evaluated using the Pearson chi-squared test ( $\chi^2$ ) or the Fisher exact test. Odds ratios (ORs) and their respective confidence intervals (95% CI) were obtained to assess the magnitude of the association between spinal parameters and OA.

## Results

The mean age of the volunteers with no joint disease was  $35.2 \pm 9.4$  years old (range, 18–56 years old), whereas the mean age of OA patients was  $58.3 \pm 11.4$  years old (range, 37–85 years old). There was no significant difference regarding gender and BMI between the two groups ( $p < 0.05$ ).

The main comorbidities in THA patients were systemic arterial hypertension ( $n = 14$ ), obesity ( $n = 8$ ) and diabetes mellitus ( $n = 6$ ). Nine patients had primary OA, whereas 18 patients presented secondary OA, with 12 cases of femoral head osteonecrosis. Both sides of the hip were equally affected, and one patient presented bilateral disease. The average time of OA evolution was 8.4 years (range, 3–36 years). The average time for the postoperative radiography was 121 days (range, 80–124 days).

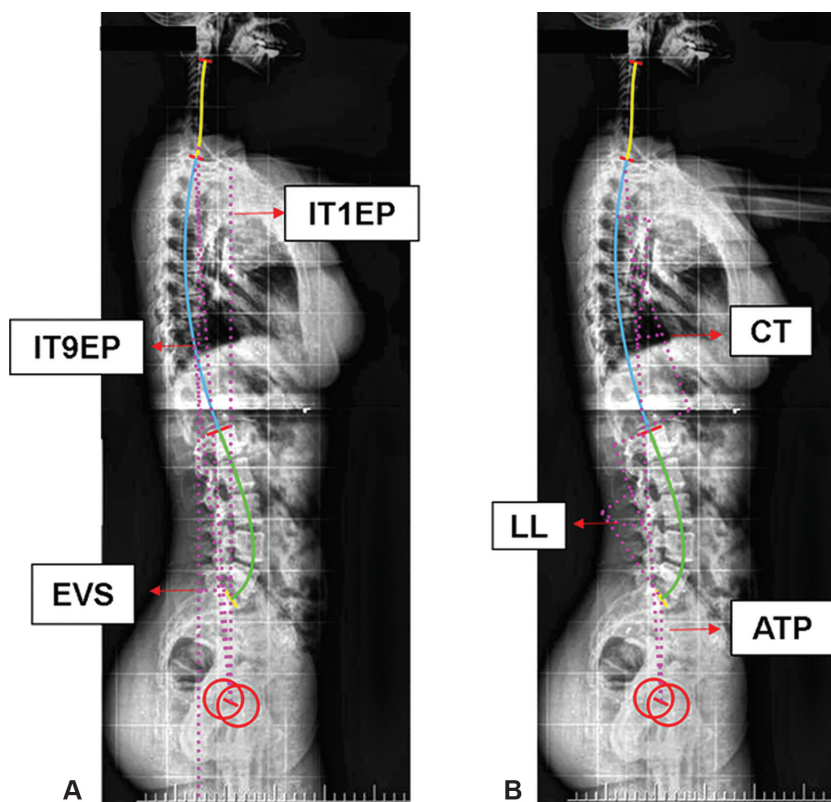
After THA, five out of six patients with radiological diagnosis of scoliosis showed improvement in scoliotic curves, and the deformity was corrected in four of them (Cobb angle  $\leq 10^\circ$ ). Two OA patients also had spondylolisthesis, whereas another three OA patients presented vertebral body collapse. Spinal degenerative changes, such as marginal osteophytes ( $n = 25$ ), intervertebral spaces reduction ( $n = 20$ ) and interapophyseal arthrosis ( $n = 17$ ), were observed. There was a significant difference in the structural parameter of vertebral body height and spinal degenerative changes between OA cases and controls. In OA patients, there was no association between obesity (BMI  $> 30 \text{ kg/m}^2$ ) and spinal degenerative changes.

No association of positive or negative sagittal alignment with hip OA was observed before or after THA. A positive association between pelvic tilt and hip OA was observed before THA (OR = 4.6; CI = 1.3–15.4), but not after THA (OR = 2.3; CI = 0.8–6.5). The radiographic parameter values from the vertebral column panoramic evaluation are detailed in ►Table 1, whereas those from the lumbar spine-pelvis-hip-proximal femur are shown in ►Table 2. No significant difference was observed in pelvis type and lumbopelvic complex type before and after THA or between patients and controls.

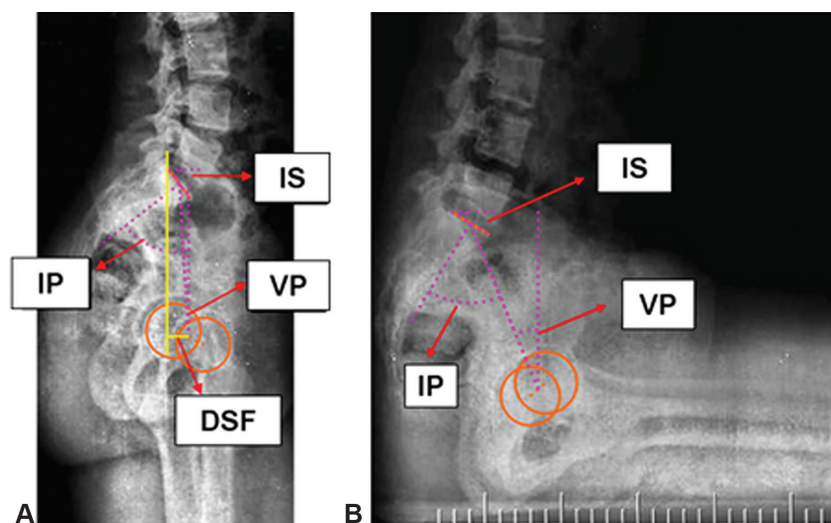
## Discussion

At the THA preoperative evaluation, AP pelvis radiographs under load, AP hip radiographs and lateral radiographs of the





**Fig. 2** Spinal radiographic parameters in lateral view. (A) Sagittal vertical axis (EVS), spinopelvic T1 tilt (IT1EP) and spinopelvic T9 tilt (IT9EP). (B) Thoracic kyphosis (CT), lumbar lordosis (LL) and pelvic T1 angle (ATP).



**Fig. 3** Lumbar spine-pelvis-hip-proximal femur radiographic parameters in lateral view. (A) Standing position. (B) Sitting position. Pelvic incidence (IP); pelvic version (VP); sacral inclination (IS); sacrofemoral distance (DSF).

upper third of the femurs are performed. However, the evaluation of sagittal and spinopelvic alignment radiographic parameters, investigated in panoramic spinal radiographs and lateral lumbar spine-pelvis-hip-proximal femur radiographs (both in standing and sitting position), is not foreseen. This analysis may help clarifying the relationship between spine and hip degenerative diseases.<sup>13</sup> Since THA is one of the main therapeutic options for patients with hip OA, the evaluation of radiographic parameters can be a complementary tool

in the clinical follow-up, particularly in individuals who remain symptomatic after surgery.<sup>12</sup>

Patients with rigid scoliosis are at an increased risk for spinal imbalance after THA due to the abrupt change in pelvic obliquity.<sup>14</sup> A scoliotic curve can be maintained after THA by the concomitance of degenerative changes, impairing the spinopelvic alignment and the compensation of pelvic anteversion parameters. Thus, structured spinal deformities may worsen after THA.<sup>14</sup>

**Table 1** Panoramic evaluation of the spine

Variables	No joint disease	Osteoarthritis	
		Before THA	After THA
Global coronal alignment (mm)	3.1 ± 9.3 (-17.7-23.5)	-1.07 ± 10.9 (-25.7-17.1)	-1.08 ± 17.9 (-33.3-35.4)
Pelvic tilt (°)	2.3 ± 1.1 (0.8-4.8)	4.0 ± 3.2 <sup>a</sup> (1.0-15.5)	2.4 ± 1.2 <sup>b</sup> (0.9-4.9)
Pelvic T1 angle (°)	5.0 ± 8.5 (-14.2-21.8)	6.9 ± 9.0 (-9.6-29.5)	5.5 ± 9.3 (-8.5-35.3)
Thoracic kyphosis (°)	31.2 ± 9.2 (13.2-48.7)	28.3 ± 11.5 (-4.4-47.0)	29.8 ± 11.7 (5.3-47.0)
Sacrofemoral distance (mm)	32.0 ± 16.1 (1.9-65.1)	28.9 ± 17.9 (1.6-65.1)	29.4 ± 18.1 (0.5-84.4)
Sagittal vertical axis (mm)	-9.8 ± 35.9 (-74.7-80.6)	19.1 ± 32.4 <sup>a</sup> (-40.9-82.3)	5.1 ± 36.0 (-66.8-97.9)
Spinopelvic T1 tilt (°)	-5.2 ± 3.3 (-11.4-3.0)	-1.8 ± 3.5 <sup>a</sup> (-8.9-4.9)	-3.1 ± 3.8 <sup>a</sup> (-9.6-6.7)
Spinopelvic T9 tilt (°)	-10.1 ± 3.7 (-18.3-4.8)	-5.8 ± 4.9 <sup>a</sup> (-13.7-3.6)	-7.3 ± 4.8 <sup>a</sup> (-16.3-2.0)
Lumbar lordosis (°)	59.8 ± 9.7 (42.9-85.2)	53.1 ± 26.4 (-57.9-79.1)	60.2 ± 12.5 (31.7-83.9)
C7/DSF ratio	-1.7 ± 4.8 (-22.6-1.4)	0.6 ± 3.6 <sup>a</sup> (-13.6-10.1)	-0.6 ± 6.2 (-28.4-13.0)
IP-LL discrepancy	-10.7 ± 10.4 (-43.1-8.6)	-6.8 ± 13.5 (-32.2-14.2)	-9.7 ± 13.2 (-33.1-21.9)

Abbreviations: DSF, sacrofemoral distance; IP, pelvic incidence; LL, lumbar lordosis; THA, total hip arthroplasty. Values expressed as mean ± standard deviation (maximum and minimum values).

<sup>a</sup>Significantly different compared to the group with no joint disease.

<sup>b</sup>Significantly different compared with before THA.

Recently, Esposito et al.<sup>15</sup> observed that 40% of the patients undergoing primary THA had degenerative spondylodiscopathy at different levels. Our results confirm this association, since the diagnostic parameters of degenerative spine disease (osteophytes, reduced intervertebral space and interapophyseal joint arthrosis) were prevalent in THA patients. Structural spinal changes (vertebral bodies alignment and height) were not associated with hip joint disease.

An asymmetry between the iliac wings (pelvic tilt), seen on frontal view radiographs with the patient standing up, may be secondary to both spinal and hip disease.<sup>16</sup> Pelvic tilt correction with pelvic horizontalization, resulting in different lengths of the lower limbs, contributes significantly to low back pain relief in patients with hip OA.<sup>14</sup> Total hip arthroplasty reduced the pelvic tilt angle to values similar to those observed in volunteers with no joint disease, as described by Abe et al., who reported that 61.5% of a total of 195 patients undergoing primary THA presented pelvic tilt angle correction.<sup>14</sup>

The EVS and C7/DSF ratio were corrected after THA. The correction of these parameters after THA suggests a significant improvement in spinal balance in the sagittal plane.<sup>8</sup>

**Table 2** Lumbar spine-pelvis-hip-proximal femur evaluation

Variables	No joint disease	Osteoarthritis	
		Before THA	After THA
Pelvic incidence (°)	50.1 ± 9.5 (32.3-70.4)	50.4 ± 10.1 (34.6-75.6)	50.4 ± 10.1 (34.6-75.6)
Sacral tilt in standing position (°)	39.4 ± 8.3 (22.0-57.1)	41.8 ± 9.7 (17.4-62.8)	41.8 ± 7.3 (30.3-61.8)
Sacral tilt in sitting position (°)	20.7 ± 12.9 (-6.9-49.2)	8.9 ± 7.8 <sup>a</sup> (-10.1-25.2)	11.7 ± 9.6 <sup>a</sup> (-13.9-28.8)
Pelvic version in standing position (°)	10.7 ± 8.0 (-10.8-25.4)	8.6 ± 9.3 (-7.4-36.0)	8.6 ± 9.9 (-5.6-43.2)
Pelvic version in sitting position (°)	29.4 ± 13.1 (4.2-68.6)	41.5 ± 10.4 <sup>a</sup> (21.4-68.6)	38.6 ± 12.1 <sup>a</sup> (19.2-70.0)

Abbreviation: THA, total hip arthroplasty.

Values expressed as mean ± standard deviation (maximum and minimum values).

<sup>a</sup>Significantly different compared to the group with no joint disease.

Our results on IT1EP and IT9EP angles agree with those from Weng et al.<sup>8</sup> Spinopelvic inclinations were partially corrected, allowing speculation about the potential of THA to promote their complete correction over time. However, longer follow-up studies would be required to establish the temporal relationship between THA and spinopelvic tilt angle normalization.

Although there was no difference between ATP, CT, DSF, LL, IP, IP and LL discrepancy, IS and VP values obtained from patients and volunteers with no joint disease in orthostatic position, all measurements performed after THA were changed and approached reference values. Among these parameters, previous studies<sup>8,9</sup> demonstrated that the LL angle, as in the present study, is not influenced by THA.

Our results showed no relationship between THA and the normalization of the IS and VP angles in radiographs obtained in sitting position. Results for both parameters remained very similar before and after THA. In a study with 89 patients undergoing primary unilateral THA and 100 individuals with no hip disease, although a reduction in pelvic range of motion and pelvic retroversion was observed in operated subjects, there was no parameter normalization, as in the present study. However, the authors emphasize the importance of evaluating this parameter since it conditions acetabular anteversion reduction, which may predispose for the posterior dislocation of the prosthesis.<sup>2</sup>

The VP difference in standing and sitting positions indicates the CLP type. During daily activities, the sagittal range of motion from the trunk to the thighs is divided between the CLP and the hips. Patients with degenerative spinal disease may develop CLP imbalance due to spinal stiffness and consequent compensatory hip overload.<sup>10</sup> In our study, after THA, all of the patients presented a difference > 10° in pelvic version when standing or sitting, indicating a flexible CLP, which may be associated with a low risk of prosthesis impact.<sup>10</sup>

The main limitations of the present study were the sample size and the absence of Harris Hip Score information to correlate imaging findings with hip pain, function, deformity and mobility complaints.

## Conclusion

Spinal deformity may be compensatory for hip changes, since the pelvic tilt, EVS and C7/DSF ratio were corrected after THA. This finding may assist surgeons in deciding on the positioning of the components of the THA in patients with concomitant spinal and hip joint disease.

### Conflict of interests

The authors have no conflict of interests to declare.

## References

- 1 Yoshimoto H, Sato S, Masuda T, et al. Spinopelvic alignment in patients with osteoarthritis of the hip: a radiographic comparison to patients with low back pain. *Spine* 2005;30(14):1650–1657
- 2 Sariali E, Lazennec JY, Khiami F, Gorin M, Catonne Y. Modification of pelvic orientation after total hip replacement in primary osteoarthritis. *Hip Int* 2009;19(03):257–263
- 3 Watelain E, Dujardin F, Babier F, Dubois D, Allard P. Pelvic and lower limb compensatory actions of subjects in an early stage of hip osteoarthritis. *Arch Phys Med Rehabil* 2001;82(12):1705–1711
- 4 Fellet A, Fellet AJF. Osteoartrose: uma revisão. *Rev Bras Med* 2007; 64:55–61
- 5 Redmond JM, Gupta A, Nasser R, Domb BG. The hip-spine connection: understanding its importance in the treatment of hip pathology. *Orthopedics* 2015;38(01):49–55
- 6 Blizzard DJ, Sheets CZ, Seyler TM, et al. The Impact of Lumbar Spine Disease and Deformity on Total Hip Arthroplasty Outcomes. *Orthopedics* 2017;40(03):e520–e525
- 7 Blizzard DJ, Nickel BT, Seyler TM, Bolognesi MP. The Impact of Lumbar Spine Disease and Deformity on Total Hip Arthroplasty Outcomes. *Orthop Clin North Am* 2016;47(01):19–28
- 8 Weng W, Wu H, Wu M, Zhu Y, Qiu Y, Wang W. The effect of total hip arthroplasty on sagittal spinal-pelvic-leg alignment and low back pain in patients with severe hip osteoarthritis. *Eur Spine J* 2016;25(11):3608–3614
- 9 Ben-Galim P, Ben-Galim T, Rand N, et al. Hip-spine syndrome: the effect of total hip replacement surgery on low back pain in severe osteoarthritis of the hip. *Spine* 2007;32(19):2099–2102
- 10 Rivière C, Hardijzer A, Lazennec JY, Beaulé P, Muirhead-Allwood S, Cobb J. Spine-hip relations add understandings to the pathophysiology of femoro-acetabular impingement: A systematic review. *Orthop Traumatol Surg Res* 2017;103(04):549–557
- 11 Rivière C, Lazennec JY, Van Der Straeten C, Auvinet E, Cobb J, Muirhead-Allwood S. The influence of spine-hip relations on total hip replacement: A systematic review. *Orthop Traumatol Surg Res* 2017;103(04):559–568
- 12 Phan D, Bederman SS, Schwarzkopf R. The influence of sagittal spinal deformity on anteversion of the acetabular component in total hip arthroplasty. *Bone Joint J* 2015;97-B(08):1017–1023
- 13 Lazennec JY, Brusson A, Rousseau MA. Hip-spine relations and sagittal balance clinical consequences. *Eur Spine J* 2011;20 (Suppl 5):686–698
- 14 Abe Y, Sato S, Abe S, Masuda T, Yamada K. The impact of the leg-lengthening total hip arthroplasty on the coronal alignment of the spine. *Scoliosis* 2015;10(Suppl 2):S4
- 15 Esposito CI, Miller TT, Kim HJ, et al. Does Degenerative Lumbar Spine Disease Influence Femoroacetabular Flexion in Patients Undergoing Total Hip Arthroplasty? *Clin Orthop Relat Res* 2016; 474(08):1788–1797
- 16 Ormond Filho AG, Gonzalez MT, Homsí C, Stump XMG. Biomecânica e alterações de alinhamento do eixo pelviraquidiano. In: Fernandes JL, Maciel Junior F, Muller CIS, Giuseppe D, Rocha AJ, editores. *Coluna Vertebral. Série Colégio Brasileiro de Radiologia e Diagnóstico por Imagem*. Rio de Janeiro: Elsevier Editora Ltda; 2013:77–106