


Bony Histiocytic Sarcoma of the Scapula: Case Report*

Sarcoma histiocítico ósseo em escápula: relato de caso

Gabriel Severo da Silva¹  Luis José Moura Alimena¹ Bernardo Vaz Peres Alves¹ Alexandre David¹
Roque Domingos Furian²

¹ Orthopedic Oncology Group, Santa Casa de Misericórdia de Porto Alegre, Universidade Federal de Ciências da Saúde de Porto Alegre, Porto Alegre, RS, Brazil

² Laboratory of Pathology and Mycology, Santa Casa de Misericórdia de Porto Alegre, Universidade Federal de Ciências da Saúde de Porto Alegre, Porto Alegre, RS, Brazil

Address for correspondence Gabriel Severo da Silva, Grupo de Oncologia Ortopédica, Santa Casa de Misericórdia de Porto Alegre, Universidade Federal de Ciências da Saúde de Porto Alegre, Porto Alegre, RS, Brazil (e-mail: gabrielseverods@gmail.com).

Rev Bras Ortop 2019;54:95–98.

Abstract

Keywords

- ▶ histiocytic sarcoma/ pathology
- ▶ histiocytic sarcoma/ diagnostic imaging
- ▶ histiocytic sarcoma/ surgery

Resumo

Palavras-chave

- ▶ sarcoma histiocítico/ patologia
- ▶ sarcoma histiocítico/ diagnóstico por imagem
- ▶ sarcoma histiocítico/ cirurgia

Case report of a pediatric patient with a diagnosis of bony histiocytic sarcoma of the scapula, submitted to oncologic resection (Tikhoff-Linberg type II surgery), who returned to previous activities and was disease-free after 24 months of follow-up.


Relato de caso de paciente pediátrico com diagnóstico de sarcoma histiocítico ósseo em escápula, submetido à ressecção oncológica (cirurgia de Tikhoff-Linberg tipo II), com retorno às atividades prévias e livre de doença após 24 meses de seguimento.

Introduction

Histiocytic sarcoma (HS) is a rare, aggressive neoplasm of high grade and hematopoietic origin.^{1,2} With unknown etiology and rapid clinical evolution, HS may present as a localized extranodal disease or as a disseminated disease,^{1,3} associated with

nonspecific systemic symptoms (fever, weight loss, anorexia, asthenia). Although several HS cases have been described, the primary involvement of the bone marrow is exceedingly rare,⁴ as well as its incidence in children.² There are several types of treatment, including surgery, radiotherapy, chemotherapy, and their combinations, with a guarded prognosis.⁴

* Work developed at the Orthopedic and Traumatology Service (Serviço de Ortopedia e Traumatologia), Santa Casa de Porto Alegre, Porto Alegre, RS, Brazil.

 Gabriel Severo da Silva's ORCID: is <https://orcid.org/0000-0002-9508-9858>

Case Report

We report a case of primary bone involvement by HS with a single lesion at the right scapula of a 15-year-old male patient. The patient initially presented with pain and swelling of the

received
May 10, 2017
accepted
July 18, 2017
published online
January 8, 2018

DOI <https://doi.org/10.1016/j.rbo.2017.07.012>.
ISSN 0102-3616.

Copyright © 2019 by Sociedade Brasileira de Ortopedia e Traumatologia. Published by Thieme Revinter Publicações Ltda, Rio de Janeiro, Brazil

License terms



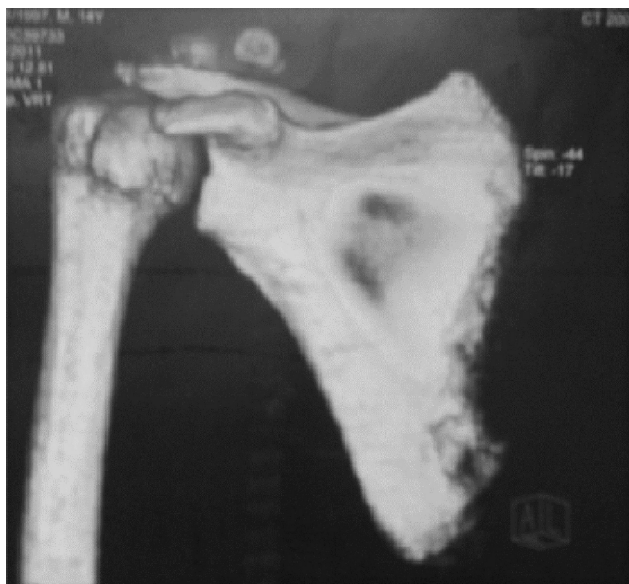

Fig. 1 Computed tomography 3D reconstruction showing the lesion.

region with an approximate evolution of 60 days and pain-induced impairment of the range of motion. About 10 days after the onset of the symptoms, the patient started to present intermittent, nocturnal fever, of $\sim 38^{\circ}\text{C}$ (100.4 F), which remitted with the usual antipyretics. The initial radiography showed a permeative lesion with lytic aspect at the body of the right scapula up to the medial border, with no cortical involvement or periosteal reaction. Imaging techniques were used to evaluate the extension of the disease. A computed tomography (CT) scan (**Fig. 1**) also evidenced a permeative lesion in the location previously noted at the plain radiography, with no associated pathological fracture, infiltrating the adjacent soft tissues. A supplementary imaging study of bone scintigraphy confirmed the presence of a hyperuptake zone at the right scapula. A needle biopsy determined the diagnosis of bony histiocytic sarcoma with the analysis of anatomopathological and immunophenotypic markers.

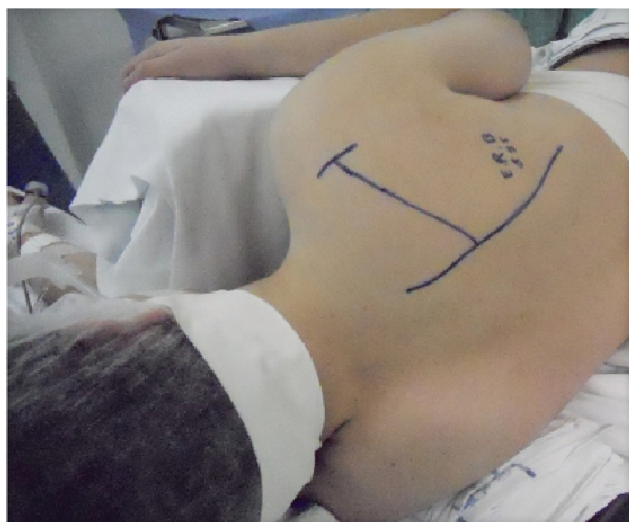

Fig. 2 Surgical planning of the incision.

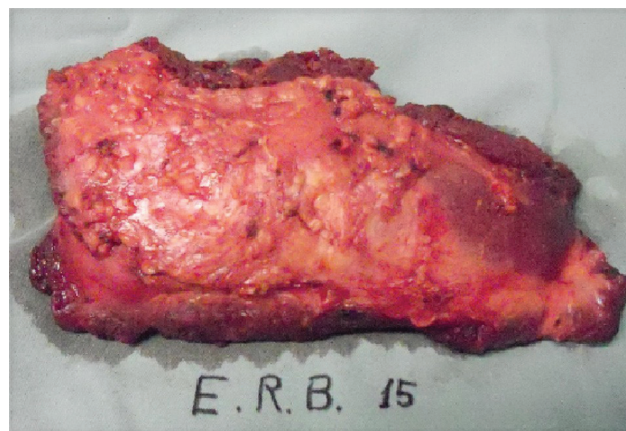

Fig. 3 Resected surgical specimen.

A multidisciplinary team evaluation determined the pre-operative institution of neoadjuvant chemotherapy according to the protocol for Ewing sarcoma. The respective chemotherapy cycles were followed by the surgical treatment according to the modified Tikhoff-Linberg type II technique, with wide tumoral resection and partial amputation of the right scapula (**Figs. 2 and 3**). The patient used a simple Velpeau immobilizer for 8 weeks after the surgery,

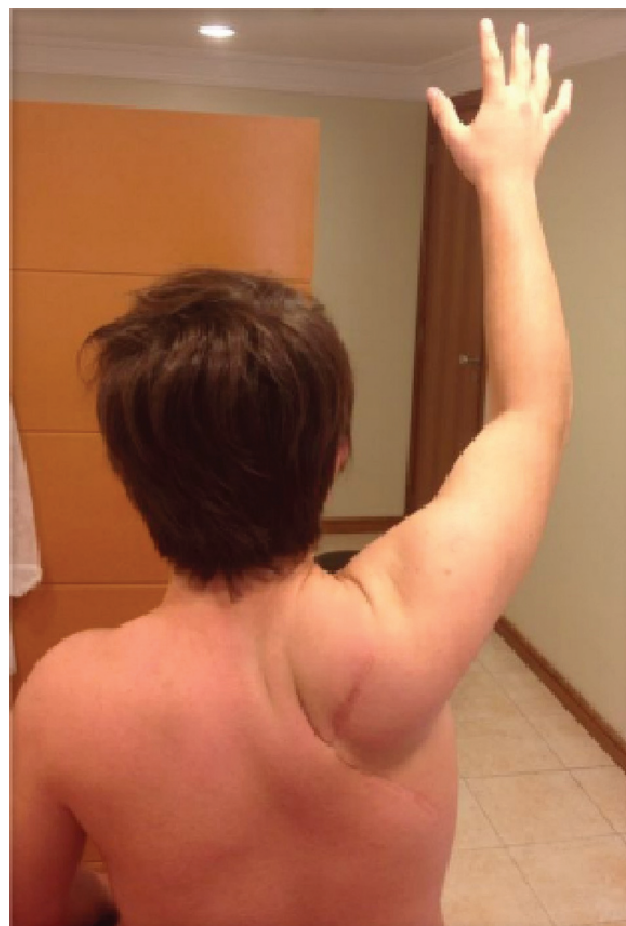

Fig. 4 Residual range of motion after surgical treatment and physical therapy.

followed by a new chemotherapy cycle based on the Brazilian protocol for Ewing sarcoma. At the oncological and subsequent physical therapy follow-up, the patient presented an important improvement of the instrumented limb range of motion and function (► Fig. 4), and no pain.

Twenty-four months after the procedure, the patient was disease-free, totally reintegrated to his social, educational, and sporting activities, asymptomatic, and medically and esthetically satisfied with the treatment.

Discussion

Histiocytic sarcoma represents < 1% of the hematopoietic tumors, and it is characterized by the proliferation of malig-

nant cells with morphological and immunohistochemical patterns based in mature tissue hystiocytes.³ With no well-established etiological factors, HS has an aggressive evolutive character and affects slightly more men than women, with an average age of 46 years old.³ The presentation depends on the affected location.² The extranodal disease might be confined to the skin, to the lymph nodes, and to the intestinal tract.³ The disseminated disease is associated with systemic symptoms, such as hyperthermia, weight loss, anorexia, and asthenia.

Several HS cases were erroneously diagnosed as lymphomas, leukemias or carcinomas.² There are reports of some HS cases with subsequent or coexisting occurrence of lymphoma/B or T cell leukemia.³ The definitive diagnosis of the

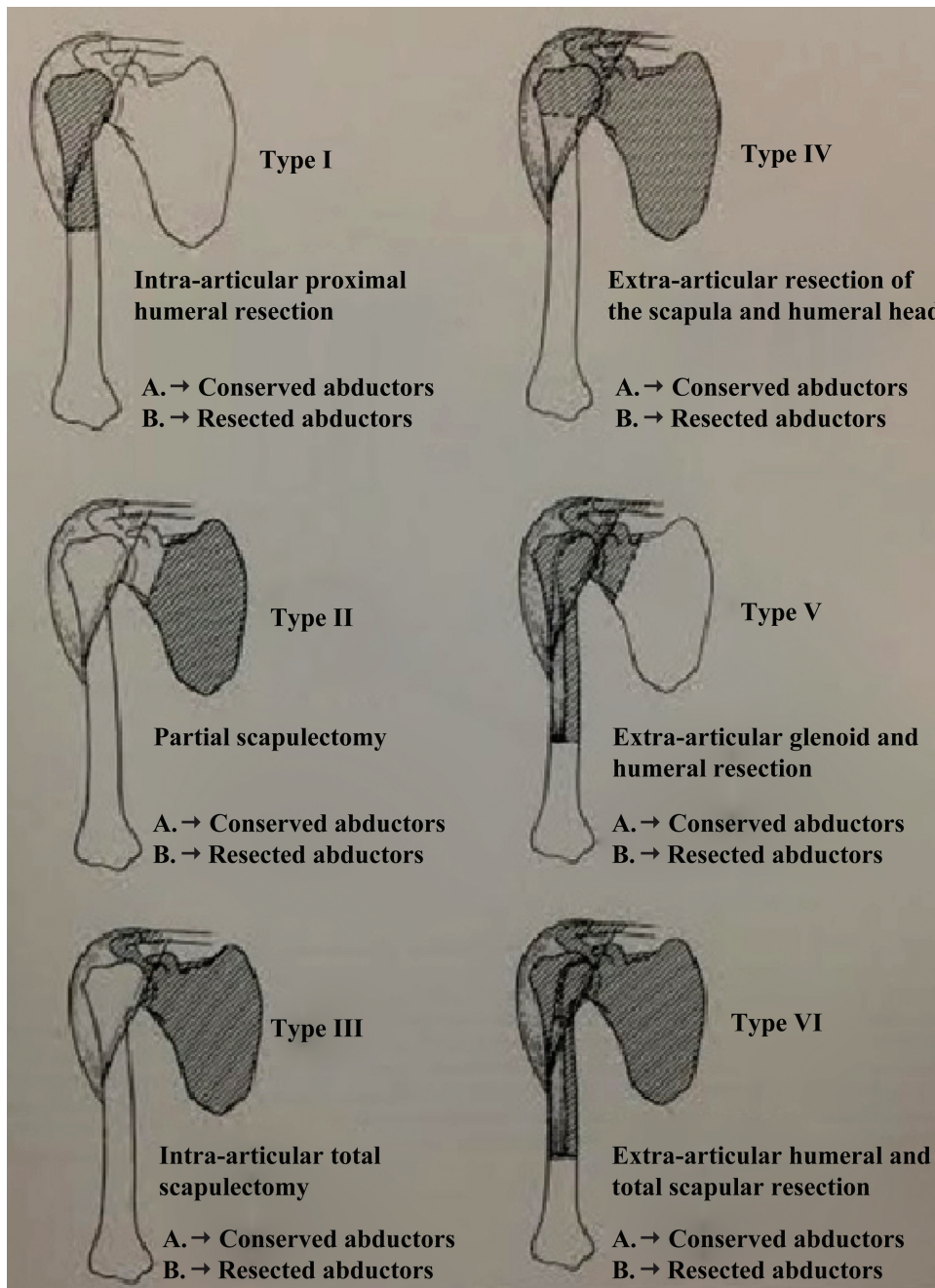


Fig. 5 Tikhoff-Linberg surgery and its modifications.⁶

disease is established by an anatomopathological study of the affected organ: bone marrow biopsy with immunophenotypic analysis.² The disease is characterized by the proliferation of histiocytes with positive expression of macrophage-associated antigen CD68, CD21, and CD35.^{1,3} Histiocytic sarcoma must be morphologically differentiated from inflammatory pseudotumor, dendritic cell sarcomas, malignant Langerhans cells histiocytosis, anaplastic large cell lymphoma, melanoma, and other sarcomas.^{1,3,4}

Histiocytic sarcoma is managed according to its stage and site by different approaches, including surgery, radiotherapy, chemotherapy, and their combinations. The limb-sparing interscapulothoracic resection (Tikhoff-Linberg surgery) is a surgical option for bony and soft parts tumors of the proximal humerus and of the shoulder girdle.⁵ In its classical form, this procedure comprises the resection of the humeral proximal third and the extra-articular removal of the shoulder joint, of the distal third of the clavicle, and of the whole scapula and their adjacent soft parts.^{5,6} The selected patients must not present tumor in the thoracic wall and in the neurovascular bundle. The area may be reconstructed with a nonconventional endoprosthesis or with a homologous bone from a bank; moreover, the area may not be reconstructed with foreign materials.⁵ Resection levels are variable and depend on the extension of the tumor (→ Fig. 5). Hand and forearm postsurgical function is partially preserved, with elbow flexion and shoulder stability requiring or not an orthosis, and through careful myotomies, myorrhaphies, and residual myoplasties.^{5,6} The main postoperative problem is neurapraxia due to nerve traction during dissection, which normally improves over the first weeks after the procedure.⁶ However, Tikhoff-Linberg type II surgery, or medial partial scapulectomy, does not cause this traction, since most of the shoulder girdle is preserved.

The bad prognosis of HS, especially in the disseminated presentation, results from the difficult systematization of a standard therapeutic protocol with good response.^{1,4} In

such cases, most patients die from the progressive disease in approximately 2 years.^{2,3} The localized disease has a favorable prognosis,⁴ often associating adjuvant methods (chemotherapy or radiotherapy) with oncological surgical resection.

Considering the rare nature of the disease and its epidemiological peculiarity, we emphasize the need to refer this kind of patient to a reference center in orthopedic oncology hoping to obtain outcomes as satisfactory as those presented here. Tikhoff-Linberg type II surgery, or medial partial scapulectomy, is a surgical procedure that is an option to interscapulothoracic amputation for large tumors in the scapulohumeral region with no invasion of the axillar neurovascular bundle.^{5,6}

Conflicts of Interest

The authors have no conflicts of interest to declare.

References

- 1 Sohn BS, Kim T, Kim JE, Bae E, Park CJ, Huh J, et al. A case of histiocytic sarcoma presenting with primary bone marrow involvement. *J Korean Med Sci* 2010;25(2):313–6
- 2 Bhalla V, Khan N, Jones M, Kumar A, Latifaj B, Colmenero I, et al. A rare case of paediatric histiocytic sarcoma of the maxilla and mandible. *Dentomaxillofac Radiol* 2016;11:20150393
- 3 Takahashi E, Nakamura S. Histiocytic sarcoma: an updated literature review based on the 2008 WHO classification. *J Clin Exp Hematop* 2013;53(1):1–8
- 4 Kaushal R, Jambhekar NA, Rao S, Raju S, Suryawanshi P, Shet T, et al. Primary extranodal histiocytic sarcoma of lumbar spine. *Skeletal Radiol* 2012;41(2):231–5
- 5 Voggenreiter G, Assenmacher S, Schmit-Neuerburg KP. Tikhoff-Linberg procedure for bone and soft tissue tumors of the shoulder girdle. *Arch Surg* 1999;134(3):252–7
- 6 Sugarbaker P, Malawer M. Cirurgia de Tikhoff-Linberg e suas modificações. In: Malawer MM, Sugarbaker PH, Lopes A, editors. *Atlas de cirurgia para sarcomas ósseos e de partes moles*. São Paulo: Lemar; 2003:373–88