

# Incidence of Meniscal Ramp Lesion in Anterior Cruciate Ligament Reconstructions\*

## *Incidência de lesões da rampa meniscal nas reconstruções do ligamento cruzado anterior*

Felipe Galvão Abreu<sup>1</sup> Sérgio Marinho de Gusmão Canuto<sup>2</sup> Maira Macedo de Gusmão Canuto<sup>2</sup>  
Eduardo Federighi Chagas<sup>3</sup> Tereza Lais Menegucci Zutin<sup>4</sup> Vitor Barion Castro de Pádua<sup>4</sup>

<sup>1</sup>Clínica Sportsmed, São José do Rio Preto, SP, Brazil

<sup>2</sup>Ortoclínica Hospital de Ortopedia, Maceió, AL, Brazil

<sup>3</sup>Department of Physical Education, Universidade de Marília, Marília, SP, Brazil

<sup>4</sup>Department of Orthopedics and Traumatology, Universidade de Marília, Marília, SP, Brazil

**Address for correspondence** Felipe Galvão Abreu, MD, Av. Juscelino Kubitschek de Oliveira, 5.000, Sala 509, Complexo Iguatemi, São José do Rio Preto, SP, 15093-270, Brazil  
(e-mail: dr.felipegalvao@hotmail.com).

Rev Bras Ortop 2022;57(3):422–428.

### Abstract

**Objective** To evaluate the incidence and epidemiological profile of meniscal ramp lesions in patients undergoing anterior cruciate ligament (ACL) reconstruction surgery, and to determine the related risk factors.

**Methods** In total, 824 patients undergoing ACL reconstruction surgery were retrospectively analyzed. Patients who presented medial meniscal instability were submitted to evaluation of the posteromedial compartment of the knee. In case of injury, surgical repair was performed. Potential risk factors associated with the lesions were analyzed.

**Results** The overall incidence of ramp lesions in the population studied was of 10.6% (87 lesions in 824 patients). The multivariate analysis through the Chi-squared test showed that the presence of meniscal ramp lesions was significantly associated with the following risk factors: right laterality and chronic lesions. Gender, age and sports activity were not statistically significant. Soccer was the most frequent cause of ramp injuries related to sport, with 78.2% of the cases. However, it was not shown to be a risk factor. The annual incidence from 2014 to 2019 ranged from 4.0% to 20.6%.

**Conclusion** The incidence of meniscal ramp lesions was of 10.6% in ACL reconstruction surgeries, being more frequent among patients with chronic lesions. The increasing annual incidence ranged from 4.0% in 2014 to 20.6% in 2019.

### Keywords

- ▶ arthroscopy
- ▶ epidemiology
- ▶ knee
- ▶ suture

\* Work developed at Clínica Sportsmed, São José do Rio Preto, SP; at the Department of Orthopedics and Traumatology, Universidade de Marília, Marília, SP; and Ortoclínica Hospital de Ortopedia, Maceió, AL, Brazil.

received  
December 4, 2020  
accepted  
June 2, 2021  
published online  
January 20, 2022

DOI <https://doi.org/10.1055/s-0041-1735942>.  
ISSN 0102-3616.

© 2022. Sociedade Brasileira de Ortopedia e Traumatologia. All rights reserved.

This is an open access article published by Thieme under the terms of the Creative Commons Attribution-NonDerivative-NonCommercial-License, permitting copying and reproduction so long as the original work is given appropriate credit. Contents may not be used for commercial purposes, or adapted, remixed, transformed or built upon. (<https://creativecommons.org/licenses/by-nc-nd/4.0/>)

Thieme Revinter Publicações Ltda., Rua do Matoso 170, Rio de Janeiro, RJ, CEP 20270-135, Brazil

**Resumo**

**Objetivo** Avaliar a incidência e o perfil epidemiológico das lesões da rampa meniscal nos pacientes submetidos a cirurgia de reconstrução do ligamento cruzado anterior (LCA), e determinar os fatores de risco relacionados.

**Métodos** Foram analisados retrospectivamente 824 pacientes submetidos a cirurgia de reconstrução do LCA. Os pacientes que apresentaram instabilidade meniscal medial foram submetidos a avaliação do compartimento posteromedial do joelho. Em caso de lesão, o reparo cirúrgico foi realizado. Potenciais fatores de risco associados às lesões foram analisados.

**Resultados** A incidência geral de lesões da rampa na população estudada foi de 10,6% (87 lesões em 824 pacientes). A análise multivariada pelo teste do Qui-quadrado demonstrou que a presença de lesões da rampa meniscal foi significativamente associada aos seguintes fatores de risco: lateralidade direita e lesões crônicas. Sexo, idade e atividade esportiva não foram estatisticamente significantes. O futebol foi a causa mais frequente de lesões da rampa relacionadas ao esporte, com 78,2% dos casos. No entanto, não se mostrou ser um fator de risco. De 2014 a 2019, a incidência anual variou de 4,0% a 20,6%.

**Conclusão** A incidência das lesões da rampa meniscal foi de 10,6% nas cirurgias de reconstrução do LCA, sendo mais frequente em pacientes com lesões crônicas. A incidência anual foi crescente, e variou de 4,0%, em 2014, a 20,6%, em 2019.

**Palavras-chave**

- ▶ artroscopia
- ▶ epidemiologia
- ▶ joelho
- ▶ sutura

**Introduction**

Meniscal ramp lesions are commonly associated with anterior cruciate ligament (ACL) ruptures. A ramp lesion consists of meniscosynovial or meniscocapsular ruptures, which can be difficult to diagnose arthroscopically from the anterior compartment, and which significantly increase the antero-posterior and rotational instability of the knee when compared to isolated ACL lesions.<sup>1-4</sup> Initially studied by Hamberg (apud Strobel<sup>5</sup>), the term “ramp lesion” was firstly attributed to these lesions to differentiate them from other classical lesions of the posterior part of the medial meniscus.

Although there is a long history of recognition of meniscal ramp lesions, the topic has been little studied in recent decades. This lack of previous importance attributed to the topic is a consequence of factors such as the low sensitivity of magnetic resonance imaging (MRI), with a high number of false-negatives, insufficient knowledge about its biomechanical consequences, and an intuitive sense that these lesions can heal spontaneously.<sup>3,6</sup> In addition, the lesion is located in a “blind spot” of the posteromedial compartment of the knee, which makes it difficult to visualize through conventional arthroscopic portals, requiring the surgeon to have a more accurate technical ability to access and repair.<sup>7</sup> In 2014, Sonnery-Cottet et al.<sup>8</sup> introduced the concept of “occult lesions”, for meniscal ramp lesions that are not visible by conventional arthroscopic approaches, proposing a systematic exploration of the posterior segment of the medial meniscus by a posteromedial arthroscopy route.

The precise diagnosis of ramp lesions is also a challenge for radiologists. In 2017, DePhillippo et al.<sup>9</sup> published an

article showing a poor correlation between imaging and arthroscopy, with more than half of the cases being underdiagnosed preoperatively. Edema in the bone marrow in the posteromedial region of the medial tibial plateau appears to be a suggestive radiological sign, being present in 72% of the cases of meniscal ramp lesion.<sup>9</sup>

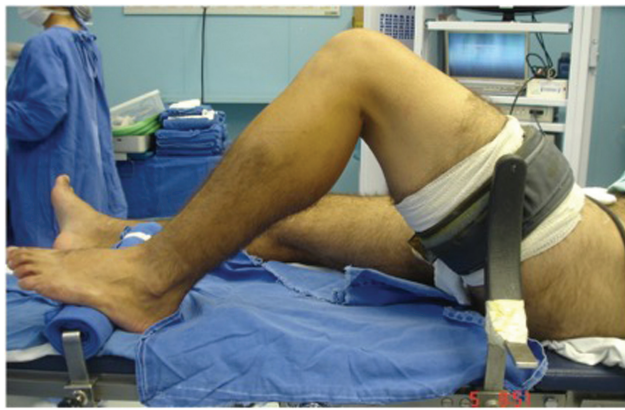Although there are still no data on the epidemiology of ramp lesions in the Brazilian population, the international literature shows an incidence between 9% and 24% in ACL reconstructions (ACLRs).<sup>1,6,7,10</sup> The aim of the present study is to evaluate the incidence and epidemiological profile of meniscal ramp lesions in patients undergoing ACLR, and to identify possible risk factors associated with these lesions.

**Materials and Methods**

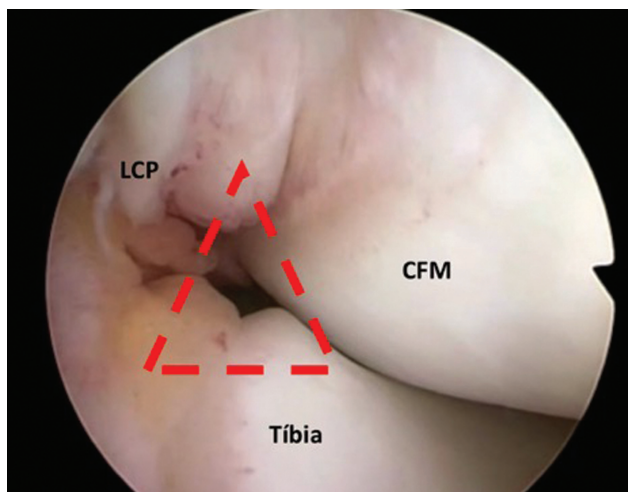
A retrospective analysis of the data of 824 ACLRs was performed through a consultation of hospital records. The inclusion criterion was patients submitted to primary or revision ACLR between July 2014 and April 2020. Patients undergoing concomitant surgeries, such as multiligament reconstructions or osteotomies, were excluded. Preoperatively, all patients had a complete rupture of the ACL, diagnosed based on clinical examination and MRI scans. The study was approved by plataforma Brasil under CAAE number 27216819.2.0000.5496

**Surgical Technique**

The surgical procedures were performed by two surgeons who are specialists in knee surgery and have great experience in ACLRs. The patients were positioned in a standard



**Fig. 1** Lateral view of the position of the lower limb during reconstruction of the anterior cruciate ligament (ACL), with the foot resting on the operating table, lateral support at the level of the tourniquet, and the knee at 90° of flexion.



**Fig. 2** Arthroscopy image of the space in the defined intercondylar space through which the arthroscope is inserted to access the posteromedial compartment of the knee. The correct point is identified in the center of a triangle (in red) formed by the medial femoral condyle (MFC), the posterior cruciate ligament (PCL), and the tibia.

way for arthroscopy (►Figure 1). Meniscal and/or clinker lesions were addressed before ligament reconstruction.

Initially, arthroscopic exploration of the knee compartments was performed. In cases on which there was any sign of meniscal instability, such as increased anterior displacement under traction, or when a fissure was observed in its lower leaflet, an investigation was carried out in the posteromedial compartment, as proposed by Sonnery-Cottet et al.<sup>8</sup> For the evaluation of the posteromedial compartment of the knee, the arthroscope is maintained in the anterolateral portal and inserted through a space in the intercondyle defined by the medial femoral condyle, posterior cruciate ligament (PCL), and tibia (►Figure 2).

In cases in which a meniscus fissure (ramp injury) was observed, repair was performed. When there was also suspicion of the presence of a hidden ramp injury (type D),<sup>11</sup> meniscal integrity was tested with a needle, and then with a

probe, inserted through a posteromedial portal. The preparation of the posteromedial portal was made through transillumination, which assists in the visualization of veins or nerves that must be preserved (►Figure 3). The shaver blade was then inserted through the posteromedial portal, and both surfaces of the lesion were scraped (►Figure 4).

For the sutures, a 25° suture hook (SutureLasso, Arthrex, Naples, FL, United States) loaded with an absorbable monofilament thread no. 1 (PDS, Ethicon, Inc., Somerville, NJ, United States) was used. The preparation of the stitches with sliding knots was carried out with the help of a knot pusher (►Figure 5). The satisfactory and stable repair was confirmed by evaluation using the probe inserted through the anterolateral and posteromedial portals. Finally, the ACLR procedure was performed with the preparation of independent anatomical tunnels (outside-in), according to the Chambat technique.<sup>12,13</sup> Patients submitted to ramp lesion repair followed the same rehabilitation protocol.

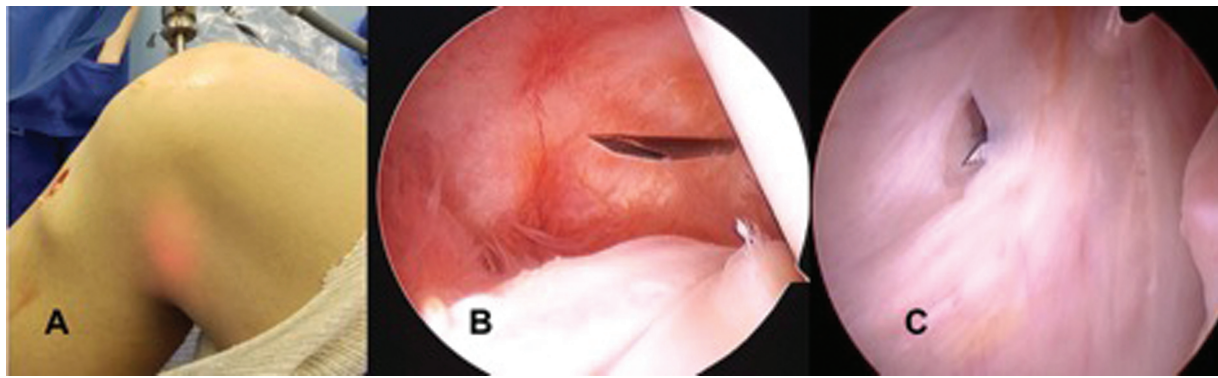
### Statistical Analysis

The quantitative variables were described by means and minimum and maximum values. The qualitative variables were described by the distribution of absolute and relative frequencies (%). The analysis of the relationship among the qualitative variables was performed by the Chi-squared association test. The total and yearly proportions of cases were analyzed by the incidence rates and their respective 95% confidence intervals (95% CIs), and they were calculated by dividing the number of confirmed cases and the aggregate of the population exposed in the period and expressed by 100. The level of statistical significance adopted was of 5%, and the data were analyzed using the Statistical Package for the Social Sciences (IBM SPSS Statistics for Windows, IBM Corp., Armonk, NY, United States) software, version 24.0.

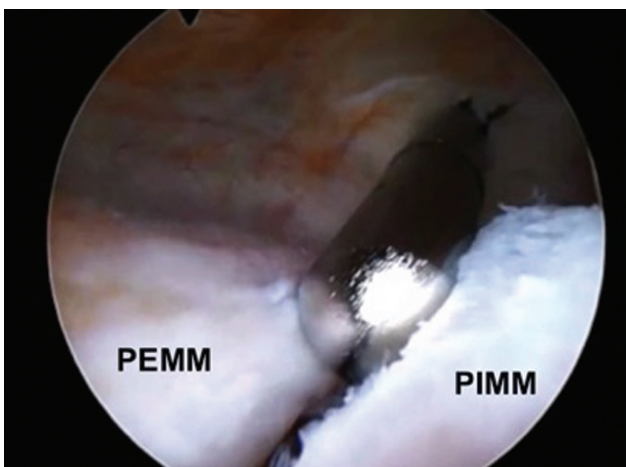
### Results

The total number of patients submitted to ACLR included in the present study was 824. Meniscal ramp lesion was observed and repaired in 87 (10.6%) patients. The characteristics of the patients diagnosed with ramp lesion are shown in ►Table 1.

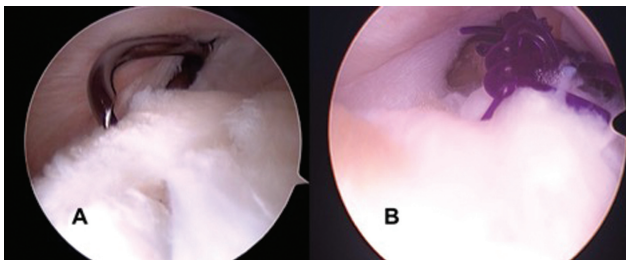
Of the total number of patients with meniscal ramp injury, 76 (87.3%) were male, and 11 (12.7%), female. The mean age in this group was of 29.9 years (range: 17 to 49 years). From the 87 ACL reconstructions with associated ramp injury, 80 (91.9%) were primary surgeries, and 7 (8.1%) were reviews, but with no statistical significance between the groups ( $p = 0.562$ ). Regarding laterality, the right knee was affected in 61 cases (70.1%), and the left knee in 26 (29.9%), which was statistically significant ( $p = 0.008$ ). The time between the lesion and ACLR was also statistically significant ( $p = 0.008$ ). In cases in which there was ramp injury, this time was of up to 3 months (28 cases; 32.2%); between 4 and 6 months (14 cases; 16.1%); between 7 and 12 months (15 cases; 17.2%); between 13 and 24 months 14 cases; 16.1%;



**Fig. 3** Details of the opening of the posteromedial portal, with the arthroscope inserted in the posteromedial compartment of the knee. (A) The use of transillumination prevents iatrogenic injury to vessels and nerves. (B) The needle is inserted in the direction of the lesion, to define the best point to create the portal. (C) Under direct view, the portal is created with the use of a scalpel blade.



**Fig. 4** Arthroscopy image, with the arthroscope located in the posteromedial compartment of the knee, evidencing the meniscal ramp lesion. The scraping and regularization of the edges of the meniscal ramp lesion is performed with a shaver blade. The outer portion of the medial meniscus (OMM) and the inner portion of the medial meniscus (IMM) are clearly visualized in the image.



**Fig. 5** Arthroscopic image of the suture in the repair of the ramp lesion through the posteromedial portal of the knee. (A) The 25° suture hook (SutureLasso, Arthrex, Naples, FL, United States) is inserted through posteromedial portal for the repair of the lesion. (B) The suture is performed with the use of simple stitches, and with the aid of a knot pusher (B).

**Table 1** Characteristics of the patients submitted to anterior cruciate ligament (ACL) reconstruction with and without associated meniscal ramp lesion

Characteristics	With injury - n (%)	No injury - n (%)	p-value
<i>Gender</i>			
Male	76 (87.3%)	631 (85.6%)	0.718
Female	11 (12.7%)	109 (14.4%)	
<i>Laterality</i>			
Right	61 (70.1%)	403 (54.7%)	0.008*
Left	26 (29.9%)	337 (45.3%)	
<i>Ligament reconstruction</i>			
Primary	80 (91.9%)	694 (94.2%)	0.562
Revision	7 (8.1%)	43 (5.4%)	
<i>Age (years)</i>			
< 20	6 (6.9%)	102 (13.8%)	0.053
20–30	44 (50.6%)	267 (36.2%)	
31–40	26 (29.9%)	255 (34.6%)	
> 40	11 (12.6%)	119 (15.4%)	
Average	29.9 (17–49)	31.4 (13–71)	
<i>Injury time (months)</i>			
≤ 3	28 (32.2%)	362 (49.1%)	0.008*
4–6	14 (16.1%)	102 (13.8%)	
7–12	15 (17.2%)	79 (10.7%)	
13–24	14 (16.1%)	58 (7.9%)	
> 24	16 (18.4%)	136 (18.5%)	
Average	16.4 (1–120)	19.7 (1–360)	

Note: \*Significant association according to the Chi-squared test for  $p \leq 0.05$ .

and longer than 24 months (16 cases; 18.4%), with an average of 16.4 months (range: 1 to 120 months). In cases in which ramp lesions were not diagnosed, 362 (49.1%) had up to 3 months of injury; 102 (13.8%), from 4 to 6 months; 79

(10.7%), from 7 to 12 months; 58 (7.9%), from 13 to 24; and 136 (18.5%), for more than 24 months, with an average of 19.7 months (range: 1 to 360 months).

**Table 2** Causes of rupture of the anterior cruciate ligament (ACL)

Non-sport-related trauma	With injury – n (%)	No injury – n (%)	p-value
Fall	7 (5.9%)	64 (54.2%)	0.939
Traffic accident	4 (3.4%)	43 (36.5%)	
Total (100%)	11 (9.3%)	107 (90.7%)	
Sport-related trauma	With injury – n (%)	No injury – n (%)	p-value
Soccer	68 (9.6%)	548 (77.6%)	0.599
Wrestling	3 (0.4%)	25 (3.5%)	
Basketball	1 (0.1%)	14 (2.0%)	
Other	4 (0.7%)	43 (6.1%)	
Total (100%)	76 (10.8%)	630 (89.2%)	

**Table 3** Annual incidence rate of ramp lesions

Year	Total exposed (n)	Ramp lesion (n)	Incidence (%)	95%CI	
				LL	UL
2014	124	5	4.00	1.70	9.10
2015	89	4	4.50	1.80	11.00
2016	110	12	10.90	6.40	18.10
2017	104	12	11.50	6.70	19.10
2018	116	6	5.20	2.40	10.80
2019	281	48	20.60	15.10	21.90
Total	824	87	10.60	8.60	12.80

Abbreviations: 95%CI, 95% confidence interval%; LL, lower limit; UL, upper limit.

Trauma related to sports or physical activities accounted for 76 (87.4%) of the total number of cases. Among these, soccer was the most frequent cause, with 68 cases (78.2%) ( $p=0.599$ ). Wrestling was the cause of 3 cases (3.4%); basketball, of 1 case (1.1%); and other sports, such as volleyball, handball, rugby and cycling, of 4 cases (4.7%). Among the causes not related to sports, there were 11 cases (9.3% of the total): 7 (5.9%) due to falls, and 4 (3.4%) due to traffic accidents (► **Table 2**).

The annual incidence rate is illustrated in ► **Table 3**, and shows that, apart from 2018 (5.2%), there was a progressive increase in the incidence of ramp injuries, ranging from 4.0% in 2014 to 20.6% in 2019.

## Discussion

The main findings of the present study were the incidence of meniscal ramp lesions in 10.6% of the patients with ACL injuries, and the highest incidence among those with chronic ACL lesions. Other authors reported values between 9% and

24%.<sup>1,6,9,10,14–16</sup> Bollen<sup>6</sup> and Di Vico et al.,<sup>15</sup> reported lower incidences, of 9.3% and 9.6% respectively. Both studies included a smaller sample, respectively of 183 and 115 patients. Liu et al.,<sup>10</sup> with a sample of 868 patients, observed an incidence of 16.6%, which is closer to that found in the present study. The studies that found the highest incidences were those by Seil et al.<sup>14</sup> and by Sonnery-Cottet et al.,<sup>1</sup> both with 24% of cases of ACL injury, and analyzing 224 and 3,214 patients respectively. This great variation in the results found in the literature may be the result of certain factors, such as the experience and ability of the surgeons to diagnose the lesion during the arthroscopic procedure, and the number of patients included in the sample. It was evident in the present study that there was an important annual increase in the incidence of ramp injuries, from 4% to 20.6%. This is attributed to the fact that the more familiar and experienced the surgeon is in investigating and repairing this injury, the greater the number of diagnoses.<sup>17</sup>

The follow-up of patients submitted to ACLR, with the medial meniscus initially considered healthy, showed that some patients still degrade the medial meniscus, although the knee seems clinically stable.<sup>18</sup> This demonstrates that part of the lesions are underdiagnosed.

Regarding risk factors, it is known that the time between injury and ACLR is associated with an increasing incidence of medial meniscus lesions.<sup>1,19,20</sup> Church and Keating<sup>21</sup> found an increase in the number of all types of meniscal lesions after twelve months, recommending early ACLR to avoid these lesions. Liu et al.<sup>10</sup> showed that, within 24 months between the ACL injury and surgery, there was an increase in the incidence of ramp injuries. In the present study, we identified that, of the cases in which this time was shorter than 3 months, 32.2% had meniscal ramp lesion, while 49.1% had no signs of injury. In chronic cases, with a time longer than 3 months, there was a proportional increase in cases with ramp injury (67.8%) compared to cases in which the meniscus was intact (50.9%) ( $p=0.008$ ).

Regarding the review cases, the literature<sup>22–24</sup> shows that knees submitted to ACL review have more intra-articular lesions than knees submitted to primary reconstruction. Wright et al.<sup>25</sup> showed that up to 90% of the ACL revision cases presented a meniscal or condral lesion, while 57% had both lesions at the time of surgery. Like Sonnery-Cottet et al.,<sup>1</sup> we chose to include in the study patients submitted to ACL review, seeking to evaluate whether this could also be considered a risk factor. Interestingly, the data found in the present study did not show a higher incidence when it comes specifically to meniscal ramp lesions in review cases ( $p=0.562$ ).

Despite the incidence of 10.6% of ACL reconstruction surgeries, the annual incidence in the period studied ranged from 4.0% in 2014 to 20.6% in 2019. This escalation in the number of cases draws attention, and may demonstrate a significant learning curve in the diagnosis and treatment of these lesions. Therefore, we recommend the establishment of routine systematic inspections of the posteromedial compartment of the knee in ACL reconstructions, especially in chronic cases.

The present study has some limitations. During the first years, some cases may have been underdiagnosed, due to the learning curve, presenting an incidence slightly below the real one. Moreover, although both surgeons had great experience in ACLRs, they were not necessarily at the same point of the learning curve for the diagnosis and repair of meniscal ramp lesions during the period studied. This may have influenced the final result and the annual incidence. Another possible bias is the fact that both surgeons are right-handed, which may justify the greater number (statistically significant) of right laterality, perhaps because it was easier from a technical point of view, or because of the preference of the surgeons in the first cases. The present study also has strengths, such as the significant sample (824 patients) compared to the samples of other similar epidemiological studies in the literature. The fact that the study involved more than one service strengthens the article, which analyzes the epidemiology of these lesions under the same arthroscopic exploration protocol, however, in different regions of the Brazilian territory. In any case, further epidemiological studies should be conducted in different centers and regions of Brazil. With a more information and data from different knee surgeons, there will be a better understanding of the risk factors and the incidence of meniscal ramp injuries among the Brazilian population.

## Conclusion

The incidence of meniscal ramp lesions was of 10.6% in ACLRs, being more frequent in chronic lesions. The annual incidence in the period studied ranged from 4.0% in 2014 to 20.6% in 2019.

### Financial Support

The authors have no sources of funding to declare.

### Conflict of Interests

The authors have no conflict of interests to declare.

## References

- Sonnery-Cottet B, Praz C, Rosenstiel N, et al. Epidemiological Evaluation of Meniscal Ramp Lesions in 3214 Anterior Cruciate Ligament-Injured Knees From the SANTI Study Group Database: A Risk Factor Analysis and Study of Secondary Meniscectomy Rates Following 769 Ramp Repairs. *Am J Sports Med* 2018;46(13):3189–3197
- Mouton C, Magosch A, Pape D, Hoffmann A, Nührenböcker C, Seil R. Ramp lesions of the medial meniscus are associated with a higher grade of dynamic rotatory laxity in ACL-injured patients in comparison to patients with an isolated injury. *Knee Surg Sports Traumatol Arthrosc* 2020;28(04):1023–1028
- Sonnery-Cottet B, Serra Cruz R, Vieira TD, Goes RA, Saithna A. Ramp Lesions: An Unrecognized Posteromedial Instability? *Clin Sports Med* 2020;39(01):69–81
- Ahn JH, Bae TS, Kang KS, Kang SY, Lee SH. Longitudinal tear of the medial meniscus posterior horn in the anterior cruciate ligament-deficient knee significantly influences anterior stability. *Am J Sports Med* 2011;39(10):2187–2193
- Strobel MJ. Menisci. In: Fett HM, Flechtner P, eds. *Manual of Arthroscopy Surgery*. New York: Springer; 1988:171–178
- Bollen SR. Posteromedial meniscocapsular injury associated with rupture of the anterior cruciate ligament: a previously unrecognized association. *J Bone Joint Surg Br* 2010;92(02):222–223
- Chahla J, Dean CS, Moatshe G, et al. Meniscal Ramp Lesions: Anatomy, Incidence, Diagnosis, and Treatment. *Orthop J Sports Med* 2016;4(07):2325967116657815
- Sonnery-Cottet B, Contedua J, Thauat M, Gunepin FX, Seil R. Hidden lesions of the posterior horn of the medial meniscus: a systematic arthroscopic exploration of the concealed portion of the knee. *Am J Sports Med* 2014;42(04):921–926
- DePhillipo NN, Cinque ME, Chahla J, Geeslin AG, Engebretsen L, LaPrade RF. Incidence and Detection of Meniscal Ramp Lesions on Magnetic Resonance Imaging in Patients With Anterior Cruciate Ligament Reconstruction. *Am J Sports Med* 2017;45(10):2233–2237
- Liu X, Feng H, Zhang H, Hong L, Wang XS, Zhang J. Arthroscopic prevalence of ramp lesion in 868 patients with anterior cruciate ligament injury. *Am J Sports Med* 2011;39(04):832–837
- Thauat M, Fayard JM, Guimaraes TM, Jan N, Murphy CG, Sonnery-Cottet B. Classification and Surgical Repair of Ramp Lesions of the Medial Meniscus. *Arthrosc Tech* 2016;5(04):e871–e875
- Garofalo R, Mouhsine E, Chambat P, Siegrist O. Anatomic anterior cruciate ligament reconstruction: the two-incision technique. *Knee Surg Sports Traumatol Arthrosc* 2006;14(06):510–516
- de Pádua VB, Maldonado H, Vilela JC, Provenza AR, Monteiro C, de Oliveira Neto HC. Comparative study of ACL reconstruction with anatomical positioning of the tunnels using the patellar tendon versus hamstrings tendon. *Rev Bras Ortop* 2015;47(01):50–56
- Seil R, Mouton C, Coquay J, et al. Ramp lesions associated with ACL injuries are more likely to be present in contact injuries and complete ACL tears. *Knee Surg Sports Traumatol Arthrosc* 2018;26(04):1080–1085
- Di Vico G, Di Donato SL, Balato G, et al. Correlation between time from injury to surgery and the prevalence of ramp and hidden lesions during anterior cruciate ligament reconstruction. A new diagnostic algorithm. *Muscles Ligaments Tendons J* 2018;7(03):491–497
- Hatayama K, Terauchi M, Saito K, Aoki J, Nonaka S, Higuchi H. Magnetic Resonance Imaging Diagnosis of Medial Meniscal Ramp Lesions in Patients With Anterior Cruciate Ligament Injuries. *Arthroscopy* 2018;34(05):1631–1637
- Sonnery-Cottet B. Editorial Commentary: Ramp Lesion: The Eye Sees Only What the Mind Is Prepared to Comprehend. *Arthroscopy* 2020;36(11):2934–2937
- Rochcongar G, Cucurulo T, Ameline T, et al. Meniscal survival rate after anterior cruciate ligament reconstruction. *Orthop Traumatol Surg Res* 2015;101(8, Suppl):S323–S326
- Woods GW, Chapman DR. Repairable posterior menisco-capsular disruption in anterior cruciate ligament injuries. *Am J Sports Med* 1984;12(05):381–385
- Kennedy J, Jackson MP, O'Kelly P, Moran R. Timing of reconstruction of the anterior cruciate ligament in athletes and the incidence of secondary pathology within the knee. *J Bone Joint Surg Br* 2010;92(03):362–366
- Church S, Keating JF. Reconstruction of the anterior cruciate ligament: timing of surgery and the incidence of meniscal tears and degenerative change. *J Bone Joint Surg Br* 2005;87(12):1639–1642
- Drogset JO, Grøntvedt T. Anterior cruciate ligament reconstruction with and without a ligament augmentation device: results at 8-Year follow-up. *Am J Sports Med* 2002;30(06):851–856
- George MS, Dunn WR, Spindler KP. Current concepts review: revision anterior cruciate ligament reconstruction. *Am J Sports Med* 2006;34(12):2026–2037

- 24 Brophy RH, Haas AK, Huston LJ, Nwosu SK; Wright RWMARS Group. Association of Meniscal Status, Lower Extremity Alignment, and Body Mass Index With Chondrosis at Revision Anterior Cruciate Ligament Reconstruction. *Am J Sports Med* 2015;43(07):1616–1622
- 25 Wright RW, Huston LJ, Spindler KP, et al. Descriptive epidemiology of the Multicenter ACL Revision Study (MARS) cohort. *Am J Sports Med* 2010;38(10):1979–1986