



## Review Article

# Cartilage lesions and ankle osteoarthritis: review of the literature and treatment algorithm <sup>☆,☆☆</sup>



Alexandre Leme Godoy Santos<sup>a,\*</sup>, Marco Kawamura Demange<sup>a</sup>, Marcelo Pires Prado<sup>b</sup>, Tulio Diniz Fernandes<sup>a</sup>, Pedro Nogueira Giglio<sup>a</sup>, Beat Hintermann<sup>c</sup>

<sup>a</sup> Institute of Orthopedics and Traumatology, School of Medicine, University of São Paulo (USP), São Paulo, SP, Brazil

<sup>b</sup> Orthopedics and Rehabilitation Center, Hospital do Coração, São Paulo, SP, Brazil

<sup>c</sup> Department of Orthopedics, Kantonsspital, Liestal, Switzerland

### ARTICLE INFO

#### Article history:

Received 21 October 2013

Accepted 21 October 2013

Available online 11 November 2014

#### Keywords:

Osteoarthritis

Ankle

Osteotomy

Arthroplasty

Arthrodesis

#### Palavras-chave:

Osteoartrite

Tornozelo

Osteotomia

Artroplastia

Artrodesse

### ABSTRACT

The main etiology of ankle osteoarthritis is post-traumatic and its prevalence is highest among young individuals. Thus, this disease has a great socioeconomic impact and gives rise to significant losses of patients' quality of life. The objective of its treatment is to eliminate pain and keep patients active. Therefore, the treatment should be staged according to the degree of degenerative evolution, etiology, joint location, systemic condition, bone quality, lower-limb alignment, ligament stability and age. The treatment algorithm is divided into non-surgical therapeutic methods and options for surgical treatment. Joint preservation, joint replacement and arthrodesis surgical procedures have precise indications. This article presents a review on this topic and a proposal for a treatment algorithm for this disease.

© 2014 Sociedade Brasileira de Ortopedia e Traumatologia. Published by Elsevier Editora Ltda. All rights reserved.

### Lesão de cartilagem e osteoartrose do tornozelo: revisão da literatura e algoritmo de tratamento

#### RESUMO

A principal etiologia da osteoartrose (OA) do tornozelo é pós-traumática e sua maior prevalência está entre indivíduos jovens; assim, essa doença apresenta grande impacto socioeconômico e significativo prejuízo na qualidade de vida dos pacientes. O objetivo do tratamento é eliminar a dor e manter os pacientes ativos. Dessa forma, o tratamento deve ser estagiado de acordo com o grau de evolução da degeneração, a etiologia, a localização articular, a condição sistêmica, a qualidade óssea, o alinhamento do membro inferior, a estabilidade ligamentar e a idade. O algoritmo de tratamento é dividido nas modalidades

\* Please cite this article as: Santos ALG, Demange MK, Prado MP, Fernandes TD, Giglio PN, Hintermann B. Lesão de cartilagem e osteoartrose do tornozelo: revisão da literatura e algoritmo de tratamento. Rev Bras Ortop. 2014;49:565-572.

☆☆ Work developed at the Institute of Orthopedics and Traumatology, School of Medicine, University of São Paulo (USP), São Paulo, Brazil.

\* Corresponding author.

E-mail: [alexandrelemegodoy@gmail.com.br](mailto:alexandrelemegodoy@gmail.com.br) (A.L.G. Santos).

<http://dx.doi.org/10.1016/j.rboe.2014.11.003>

2255-4971/© 2014 Sociedade Brasileira de Ortopedia e Traumatologia. Published by Elsevier Editora Ltda. All rights reserved.

de terapia não cirúrgicas e nas opções de tratamento cirúrgico. As cirurgias de preservação articular, as cirurgias de substituição articular e as artrodeses apresentam indicações precisas. O presente artigo apresenta uma revisão sobre o tema e uma proposta de algoritmo de tratamento para essa doença.

© 2014 Sociedade Brasileira de Ortopedia e Traumatologia. Publicado por Elsevier Editora Ltda. Todos os direitos reservados.

## Introduction

Osteoarthritis (OA) is a syndrome characterized by degeneration of the joint cartilage, alterations to subchondral bone, intra-articular inflammatory alterations and periarticular bone growth, and it causes pain and functional loss in the affected limb.<sup>1-3</sup> There is still no effective cure for this syndrome today, through any methods for prevention, diminution of its progression or treatment of symptoms that have been proposed.<sup>1,2,4,5</sup>

OA affects 15% of the worldwide adult population, which makes it a disease of high socioeconomic impact both for individuals and for all of society.<sup>6</sup> For example, in the United States, this represents annual costs of 60 billion dollars for the direct treatment.<sup>1,6,7</sup>

The most important universal risk factors are age, excessive joint loading, joint injuries, fractures and ligament injuries.<sup>1,6</sup>

OA of the tibiotarsal joint is present in 4.4% of the patients who seek orthopedic attendance because of OA of the lower limbs.

Differently from hip joint degeneration (58%) and knee joint degeneration (67%), OA of the ankle is of primary origin in only 9% of the cases. The secondary causes (rheumatoid arthritis, hemochromatosis, hemophilia or osteonecrosis) are present in 13% of the cases. The main etiology is post-traumatic and this is the reason for tibiotarsal joint degeneration in 78% of the cases, while fractures around the ankle are the cause in 62% and ligament injuries are the cause in 16%.<sup>7-9</sup>

Individuals with ankle arthrosis tend to be younger than other patients with joint degeneration in the lower limbs and present faster functional loss, with progression to the final stages of the disease between 10 and 20 years after the start of the lesion.<sup>9</sup>

## Physiopathogenesis

A variety of anatomical and biomolecular characteristics of the ankle are determinants for understanding the susceptibility of the cartilage of this joint to degeneration.

The total area of the tibiotarsal joint is 350 mm<sup>2</sup> and it is subjected to a force of 500 N, while the hip and knee, with joint areas of respectively 1100 mm<sup>2</sup> and 1120 mm<sup>2</sup>, are subjected to the same force.<sup>10-12</sup> Thus, the pressure on the joint cartilage of the ankle may be up to three times greater than the pressure on the other joints of the lower limbs. On the other hand, the load distribution on the congruent joints, i.e. the ankle and hip, differs from the load distribution on the knee, such that

the compressive forces are distributed over a larger area. This possibly allows the ankle cartilage to be thinner than that of the knee. The thickness of the ankle joint cartilage ranges from 1 to 1.62 mm and is thinner than that of the hip (1.35–2 mm) and knee (1.69–2.55 mm).<sup>13</sup>

Comparative biomolecular studies on humans have shown that the ankle cartilage has higher density of glycosaminoglycan sulfate and lower modulus of equilibrium, dynamic rigidity, water component and hydraulic permeability than those of the knee cartilage. The properties influence the capacity to deform under compression during the load cycle.<sup>14,15</sup> The way in which the collagen of the ankle cartilage is organized resembles that of the knee, but the chondrocyte distribution differs. In the ankle, in the superficial layer of the cartilage, the chondrocytes are presented in groups.<sup>16</sup>

Along with these characteristics, the cartilage tissue of ankles that are subjected to injury presents increased collagen synthesis. The chondrocytes of the ankle are metabolically more active than those of the knee and present greater aggrecan turnover and greater sensitivity to anabolic stimuli, followed by removal of interleukin-1, and greater response of the chondrocytes to inflammatory stimuli.<sup>17-20</sup>

The following are also determinants for the physiopathogenesis: poor structural or acquired alignments of the lower limb, muscle imbalance and weakness around the tibiotarsal joint, age, gender, ethnicity and genetic predisposition.<sup>2,6</sup>

## Diagnosis and classification system

The clinical presentation consists of pain in the region of the joint interline, with or without an associated increase in volume (joint effusion) and limitations on the range of joint motion, functioning, work and recreational activities. These conditions may diminish the quality of life of individuals with diseases like hip OA, dialytic kidney failure, congestive heart failure or radiculopathy.<sup>21</sup> Other associated clinical alterations include leg muscle atrophy and alterations to gait patterns, particularly changes to kinematics and kinetics.<sup>22-25</sup>

The initial investigation by means of imaging is conducted using radiographs with weight-bearing. These may show different degrees of diminution of the joint space and formation of osteophytes, sclerosis and subchondral cysts. The Morrey and Wiedeman classification system is based on these radiographic findings.<sup>26,27</sup>

Magnetic resonance imaging (MRI) is the most sensitive and specific noninvasive imaging examination for evaluating the joint cartilage. By means of specific protocols for image acquisition and analysis, it also enables access to the morphology and biochemical composition of this tissue.<sup>28</sup>

Determining the precise location, size of the area affected and depth of the cartilaginous lesion is fundamental in selecting the treatment. Thus, MRI protocols aimed toward the cartilage and equipment with bigger magnetic fields (three to seven Tesla) provide a better view of the cartilage and the associated lesions.<sup>29-32</sup>

New MRI techniques for studying the cartilage, such as volumetric quantitative analysis, dGEMRIC mapping, T1-rho mapping, T2 mapping and MRI using sodium-23, enable access to the microstructure and, indirectly, to fundamental characteristics of the ankle cartilage, thereby improving the diagnosis and treatment of chondral and osteochondral lesions.<sup>30-33</sup>

Recently, the SPECT technique made it possible to correlate the morphological and biochemical information in investigating ankle OA and was shown to be useful for locating the active degeneration, especially in areas in which the number and the configuration of the joint are complex.<sup>34-36</sup>

### Algorithm for staged treatment

The decision on which treatment to use depends on the intensity of the pain, functional limitation, degree of joint degeneration, etiology, joint location, systemic condition, bone quality, lower-limb alignment, ligament stability and age, following the stages proposed through the treatment algorithm (Fig. 1).

#### Stage I. Nonsurgical treatment

Nonsurgical treatment is mainly indicated for patients with mild to moderate OA, mild pain, slight functional limitations, any etiology, good bone quality, adequate lower-limb alignment and stable joints, of any age group.

The objectives are to improve the symptoms, maintain the remaining joint range of motion and provide the conditions for appropriate future surgical treatment.

#### Braces and insoles

Braces and insoles should be used to keep the joint in the neutral position during walking movements. Some braces also limit ankle mobility in the sagittal plane and thus reduce the joint instability and overloading on the injured cartilage.<sup>37</sup>

Although some studies have shown satisfactory results from use of corrective insoles for treating knee OA (to produce varus deformity),<sup>38,39</sup> this has not been seen in treating ankle OA.<sup>37,40</sup>

#### Analgesics and anti-inflammatory agents

Analgesics and anti-inflammatory agents present proven effects relating to pain, and the latter also shows additional relief relating to active OA.

However, because of the various systemic side effects and also because progression of the degeneration is not avoided, these medications are not used as long-term solutions.

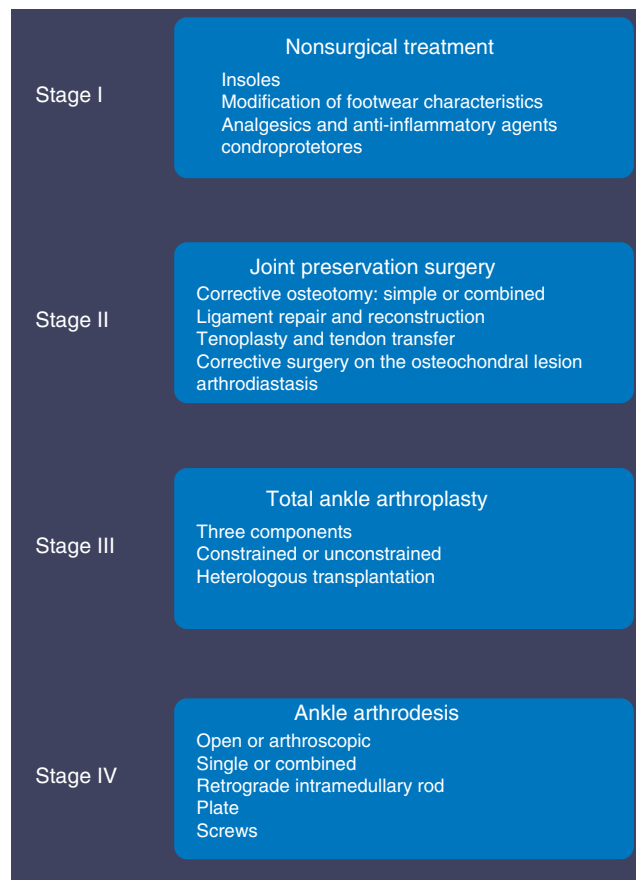


Fig. 1 – Staged treatment algorithm.

#### Physiotherapy

In cases of mild to moderate ankle OA, physiotherapy may help to preserve the range of motion and may increase the dynamic joint stability through muscle strengthening. This is useful until the time of future treatment with total ankle arthroplasty.<sup>8</sup>

#### Viscosupplementation

Interest in using intra-articular viscosupplementation with hyaluronic acid in the ankle, as a treatment option for joint degeneration, has been increasing significantly.<sup>41</sup>

In patients with OA, chondrocytes and synovial cells produce increased levels of inflammatory cytokines, such as interleukin 1 $\beta$  (IL-1 $\beta$ ) and tumor necrosis factor alpha (TNF- $\alpha$ ). In turn, these decrease collagen synthesis and increase the levels of catabolic mediators such as metalloproteinases (MMPs) and other inflammatory mediators like interleukin 8 (IL-8), interleukin 6 (IL-6), prostaglandin E2 (PGE2) and nitric oxide (NO).<sup>42,43</sup> One key protein in the pathological process of OA is CD44, which is found on the surfaces of chondrocytes, synovioblasts and macrophages. CD44 is capable of inhibiting the synthesis of inflammatory cytokines when bound to hyaluronic acid.<sup>44</sup>

Hyaluronic acid is an important modulator, especially through interaction with CD44 receptors that are present in

fibroblast-like synoviocytes.<sup>45</sup> Therefore, in addition to the mechanical effects of promoting better distribution of forces, decreasing the pressure on the chondrocytes<sup>46</sup> and recovering the rheological properties of the synovial fluid,<sup>47</sup> hyaluronic acid acts biochemically to diminish the gene expression of the cytokines and the enzymes associated with OA, the production of prostaglandins and the intra-articular concentration of metalloproteinases.<sup>46,48</sup>

Mei-Dan et al.<sup>49</sup> studied 16 patients with symptomatic OA in the ankle who received intra-articular injections of 25 mg of sodium hyaluronate for five consecutive weeks. There was a 20% improvement in range of motion and a significant reduction in pain, as assessed using a visual analog scale and scorings for the ankle and hindfoot.

Sun et al.<sup>50</sup> observed improvements in pain and ankle functioning in a series of 50 patients with ankle arthrosis who were treated with three intra-articular injections of hyaluronic acid per week. Another prospective case series revealed that Hylan GF 20 was effective for significantly reducing the pain associated with ankle OA. This effect seemed to last even beyond six to seven months after the treatment.<sup>51</sup>

The safety seems to be similar to that of the applications that are widely used in treating OA in several other joints, such as the knee, hip, shoulder and hand.<sup>51-56</sup>

Findings from meta-analyses have suggested that intra-articular viscosupplementation with hyaluronic acid can significantly reduce pain in patients with ankle OA, in comparison with the state before the treatment, and that this treatment option is superior to other conservative therapies in patients with symptoms. However, there is no consensus regarding the total number of injections and the volume per dose, in relation to the therapeutic results.<sup>57</sup>

## Stage II. Joint preservation surgery

Joint preservation surgery is mainly indicated for patients with moderate OA presenting daily pain of significant intensity and mild to moderate functional limitation, of post-traumatic or primary etiology, with good bone quality, asymmetry of lower-limb alignment and joint instability, in a non-elderly age group and without systemic comorbidities.

The objectives are to reestablish the biomechanics, alignment and joint stability, decelerate the evolution of the joint degeneration and postpone procedures of a more invasive nature.

### Joint debridement

There is controversy regarding the value of joint debridement for treating ankle OA.<sup>58</sup> Studies conducted among patients with knee arthrosis have indicated that joint lavage and debridement in the absence of mechanical causes that would justify the procedure only provide short-term pain relief.<sup>59,60</sup> Thus, there is greater evidence that debridement that addresses all the concomitant factors involved in the etiology of OA (removal of osteophytes and loose bodies, resection of scar and hypertrophic synovial tissue and repair techniques for focal osteochondral cartilage defects) presents

improvements in pain, edema and stiffness over the short and medium terms.<sup>58,61,62</sup>

### Arthroscopic joint debridement

Specific lesions associated with OA, such as osteophytes, loose bodies and chondral defects, can be treated by means of arthroscopy. However, these present worse results than do other diagnoses.<sup>60,61</sup>

### Arthrodiastasis

It is believed that application of traction to a joint may improve nutrition and the repair properties, through withdrawal of the load. This is done by means of external fixators, which enable removal of traction on the joint line, with maintenance of joint movement, which has positive effects on the joint fluid pressure. Aldegheri et al.<sup>62</sup> described this procedure in 1979, for treating degenerative lesions of the hip in young patients.

Some studies have shown satisfactory results with type of approach in small case series,<sup>63-66</sup> but this option has to be understood as a non-definitive procedure that has the aim of postponing arthroplasty or arthrodesis of the ankle. It is indicated for young patients.

---

## Osteotomies

In patients with asymmetry of alignment of the lower limbs (either varus or valgus) associated ankle OA, realignment surgery provides an alternative to fusion or arthroplasty in selected cases.

Osteotomies can be simple (tibia and fibula) or combined (leg and heel), with or without associated soft-tissue procedures.<sup>67</sup>

The aims are to transfer the weight from areas with damaged cartilage to areas with good-quality cartilage; to improve the joint congruence; to decelerate the progression of the OA; and to reduce the pain.

Pagenstert et al.<sup>67</sup> found that there was an improvement in the AOFAS score over a five-year follow-up on 35 consecutive patients with post-traumatic OA who were treated by means of realignment of the leg and hindfoot.

Precise selection of the patients and adequate correction of the joint alignment angle are crucial to success.<sup>68,69</sup>

### Treatment of osteochondral lesions

Repair of focal osteochondral cartilage defects.

### Microfractures

The microfracture procedure consists of making small drill holes in the subchondral bone after regularization of the lesion, in association with removal of the calcified layer of the joint cartilage. This procedure follows the principle of obtaining a coagulum formed by mesenchymal cells originating from the bone marrow.

More recently, some centers have followed the same line of reasoning as in the microfracture procedure and have used

concentrates of bone marrow aspirate (which contain mesenchymal cells) but without attacking the subchondral bone. These procedures are under development and under evaluation. The logic behind these procedures is based on obtaining a pluripotent cell content that is theoretically at a concentration greater than through microfracturing, but without attacking the subchondral bone. Studies on animals have demonstrated that superior repair tissue is formed<sup>70</sup> and have compared use of bone marrow aspirate concentrate with microfracturing. Furthermore, several clinical studies have reported occurrences of significant alterations to subchondral bone (such as bone cysts and osteophytes inside the lesions), after microfracture procedures.<sup>71,72</sup>

The factors indicating a poor prognosis from this procedure comprise lesion size greater than 1.5 cm<sup>2</sup>, which signifies diameter greater than 1.2 cm,<sup>73</sup> uncontained lesions and presence of cystic lesions associated with the osteochondral lesion.<sup>74</sup>

### **Autologous osteochondral transfer**

Osteochondral transfer is based on using an osteochondral cylinder obtained from a low-demand area, usually from the knee: in the intercondylar region, the lateral portion of the trochlea immediately proximal to the loading area of the lateral condyle or the lateral crest proximal to the trochlea.

This procedure is indicated for lesions of up to an area of 2 cm<sup>2</sup>, in which either the cartilage alone is affected or the cartilage together with the subchondral bone, as in osteochondritis dissecans. The main limiting factor for osteochondral transfer consists of morbidity in the donor area, which restricts the quantity and size of the cylinders to be used.

### **Autologous implantation of chondrocytes**

This consists of cell therapy for treating joint cartilage lesions in which a biopsy is first performed in order to culture chondrocytes. This cell expansion is done in the laboratory for approximately six weeks. In a second surgical procedure, debridement of the lesion and implantation of chondrocytes are performed. In the first generations, this implantation was done using a periosteal membrane, but collagen membranes are now used (seeded during the surgery or using cells that had previously been cultured in the membrane).

### **Stage III. Total ankle arthroplasty**

Total ankle arthroplasty (TAA) is mainly indicated for patients with severe OA presenting daily pain of significant intensity and major functional limitations, of any etiology, with good bone quality, adequate alignment or only mild asymmetry of the lower limbs and stable joints, in a non-elderly age group and without any severe systemic comorbidities.

The aims are to restore the functional range of motion, eliminate pain and improve quality of life.

The first designs for total ankle prostheses appeared in the 1970s. Despite high failure rates experiences with the first generations of total ankle prostheses,<sup>75</sup> several groups continued with the research and today a variety of implants that come

close to the anatomical and functional requirements of this joint are available.

This evolution has resulted in improvement of the clinical results and has made this procedure more popular for treating ankle OA.<sup>76</sup>

Analysis of the literature indicates that the main advance has been the concept of "mobile support", in which the prosthetic components interrelate with various degrees of freedom, without any occurrence of joint constriction. The third-generation prostheses, which comprise three elements (tibial, talar and intermediate components), have been the most successful of these so far.<sup>77-79</sup>

However, TAA still presents high complication rates in comparison with knee and hip arthroplasty.<sup>80</sup> The intraoperative complications are due to difficulty in aligning the components and making the bone cuts and to fracturing of the malleoli. During the postoperative period, the complications relate to dehiscence of the surgical incision and infection.<sup>78,81</sup> Over the long term, the greatest complication is aseptic loosening of the tibial or talar components, followed by stress fracturing, capsule retraction and retraction of the periarticular soft tissues.<sup>82</sup>

Thus, precise patient selection is fundamental to the success of this procedure.

The contraindications include osteonecrosis, severe peripheral vascular disease, peripheral neuropathy, recent or previous joint infection, severe ligament instability, major misalignment of the lower limb and poor bone quality.<sup>8</sup>

There is also the possibility of performing complete joint replacement by means of a fresh bipolar graft from the tibiotarsal joint. This procedure is a useful option for carefully selected patients, especially young and active individuals. It allows pain relief and maintenance of functional joint mobility. However, further studies on the immunological behavior of the transplanted cartilage in this type of procedure are needed.<sup>83-85</sup>

### **Stage IV. Arthrodesis**

Arthrodesis is mainly indicated for patients with severe OA presenting daily pain of significant intensity and major functional limitation, of any etiology, with good bone quality, adequate alignment or mild asymmetry of the lower limbs and stable joints, in the elderly and young adult age groups and with absence of severe systemic comorbidities.

The aims are to reestablish the alignment of the lower limb and eliminate the pain.

#### **Tibiotarsal and tibiotalar-calcaneal arthrodesis**

Patients with advanced ankle OA without an indication for total ankle arthroplasty and those who present TAA failure form a group that might benefit from salvage procedures consisting of tibiotarsal or tibiotalar-calcaneal arthrodesis. Many surgical techniques and fixation materials have already been described in the literature.<sup>86-88</sup>

The choice between tibiotarsal or tibiotalar-calcaneal arthrodesis will depend on the conditions of degeneration, pain and alignment of the subtalar joint.

This procedure generally provides good functional results and a high rate of symptom relief. There is no doubt that correct positioning of the joint fusion during the operation has a direct impact on the clinical results achieved. Thus, valgus angles of 5°, external rotation angles of 5°-10° and neutral flexion-extension positions of the ankle need to be achieved.<sup>89</sup>

Its disadvantages include the time taken after the operation to reach consolidation, painful nonunion rates, length discrepancies between the lower limbs, chronic edema, implant loosening and peri-implant fracturing.<sup>88,89</sup>

### Final remarks

Ankle OA is a disease that differs from other forms of arthrosis of the lower limbs. Its main etiological factor is joint trauma, especially malleolar fractures, chronic ankle instability and distal fractures of the tibia. It affects young individuals in the productive age group, which results in high personal and social costs relating to the direct treatment of this disease, which usually takes a long time.

The therapeutic strategies are based on a staged treatment algorithm and depend on a broad spectrum of related factors.

### Conflicts of interest

The authors declare no conflicts of interest.

### REFERENCES

- Buckwalter JA, Saltzman C, Brown T. The impact of osteoarthritis. *Clin Orthop Rel Res*. 2004; 427 Suppl.:S6-15.
- Division of Adult and Community Health, National Center for Chronic Disease Prevention and Health Promotion. <http://www.cdc.gov/arthritis/basics/osteoarthritis.htm>
- Lawrence RC, Felson DT, Helmick CG, Arnold LM, Choi H, Deyo RA, et al. Estimates of the prevalence of arthritis and other rheumatic conditions in the United States. Part II *Arthritis Rheum*. 2008;58(1):26-35.
- Martel-Pelletier J, Boileau C, Pelletier JP, Roughley PJ. Cartilage in normal and osteoarthritis conditions. *Best Pract Res Clin Rheumatol*. 2008;22(2):351-84.
- De Lange-Brokaar BJ, Ioan-Facsinay A, van Osch GJ, Zuurmond AM, Schoones J, Toes RE, et al. Synovial inflammation, immune cells and their cytokines in osteoarthritis: a review. *Osteoarthr Cartil*. 2012;20(12):1484-99.
- Felson DT. The epidemiology of osteoarthritis: prevalence and risk factors. In: Kuettner KE, Goldberg VM, editors. *Osteoarthritis disorders*. Rosemont, IL: American Academy of Orthopaedic Surgeons; 1995. p. 13-24.
- Brown TD, Johnston RC, Saltzman CL, Marsh JL, Buckwalter JA. Posttraumatic osteoarthritis: a first estimate of incidence, prevalence, and burden of disease. *J Orthop Trauma*. 2006;20(10):739-44.
- Horisberger M, Valderrabano V, Hintermann B. Posttraumatic ankle osteoarthritis after ankle-related fractures. *J Orthop Trauma*. 2009;23(1):60-7.
- Valderrabano V, Horisberger M, Russell I, Dougall H, Hintermann B. Etiology of ankle osteoarthritis. *Clin Orthop Relat Res*. 2009;467(7):1800-6.
- Chang KV, Hsiao MY, Chen WS, Wang TG, Chien KL. Effectiveness of intra-articular hyaluronic acid for ankle osteoarthritis treatment: a systematic review and meta-analysis. *Arch Phys Med Rehabil*. 2013;94(5):951-60.
- Kimizuka M, Kurosawa H, Fukubayashi T. Load-bearing pattern of the ankle joint: contact area and pressure distribution. *Arch Orthop Trauma Surg*. 1980;96(1):45-9.
- Ihn JC, Kim SJ, Park IH. In vitro study of contact area and pressure distribution in the human knee after partial and total meniscectomy. *Int Orthop*. 1993;17(4):214-8.
- Brown TD, Shaw DT. In vitro contact stress distributions in the natural human hip. *J Biomech*. 1983;16(6):373-84.
- Shepherd DE, Seedhom BB. Thickness of human articular cartilage in joints of the lower limb. *Ann Rheum Dis*. 1999;58(1):27-34.
- Treppo S, Koeppe H, Quan EC, Cole AA, Kuettner KE, Grodzinsky AJ. Comparison of biomechanical and biochemical properties of cartilage from human knee and ankle pairs. *J Orthop Res*. 2000;18(5):739-48.
- Kuettner KE, Cole AA. Cartilage degeneration in different human joints. *Osteoarthr Cartil*. 2005;13(2):93-103.
- Hendren L, Beeson P. A review of the differences between normal and osteoarthritis articular cartilage in human knee and ankle joints. *Foot (Edinb)*. 2009;19(3):171-6.
- Aurich M, Squires GR, Reiner A, Mollenhauer JA, Kuettner KE, Poole AR, et al. Differential matrix degradation and turnover in early cartilage lesions of human knee and ankle joints. *Arthritis Rheum*. 2005;52(1):112-9.
- Eger W, Schumacher BL, Mollenhauer J, Kuettner KE, Cole AA. Human knee and ankle cartilage explants: catabolic differences. *J Orthop Res*. 2002;20(3):526-34.
- Kang Y, Koeppe H, Cole AA, Kuettner KE, Homandberg GA. Cultured human ankle and knee cartilage differ in susceptibility to damage mediated by fibronectin fragments. *J Orthop Res*. 1998;16(5):551-6.
- Cole AA, Kuettner KE. Molecular basis for differences between human joints. *Cell Mol Life Sci*. 2002;59(1):19-26.
- Saltzman CL, Zimmerman MB, O'Rourke M, Brown TD, Buckwalter JA, Johnston R. Impact of comorbidities on the measurement of health in patients with ankle osteoarthritis. *J Bone Joint Surg Am*. 2006;88(11):2366-72.
- Valderrabano V, von Tscharnar V, Nigg BM, Hintermann B, Goepfert B, Fung TS, et al. Lower leg muscle atrophy in ankle osteoarthritis. *J Orthop Res*. 2006;24(12):2159-69.
- Thomas R, Daniels TR, Parker K. Gait analysis and functional outcomes following ankle arthrodesis for isolated ankle arthritis. *J Bone Joint Surg Am*. 2006;88(3):526-35.
- Nüesch C, Huber C, Pagenstert G, von Tscharnar V, Valderrabano V. Muscle activation of patients suffering from asymmetric ankle osteoarthritis during isometric contractions and level walking – a time-frequency analysis. *J Electromyogr Kinesiol*. 2012;22(6):939-46.
- Nüesch C, Valderrabano V, Huber C, von Tscharnar V, Pagenstert G. Gait patterns of asymmetric ankle osteoarthritis patients. *Clin Biomech (Bristol, Avon)*. 2012;27(6):613-8.
- Morrey BF, Wiedeman GP Jr. Complications and long-term results of ankle arthrodeses following trauma. *J Bone Joint Surg Am*. 1980;62(5):777-84.
- Muehleman C, Fogarty D, Reinhart B, Tzvetkov T, Li J, Nesch I. In-laboratory diffraction-enhanced X-ray imaging for articular cartilage. *Clin Anat*. 2010;23(5):530-8.
- Lang P, Yoshioka H, Steines D, Nöbauer-Huhmann IM, Imhof H. Magnetic resonance tomography (MRI) of joint cartilage. Current status of knowledge and new developments. *Radiologe*. 2000;40(12):1141-8.
- Link TM, Stahl R, Woertler K. Cartilage imaging: motivation, techniques, current and future significance. *Eur Radiol*. 2007;17(5):1135-46.
- Welsch GH, Mamisch TC, Hughes T, Zilkens C, Quirbach S, Scheffler K, et al. In vivo biochemical 7.0 Tesla magnetic

- resonance: preliminary results of dGEMRIC, zonal T2, and T2\* mapping of articular cartilage. *Invest Radiol.* 2008;43(9):619-26.
32. Strickland CD, Kijowski R. Morphologic imaging of articular cartilage. *Magn Reson Imaging Clin N Am.* 2011;19(2):229-48.
  33. Forney M, Subhas N, Donley B, Winalski CS. MR imaging of the articular cartilage of the knee and ankle. *Magn Reson Imaging Clin N Am.* 2011;19(2):379-405.
  34. Jazrawi LM, Alaia MJ, Chang G, Fitzgerald EF, Recht MP. Advances in magnetic resonance imaging of articular cartilage. *J Am Acad Orthop Surg.* 2011;19(7):420-9.
  35. Pagenstert GI, Barg A, Leumann AG, Rasch H, Müller-Brand J, Hintermann B, et al. SPECT-CT imaging in degenerative joint disease of the foot and ankle. *J Bone Joint Surg Br.* 2009;91(9):1191-6.
  36. Knupp M, Pagenstert GI, Barg A, Bolliger L, Easley ME, Hintermann B. SPECT-CT compared with conventional imaging modalities for the assessment of the varus and valgus malaligned hindfoot. *J Orthop Res.* 2009;27(11):1461-6.
  37. Nathan M, Mohan H, Vijayanathan S, Fogelman I, Gnanasegaran G. The role of 99mTc-diphosphonate bone SPECT/CT in the ankle and foot. *Nucl Med Commun.* 2012;33(8):799-807.
  38. John S, Bongiovanni F. Brace management for ankle arthritis. *Clin Podiatr Med Surg.* 2009;26(2):193-7.
  39. Pham T, Maillerfert JF, Hudry C, Kieffert P, Bourgeois P, Lechevalier D, et al. Laterally elevated wedged insoles in the treatment of medial knee osteoarthritis: a two-year prospective randomized controlled study. *Osteoarthr Cartil.* 2004;12(1):46-55.
  40. Toda Y, Tsukimura N. A 2-year follow-up of a study to compare the efficacy of lateral wedged insoles with subtalar strapping and in-shoe lateral wedged insoles in patients with varus deformity osteoarthritis of the knee. *Osteoarthr Cartil.* 2006;14(3):231-7.
  41. Kitaoka HB, Crevoisier XM, Harbst K, Hansen D, Kotajarvi B, Kaufman K. The effect of custom-made braces for the ankle and hindfoot on ankle and foot kinematics and ground reaction forces. *Arch Phys Med Rehabil.* 2006;87(1):130-5.
  42. Pelletier JP, Martel-Pelletier J, Abramson SB. Osteoarthritis, an inflammatory disease: potential implication for the selection of new therapeutic targets. *Arthritis Rheum.* 2001;44(6):1237-47.
  43. DiBattista JA, Martel-Pelletier J, Wosu LO, Sandor T, Antakly T, Pelletier JP. Glucocorticoid receptor mediated inhibition of interleukin-1 stimulated neutral metalloprotease synthesis in normal human chondrocytes. *J Clin Endocrinol Metab.* 1991;72(2):316-26.
  44. Yasuda T. Hyaluronan inhibits prostaglandin E2 production via CD44 in U937 human macrophages. *Tohoku J Exp Med.* 2010;220(3):229-35.
  45. Wang CT, Lin YT, Chiang BL, Lin YH, Hou SM. High molecular weight hyaluronic acid down-regulates the gene expression of osteoarthritis-associated cytokines and enzymes in fibroblast-like synoviocytes from patients with early osteoarthritis. *Osteoarthr Cartil.* 2006;14(12):1237-47.
  46. Peyron JG, Balazs EA. Preliminary clinical assessment of Na-hyaluronate injection into human arthritic joints. *Pathol Biol (Paris).* 1974;22(8):731-6.
  47. Bagga H, Burkhardt D, Sambrook P, March L. Longterm effects of intraarticular hyaluronan on synovial fluid in osteoarthritis of the knee. *J Rheumatol.* 2006;33(5):946-50.
  48. Sasaki A, Sasaki K, Kontinen YT, Santavirta S, Takahara M, Takei H, et al. Hyaluronate inhibits the interleukin-1beta-induced expression of matrix metalloproteinase (MMP)-1 and MMP-3 in human synovial cells. *Tohoku J Exp Med.* 2004;204(2):99-107.
  49. Mei-Dan O, Kish B, Shabat S, Masarawa S, Shteren A, Mann G, et al. Treatment of osteoarthritis of the ankle by intra-articular injections of hyaluronic acid: a prospective study. *J Am Podiatr Med Assoc.* 2010;100(2):93-100.
  50. Sun SF, Hsu CW, Sun HP, Chou YJ, Li HJ, Wang JL. The effect of three weekly intra-articular injections of hyaluronate on pain, function, and balance in patients with unilateral ankle arthritis. *J Bone Joint Surg Am.* 2011;93(18):1720-6.
  51. Witteveen A, Giannini S, Guido G, Jerosch J, Lohrer H, Vannini F, et al. A prospective multi-centre, open study of the safety and efficacy of hylan G-F 20 (Synvisc) in patients with symptomatic ankle (talo-crural) osteoarthritis. *Foot Ankle Surg.* 2008;14(3):145-52.
  52. Blaine T, Moskowitz R, Udell J, Skyhar M, Levin R, Friedlander J, et al. Treatment of persistent shoulder pain with sodium hyaluronate: a randomized, controlled trial. A multicenter study. *J Bone Joint Surg Am.* 2008;90(5):970-9.
  53. Silverstein E, Leger R, Shea K. The use of intra-articular Hylan GF-20 in the treatment of symptomatic osteoarthritis of the shoulder: a preliminary study. *Am J Sports Med.* 2007;35(6):979-85.
  54. Figen Ayhan F, Ustun N. The evaluation of efficacy and tolerability of Hylan GF-20 in bilateral thumb base osteoarthritis: 6 months follow-up. *Clin Rheumatol.* 2009;28(5):535-41.
  55. Salini V, De Amicis D, Abate M, Natale MA, Di Iorio A. Ultrasound-guided hyaluronic acid injection in carpometacarpal osteoarthritis: short-term results. *Int J Immunopathol Pharmacol.* 2009;22(2):455-60.
  56. De Campos GC, Rezende MU, Pailo AF, Frucchi R, Camargo OP. Adding triamcinolone improves viscosupplementation: a randomized clinical trial. *Clin Orthop Relat Res.* 2013;471(2):613-20.
  57. Ogilvie-Harris D, Sekyi-Otu A. Arthroscopic debridement for the osteoarthritic ankle. *Arthroscopy.* 1995;11(4):433-6.
  58. Jackson R, Gilbert R, Sharkey PF. Arthroscopic debridement versus arthroplasty in osteoarthrotic knee. *J Arthroplasty.* 1997;12(4):465-70.
  59. Cheng J, Ferkel R. The role of arthroscopy in ankle and subtalar degenerative joint disease. *Clin Orthop Relat Res.* 1998;(349):65-72.
  60. Loong TW, Mitra AK, Tan SK. Role of arthroscopy in ankle disorder - early experience. *Ann Acad Med Singapore.* 1994;23(3):348-50.
  61. Hassouna H, Kumar S, Bendall S. Arthroscopic ankle debridement: 5-year survival analysis. *Acta Orthop Belg.* 2007;73(6):737-40.
  62. Aldegheri R, Trivella G, Saleh M. Articulated distraction of the hip. Conservative surgery for arthritis in young patients. *Clin Orthop Relat Res.* 1994;(301):94-101.
  63. Paley D, Lamm BM. Ankle joint distraction. *Foot Ankle Clin.* 2005;10(4):685-98.
  64. Inda DJ, Blyakher A, O'Malley MJ. Distraction arthroplasty for the ankle using the Ilizarov frame. *Tech Foot Ankle Surg.* 2003;2(4):249-53.
  65. Ploegmakers JJ, van Roermund PM, van Melkebeek J, Lammens J, Bijlsma JW, Lafeber FP, et al. Prolonged clinical benefit from joint distraction in the treatment of ankle osteoarthritis. *Osteoarthr Cartil.* 2005;13(7):582-8.
  66. Pagenstert G, Hintermann B, Barg A, Leumann A, Valderrabano V. Realignment surgery as alternative treatment of varus and valgus ankle osteoarthritis. *Clin Orthop Relat Res.* 2007;(462):156-68.
  67. Pagenstert G, Leumann A, Hintermann B, Valderrabano V. Sports and recreation activity of varus and valgus ankle osteoarthritis before and after realignment surgery. *Foot Ankle Int.* 2008;29(10):985-93.

68. Cheng Y, Huang P, Hong S, Lin SY, Liao CC, Chiang HC, et al. Low tibial osteotomy for moderate ankle arthritis. *Arch Orthop Trauma Surg.* 2001;121(6):355-8.
69. Kreuz PC, Steinwachs MR, Erggelet C, Krause SJ, Konrad G, Uhl M, et al. Results after microfracture of full-thickness chondral defects in different compartments in the knee. *Osteoarthr Cartil.* 2006;14(11):1119-25.
70. Mithoefer K, Williams RJ 3rd, Warren RF, Potter HG, Spock CR, Jones EC, et al. The microfracture technique for the treatment of articular cartilage lesions in the knee. A prospective cohort study. *J Bone Joint Surg Am.* 2005;87(9):1911-20.
71. Fortier LA, Potter HG, Rickey EJ, Schnabel LV, Foo LF, Chong LR, et al. Concentrated bone marrow aspirate improves full-thickness cartilage repair compared with microfracture in the equine model. *J Bone Joint Surg Am.* 2010;92(10):1927-37.
72. Furukawa T, Eyre DR, Koide S, Glimcher MJ. Biochemical studies on repair cartilage resurfacing experimental defects in the rabbit knee. *J Bone Joint Surg Am.* 1980;62(1):79-89.
73. Cuttica DJ, Smith WB, Hyer CF, Philbin TM, Berlet GC. Osteochondral lesions of the talus: predictors of clinical outcome. *Foot Ankle Int.* 2011;32(11):1045-51.
74. Hintermann B. History of total ankle arthroplasty. In: *Total ankle arthroplasty: historical overview, current concepts and future perspectives.* New York: Springer-Verlag; 2005. p. 53-63.
75. Haddad S, Coetzee J, Estok R, Fahrbach K, Banel D, Nalysnyk L. Intermediate and long-term outcomes of total ankle arthroplasty and ankle arthrodesis. A systematic review of the literature. *J Bone Joint Surg Am.* 2007;89(9):1899-905.
76. Hintermann B. Short and mid-term results with Star total ankle prosthesis. *Orthopade.* 1999;28(9):792-803.
77. Hintermann B, Valderrabano V, Dereymaeker G, Dick W. The Hintegra ankle: rationale and short-term results of 122 consecutive ankles. *Clin Orthop Rel Res.* 2004;(424):57-68.
78. Nery C, Fernandes TD, Réssio C, Fuchs ML, Godoy-Santos AL, Ortiz RT. Total ankle replacement: Brazilian experience with the Hintegra prosthesis. *Rev Bras Ortop.* 2010;45(1):92-100.
79. Gougoulas N, Khanna A, Maffulli N. How successful are current ankle replacements?: a systematic review of the literature. *Clin Orthop Relat Res.* 2010;(468): 199-208.
80. Lee K, Cho S, Hur C, Yoon T. Perioperative complications of Hintegra total ankle replacement: our initial 50 cases. *Foot Ankle Int.* 2008;29(10):978-84.
81. Karantana A, Hobson S, Dhar S. The Scandinavian total ankle replacement: survivorship at 5 and 8 years comparable to other series. *Clin Orthop Relat Res.* 2010;(468): 951-7.
82. Bugbee WD, Khanna G, Cavallo M, McCauley JC, Görtz S, Brage ME. Bipolar fresh osteochondral allografting of the tibiotalar joint. *J Bone Joint Surg Am.* 2013;95(5):426-32.
83. Giannini S, Buda R, Grigolo B, Bevoni R, Di Caprio F, Ruffilli A, et al. Bipolar fresh osteochondral allograft of the ankle. *Foot Ankle Int.* 2010;31(1):38-46.
84. Pimenta R, Carvalho P, Amado P. Fresh bipolar osteochondral allograft of the ankle. Review of the literature and case report of a young patient with bilateral post-traumatic osteoarthritis. *Rev Esp Cir Ortop Traumatol.* 2012;56(2):120-6.
85. Demetriades L, Strauss E, Gallina J. Osteoarthritis of the ankle. *Clin Orthop Relat Res.* 1998;(349):28-42.
86. Culpán P, Le Strat V, Piriou P, Judet T. Arthrodesis after failed total ankle replacement. *J Bone Joint Surg Br.* 2007;89(9):1178-83.
87. Coester L, Saltzman C, Leupold J, Pontarelli W. Long-term results following ankle arthrodesis for post-traumatic arthritis. *J Bone Joint Surg Am.* 2001;83(2): 219-28.
88. Fuchs S, Sandmann A, Skwar A, Chylarecki C. Quality of life 20 years after arthrodesis of the ankle: a study of adjacent joints. *J Bone Joint Surg Br.* 2003;85(7):994-8.
89. Buchner M, Sabo D. Ankle fusion attributable to posttraumatic arthrosis: a long-term followup of 48 patients. *Clin Orthop Relat Res.* 2003;(406):155-64.