


# Analysis of the Clinical and Radiological Results of Bridge Plate Versus External Fixation in Comminuted Distal Radius Fractures\*

## *Análise clínica e radiológica do resultado placa ponte versus fixador externo na fratura cominutiva do rádio distal*

Beatriz Canhoto Carula<sup>1</sup> Matheus da Silva Pereira<sup>1</sup> Ana Paula Bonilauri Ferreira<sup>2</sup>  
Henrique Ayzemberg<sup>3</sup> Valdir Steglich<sup>3</sup> Tiago Salati Stangarlin<sup>3</sup>

<sup>1</sup>Instituto de Ortopedia e Traumatologia de Joinville, Hospital Municipal São José, Joinville, SC, Brazil

<sup>2</sup>Curso de Odontologia, Universidade da Região de Joinville (UNIVILLE), Joinville, SC, Brazil

<sup>3</sup>Serviço de Residência Médica, Instituto de Ortopedia e Traumatologia de Joinville, Hospital Municipal São José, Joinville, SC, Brazil

Address for correspondence Ana Paula Bonilauri Ferreira, PhD, Rua Ex-Combatentes, 125, Joinville, SC, 89221-103, Brazil (e-mail: apbonilauri@gmail.com).

Rev Bras Ortop 2021;56(1):61–68.

### Abstract

**Objective** To evaluate and compare the clinical and radiological outcomes of patients with comminuted distal radius fractures treated with an external fixator or a dorsal bridge plate.

**Methods** In total, 45 patients were analyzed 1 year after surgery; 18 were treated with an external fixator, and 25 received a dorsal bridge plate. An analog pain scale and the Disabilities of the Arm, Shoulder and Hand (DASH) questionnaire were applied, in addition to radiographic, strength and range of motion assessments. Statistical analyzes were performed using the chi-squared test and the Mann-Whitney non-parametric test.

**Results** Fractures were more common in women over 60 years old who suffered falls from their own height. Both methods demonstrated similar functional and radiological results. Infections were more prevalent in patients receiving external fixators, but their residual grip strength was better. Reflex sympathetic neuropathy was more common in subjects treated with a dorsal bridge plate.

**Conclusion** Our analysis showed no consensus on the superiority of one method over the other. Each method had advantages and disadvantages, but both led to good, similar outcomes. The treatment must be chosen according to the profile of the trauma, the patient's clinical conditions, the surgeon's experience, and the availability of materials.

### Keywords

- ▶ distal radius
- ▶ bone plates
- ▶ external fixators

\* Study developed at Instituto de Ortopedia e Traumatologia de Joinville, Hospital Municipal São José, Joinville, SC, Brazil.

received  
August 16, 2019  
accepted  
April 15, 2020  
published online  
September 24, 2020

DOI <https://doi.org/10.1055/s-0040-1713393>.  
ISSN 0102-3616.

© 2020. Sociedade Brasileira de Ortopedia e Traumatologia. All rights reserved.  
This is an open access article published by Thieme under the terms of the Creative Commons Attribution-NonDerivative-NonCommercial-License, permitting copying and reproduction so long as the original work is given appropriate credit. Contents may not be used for commercial purposes, or adapted, remixed, transformed or built upon. (<https://creativecommons.org/licenses/by-nc-nd/4.0/>)  
Thieme Revinter Publicações Ltda., Rua do Matoso 170, Rio de Janeiro, RJ, CEP 20270-135, Brazil

**Resumo**

**Objetivo** Avaliar e comparar os resultados clínicos e radiológicos de pacientes com fraturas cominutivas distais do rádio tratados com fixador externo ou placa ponte dorsal.

**Métodos** Foram analisados 45 pacientes, sendo 18 tratados com fixador externo, e 25, com placa ponte dorsal, após 1 ano de pós-operatório. Aplicou-se uma escala analógica de dor e o questionário Disabilities of the Arm, Shoulder and Hand (DASH), além de análise radiográfica, da avaliação de força, e da amplitude de movimento. As análises estatísticas foram realizadas utilizando o teste qui-quadrado e o teste não paramétrico de Mann-Whitney.

**Resultados** A fratura foi mais comum em mulheres acima de 60 anos por queda do mesmo nível. Ambos os métodos demonstraram resultados funcional e radiológico similares. A infecção foi mais prevalente com o uso do fixador externo, mas a força de preensão residual foi melhor. Neuropatia simpático-reflexa foi mais comum com o uso da placa ponte dorsal.

**Conclusão** Não houve consenso da superioridade de um método em relação ao outro em nossa análise. Cada um dos métodos apresenta vantagens e desvantagens, mas ambos mostraram resultados bons e semelhantes. A escolha do tratamento deve ser atribuída ao perfil do trauma, às condições clínicas do paciente, à experiência do profissional, e à disponibilidade de materiais.

**Palavras-chave**

- ▶ rádio distal
- ▶ placas ósseas
- ▶ fixadores externos

**Introduction**

Distal radius fractures correspond to 12% of fractures in adults, constituting a major cause of morbidity.<sup>1</sup> In younger populations, these injuries are severe comminuted fractures resulting from high-energy trauma; in the elderly population, they are caused by low-energy trauma.<sup>2</sup> If not properly treated, these fractures result in chronic pain, motion limitation and functional impairment,<sup>3</sup> with a great impact on the patient's quality of life and burdening the public health-care system, since most of these subjects are young patients who are unable to work.<sup>2</sup>

Despite the great prevalence and social consequences of these injuries, there is still no consensus as to the best treatment due to the great possibility of distal radial fracture profiles.<sup>4</sup> The best therapeutic method must consider the fracture pattern (classification, bone quality), patient profile (age, daily activities), additional injuries (ligament or bone lesions) and the surgeon's experience with the materials.<sup>5</sup>

Distal radius fractures can be conservatively or surgically treated depending on the aforementioned factors.<sup>6</sup> No treatment is exempt from complications, and they must be customized for each individual patient. The surgical treatment can be beneficial in fractures meeting the Lafontaine criteria after closed reduction.<sup>7</sup> The options of surgical treatment include percutaneous fixation with Kirschner wires, volar or dorsal plates, and external fixators.<sup>8</sup> The most widespread methods are Kirschner wires and volar plates due to the easy access to these materials. However, in highly-comminuted fractures from high-energy trauma or those affecting osteoporotic bones, these methods may be unsuccessful.<sup>1,3</sup> Since these joint fractures are difficult to

stabilize, new fixation forms are required. Other options include external fixators and bridge plates associated with Kirschner wires.<sup>9</sup> External fixators are promptly placed, with lower cutaneous aggression, but they are esthetically worse for patients and related to a higher risk of infection at their path.<sup>10</sup> Bridge plates are more aggressive to the soft tissues due to the incision, but they can result in an improved fracture reduction.<sup>11</sup>

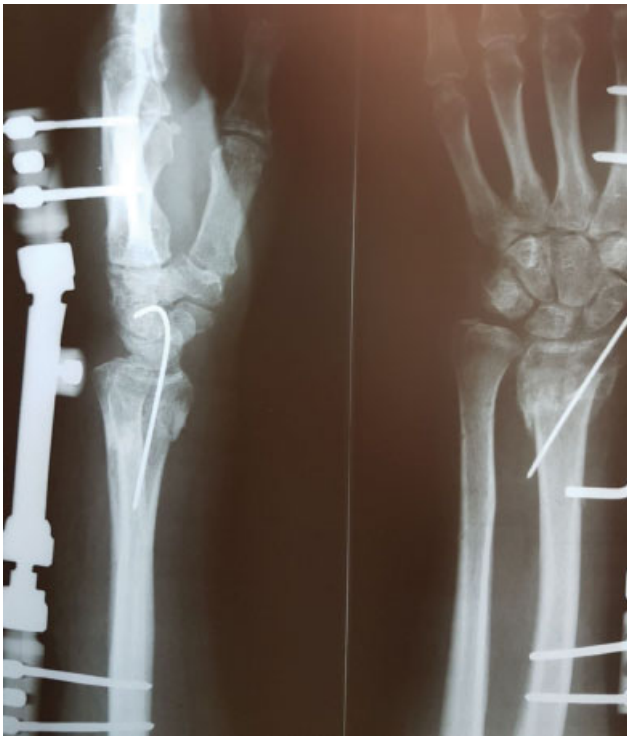The present study compared the postoperative outcomes of comminuted distal radius fractures classified as 23C2 or 23C3 according to AO Classification System surgically treated with an external fixator and Kirschner wires or with a dorsal bridge plate.

**Materials and Methods****Ethics**

The present was an observational, analytical study approved by the Ethics in Research Committee of Hospital Municipal São José (Joinville, Santa Catarina, Brazil) under opinion number 2.439.743.

**Participants**

In total, 43 patients presenting intra-articular distal radius fracture with AO classification 23C2 or C3 and followed-up for at least 1 year after surgery in an outpatient facility were selected. Among them, 18 patients were treated with an external fixator, and 25 received a bridge plate, associated with Kirschner wires if required. The sample size was based on previously-published studies comparing surgical techniques for distal radius fractures using the Disabilities of the Arm, Shoulder and Hand (DASH) questionnaire.<sup>12,13</sup>



**Fig. 1** Postoperative radiograph of a patient with an external fixator.

The patients were recruited from December 2017 to May 2018 during outpatient return visits at Hospital Municipal São José, in which the surgical treatment was performed, always by the same hand surgeon, who is the chief physician. Patients with associated fractures in the same limb, open distal radial fractures, previous deformities and/or those requiring care at an intensive care unit were excluded from the study.

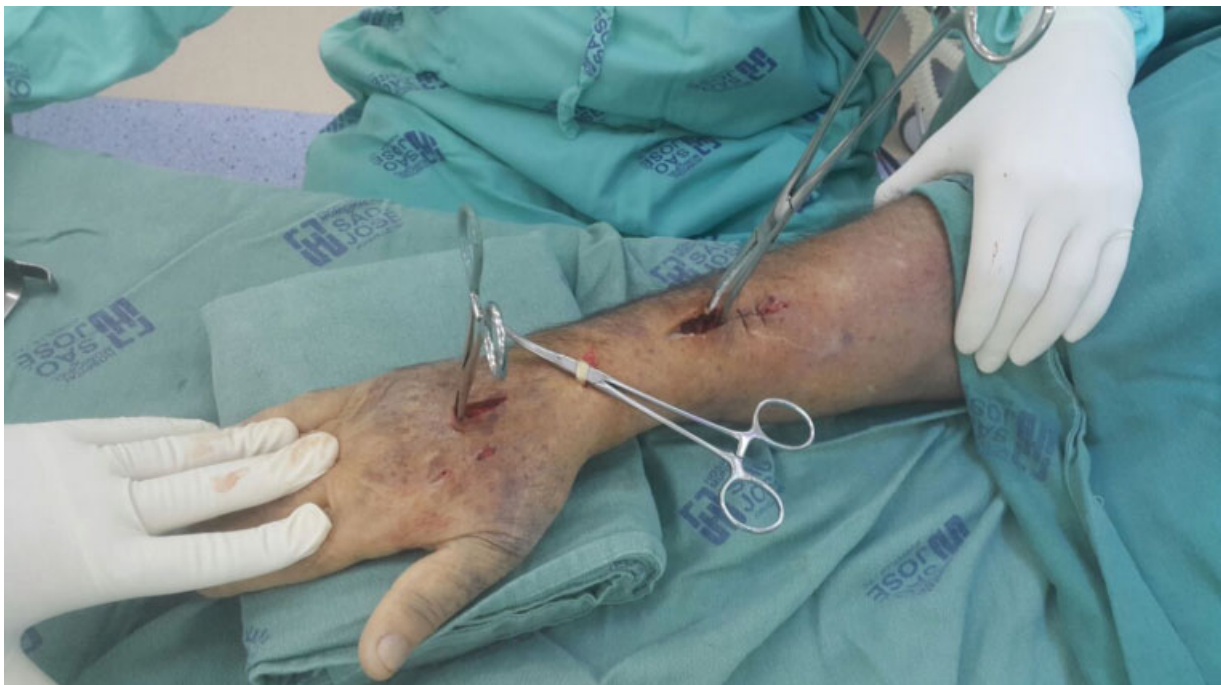### Surgical Techniques

In patients treated with an external fixator, Schanz pins were placed under fluoroscopy at the second metacarpal bone diaphysis and the radial diaphysis; the fracture was reduced and fixed using the Colles external wrist fixator. If required, Kirschner wires were associated to maintain the reduction and add stability (► **Figure 1**). At the postoperative follow-up of six to eight weeks, the external fixator and the Kirschner wires were removed under local anesthesia at the Schanz pins, according to the radiographic evaluation. Subsequently, the patient was referred for physical therapy and rehabilitation.

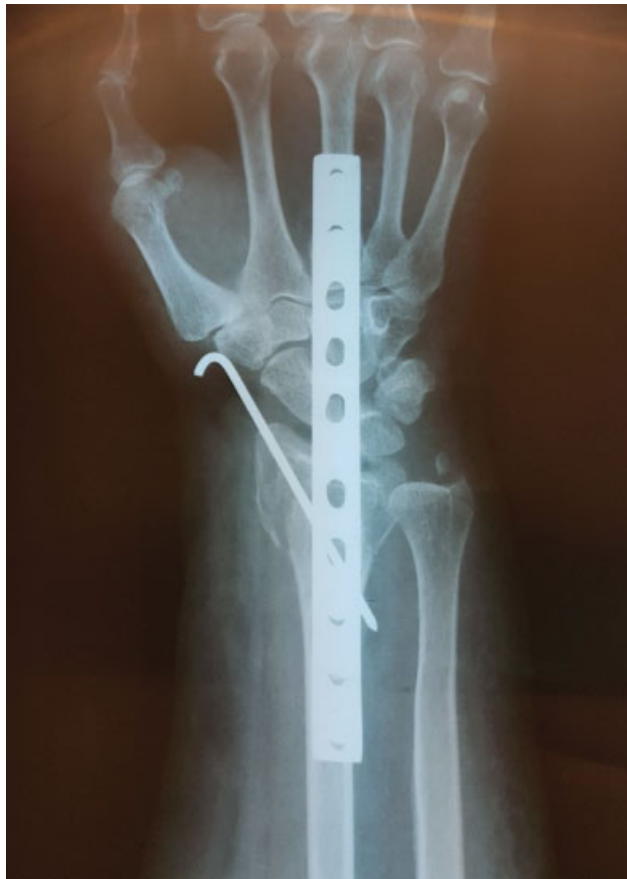The dorsal bridge plate technique was initially described as a form of distraction for more complex type-C3 fractures; here, however, it was used as an alternative in type-C2 fractures, which are more common in hospital care.

In patients treated with dorsal bridge plate and screws, 3 incisions were made: an incision of approximately 2 cm at the region of the third metacarpal diaphysis, an incision at the third extensor tunnel, at the level of the Lister tubercle, to isolate the long extensor tendon of the thumb, and 1 incision at the radial diaphysis (► **Figure 2**). Then, the plate was placed retrogradely.

A dynamic compression plate (DCP) was placed juxta-ossously, moving the long extensor tendon of the thumb at the third tunnel through an access of approximately 3 cm in the Lister tubercle. The plate was passed below the extensor tunnels, and an access was made to isolate the long extensor tendon of the thumb and to make sure that the plate was below the tendons. Fixation was performed with two distal screws, followed by fracture reduction and fixation with two proximal screws. A synthesis with Kirschner wires was also performed if required (► **Figure 3**).



**Fig. 2** Intraoperative image of the bridge plate technique.



**Fig. 3** Postoperative radiograph of a patient with a dorsal bridge plate.

All patients received an intraoperative antibiotic agent (cefazolin), in addition to an oral prophylactic antibiotic agent (cephalexin) for 10 days.

The first return visit was standardized for two weeks after surgery for suture removal and general education. Six weeks after the procedure, finger mobility was accessed, and the external fixator and Kirschner wires were removed. Twelve weeks after surgery, finger mobility after the removal of the external fixator was accessed; in addition, the synthesis material was removed at the operating room under anesthesia, and the joint was manipulated. After the removal of the synthesis material, patients from both groups were referred to physical therapy and rehabilitation, returning for visits every 12 weeks to assess mobility until completing 1 year of outpatient follow-up.

### Evaluated Variables

Outcome variables were collected up to one year after surgery during the outpatient follow-up. The presence of superficial or deep infections and the incidence of reflex sympathetic neuropathy were determined through the analysis of the medical records, as the diagnosis is clinical in both situations.

The visual analog scale (VAS) was used to assess the postoperative pain.

The DASH questionnaire was used for the functional assessment of the patients, and it consists of 30 questions related to limitations in daily living activities.<sup>14</sup> The ques-

tionnaire was always applied by the same evaluator. The questions were read and explained before they were answered by the patient.

Radiographic measurements of distal radial angles were performed with a goniometer on anteroposterior (AP) and lateral radiographs using the appropriate technique.

Ranges of motion were determined at a physical examination using a goniometer in flexion (normal: 70° to 80°), extension (normal: 60° to 70°), maximum pronation (normal: 0° to 80°), maximum supination (normal: 0° to 90°), radial deviation (normal: 20°) and ulnar deviation (normal: 45°).<sup>15</sup>

Grip strength was evaluated using a calibrated digital dynamometer, always by the same operator; values from both hands were determined and considered normal, decreased, or increased compared to the contralateral side.

### Statistical Analysis

Data were tabulated in an Excel (Microsoft Corp. Redmond, WA, US) spreadsheet and submitted to statistical analysis using the Statistical Package for the Social Sciences (SPSS, IBM Corp., Armonk, NY, EUA), version 20.0. The frequency and distribution of the variables were determined. Nominal variables were related to surgical techniques using the chi-squared test. Numerical variables were related to surgical techniques through a non-parametric Mann-Whitney test.

### Results

From the 43 patients evaluated, the mean age was 54.4 years old, and 25 patients (58.1%) of them were female. The most prevalent trauma mechanism was a fall from the own height (51.2%). In 22 patients (51.2%), the fracture occurred on the right side; 34 patients (79.1%) were right-handed (► **Table 1**).

Regarding postoperative infection, there was one case in the bridge plate group and two cases in the external fixator group, with no significant difference in incidences from both techniques ( $p = 0.379$ ). Reflex sympathetic neuropathy occurred in two patients treated with bridge plates and in one patient receiving an external fixator; once again, there was also no statistically significant difference between both groups ( $p = 0.738$ ). In total, 15 patients operated with bridge plate and 6 treated with an external fixator showed decreased grip strength, with a statistically significant difference between the 2 surgical techniques ( $p = 0.041$ ) (► **Table 2**).

According to the VAS, both techniques were associated with the same level of pain, with no statistically significant difference between them. The mean DASH score for the patients operated with a bridge plate was 39.05, and it was 36.36 for those operated with an external fixator, with no statistically significant difference between them ( $p = 0.569$ ). At the radiographic assessment, there were no statistically significant differences between the two surgical techniques in any of the measurements performed. Similarly, there were no statistically significant differences in the ranges of motion for extension, flexion, pronation, and radial deviation. In supination, the mean values were 41.82 and 59.29 for the bridge plate and the external fixator respectively, with a statistically significant difference between them ( $p = 0.012$ ).

**Table 1** Descriptive analysis of the demographic characteristics, surgeries, and fracture causes

Characteristics		N (%)
Gender	Male	18 (41.9)
	Female	25 (58.1)
Age	20–35	9 (20.9)
	36–45	5 (11.6)
	46–60	9 (20.9)
	> 61	20 (46.5)
Surgical technique	Bridge plate	25 (58.2)
	External fixator	18 (41.8)
Trauma mechanism	Fall at the own height	22 (51.2)
	Fall from height	14 (31.7)
	Traffic accident	7 (17.1)
Fractured side	Right	22 (51.2)
	Left	21 (48.8)
Dominant side	Right	34 (79.1)
	Left	9 (20.9)

**Table 2** Comparative analysis of the two surgical techniques

Surgical techniques				
		Bridge plate	External fixator	p-value
Postoperative infection	Yes	1	2	0.379
	No	24	16	
Reflex sympathetic neuropathy	Yes	2	1	0.738
	No	23	17	
Grip strength	Normal	10	12	0.041
	Decreased	15	6	

Ulnar deviation presented a statistically significant difference between both surgical techniques ( $p = 0.0049$ ), with 7.73 for the bridge plate, and 13.57 for the external fixator (► **Table 3**).

### Discussion

To our current knowledge, few studies compared the treatment of comminuted fractures with external fixators and bridge plates. These fractures are very prevalent and difficult to manage, and there is no consensus on the best surgical technique to treat them. As such, the present study was

**Table 3** Mean and standard deviation values for the two surgical techniques considering the numerical variables

	Bridge plate	External fixator	p-value
Pain scale	3.68 ± 2.61	4.64 ± 2.43	0.172
DASH	39.05 ± 13.75	36.36 ± 12.03	0.569
<b>Radiographic measurements</b>			
Radial height	8.14 ± 2.27	9.29 ± 2.19	0.069
Radial angle	15.91 ± 4.45	17.86 ± 3.18	0.217
Volar deviation	3.55 ± 4.00	4.21 ± 3.66	0.329
<b>Range of motion (ROM)</b>			
ROM – extension	40.45 ± 16.75	45.71 ± 14.39	0.667
ROM – flexion	51.14 ± 16.68	52.14 ± 18.47	0.438
ROM – pronation	43.18 ± 18.09	58.21 ± 17.71	0.062
ROM – supination	41.82 ± 18.67	59.29 ± 20.17	0.012
ROM – ulnar deviation	7.73 ± 7.02	13.57 ± 8.41	0.0049
ROM – radial deviation	7.73 ± 6.31	12.86 ± 6.41	0.066

Abbreviation: DASH, Disabilities of the Arm, Shoulder and Hand questionnaire.

carried out to show the outcomes with the use of materials that are easily accessible through the Brazilian Unified Health System (Sistema Único de Saúde, SUS, in Portuguese) and may improve the lives of the patients.

The dorsal bridge plate technique is indicated for deviated comminuted joint fractures with diminutive fragments that cannot be fixed using a volar plate.<sup>16</sup> Some authors advocate dorsal plates due to ligamentotaxis, which helps reduce fractures and spares soft tissues. Since there is no friction between tendons of the extensors and the plate, this technique favors finger mobility, and it is indicated in osteopenic bones, comminuted fractures, and polytraumas.<sup>17</sup> However, the dorsal plate may result in loss of wrist mobility, and it requires removal and reduces the fracture in only one plane.<sup>17</sup> In addition to the 3.5-mm DCP plate, there are semi-tubular plates in a single column for the radius or double column. When the fracture line is more proximal, 2.4-mm and 3.5-mm reconstruction plates may be used, which are more available at the SUS. Other plate types have been developed for this surgical technique, such as low-profile interlocked plates, which can be used in the second or third metacarpal bones. Wrist arthrodesis plates can also be employed to fix distal radius fractures, enabling the placement of larger screws to add stability. Similar to arthrodesis plates, more specific devices have recently emerged to treat these fractures through distraction; these are the spanning plates, which are shaped to facilitate the passage through extensor tendons and have fewer central holes, providing increased stiffness.<sup>16,18</sup>

Wrist transarticular external fixators were introduced in 1970,<sup>17</sup> and are increasingly used. As an advantage, these

fixators are minimally-invasive, sparing the retinaculum and the tendons. In addition, this is an easy and quick technique for polytrauma patients.<sup>19</sup>

When comparing the two surgical techniques, in general terms, we did not observe statistically significant differences, similarly to Saving et al.,<sup>20</sup> who evaluated the postoperative outcomes of external fixators and volar plates in a three-year follow-up period.

As complications, there were three cases of postoperative infection, two in patients treated with external fixators and one in a subject receiving a bridge plate. One of the cases of infection with an external fixator was superficial, and it was treated with an oral antibiotic agent, whereas the other required surgical debridement and fixator realignment. The bridge plate infection required surgical debridement and intravenous antibiotic therapy. Cui et al.<sup>21</sup> compared the use of internal versus external synthesis in patients with AOC3 distal radial fracture, and they observed a higher rate of infection when the external synthesis was performed. Abramo et al.<sup>22</sup> evaluated 50 patients with unstable distal radius fractures submitted to open reduction and internal fixation or closed reduction and external fixation, and they observed equivalent rates of superficial and deep infections in both techniques, corroborating our findings. In that study,<sup>22</sup> the main postoperative complication was hyperesthesia at the sensitive path of the radial nerve. Kreder et al.<sup>23</sup> assessed 179 patients with distal radial fractures treated with percutaneous fixation or internal fixation, using external fixators and plates. Infection was the most common postoperative complication; superficial infections were more common in indirect reduction with percutaneous fixation, but the incidence of deep infections was similar in both groups. In a meta-analysis study<sup>18</sup> comparing external fixators and bridge plates, the incidence of infection and reflex sympathetic dystrophy was lower in patients treated with bridge plates, but the cases of dystrophy did not require additional surgical treatment.

Reflex sympathetic neuropathy occurred in 2 patients treated with plates and 1 patient receiving an external fixator, corresponding to almost 7% of the total of patients; all of these subjects were female. Xu et al.<sup>24</sup> compared the treatment of type-C fractures according to the AO classification with external fixation and plates and did not observe any case of reflex sympathetic dystrophy. Arora et al.<sup>25</sup> evaluated the incidence of reflex sympathetic neuropathy in patients older than 65 years of age with distal radial fractures, including 36 subjects who underwent surgery and 37 individuals who were conservatively treated. Two surgical patients and five who were treated conservatively developed the syndrome. All patients improved their condition with analgesia and physical therapy. Xavier et al.<sup>26</sup> evaluated patients treated with blocked volar plates for distal radius fractures, and they observed an incidence of 1.5% of reflex sympathetic dystrophy, illustrating that even more modern materials may cause this complication.

Grip strength increased when external fixators were used. This is probably due to the earlier finger mobility provided by

the lack of plastered immobilization, with sustained moving during the immediate postoperative period; in addition, the placement of the dorsal plate requires lesser muscle manipulation during surgery. This finding is in line with the observation by Schönemann et al.<sup>27</sup> that internal synthesis materials have better outcomes when external fixation is compared with intramedullary fixation. Aita et al.<sup>28</sup> compared the distal radial fixation with plates, nails and external fixators, and they observed that, at the third postoperative week, the grip strength was lower in the subjects treated with external fixators compared to other techniques; however, after one year, the grip strength was similar in the patients from the three groups.

McQueen and Caspers<sup>29</sup> described the main complications of distal radius fractures, such as pain, stiffness, deformity, and loss of grip strength. These findings remain true today, despite the major advances in surgical techniques.

In the present study, we observed that, regardless of the treatment, postoperative pain after the removal of the synthesis material and physical therapy was similar in both groups. This outcome may be attributed to the reduction in fractures with similar radiographic features, because a better reduction of the fracture results in improved range of motion and less pain.<sup>30</sup> Aita et al.<sup>28</sup> compared locked volar plates, intramedullary nails and external fixators for the treatment of distal radius fractures, and they found a lower rate of pain in patients with internal synthesis material compared to those receiving external fixators after the third week.

The DASH scores were similar for both surgical techniques. These data were also obtained by Zenke et al.,<sup>31</sup> who found no significant difference when comparing these techniques. Xavier et al.<sup>26</sup> observed a correlation between reduced extension, flexion and grip strength with worse DASH scores, with an average DASH score of 10 for young people and of 21 for elderly patients.

The radiographic evaluation showed that we achieved a similarly acceptable fracture reduction with both techniques. A meta-analysis by Cui et al.<sup>21</sup> showed that several papers comparing different techniques also managed to reduce fractures within the recommended parameters. The only difference found by Xu et al.<sup>24</sup> was regarding radial inclination throughout years of evaluation, with no alterations in the range of motion of the patients.

In the present study, the ranges of motion resulting from both techniques were similar, except for supination and ulnar deviation, which were improved with the use of external fixators. Despite this difference, both techniques reached functional ranges of motion. Xavier et al.<sup>26</sup> also found no difference the range of motion of the patients. Kreder et al.<sup>23</sup> did not observe differences between different groups regarding postoperative mobility. Evaluating 33 patients older than 60 years of age with osteoporotic bones and C2 or C3 fractures who were treated using the dorsal bridge plate technique, Richard et al.<sup>32</sup> obtained good results for consolidation and range of motion.

Lewis et al.<sup>33</sup> assessed the incidence of complications in the fixation of second or third metacarpal bones in cadavers. The authors concluded that the fixation of the third

metacarpal bone had a greater chance of injury to the long extensor tendon of the thumb and, that the flexion-extension of the wrist was a bad indicator.

Our findings are particularly important for the progression of the fixation of distal radius fractures in patients with severe injuries who need to return to their daily and professional activities as soon as possible. Both operative techniques are easy to perform for orthopedic surgeons, and they require cheap materials that are promptly available at public services.

The reduced number of patients evaluated and their highly variable age, indicating different bone qualities, can be considered limitations for this study. We suggest that future studies include a higher number of subjects, stratified by age, and the inclusion of other fixation methods available, such as radial intramedullary nail and distal radial locked plate.

## Conclusion

Both techniques proved to be effective in the treatment of complex distal radius fractures, with a low rate of postoperative complications, satisfactory functional outcomes, and no superiority of one over the other.

### Conflict of Interests

The authors have no conflict of interests to declare.

## References

- Alffram PA, Bauer GC. Epidemiology of fractures of the forearm. A biomechanical investigation of bone strength. *J Bone Joint Surg Am* 1962;44-A:105-114
- Arora R, Gabl M, Gschwentner M, Deml C, Krappinger D, Lutz M. A comparative study of clinical and radiologic outcomes of unstable Colles type distal radius fractures in patients older than 70 years: nonoperative treatment versus volar locking plating. *J Orthop Trauma* 2009;23(04):237-242
- Tumia N, Wardlaw D, Hallett J, Deutman R, Mattsson SA, Sandén B. Aberdeen Colles' fracture brace as a treatment for Colles' fracture. A multicentre, prospective, randomised, controlled trial. *J Bone Joint Surg Br* 2003;85(01):78-82
- Glickel SZ, Catalano LW, Raia FJ, Barron OA, Grabow R, Chia B. Long-term outcomes of closed reduction and percutaneous pinning for the treatment of distal radius fractures. *J Hand Surg Am* 2008;33(10):1700-1705
- Lee DY, Park YJ, Park JS. A Meta-analysis of studies of volar locking plate fixation of distal radius fractures: conventional versus minimally invasive plate osteosynthesis. *Clin Orthop Surg* 2019;11(02):208-219
- Handoll HHG, Madhok R. Closed reduction methods for treating distal radial fractures in adults. *Cochrane Database Syst Rev* 2003; (01):CD003763
- LaMartina J, Jawa A, Stucken C, Merlin G, Tornetta P III. Predicting alignment after closed reduction and casting of distal radius fractures. *J Hand Surg Am* 2015;40(05):934-939
- Piva Neto A, Lhamby FC. Fixação das fraturas da extremidade do rádio distal pela técnica de Kapandji: avaliação dos resultados radiológicos. *Rev Bras Ortop* 2011;46(04):368-373
- Snow M, Kelly M, Jeyam M, Fahmy N. Functional versus position: a randomized controlled trial of interfocal Kirschner wiring of unstable distal radial fractures. *Eur J Trauma Emerg Surg* 2007; 33(01):81-86
- Benson LS, Minihane KP, Stern LD, Eller E, Seshadri R. The outcome of intra-articular distal radius fractures treated with fragment-specific fixation. *J Hand Surg Am* 2006;31(08):1333-1339
- Azad A, Intravia JM, Hill JR, et al. Carpal translocation following dorsal bridge plate fixation of distal radius fractures: a cadaveric study. *J Wrist Surg* 2019;8(03):234-239
- Harley BJ, Scharfenberger A, Beaupre LA, Jomha N, Weber DW. Augmented external fixation versus percutaneous pinning and casting for unstable fractures of the distal radius—a prospective randomized trial. *J Hand Surg Am* 2004;29(05):815-824
- Atroshi I, Brogren E, Larsson GU, Kloow J, Hofer M, Berggren AM. Wrist-bridging versus non-bridging external fixation for displaced distal radius fractures: a randomized assessor-blind clinical trial of 38 patients followed for 1 year. *Acta Orthop* 2006;77 (03):445-453
- Hudak PL, Amadio PC, Bombardier C; The Upper Extremity Collaborative Group (UECG). Development of an upper extremity outcome measure: the DASH (disabilities of the arm, shoulder and hand) [corrected]. *Am J Ind Med* 1996;29(06):602-608
- Barros Filho TEP, Lech O. Exame físico em ortopedia. 3ª. Ed. São Paulo: Editora Sarvier; 2017
- Vakhshori V, Alluri RK, Stevanovic M, Ghiassi A. Review of internal radiocarpal distraction plating for distal radius fracture fixation. *Hand (N Y)* 2018;1558944718787877
- Hyatt BT, Hanel DP, Saucedo JM. Bridge plating for distal radius fractures in low-demand patients with assist devices. *J Hand Surg Am* 2019;44(06):507-513
- Tinsley BA, Ilyas AM. Distal radius fractures in a functional quadruped: spanning bridge plate fixation of the wrist. *Hand Clin* 2018;34(01):113-120
- Mishra AK, Sud AD, Prasad M, Kaul R, Singh CM. A comparative study of functional outcome of external fixation and volar plating in unstable distal radius fractures. *Int J Res Orthop* 2019;5(02):326-334
- Saving J, Enocson A, Ponzer S, Mellstrand Navarro C. External Fixation Versus Volar Locking Plate for Unstable Dorsally Displaced Distal Radius Fractures-A 3-Year Follow-Up of a Randomized Controlled Study. *J Hand Surg Am* 2019;44(01):18-26
- Cui Z, Pan J, Yu B, Zhang K, Xiong X. Internal versus external fixation for unstable distal radius fractures: an up-to-date meta-analysis. *Int Orthop* 2011;35(09):1333-1341
- Abramo A, Kopylov P, Geijer M, Tägil M. Open reduction and internal fixation compared to closed reduction and external fixation in distal radial fractures: a randomized study of 50 patients. *Acta Orthop* 2009;80(04):478-485
- Kreder HJ, Hanel DP, Agel J, et al. Indirect reduction and percutaneous fixation versus open reduction and internal fixation for displaced intra-articular fractures of the distal radius: a randomised, controlled trial. *J Bone Joint Surg Br* 2005;87(06): 829-836
- Xu GG, Chan SP, Puhaindran ME, Chew WY. Prospective randomised study of intra-articular fractures of the distal radius: comparison between external fixation and plate fixation. *Ann Acad Med Singapore* 2009;38(07):600-606
- Arora R, Lutz M, Deml C, Krappinger D, Haug L, Gabl M. A prospective randomized trial comparing nonoperative treatment with volar locking plate fixation for displaced and unstable distal radial fractures in patients sixty-five years of age and older. *J Bone Joint Surg Am* 2011;93(23):2146-2153
- Xavier CR, Molin DC, Santos RM, Santos RD, Ferreira Neto JC. Tratamento cirúrgico das fraturas do rádio distal com placa volar bloqueada: correlação dos resultados clínicos e radiográficos. *Rev Bras Ortop* 2011;46(05):505-523
- Schönnemann JO, Hansen TB, Søballe K. Randomised study of non-bridging external fixation compared with intramedullary fixation of unstable distal radial fractures. *J Plast Surg Hand Surg* 2011;45(4-5):232-237
- Aita MA, Ferreira CH, Ibanez DS, et al. Ensaio clínico randomizado de osteossíntese percutânea e minimamente invasiva das fraturas

- da extremidade distal do rádio. *Rev Bras Ortop* 2014;49(03): 218–226
- 29 McQueen M, Caspers J. Colles fracture: does the anatomical result affect the final function? *J Bone Joint Surg Br* 1988;70(04):649–651
- 30 Andrade LE, Oliveira D, Barros JW. Tratamento das fraturas instáveis da extremidade distal do rádio com desvio volar utilizando-se placa de apoio. *Acta Ortop Bras* 2002;10(04):5–9
- 31 Zenke Y, Sakai A, Oshige T, et al. Clinical results of volar locking plate for distal radius fractures: conventional versus minimally invasive plate osteosynthesis. *J Orthop Trauma* 2011;25(07): 425–431
- 32 Richard MJ, Katolik LI, Hanel DP, Wartinbee DA, Ruch DS. Distraction plating for the treatment of highly comminuted distal radius fractures in elderly patients. *J Hand Surg Am* 2012;37(05): 948–956
- 33 Lewis S, Mostofi A, Stevanovic M, Ghiassi A. Risk of tendon entrapment under a dorsal bridge plate in a distal radius fracture model. *J Hand Surg Am* 2015;40(03):500–504