



Percutaneous Suspensory Stabilization of Chronic Distal Radioulnar Joint (DRUJ) Dislocation Using an Adjustable Loop Endobutton Construct: Case Report*

Fixação suspensiva percutânea de luxação crônica da articulação radioulnar distal (ARUD) usando um dispositivo de endobutton de laço ajustável: Relato de caso

Mohammed Schezan Iqbal¹ Anil Kumar Mishra² Rajiv Kaul³

¹ Department of Orthopaedics, INHS Kalyani, Visakhapatnam, India

² Department of Orthopaedics, Military Hospital Kirkee, Pune, India

³ Department of Orthopaedics, Armed Forces Medical College, Pune, India

Endereço para correspondência Mohammed Schezan Iqbal, MS (Orthopaedics), Department of Orthopaedics, INHS Kalyani, Visakhapatnam, Andhra Pradesh, 530005, India (e-mail: dr.schezaniqbal@gmail.com).

Rev Bras Ortop 2023;58(2):351–355.

Abstract

Keywords

- ▶ wrist injuries/diagnosis
- ▶ wrist injuries/surgery
- ▶ wrist injuries/physiology
- ▶ orthopedics/trends
- ▶ external fixators

Resumo

Palavras-chave

- ▶ lesões no punho/diagnóstico

Chronic distal radioulnar joint (DRUJ) dislocation has been treated historically with complex osteotomies and reconstructive procedures, often resulting in intractable stiffness and loss of function. It is desirable to use a technique of fixation that will not only restore the wrist biomechanics but also be cosmetically appealing to the individual. We present a novel technique of reduction and fixation of a chronically dislocated DRUJ in a 26-year-old male using a minimally invasive approach, with successful restoration of DRUJ function and no postoperative complications.

Luxação crônica da articulação radioulnar distal (ARUD) foi tratada historicamente com osteotomias complexas e procedimentos reconstrutivos, geralmente resultando em rigidez intratável e perda de função. É desejável usar uma técnica de fixação que não apenas restaure a biomecânica do punho, mas também seja esteticamente atraente para o indivíduo. Apresentamos uma nova técnica de redução e fixação de uma ARUD

* Work developed at the Department of Orthopaedics, INHS Kalyani, Visakhapatnam, India.

received
April 11, 2020
accepted
June 1, 2020
article published online
September 25, 2020

DOI <https://doi.org/10.1055/s-0040-1715515>.
ISSN 0102-3616.

© 2020. Sociedade Brasileira de Ortopedia e Traumatologia. All rights reserved.
This is an open access article published by Thieme under the terms of the Creative Commons Attribution-NonDerivative-NonCommercial-License, permitting copying and reproduction so long as the original work is given appropriate credit. Contents may not be used for commercial purposes, or adapted, remixed, transformed or built upon. (<https://creativecommons.org/licenses/by-nc-nd/4.0/>)
Thieme Revinter Publicações Ltda., Rua do Matoso 170, Rio de Janeiro, RJ, CEP 20270-135, Brazil

- ▶ lesões no punho/cirurgia
 - ▶ lesões no punho/fisiologia
 - ▶ ortopedia/tendências
 - ▶ fixadores externos
- deslocada cronicamente em um homem de 26 anos, usando uma abordagem minimamente invasiva, com restauração bem-sucedida da função da ARUD e sem complicações pós-operatórias.

Introduction

Distal radioulnar joint (DRUJ) instability occurs due to disruption of both the intrinsic (i.e., the triangular fibrocartilage complex [TFCC]) and the extrinsic wrist stabilizers (i.e., the volar and dorsal radioulnar ligaments). This can occur in isolation or in association with distal radius fractures and their variants (3–37%).¹ Treatment options include osteotomies, osteoplasty, soft tissue reconstructions and salvage surgeries like the Darrach and Sauve-Kapandji procedures.¹

In the present report, we have described a novel percutaneous, suspensory fixation for a chronic DRUJ dislocation secondary to an old distal radius fracture.

Case Report

The subject was a 26-year-old male with a 9-month long history of pain and deformity in the left wrist, following a road traffic accident. At the initial injury, there was extensive skin loss over the wrist and the forearm, which was managed

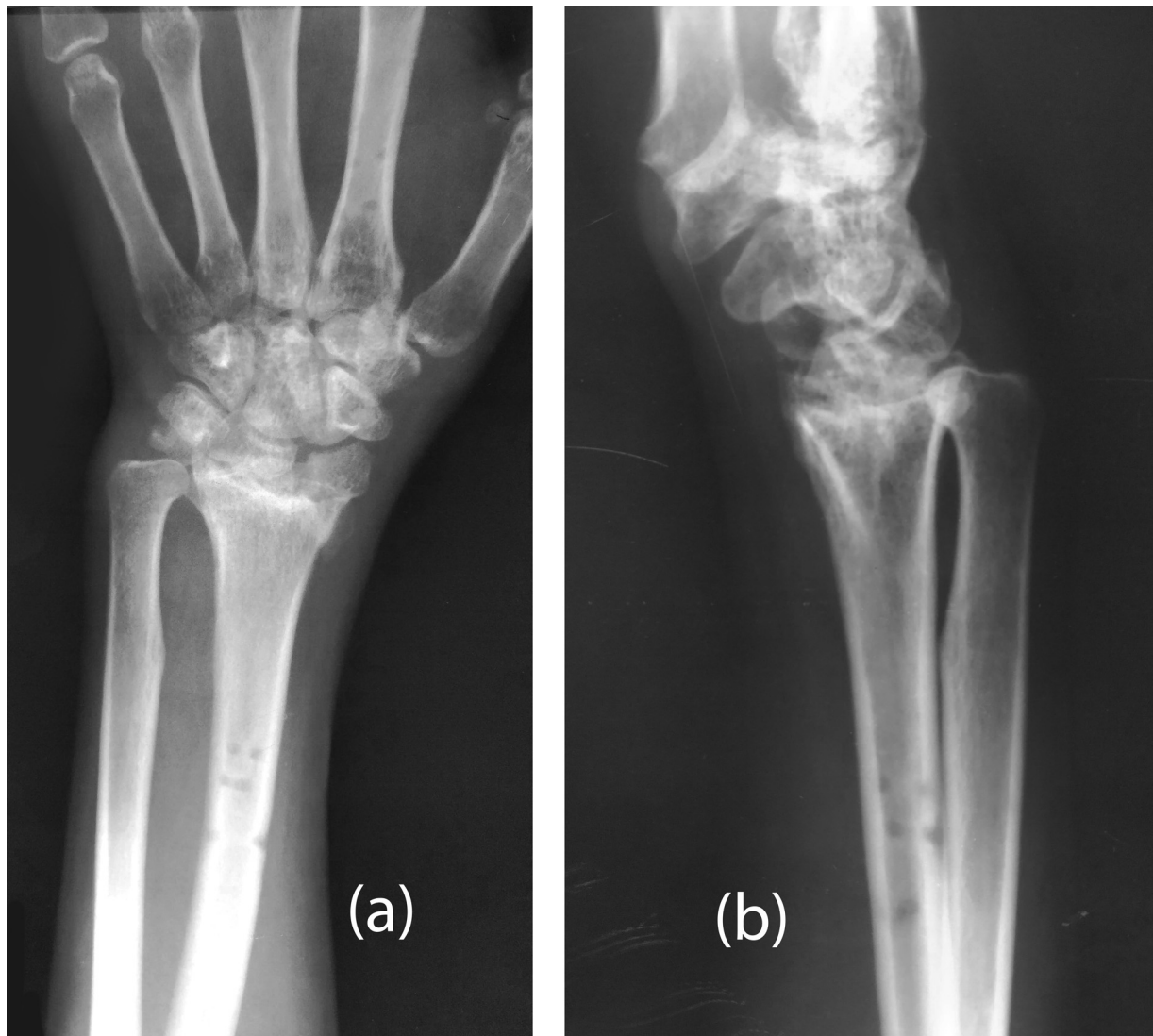


Fig. 1 Preoperative X-ray of the Wrist (PA and lateral views).

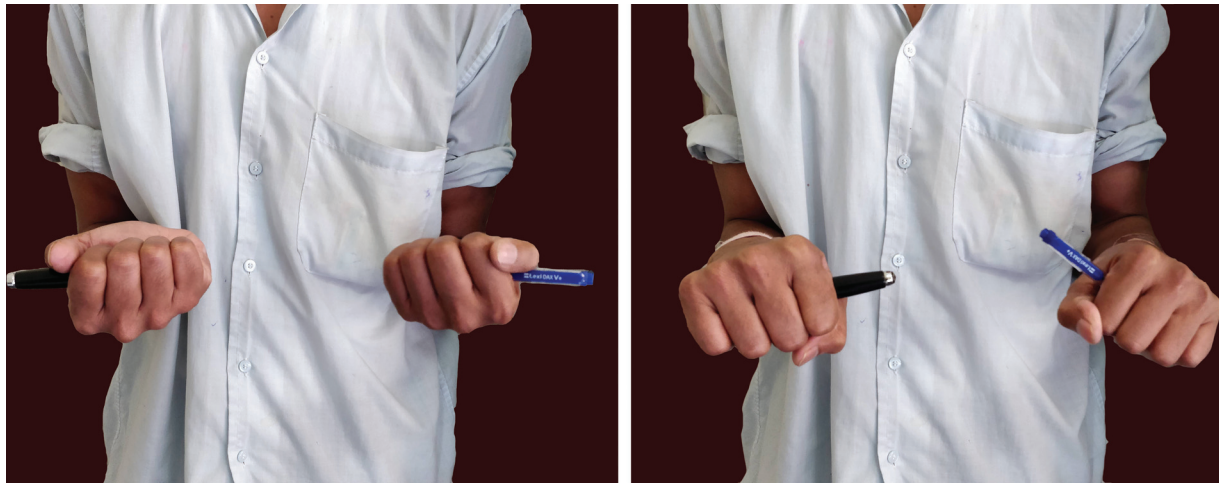

Fig. 2 Postoperative clinical photograph (Pronosupination).

with a unilateral wrist spanning external fixator and percutaneous Kirschner wire fixation for a period of 2 months. Split skin grafting (SSG) was done to address the raw areas keeping the external fixator in situ. Following the fixator removal, the patient noted a deformity of the wrist that included an undue prominence of the ulna along with a severe restriction of pronosupination, and occasional clicking of the wrist.

On examination, the patient had a manus varus deformity along with an abnormal prominence of the ulnar head dorsally. Ballottement test and piano key sign were positive.

The wrist movements were restricted to 50° of dorsiflexion, 30° of palmar flexion, 60° of pronation and no supination. Grip strength was 50% of the normal hand. There were no neurovascular deficits in the affected extremity.

X-rays of the wrist (Postero-anterior [PA] and lateral views) (→**Fig. 1a-b**) showed a gross articular incongruity of the radiocarpal joint, with evidence of early, extensive wrist arthrosis and radial shortening. There was dorsal dislocation of the distal ulna on the lateral view, with an overlap of the distal radius and ulna on the PA view.

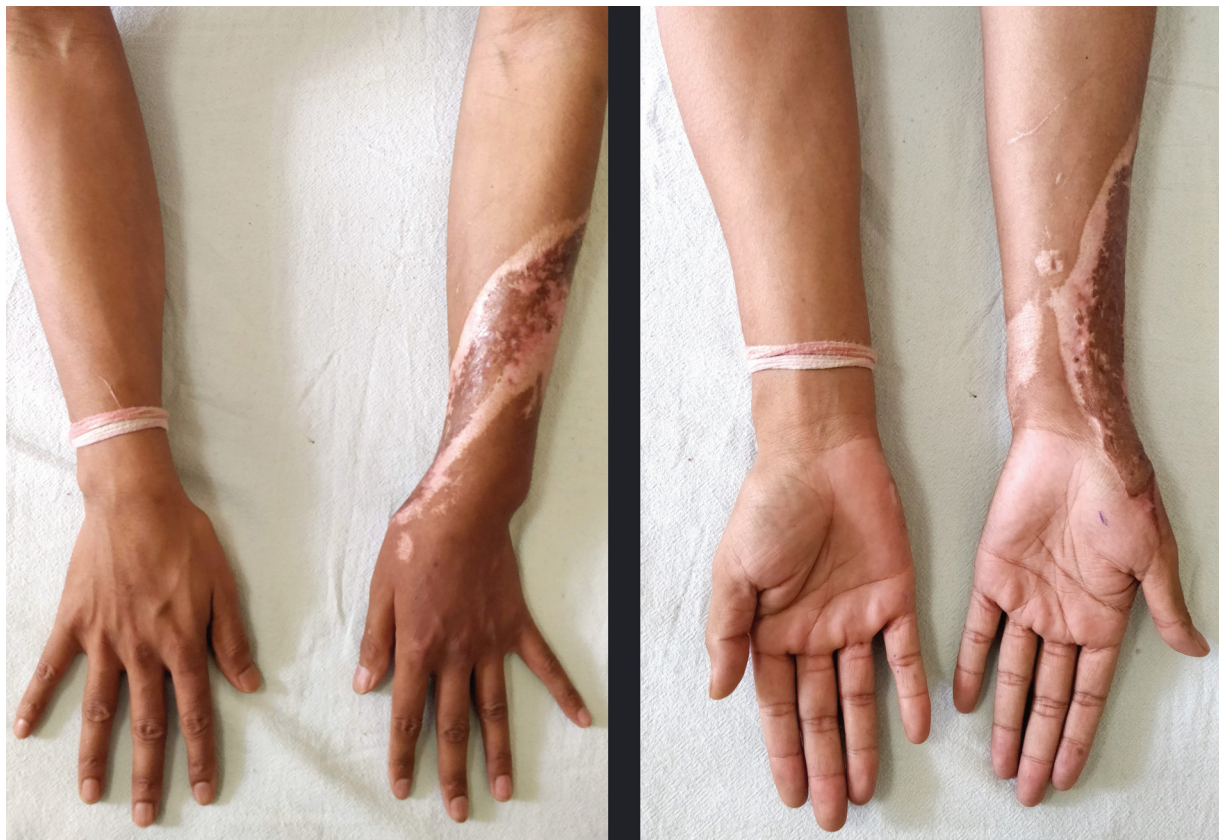


Fig. 3 Postoperative clinical photograph (Dorsal and volar aspects).

In view of the young age and functional requirements of the patient, a decision to perform a minimally invasive surgical intervention was taken, which was performed in the following manner.

Surgical Technique

Under regional anesthesia, the affected upper limb was placed prone on a radiolucent table. Satisfactory closed reduction of the DRUJ dislocation was achieved by applying a volarly directed pressure on the ulnar head and provisional fixation done using a 1.5 mm Kirschner wire. A 2.7 mm cannulated drill bit was used over a guidewire to drill a tunnel from the distal ulna to the distal radius in the general direction of the distal oblique bundle. Arthrex Tightrope RT

(Arthrex, Inc. Naples, Florida, USA) was passed from the ulnar side with the endobutton on the radial side and after confirming the reduction under fluoroscopy, the button was flipped and tightened. The polyester suture was looped around the ulna and tied after passing through a separate drill hole in the ulna. An above-elbow slab with wrist in full supination was applied for 4 weeks, following which gradual mobilization and strengthening exercises were initiated. We did not experience any postoperative complications like paresthesia, infection, stiffness etc. The range of motion (ROM) achieved at 3 months of follow-up was 70° of dorsiflexion, 60° of palmar flexion, 80° pronation and 70° supination. Grip strength was 80% of the normal hand (►Figs. 2 and 3). The postoperative X-ray at 3 months is shown in ►Fig. 4a-b.

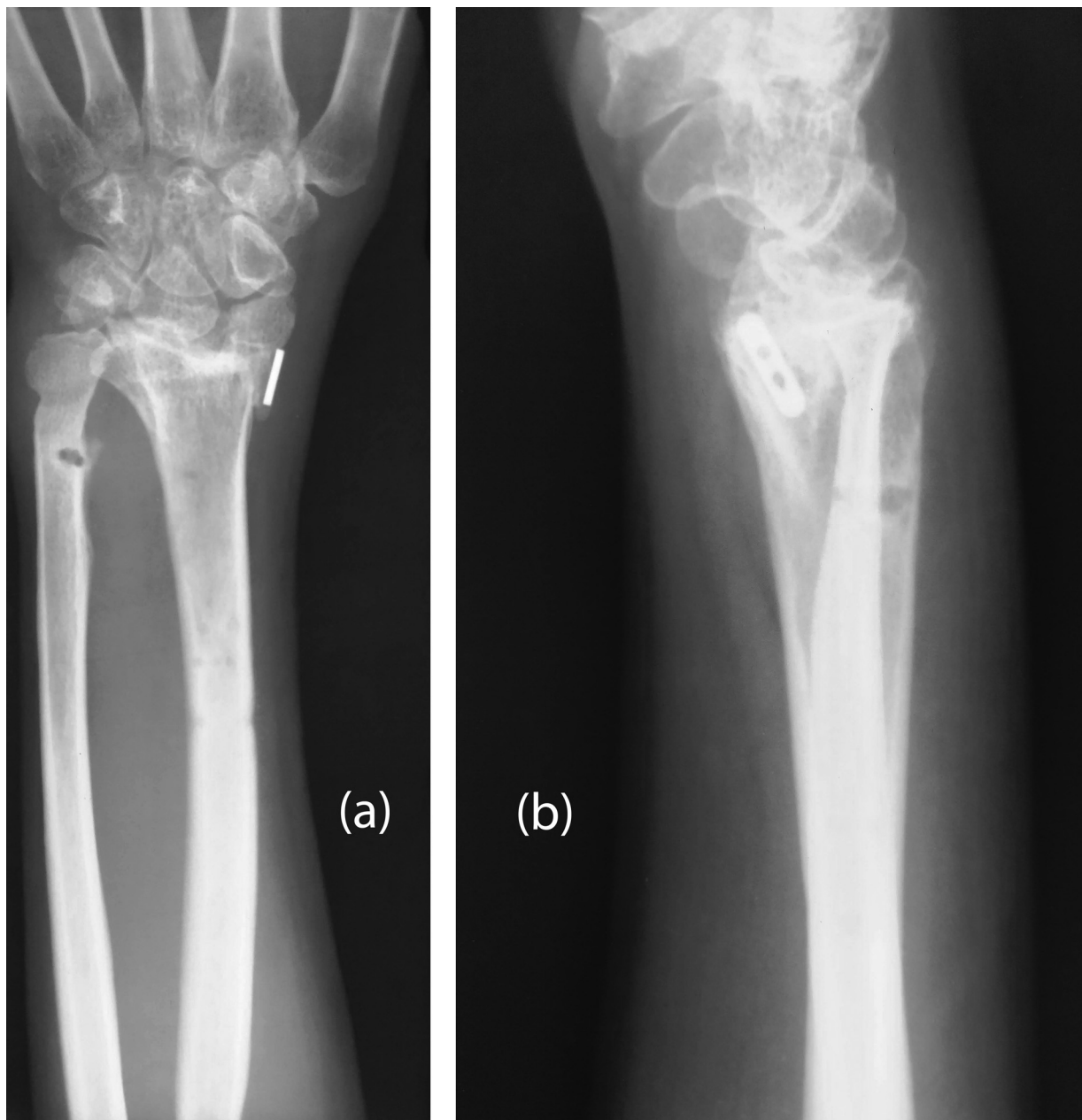


Fig. 4 Postoperative X-ray of the Wrist (PA and lateral views).

Discussion

The principles that govern the management of chronic DRUJ instability are essentially based on bone or soft tissue involvement and reconstructions thereof.² In cases with considerable bony deformities, realignment osteotomies with or without ulnar shortening are performed.

If the TFCC is repairable, then procedures like capsular plication and TFCC reinsertion using suture anchors, either arthroscopically or open, are usually the first line of treatment. When direct repair of the TFCC is no longer possible, then extra-anatomical tenodesis or ligament reconstruction is needed to reconstruct the radioulnar ligaments and foveal insertion.² Called the Adams and Berger technique,³ anatomical tenodesis uses the palmaris longus tendon and needs radial and ulnar transosseous tunnels. This technique best reproduces the normal kinematics of the DRUJ.⁴ Nakamura⁵ described an extra-anatomical procedure that combined tenodesis & ligament reconstruction using a distally pedicled hemi-extensor carpi ulnaris (ECU) graft with a single transulnar tunnel which is passed through the TFCC remnants and impacted on the foveal attachment. Recently, reconstruction of the distal oblique bundle (DOB)⁶ has been described, which configures an isometric radioulnar graft that stabilizes the DRUJ over the entire pronosupination ROM.

For cartilage injuries involving the DRUJ, palliative procedures like the Sauvé-Kapandji⁷ or Darrach & Bowers and Gaebler and McQueen⁸ and their variants can be performed; however, stabilization of the proximal ulnar stump remains a concern. Constrained arthroplasties⁹ are limited by the relatively small number of studies and short follow-up of this cohort of patients.

In their work, de Vries et al.¹⁰ described a minimally invasive procedure for stabilization of the distal radioulnar joint in cadaveric specimens, using a suture-button construct placed percutaneously directed along the distal oblique bundle of the interosseous membrane. Similar to the aforementioned technique, we used a minimally invasive suspensory fixation placed along the direction of the DOB to restore DRUJ stability.

Our simple technique is both anatomically and biologically stable. Removal can be done percutaneously, if needed. This technique is a useful alternative to the traditional

method of transfixation using a Kirschner wire. Potential complications include decreased joint mobility and overstuffing of the sigmoid notch if the construct is overtightened. Also, inaccurate drilling could result in iatrogenic fractures of the ulna or of the radius, damage to the ulnar or superficial radial nerve and a nonanatomical tunnel which will impede DRUJ movements. Based upon our experience, we recommend this technique in the setting of acute as well as chronic DRUJ dislocations.

Financial Support

The authors declare that they have not received financial support from public, private, or non-profit sources for the conduction of the present study.

Conflict of Interests

The authors have no conflict of interests to declare.

Referências

- Mulford JS, Axelrod TS. Traumatic injuries of the distal radioulnar joint. *Hand Clin* 2010;26(01):155-163
- Marès O. Distal radioulnar joint instability. *Hand Surg Rehabil* 2017;36(05):305-313
- Adams BD, Berger RA. An anatomic reconstruction of the distal radioulnar ligaments for posttraumatic distal radioulnar joint instability. *J Hand Surg Am* 2002;27(02):243-251
- Gofton WT, Gordon KD, Dunning CE, Johnson JA, King GJ. Comparison of distal radioulnar joint reconstructions using an active joint motion simulator. *J Hand Surg Am* 2005;30(04):733-742
- Nakamura T. Anatomical Reattachment of the TFCC to the Ulnar Fovea Using an ECU Half-Slip. *J Wrist Surg* 2015;4(01):15-21
- Brink PR, Hannemann PF. Distal Oblique Bundle Reinforcement for Treatment of DRUJ Instability. *J Wrist Surg* 2015;4(03):221-228
- Kapandji IA. The Kapandji-Sauvé operation. Its techniques and indications in non rheumatoid diseases. *Ann Chir Main* 1986;5(03):181-193
- Gaebler C, McQueen MM. Ulnar procedures for post-traumatic disorders of the distal radioulnar joint. *Injury* 2003;34(01):47-59
- Kakar S, Fox T, Wagner E, Berger R. Linked distal radioulnar joint arthroplasty: an analysis of the APTIS prosthesis. *J Hand Surg Eur Vol* 2014;39(07):739-744
- de Vries EN, Walenkamp MM, Mulders MA, Dijkman CD, Strackee SD, Schep NW. Minimally invasive stabilization of the distal radioulnar joint: a cadaveric study. *J Hand Surg Eur Vol* 2017;42(04):363-369