


# Anatomical Study of the Infrapatellar Branch of the Saphenous Nerve in Humans\*

## *Estudo anatômico do ramo infrapatelar do nervo safeno em humanos*

Alexandre Paiva Luciano<sup>1,2</sup>  Renan Toshio Melo Honda<sup>2</sup> Anuar Ralio Kamar<sup>2</sup> Nelson Franco Filho<sup>1,2</sup> Magno César Vieira<sup>3</sup>

<sup>1</sup>Discipline of Orthopedics and Traumatology, Faculty of Medicine, Universidade de Taubaté, Taubaté, SP, Brazil

<sup>2</sup>Orthopedics and Traumatology Service, Hospital Universitário de Taubaté, Taubaté, SP, Brazil

<sup>3</sup>Discipline of Descriptive and Topographic Anatomy, Faculty of Medicine, Universidade de Taubaté, Taubaté, SP, Brazil

Address for correspondence Alexandre de Paiva Luciano, PhD, Orthopedics and Traumatology Service, Hospital Universitário de Taubaté, Av. Granadeiro Guimarães, 270, Centro, Taubaté, SP, 12020-130, Brazil (e-mail: paivaortopedia@gmail.com).

Rev Bras Ortop 2020;55(5):557–563.

### Abstract

**Objective** To perform an anatomical study of the location of the infrapatellar branch of the saphenous nerve in relation to the structures of the knee.

**Methods** An anatomical study was performed by dissection of 18 humans knees (9 right and 9 left knees). After exposure of the infrapatellar branch and its direct and indirect branches, they were then measured. We adopted a quadrant in the medial region of the knee delimited by two transversal planes as a parameter of the study.

**Results** In 17 of the 18 knees (94.4%) studied, a single infrapatellar branch was observed. The infrapatellar branch emerged as fibers of the womb of the sartorius muscle in 17 of the 18 knees (94.4%). In relation to the branch, we observed that in 100% of the knees the infrapatellar branch had at least one primary branch, resulting in a superior branch and an inferior branch. In 9 limbs (50% of the cases) this branch occurred outside the proposed quadrant, and, in the remaining limbs, it occurred within the quadrant.

**Conclusion** The infrapatellar saphenous nerve branch was found in all dissected knees, and, in 94.4% of the cases, it was of the penetrating type; in 100% of the cases, it originated two primary direct branches. The direct and indirect branches presented great variability regarding their path.

### Keywords

- ▶ knee/innervation
- ▶ nerve compression syndromes
- ▶ anatomy

### Resumo

**Objetivo** Realizar um estudo anatômico da localização do ramo infrapatelar do nervo safeno em relação às estruturas do joelho.

\* Work developed in the Disciplines of Descriptive and Topographic Anatomy, and Discipline of Orthopedics and Traumatology, Divisão de Medicina Esportiva, Departamento de Medicina da Universidade de Taubaté, Taubaté, SP, Brazil.

**Palavras-chave**

- ▶ joelho/inervação
- ▶ síndromes de compressão nervosa
- ▶ anatomia

**Métodos** Estudo anatômico realizado por meio de dissecação de 18 joelhos (9 diretos e 9 esquerdos). Após a exposição do ramo infrapatelar e de seus ramos diretos e indiretos, seguiram-se as medidas deles. Como parâmetro do estudo, adotamos um quadrante na região medial do joelho delimitado por dois planos transversais.

**Resultados** Em 17 dos 18 joelhos estudados (94,4%), observou-se um único ramo infrapatelar. O ramo infrapatelar emergia por entre as fibras do ventre do músculo sartório em 17 dos 18 joelhos (94,4%). Em relação à ramificação, observamos que em 100% dos joelhos o ramo infrapatelar apresentava pelo menos uma ramificação primária, resultando num ramo superior e em outro inferior. Em 9 membros (50% dos casos), esta ramificação ocorria fora do quadrante proposto, e, no restante, dentro do quadrante.

**Conclusão** O ramo infrapatelar do nervo safeno foi encontrado em todos os joelhos dissecados e, em 94,4% dos casos, o ele era do tipo penetrante; em 100% dos casos, ele originava 2 ramos diretos primários. Seus ramos diretos e indiretos apresentaram grande variabilidade quanto ao trajeto.

## Introduction

The neuropathy of the infrapatellar branch of the saphenous nerve is a frequently overlooked and underdiagnosed cause of persistent postoperative knee pain.<sup>1,2</sup>

The infrapatellar branch originates from the saphenous nerve, emerges distally to the adductor canal, and pierces the sartorius muscle, after which it travels a superficial path and usually subdivides into two branches. Both branches cross the patellar ligament transversely to form the infrapatellar plexus.<sup>3</sup> These small superficial branches are at risk of transection, especially when longitudinal surgical incisions are made. Injury to the infrapatellar branch of the saphenous nerve generally results in numbness on the anterior aspect of the knee, in lateral and proximal parts of the leg.

After knee surgical procedures, it is common for patients to complain of pain and paresthesia in the anterior knee region, which may radiate to the anterior, lateral and proximal regions of the ipsilateral leg. Studies also relate the infrapatellar branch of the saphenous nerve with the direct innervation of the anterior medial ligaments of the knee, being one of the factors responsible for proprioception and the consequent stability and balance of the knee.<sup>3,4</sup>

Damage to the infrapatellar branch of the saphenous nerve was also reported after major surgical procedures in the knee, such as total knee arthroplasty,<sup>5</sup> arthroscopy for meniscectomies,<sup>6</sup> and after reconstruction of the anterior cruciate ligament.<sup>7</sup>

Thus, we understand that detailed knowledge of the anatomical path and of the possible anatomical variations of the infrapatellar branch of the saphenous nerve in relation to the knee structures is of essential importance to control postoperative morbidity, which may range from paresthesias to proprioception deficit of the knee joint.

Therefore, the present research aims to perform an anatomical study of the location of the infrapatellar branch of the saphenous nerve in relation to the knee structures, in order

to identify its route, its direct and indirect branches, and its distribution territory.

## Materials and Methods

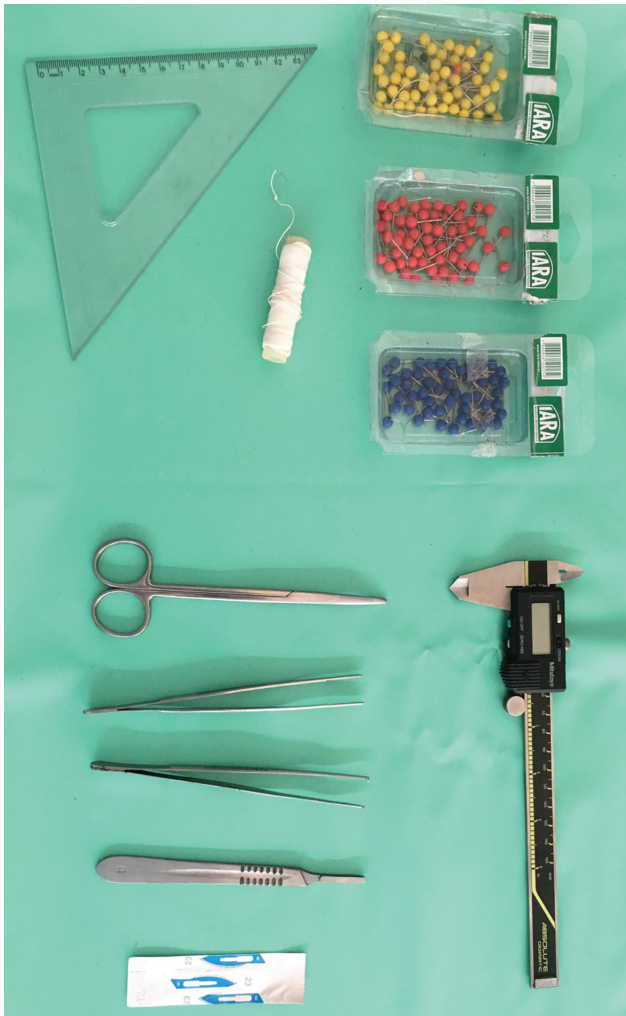
The present is an anatomical study that was performed by dissecting 18 knees (9 right and nine left knees), 11 of them belonging to males and 7, to females, from the Human Anatomy Laboratory of our institution. The study was previously approved by the ethics committee (CAAE: 44657115.5.0000.5501, opinion: 1055300).

In total, 2 authors were responsible for the dissection of 18 knees, 77.8% (14) of which belonged to 7 complete cadavers; 16.7% (3) were from isolated lower limbs, and 5.5% (1) were from an amputated lower limb. For the dissection, scalpels with number 3 and 4 handles, Metzemaum scissors, anatomical and toothed clamp tweezers were used. The measurements were performed using a Digimess digital caliper (Digimess Instrumentos de Precisão Ltda. São Paulo, SP, Brasil) (▶ **Figure 1**), and they were expressed in millimeters (mm) and compared between two authors.

## Dissection Description

The dissection was performed by positioning the corpse in horizontal supine position, with the knee extended. Three skin incisions were made. Two horizontal incisions: the first, in the lower and distal third of the thigh, and the second, between the upper and middle thirds of the leg. A vertical incision was made, joining the coincident midpoints of the horizontal incisions, in the longitudinal position, with the midpoints of the base and apex of the patella and the tibial tuberosity. Subsequently, lateral to medial skin folding was performed, exposing the subcutaneous mesh, in which the infrapatellar branch of the saphenous nerve and its direct and indirect branches were dissected. (▶ **Figure 2**).

After exposure of the infrapatellar branch and its direct and indirect branches, they were measured. For this, we



**Fig. 1** Material used for the dissection: scalpels with number 3 and 4 handles, Metzenbaum scissors, anatomical and toothed clamp tweezers, and Digimess digital caliper.

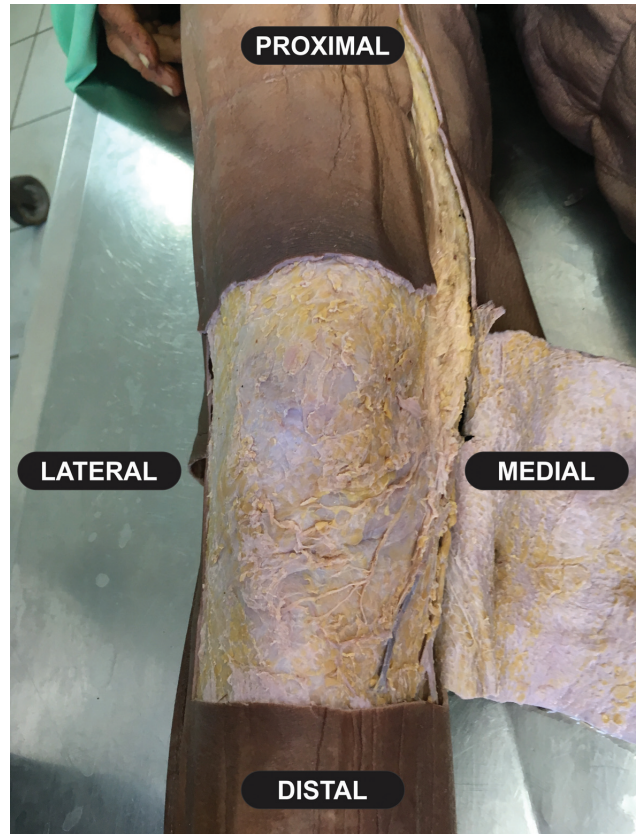
adopted a quadrant (study area), in the medial region of the knee, delimited by two transverse planes. A superior plane, that passes through the articular line (AL) of the knee; and another inferior plane that crosses the highest point of the tibial tuberosity, called the tibial tubercle line (TTL), and a longitudinal line (LL) that crosses the transverse planes perpendicularly, from the midpoint of the tibial plateau to the highest point of the tibial tuberosity (► **Figure 3**).

The reference points of the tibial plateau and tibial tuberosity, respectively superiorly and inferiorly, were marked with colored pins. With a T-square, the crossing point of the lines was marked, defining the quadrant for the study (► **Figure 4**).

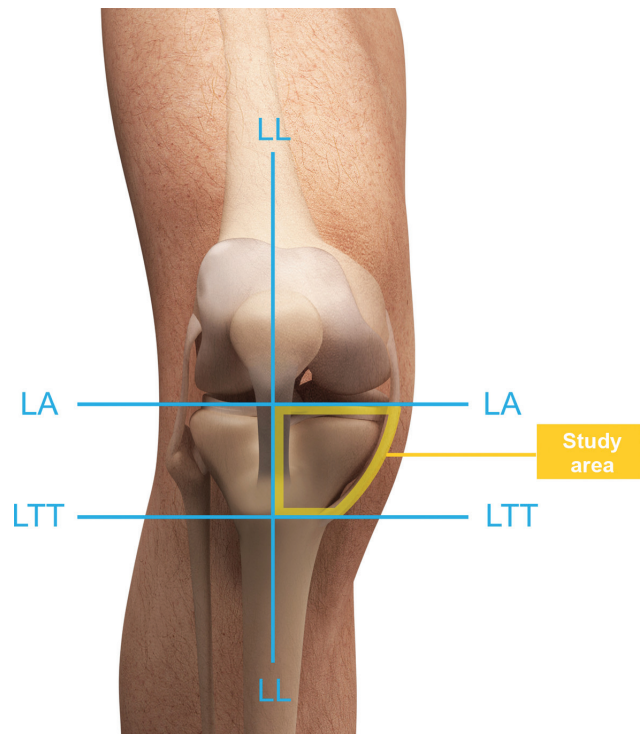
**Nomenclature Used for Measurements (► **Figure 4**)**

Measurement 1: distance between the point of emergency of the infrapatellar branch in the medial region of the knee and the AL;

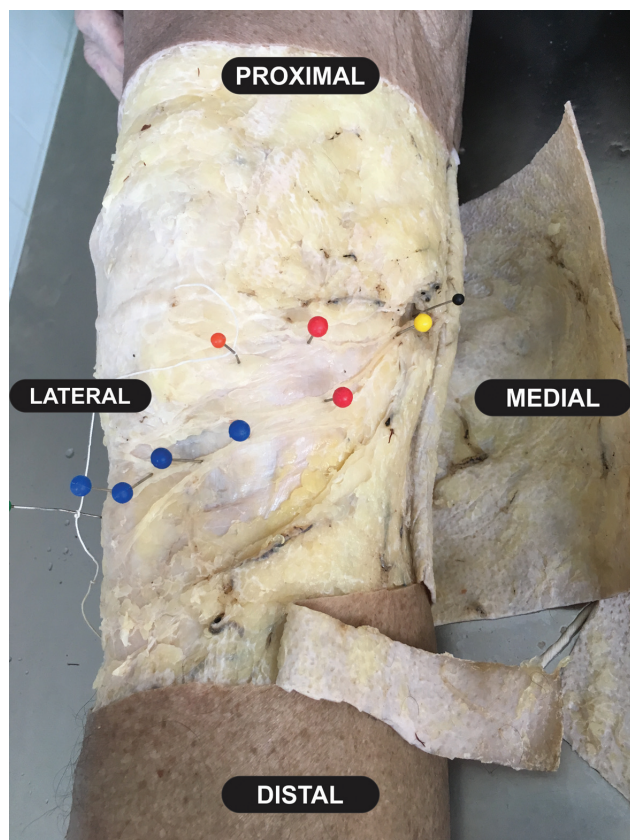
Measurement 2: distance between the primary branching point of the infrapatellar branch and AL and LL;



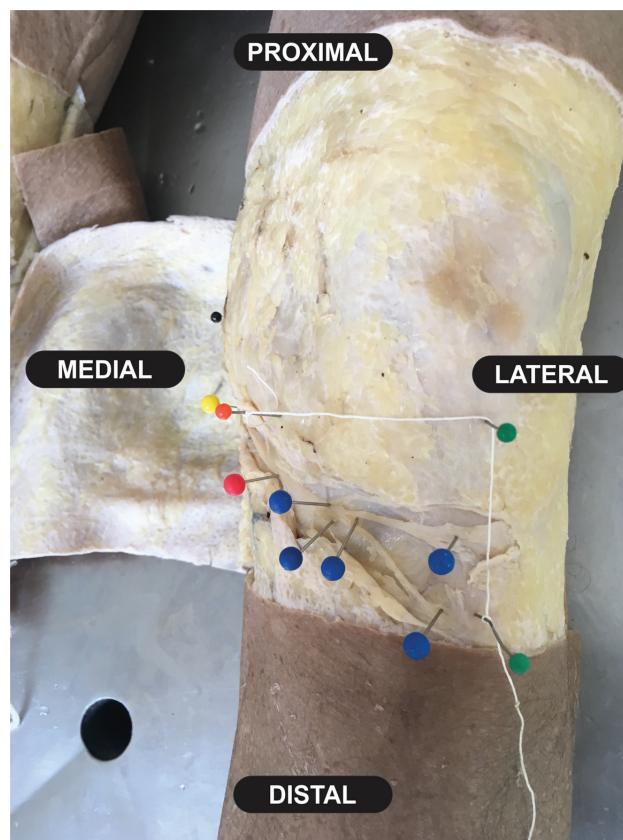
**Fig. 2** Skin incisions with lateral to medial cutaneous folding, in which the infrapatellar branch of the saphenous nerve and its direct and indirect branches were dissected.



**Fig. 3** Reference lines: articular Line (LA); tibial tubercle line (TTL), and longitudinal line (LL) used to establish the quadrant (area) of the study. 1: Study area.



**Fig. 4** Reference points for the tibial plateau and tibial tuberosity, respectively superior and inferior, marked with colored pins.



**Fig. 5** Distribution of the distance between the emerging point and the AL and LL showing great variation.

Measurement 3: distance between the secondary branches, called “a,” “b” and “c” according to their appearance, and the AL and LL;

Measurement 4: distance between the tertiary branches, called “a,” “b” and “c” according to their appearance, and AL and LL.

The data obtained from each knee were organized in tables with their proper identifications (gender, side and whether it belonged to the same individual, isolated limb or amputated limb) and measurements according to the criteria adopted and described (► **Figure 5**).

## Results

In 17 (94.4%) of the 18 knees studied, a single infrapatellar branch was observed. A proximal subdivision of the infrapatellar branch was observed in a single knee.

The infrapatellar branch emerged from the proximal fibers of the sartorius muscle belly in 17 (94.4%) of the 18 knees, but, in 1 knee, its complete identification was not possible at the described site of origin.

► **Table 1** shows the distribution of the distance between the emerging point in relation to the AL; these measures showed great variation. In 9 knees, in a total of 10 infrapatellar branches, measurement 1 occurred outside the quadrant proposed in the study: the longest distance was of 200.14 mm, and the shortest, of 2.81 mm, with a mean of

83.14 mm. In 8 knees, the infrapatellar branch originated within the proposed quadrant, and the distal distance from the AL was of 44.85 mm, and the proximal distance was of 5.64 mm, with a mean of 37.80 mm. Among the seven individuals in which we observed both knees, four presented the emerging point of the infrapatellar branch outside and within the proposed quadrant; in two individuals, the emerging point was outside the quadrant on both knees; and, in only one individual, the emerging point of the infrapatellar branch, in both knees, was within the quadrant.

► **Table 2** shows the measurements of the distances between the primary, secondary and tertiary branching points from the interior of the established quadrant to the AL and LL.

Regarding the branching, we observed that in 100% of the knees the infrapatellar branch presented at least one primary branch, resulting in a superior and an inferior branch. In 9 limbs (50% of cases), this branching occurred outside the proposed quadrant, and the remainder, within the quadrant; in the knee with two infrapatellar branches, the primary ramifications of both branches occurred within the quadrant.

The longest distance between the primary branch of the 10 infrapatellar branches dividing within the quadrant to the AL was of 64.23 mm, and the shortest was of 2.9 mm, with a mean of 26.51 mm. In relation to the LL, the longest distance was of 86.07 mm, and the shortest was of 59.61 mm, with a mean of 73.53 mm (► **Table 2**).

In ► **Table 2**, we can observe that, in 11 (61.1%) knees, the secondary ramifications occurred within the quadrant,

**Table 1** Distance in millimeters from the emerging point of the saphenous nerve branch in relation to the determined quadrants

Individuals	Distance (mm) – emerging point in relation to the articular line	
	Outside the quadrant	Inside the quadrant
Individual 1 - R Knee Male	61.86	–
Individual 1 - L Knee Male	112.15	–
Individual 2 - R Knee Male	182.03	–
Individual 2 - L Knee Male	–	11.42
Individual 3 - R Knee Male	–	5.84
Individual 3 - L Knee Male	–	44.85
Individual 4 - R Knee Male	–	26.78
Individual 4 - L Knee Male	30.5	–
Individual 5 - R Knee Male	–	5.64
Individual 6 - L Knee Male	–	29.2
Individual 7 - L Knee Male N	20.50N/ 15.90N*	–
Individual 8 - R Knee Fem	134.88	–
Individual 8 - L Knee Fem	200.14	–
Individual 9 - R Knee Fem	–	13.74
Individual 9 - L Knee Fem	70.66	–
Individual 10 - R Knee Fem	–	13.74
Individual 10 - R Knee Fem	2.81	–
Individual 11 - R Knee Fem	–	–

Abbreviations: Fem, female; L, left; N, N\*, proximal subdivisions of the infrapatellar branch observed in a single knee; R, right.

and in 8 (72.7%) cases, this branch originated from a primary branching within the quadrant, and in 3 (27.3%) cases, the branching occurred outside the quadrant studied. Out of these 11 knees, 6 (54.5%) had 2 secondary branches that were named “a” and “b,” resulting in 4 branches; 3 (27.3%) had a single branching, originating 2 branches; in 1 (9.1%) knee, there were 3 secondary branches, called “a,” “b” and “c,” resulting in 6 secondary branches; and in 1 (9.1%) knee there were 5 branches, called “a,” “b,” “c,” “d,” “e,” resulting in 10 secondary branches.

In relation to the AL, the most distal secondary branch was at a distance of 65.65 mm, and the most proximal secondary branch was at a distance of 2.34 mm, with a mean value of 31.87 mm. Regarding the LL, the most medial distance was of 86.54 mm, and the most lateral distance was of 17.57 mm, with a mean of 48.40 mm.

In ► **Table 2**, it can also be noted that in 7 (38.9%) of the 18 knees studied there were tertiary ramifications of the infrapatellar branch; in 5 (71.4%) lower limbs, these branches came from secondary branching present in the quadrant; and, in 2 (28.6%) cases, they came from secondary branches located outside the quadrant. Regarding the number of tertiary branches, it can be observed that in 3 (42.8%) of the 7 knees there were two branches; in 2 (28.6%) knees,

there were three branches; in 1 (14.3%) knee, there were 4 branches; and, in 1 (14.3%) knee, there was only 1 branch.

The farthest point of origin of the tertiary branches from the AL was at 73,62 mm, and the closest, at 0,92 mm, with a mean value of 46,33 mm. Regarding the LL, the most medial point was at 51.57 mm, and the most lateral point was at 12.30 mm, with a mean of 32.98 mm.

In 3 (16.7%) of the 18 studied knees, we could observe that they had the primary, secondary and tertiary branches within the proposed quadrant.

We also observed that, in the 9 cases in which the primary branching occurred outside the quadrant, on 7 (77.8%), it occurred above the AL, and in 2 (22.2%), it occurred below the TTL.

Regarding the 18 knees, we observed that in 5 (27.8%) cases, the secondary branches crossed the LL and, in 2 (11.1%) cases, it was the tertiary branches that exceed it, innervating the lateral knee region; in 2 (11.1%) cases, tertiary branches crossed the LT to spread below the tibial tuberosity and, in 9 (50.0%) of the cases studied, the secondary and tertiary branches crossed both the LL and TTL.

Regarding the proposed quadrant, the infrapatellar branch was not restricted to the limits proposed in any knee evaluated. However, beyond its limits, the infrapatellar branch reached the region below the TTL in 11 (61.1%) knees, the region above the AL in 9 (50%) cases, and it extended from above AL to below the LT in 6 (33.3%) knees.

## Discussion

The importance of the study of the infrapatellar branch of the saphenous nerve is well established in the literature, and its injury can cause mild paresthesia, anesthesia, neuroma formation, and reflex sympathetic dystrophy.<sup>8,9</sup>

In the present study, the infrapatellar branch was observed in all dissected knees, and in only one knee the presence of two infrapatellar branches was found, which is in accordance with the literature, which is clear about the presence of the infrapatellar branch of the saphenous nerve.<sup>10-12</sup> For some authors,<sup>3,11</sup> the infrapatellar branch originated two trunks, one superior and one inferior, as in our study, in which we found the presence of two branches originating from the infrapatellar branch in 100% of the cases.

The results of the present research also show that, according to the literature, the anatomical variation of the infrapatellar branch of the saphenous nerve is high.<sup>3,13,14</sup> Other studies<sup>15,16</sup> identified on average three to four different types of infrapatellar branching in relation to the sartorius muscle: anterior, posterior, penetrating and *pes anserinus*. In our findings, we observed that in 17 (94.4%) cases, the infrapatellar branch was penetrating, that is, it emerged between the muscle fibers of the sartorius muscle belly.

Kalthur et al.,<sup>16</sup> in their study, showed that branching distribution was observed: between the patella apex and the tibial tuberosity in 17 of the 32 knees evaluated; at the level of the tibial tuberosity in 5 knees; at the level of the patella 1 one case; and the remaining cases had a variable distribution. In

**Table 2** Distance in millimeters (mm) of the main branching in relation to the articular line (AL) and the longitudinal line (LL)

Individuals	Distance (mm) primary branching - LA/LL		Distance (mm) secondary branching - LA/LL		Distance (mm) tertiary branching - LA/LL	
	LA	LL	LA	LL	LA	LL
Individual 1 - R Knee Male	A: 15.90	A: 71.50	A: 11.94	A: 35.36		
			B: 31.58	B: 38.65		
Individual 1 - L Knee Male	A: 2.90	A: 60.50	A: 27.85	A: 58.87		
			B: 28.12	B: 42.88		
Individual 2 - R Knee Male			A: 2.34	A: 60.55	A: 24.54	A: 39.57
					B: 49.90	B: 38.97
					C: 53.08	C: 37.07
Individual 2 - L Knee Male	A: 17.24	A: 85.49	A: 45.81	A: 58.89	A: 68.98	A: 33.60
			B: 45.61	B: 54.46		
			C: 50.95	C: 49.31		
Individual 3 - R Knee Male	A: 24.17	A: 81.15	A: 42.24	A: 74.94		
Individual 3 - L Knee Male						
Individual 4 - R Knee Male						
Individual 4 - L Knee Male					A: 23.81	A: 45.05
					B: 30.28	B: 45.21
Individual 5 - R Knee Male	A: 20.9	A: 86.1	A: 22.89	A: 38.80		
			B: 22.60	B: 27.91		
Individual 6 - L Knee Male	A: 64.23	A: 76.06				
Individual 7 - L Knee Male N	A: 23.92 N/A: 26.46N*	A: 63.84N/A: 76.06N*	A: 43.18	A: 28.91	A: 47.21	A: 13.00
					B: 52.01	B: 12.30
Individual 8 - R Knee Fem	A: 28.82	A: 59.61	A: 31.52	A: 58.57	A: 54.93	A: 39.65
			B: 39.03	B: 63.14	B: 54.97	B: 36.65
					C: 60.23	C: 31.49
Individual 8 - L Knee Fem			A: 8.88	A: 86.54	A: 57.75	A: 51.57
			B: 41.12	B: 63.69	B: 73.62	B: 37.39
					C: 68.08	C: 22.24
Individual 9 - R Knee Fem						
Individual 9 - L Knee Fem			A: 16.20	A: 57.68		
			B: 21.94	B: 38.17		
			C: 23.08	C: 19.69		
Individual 10 - R Knee Fem						
Individual 10 - L Knee Fem	A: 40.64	A: 75.06	A: 49.56	A: 75.23		
			B: 65.65	B: 42.51		
Individual 11 - R Knee Fem					A: 0.92	A: 22.22
					B: 12.82	B: 25.71

Abbreviations: A, B, C, number of secondary branches found during dissection; Fem, female; L, left; N, N\*, proximal subdivisions of the infrapatellar branch observed in a single knee; R, right.

our study, we found a total of 114 direct and/or indirect branches present within the proposed quadrant. Of the 18 knees studied, no branching at the level of the patella was observed, nor there was a branch strictly above AL. In two cases, branch distribution occurred below the TTL. In the other

cases, it was below the AL, with variable distribution, but following a distal-lateral course.

In the present research, the longest distance between the primary branch of the 10 infrapatellar branches that divided within the quadrant proposed to the AL was of 64.23 mm,

and the smallest was of 2.9 mm, with a mean of 26.51 mm. In relation to the LL, the longest distance was of 86.07 mm, and the shortest was of 59.61 mm, with a mean of 73.53 mm. No pattern of innervation restricted to gender or limbs of the same individual was observed, which reinforces the difficulty of finding an ideal incision in knee surgical procedures. Despite the wide variation, the main branches were all located in the medial region of the knee, at the level of the tibial plateau, close to the medial AL, with horizontal branching toward the patellar tendon, near the LL. Therefore, we can establish an anteromedial area of greater risk for surgical incisions in the knee. The literature points out that skin incisions in the anteromedial region provide excellent surgical exposure and minimize the length of the incision. However, they are also associated, in 55% to 100% of the cases, with persistence of an area of hypoesthesia on the anterior face of the knee.<sup>17-21</sup>

Other studies<sup>3,6,10,11</sup> have also delimited areas of higher and/or lower risk for surgical incisions in relation to the infrapatellar branch of the saphenous nerve around the knee. Kerver et al.<sup>3</sup> established three distinct zones, considered of low morbidity, with lower density of infrapatellar branches of the saphenous nerve, theoretically safe and with lower morbidity for surgical incisions. The first zone would be located on the medial side of the knee, at the level of the anterior tibial tuberosity, where an oblique incision is less likely to damage the infrapatellar branch, and the other two zones are located medially to the apex of the patella, and in both of them, more horizontal incisions are less likely to damage the infrapatellar branch.

## Conclusion

Thus, we can conclude that the infrapatellar branch of the saphenous nerve was found in all dissected knees, and in most cases it was of the penetrating type, originating two primary straight branches; one superior and other inferior, on all dissected knees. The infrapatellar branch of the saphenous nerve showed great variability in its path and its direct and indirect branching, innervating the region between the AL and the anterior tibial tuberosity through its branches. Thus, there are few subsidies for the standardization of its behavior. As a result, the infrapatellar branch of the saphenous nerve is at risk of damage in any surgical procedure on the anteromedial aspect of the knee.

### Conflict of Interests

The authors have no conflict of interests to declare.

## References

- Tennent TD, Birch NC, Holmes MJ, Birch R, Goddard NJ. Knee pain and the infrapatellar branch of the saphenous nerve. *J R Soc Med* 1998;91(11):573-575
- Lippitt AB. Neuropathy of the saphenous nerve as a cause of knee pain. *Bull Hosp Jt Dis* 1993;52(02):31-33
- Kerver AL, Leliveld MS, den Hartog D, Verhofstad MH, Kleinrensink CJ. The surgical anatomy of the infrapatellar branch of the saphenous nerve in relation to incisions for anteromedial knee surgery. *J Bone Joint Surg Am* 2013;95(23):2119-2125
- Katz MM, Hungerford DS. Reflex sympathetic dystrophy affecting the knee. *J Bone Joint Surg Br* 1987;69(05):797-803
- Sundaram RO, Ramakrishnan M, Harvey RA, Parkinson RW. Comparison of scars and resulting hypoesthesia between the medial parapatellar and midline skin incisions in total knee arthroplasty. *Knee* 2007;14(05):375-378
- Mochida H, Kikuchi S. Injury to infrapatellar branch of saphenous nerve in arthroscopic knee surgery. *Clin Orthop Relat Res* 1995; (320):88-94
- Papastergiou SG, Voulgaropoulos H, Mikalef P, Ziogas E, Pappis G, Giannakopoulos I. Injuries to the infrapatellar branch(es) of the saphenous nerve in anterior cruciate ligament reconstruction with four-strand hamstring tendon autograft: vertical versus horizontal incision for harvest. *Knee Surg Sports Traumatol Arthrosc* 2006;14(08):789-793
- Poehling GG, Pollock FE Jr, Komar LA. Reflex sympathetic dystrophy of the knee after sensory nerve injury. *Arthroscopy* 1988;4(01): 31-35
- Katsoulis E, Court-Brown C, Giannoudis PV. Incidence and aetiology of anterior knee pain after intramedullary nailing of the femur and tibia. *J Bone Joint Surg Br* 2006;88(05):576-580
- Ebraheim NA, Mekhail AO. The infrapatellar branch of the saphenous nerve: an anatomic study. *J Orthop Trauma* 1997;11(03): 195-199
- Tifford CD, Spero L, Luke T, Plancher KD. The relationship of the infrapatellar branches of the saphenous nerve to arthroscopy portals and incisions for anterior cruciate ligament surgery. An anatomic study. *Am J Sports Med* 2000;28(04):562-567
- Gali JC, Resina AF, Pedro G, et al. Importância da localização anatômica do ramo infrapatelar do nervo safeno na reconstrução do ligamento cruzado anterior com tendões flexores. *Rev Bras Ortop* 2014;49(06):625-629
- Kartus J, Ejerhed L, Eriksson BI, Karlsson J. The localization of the infrapatellar nerves in the anterior knee region with special emphasis on central third patellar tendon harvest: a dissection study on cadaver and amputated specimens. *Arthroscopy* 1999;15(06):577-586
- Horner G, Dellon AL. Innervation of the human knee joint and implications for surgery. *Clin Orthop Relat Res* 1994;(301):221-226
- Ackmann T, Von Düring M, Teske W, Ackermann O, Muller P, Von Schulze Pellengahr C. Anatomy of the infrapatellar branch in relation to skin incisions and as the basis to treat neuropathic pain by cryodestruction. *Pain Physician* 2014;17(03):E339-E348
- Kalthur SG, Sumalatha S, Nair N, Pandey AK, Sequeria S, Shobha L. Anatomic study of infrapatellar branch of saphenous nerve in male cadavers. *Ir J Med Sci* 2015;184(01):201-206
- Laffosse JM, Potapov A, Malo M, Lavigne M, Vendittoli PA. Hypoesthesia after anterolateral versus midline skin incision in TKA: a randomized study. *Clin Orthop Relat Res* 2011;469(11):3154-3163
- Borley NR, Edwards D, Villar RN. Lateral skin flap numbness after total knee arthroplasty. *J Arthroplasty* 1995;10(01):13-14
- Hopton BP, Tommichan MC, Howell FR. Reducing lateral skin flap numbness after total knee arthroplasty. *Knee* 2004;11(04): 289-291
- Spicer DD, Blagg SE, Unwin AJ, Allum RL. Anterior knee symptoms after four-strand hamstring tendon anterior cruciate ligament reconstruction. *Knee Surg Sports Traumatol Arthrosc* 2000;8(05): 286-289
- Quayle JB, Robinson MP. An operation for chronic prepatellar bursitis. *J Bone Joint Surg Br* 1976;58-B(04):504-506