


Subspine Hip Impingement: Clinical and Radiographic Results of its Arthroscopic Treatment*

Impacto subespinal do quadril: Resultados clínicos e radiográficos do tratamento artroscópico

Bruno Dutra Roos¹  Milton Valdomiro Roos¹ Antero Camisa Júnior¹
Ezequiel Moreno Ungaretti Lima¹ Mariano Feraboli Fontana¹ Roger Pires Okamoto¹

¹Hip Surgery Service, Hospital Ortopédico de Passo Fundo, Passo Fundo, RS, Brazil

Rev Bras Ortop 2020;55(6):722–727.

Address for correspondence Bruno Dutra Roos, MD, Hip Surgery Service, Hospital Ortopédico de Passo Fundo, Rua Sete de Setembro, 817, Passo Fundo, RS, 99010-121, Brazil (e-mail: brunodroos@gmail.com).

Abstract

Objective To evaluate the clinical and radiographic results as well as complications related to patients undergoing arthroscopic treatment of subspine hip impingement.

Methods We retrospectively evaluated 25 patients (28 hips) who underwent arthroscopic treatment of subspine impingement between January 2012 and June 2018. The mean follow-up was 29.5 months, and the patients were evaluated clinically by using the Harris hip score modified by Byrd (MHHS), the non-arthritic hip score (NAHS), and in terms of internal rotation and hip flexion. In addition, the following items were evaluated by imaging exams: the center-edge (CE) acetabular angle, the Alpha angle, the presence of a sign of the posterior wall, the degree of arthrosis, the presence of heterotopic hip ossification, and the Hetsroni classification for subspine impingement.

Results There was an average postoperative increase of 26.9 points for the MHHS, 25.4 for the NAHS ($p < 0.0001$), 10.5° in internal rotation ($p < 0.0024$), and 7.9° for hip flexion ($p < 0.0001$). As for the radiographic evaluation, an average reduction of 3.3° in the CE angle and of 31.6° for the Alpha angle ($p < 0.0001$). Eighteen cases (64.3%) were classified as grade 0 osteoarthritis of Tönnis, and 10 (35.7%) were classified as Tönnis grade 1. Two cases (7.1%) presented grade 1 ossification of Brooker. Most hips ($n = 15$, 53.6%) were classified as type II of Hetsroni et al.

Conclusion In the present study, patients undergoing arthroscopic treatment with subspine impingement showed improvement in clinical aspects and radiographic patterns measured postoperatively, with an average follow-up of 29.5 months.

Keywords

- ▶ femoroacetabular impingement
- ▶ hip joint
- ▶ arthroscopy

Introduction

Femoroacetabular impingement (FAI) results from changes in contact between the head and femoral neck with the acetabular border.^{1,2} These pathological mechanical changes

* Work developed at the Department of Orthopedics and Traumatology of Hospital Ortopédico de Passo Fundo, Passo Fundo, RS, Brazil.

Resumo

Objetivo Avaliar os resultados clínicos e radiográficos assim como as complicações relacionadas a pacientes submetidos ao tratamento artroscópico do impacto subespinal do quadril.

Métodos Foram avaliados retrospectivamente 25 pacientes (28 quadris) submetidos ao tratamento artroscópico de impacto subespinal entre janeiro de 2012 e junho de 2018. O seguimento médio foi de 29,5 meses, e os pacientes foram avaliados clinicamente pelo *Harris hip score* modificado por Byrd (MHHS), o *non-arthritic hip score* (NAHS), e quanto à rotação interna e flexão do quadril. Além disso, foram avaliados por exames de imagem: o ângulo *center-edge* (CE) acetabular, o ângulo alfa, a presença de sinal da parede posterior, o grau de artrose, a presença de ossificação heterotópica do quadril e a classificação de Hetsroni para Impacto Subespinal.

Resultados Observou-se aumento médio pós-operatório de 26,9 pontos para o MHHS, 25,4 para o NAHS ($p < 0,0001$), $10,5^\circ$ na rotação interna ($p < 0,0024$) e $7,9^\circ$ para flexão do quadril ($p < 0,0001$). Quanto à avaliação radiográfica, observou-se redução média de $3,3^\circ$ no ângulo CE e de $31,6^\circ$ para o ângulo alfa ($p < 0,0001$). Foram classificados 18 casos (64,3%) como artrose grau 0 de Tönnis e 10 (35,7%) como Tönnis 1. Dois casos (7,1%) apresentaram ossificação grau 1 de Brooker. A maioria dos quadris ($n = 15$; 53,6%) foi classificada como tipo II de Hetsroni et al.

Conclusão No presente estudo, os pacientes submetidos a tratamento artroscópico de impacto subespinal apresentaram melhora nos aspectos clínicos e nos padrões radiográficos aferidos pós-operatoriamente, com seguimento médio de 29,5 meses.

Palavras-chave

- ▶ impacto femoroacetabular
- ▶ articulação do quadril
- ▶ artroscopia

in the hip can damage the chondrolabral junction and potentially cause early osteoarthritic changes in the hip.³

Both arthroscopic treatment and open surgical approaches (through controlled hip dislocation or anterior approach) are widely described in the literature for the treatment of labral injury and restoration of the contour of the neck-head junction, and they result in improved clinical outcomes in patients with symptomatic FAI.⁴ Despite the wide application and success of these techniques for the surgical treatment of FAI, a subset of patients does not show significant improvement, suggesting that unrecognized sources of impingement may exist. The extra-articular FAI results from abnormal contact between the extra-articular regions of the proximal femur (major trochanter, minor trochanter, and extracapsular portion of the femoral neck) with the ilium or the ischium.^{4,5}

Recent studies^{6,7} demonstrate that the prominence of the anterior inferior iliac spine (AIIS) could contribute as a cause of FAI. In such cases, terminal flexion of the hip would result in an impact with the caudal region of the AIIS prominence against the femoral neck. Decreased pain and general improvement in hip function have been reported after resection of AIIS prominence.⁸

The aim of the present study was to evaluate the clinical and radiographic results as well as the complications related to patients undergoing arthroscopic treatment of subspine impingement (SSI).

Materials and Methods

Patients undergoing arthroscopic FAI treatment, operated between January 2012 and October 2018, were included.

During this period, 275 patients underwent this treatment, all of which were performed by the same surgeon (BDR). The exclusion criteria for the study were patients with FAI without the presence of subspine impingement (240 cases), loss of patient to follow-up, and/or lack of tests for radiographic measurements (10 cases).

All patients were called and reassessed. The authors of the present study signed an agreement to use the data. It should also be noted that the research project was approved by the research ethics committee under the number CAAE 089656 19.0.0000.5342.

According to the established criteria, 25 patients met all necessary requirements. Of these, 18 (72%) were male, and the mean age was 32.1 years (standard deviation [SD] = 7.2, range from 19–44 years). The right hip was operated on in 17 cases (60.7%), the left hip in 11 cases (39.3%), and 3 cases were treated bilaterally and simultaneously, totaling 28 hips evaluated. The median follow-up was 29.5 months (range from 6–82 months).

As for the clinical aspects, the patients were evaluated pre- and postoperatively according to the Harris hip score modified by Byrd⁹ (MHHS), non-arthritic hip score¹⁰ (NAHS), the degree of internal rotation (IR) and flexion of the affected hip (using a goniometer for measurement). All patients underwent a test to assess positive subspine impingement, which consists of pain in passive flexion of the hip in neutral rotation.¹¹ According to the MHHS, the results were stratified as poor (MHHS < 70 points), reasonable (MHHS 70–79 points), good (MHHS 80–89 points), and excellent (MHHS 90–100).

All patients were assessed by means of anteroposterior (AP) pelvic radiographs, Dunn 45°,¹¹ and Lequesne false profile,¹² Computed tomography with 3D Reconstruction (3D CT) and

nuclear magnetic resonance (NMR). Preoperative radiographs measured the center-edge angle (θ CE), the alpha angle ($\theta\alpha$) as described by Meyer in the incidence 45° ,¹¹ the presence of the sign of the crossing of the acetabular lines,¹³ the presence of the sign of the posterior wall, and the classification of Tönnis¹⁴ for coxarthrosis. In patients with the presence of sign of the crossing of acetabular lines, the degree of acetabular retroversion was measured, being classified as mild when it occurred in the upper third of the acetabulum, moderate in the middle third, and severe in the lower third.¹⁵ In the postoperative radiographs the θ CE, the $\theta\alpha$, and the presence of heterotopic ossification according to the classification proposed by Brooker et al. were measured.¹⁶

The subspine impingement was classified preoperatively from 3D CT studies based on AIIS morphology as described by Hetsroni et al.¹⁷ in type I, the distal AIIS extension is located proximal to the acetabular border; in type II, the bony prominence of the ilium extends to the acetabular ridge; in type III, the AIIS extends distally to the acetabular ridge.

The cam-type FAI was defined as $\theta\alpha > 50^\circ$.¹⁸ The pincer-type FAI was defined in the presence of θ CE greater than or equal to 40° on pelvic AP radiographs and/or Lequesne false profile,¹² or in the presence of the sign of the crossing of the acetabular lines.¹³ The presence of an association of crossing signal and posterior wall signal indicated true acetabular retroversion. The isolated presence of the crossing sign indicated relative acetabular retroversion.¹⁵

To avoid inter and intraobserver errors, measurements were monitored by two surgeons from the Hip Group. In the event of disagreement of more than 3° in the angular measurements, a new evaluation was performed by a third surgeon, and, then, a consensus of the measurement was proceeded. A 15% mean magnification of the hip AP radiography was considered, which was quantified in the equipment of our department.

Quantitative variables of interest did not undergo the normality test. Thus, the statistical test used to analyze the pre and postoperative variables was the Wilcoxon test (non-parametric for dependent samples), with a significance level of 0.05.

Results

Of the 28 hips evaluated, 23 (82.1%) had a subspine impingement associated with cam-type and pincer impacts, 4 (14.3%) a subspine impingement associated with a cam impingement, and 1 (3.6%) hip had an isolated subspine impingement. Most

Table 1 Description of the types of arthroscopic treatments performed

Arthroscopic treatment	Number of cases
Resection of the anterior inferior iliac spine	28 cases
Femoral osteochondroplasty	27 cases
Acetabular osteochondroplasty	23 cases
Labral debridement	16 cases
Labral refixation	6 cases
Release of the iliopsoas tendon	3 cases

hips ($n = 15$, 53.6%) were classified as type II of Hetsroni et al.¹⁷ In addition to the resection of the AIIS, other treatments were performed arthroscopically, which are listed in **Table 1**.

Regarding the assessment of the MHHS clinical score,⁹ there was a preoperative mean of 62.3 points (SD = 6.2, range from 50–72 points), and a postoperative mean of 89.2 points (SD = 5.7, range from 77–100 points), with an average postoperative increase of 26.9 points. Regarding the NAHS clinical score,¹⁰ there was an average preoperative score of 65.7 points (SD = 8.7, range from 45–80 points), and a postoperative score of 91.1 points (SD = 5.8, range from 80–100 points), with a mean postoperative increase of 25.4 points. The hip IR measurement showed a preoperative mean of 8.9° (SD = 7.6° , range from 0° – 30°) and postoperative of 19.5° (SD = 5.7° , range from 10° – 30°), with mean postoperative increase of 10.5° . As for hip flexion, there was a preoperative mean of 111.1° (SD = 10.7° , range from 90° – 130°) and postoperative of 118.9° (SD = 6.3° , range from 100° – 130°), with mean postoperative increase of 7.9° . According to the established criteria based on the evaluation of the MHHS clinical score⁹ of the 28 hips treated, 16 (57.1%) had good clinical results and 12 (42.9%) excellent. There was a statistical difference ($p < 0.005$) in the pre and postoperative clinical measurements of the MHHS clinical scores⁹ and in the NAHS,¹⁰ in addition to the IR and hip flexion.

Regarding the preoperative radiographic evaluation, the mean for the θ CE was 34.7° (22° – 48°) and 72° (48° – 86°) for the $\theta\alpha$. The sign of crossing of the acetabular lines was found in 23 patients (82.1%), with all cases classified as mild retroversion. The sign of the posterior wall was seen in 15 patients (53.6%). In 15 cases (53.6%), true acetabular retroversion was found, and in 8, relative retroversion (28.6%). Eighteen cases (64.3%) were classified as grade 0 osteoarthritis of Tönnis, and 10 (35.7%) as Tönnis 1.

Concerning the θ CE, a mean reduction of 3.3° (22° – 39°) was observed postoperatively. In the $\theta\alpha$, there was a mean reduction of 31.6° (28° – 52°) (**Table 2**). In the late postoperative period, heterotopic ossification was not observed in 26

Table 2 Comparison of pre and postoperative measurements, clinical and radiographic measurements

Evaluation		P	
MHHS	Preoperative	62.3	$p < 0.0001$
	Postoperative	89.2	
NAHS	Preoperative	65.7	$p < 0.0001$
	Postoperative	91.1	
IR	Preoperative	8.9°	$p < 0.0001$
	Postoperative	19.5°	
Flex	Preoperative	111.1°	$p < 0.0024$
	Postoperative	118.9°	
$\theta\alpha$	Preoperative	72.0°	$p < 0.0001$
	Postoperative	40.3°	
θ CE	Preoperative	34.7°	$p < 0.0001$
	Postoperative	31.4°	

Abbreviations: MHHS, modified Harris hip score; NAHS, non-arthritic hip score; IR, internal hip rotation; $\theta\alpha$, alpha angle; θ CE, CE angle.

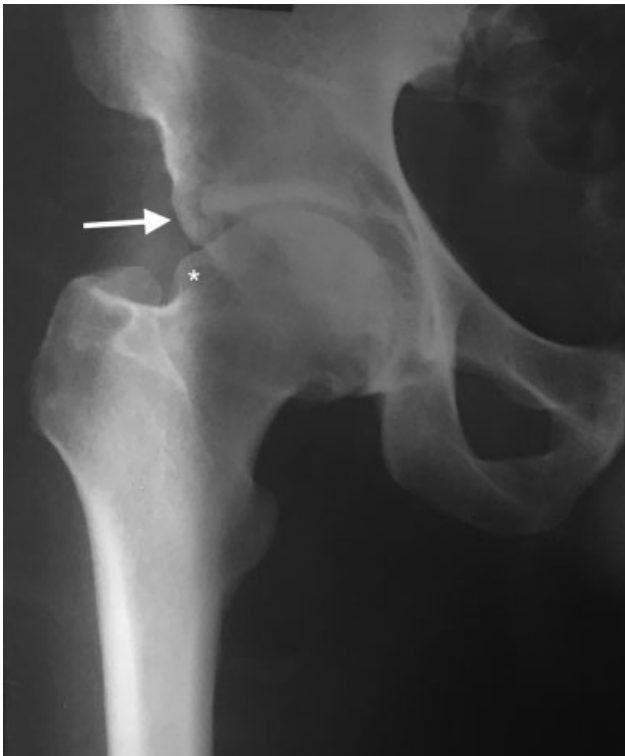


Fig. 1 Preoperative radiography in anteroposterior view of the hip joint, showing the presence of prominent anterior inferior iliac spine (white arrow) and deformity in the neck-head transition (asterisk). center-edge Angle: 36°.

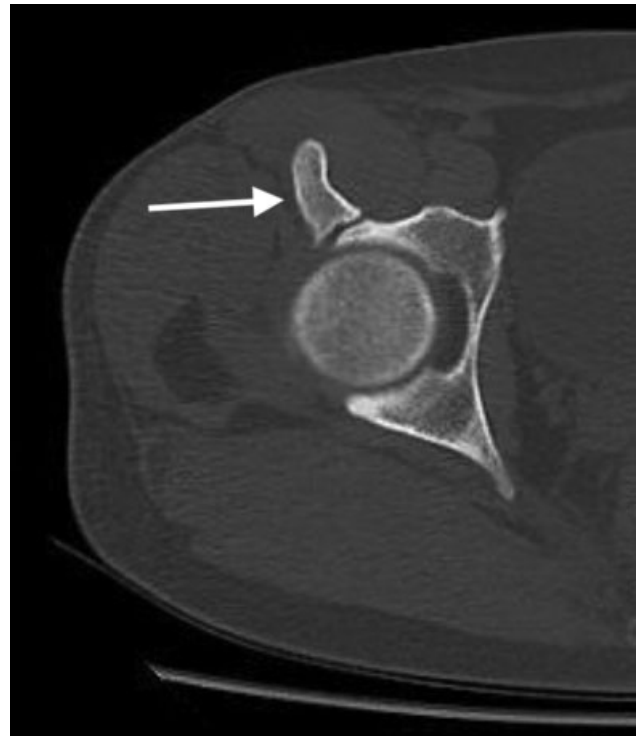


Fig. 3 Preoperative image of computed tomography in axial section, showing the presence of prominent anterior inferior iliac spine (white arrow).

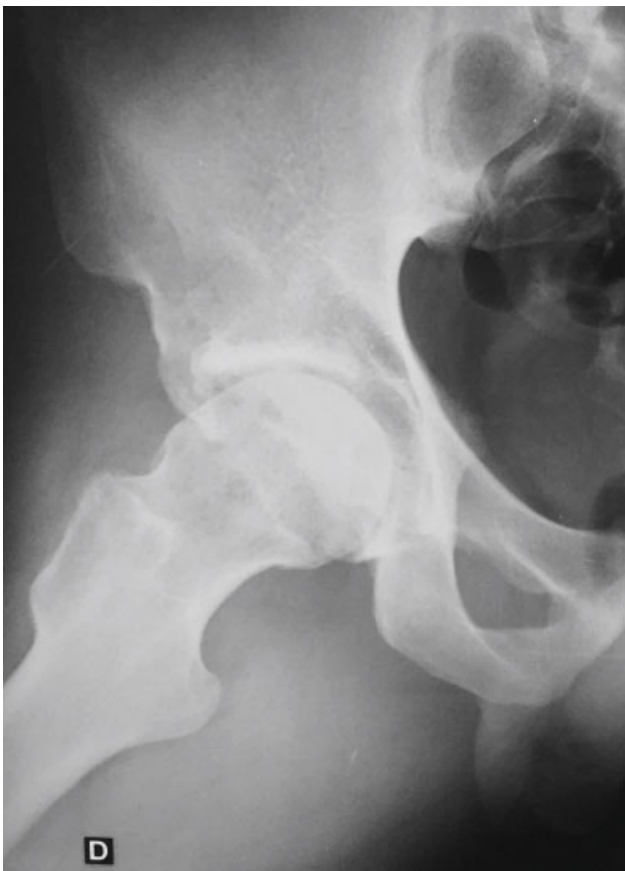

Fig. 2 Preoperative radiography in DUNN view 45° evidencing the presence of cam-type deformity. Alpha angle: 80°.

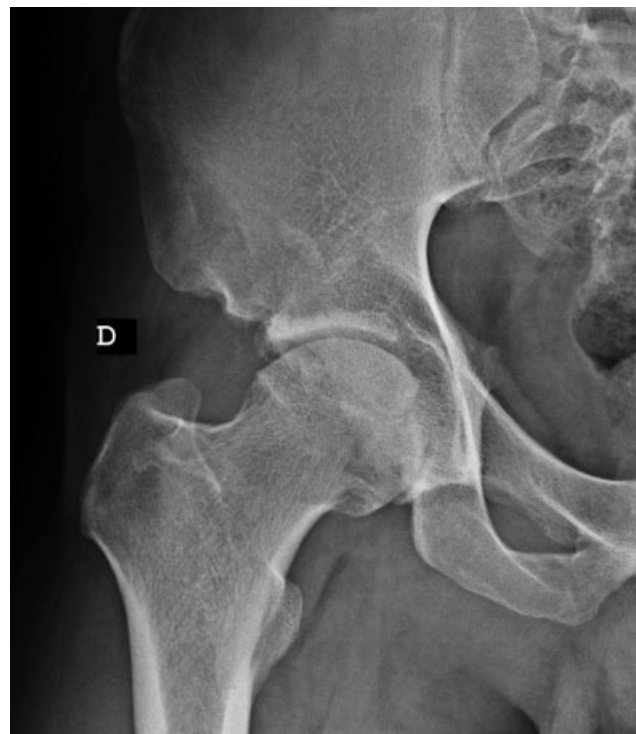

Fig. 4 Two-year postoperative radiograph in anteroposterior view of the hip joint, showing the correction of the subspine impingement and of the deformity of the neck-head transition.

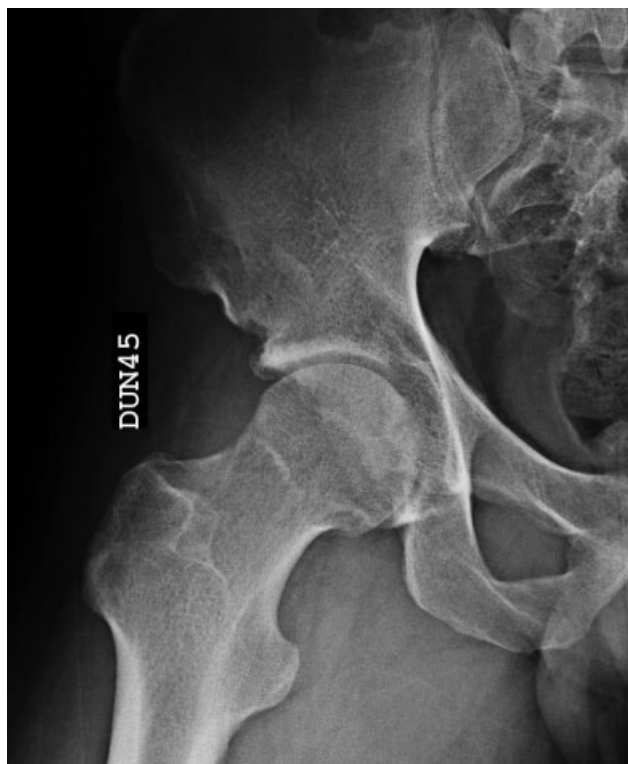

Fig. 5 Two-year postoperative radiograph in DUNN 45° view showing the correction of the cam-type deformity. Alpha angle: 38°.

cases (92.9%), and 2 cases (7.1%) presented Brooker grade 1 ossification.¹⁶ As complications, we verified a case (0.28%) with a small vaginal skin lesion resulting from traction, with complete improvement in 6 weeks. (► **Figures 1–5**).

Discussion

Surgical treatment of FAI is recognized in the literature as an effective treatment based on remodeling the proximal femur and acetabulum and treating chondral and labral lesions in order to reduce the impact of the femur against the acetabular ridge and, consequently, improve the range of motion of the hip.^{18,19} However, there is a subgroup of patients with unfavorable outcomes after surgery suggesting that unrecognized causes of impingement may coexist.²⁰ More recently, a study has been carried out with the purpose of identifying and understanding extra-articular causes of hip impingement.^{21–23}

Subspine impingement is caused by an AIIS prominence causing abnormal contact with the distal femoral neck during hip flexion.²¹ The literature shows that this condition is more common in active, young men (aged 14–30 years) and tends to have lower preoperative results for the MHHS.^{21,22} Patients often report pain in the anterior aspect of the hip or groin, aggravated by active hip flexion.

Due to the infrequency of the isolated form of SSI, few studies in the literature show results of its treatment. However, good results have been demonstrated in mixed series studies (SSI associated with intra-articular forms of FAI).^{7,24,25} Nwachukwu et al.²⁶ published the results of 33

patients with isolated SSI undergoing arthroscopic treatment, with an average follow-up of 19 months. All patients were female, and most hips had AIIS classified as type II. At the end of the follow-up, a mean increase of 22.3 points was found in the MHHS. Hetsroni et al.⁶ performed a retrospective review of 10 symptomatic patients undergoing arthroscopic treatment of SSI and reported significant improvement in range of motion of the hip and of the MHHS.

In our study, we obtained results that agree with those described in the literature. Postoperative clinical improvement was observed in these patients, with improved pain assessment scores, as well as increased hip range of motion (especially internal rotation). There was also an improvement in the radiographic patterns measured. It should be noted, based on radiographic analysis, that a significant portion of the patients (15 cases) presented signs of acetabular crossing (diagnosis of acetabular retroversion), showing changes in the orientation of acetabular walls with increased anterior acetabular coverage.

The limitations of the present study are the small number of patients, the short average follow-up time (29.5 months), and the absence of postoperative CT analysis to confirm the adequacy of AIIS resection.

Conclusion

In the present study, patients undergoing arthroscopic treatment of subspine impingement showed improvement in clinical aspects and in the radiographic patterns measured postoperatively.

Conflict of Interests

The authors declare that there is no conflict of interests.

References

- Ganz R, Gill TJ, Gautier E, Ganz K, Krügel N, Berlemann U. Surgical dislocation of the adult hip a technique with full access to the femoral head and acetabulum without the risk of avascular necrosis. *J Bone Joint Surg Br* 2001;83(08):1119–1124
- Ito K, Minka MA II, Leunig M, Werlen S, Ganz R. Femoroacetabular impingement and the cam-effect. A MRI-based quantitative anatomical study of the femoral head-neck offset. *J Bone Joint Surg Br* 2001;83(02):171–176
- Wagner S, Hofstetter W, Chiquet M, et al. Early osteoarthritic changes of human femoral head cartilage subsequent to femoroacetabular impingement. *Osteoarthritis Cartilage* 2003;11(07):508–518
- Espinosa N, Beck M, Rothenfluh DA, Ganz R, Leunig M. Treatment of femoro-acetabular impingement: preliminary results of labral refixation. Surgical technique. *J Bone Joint Surg Am* 2007;89 (Suppl 2 Pt.1):36–53
- Ali AM, Teh J, Whitwell D, Ostlere S. Ischiofemoral impingement: a retrospective analysis of cases in a specialist orthopaedic centre over a four-year period. *Hip Int* 2013;23(03):263–268
- Hetsroni I, Larson CM, Dela Torre K, Zbeda RM, Magennis E, Kelly BT. Anterior inferior iliac spine deformity as an extra-articular source for hip impingement: a series of 10 patients treated with arthroscopic decompression. *Arthroscopy* 2012;28(11):1644–1653
- Larson CM, Kelly BT, Stone RM. Making a case for anterior inferior iliac spine/subspine hip impingement: three representative case reports and proposed concept. *Arthroscopy* 2011;27(12):1732–1737

- 8 Pan H, Kawanabe K, Akiyama H, Goto K, Onishi E, Nakamura T. Operative treatment of hip impingement caused by hypertrophy of the anterior inferior iliac spine. *J Bone Joint Surg Br* 2008;90(05):677–679
- 9 Guimarães RP, Alves DPL, Azuaga TL, et al. Tradução e adaptação transcultural do Harris Hip Score modificado por Byrd. *Acta Ortop Bras* 2010;18(06):339–342
- 10 Del Castillo LN, Leporace G, Cardinot TM, Levy RA, Oliveira LP. Translation, cross-cultural adaptation and validation of the Brazilian version of the Nonarthritic Hip Score. *Sao Paulo Med J* 2013;131(04):244–251
- 11 Meyer DC, Beck M, Ellis T, Ganz R, Leunig M. Comparison of six radiographic projections to assess femoral head/neck asphericity. *Clin Orthop Relat Res* 2006;445(445):181–185
- 12 Clohisy JC, Carlisle JC, Beaulé PE, et al. A systematic approach to the plain radiographic evaluation of the young adult hip. *J Bone Joint Surg Am* 2008;90(Suppl 4):47–66
- 13 Li PL, Ganz R. Morphologic features of congenital acetabular dysplasia: one in six is retroverted. *Clin Orthop Relat Res* 2003;(416):245–253
- 14 Busse J, Gasteiger W, Tönnis D. [A new method for roentgenologic evaluation of the hip joint—the hip factor]. *Arch Orthop Unfallchir* 1972;72(01):1–9
- 15 Jamali AA, Mladenov K, Meyer DC, et al. Anteroposterior pelvic radiographs to assess acetabular retroversion: high validity of the “cross-over-sign”. *J Orthop Res* 2007;25(06):758–765
- 16 Brooker AF, Bowerman JW, Robinson RA, Riley LH Jr. Ectopic ossification following total hip replacement. Incidence and a method of classification. *J Bone Joint Surg Am* 1973;55(08):1629–1632
- 17 Hetsroni I, Poultsides L, Bedi A, Larson CM, Kelly BT. Anterior inferior iliac spine morphology correlates with hip range of motion: a classification system and dynamic model. *Clin Orthop Relat Res* 2013;471(08):2497–2503
- 18 Matsuda DK, Carlisle JC, Arthurs SC, Wierks CH, Philippon MJ. Comparative systematic review of the open dislocation, mini-open, and arthroscopic surgeries for femoroacetabular impingement. *Arthroscopy* 2011;27(02):252–269
- 19 Byrd JW, Jones KS. Arthroscopic management of femoroacetabular impingement: minimum 2-year follow-up. *Arthroscopy* 2011;27(10):1379–1388
- 20 Ricciardi BF, Fabricant PD, Fields KG, Poultsides L, Zaltz I, Sink EL. What are the demographic and radiographic characteristics of patients with symptomatic extraarticular femoroacetabular impingement? *Clin Orthop Relat Res* 2015;473(04):1299–1308
- 21 de Sa D, Alradwan H, Cargnelli S, et al. Extra-articular hip impingement: a systematic review examining operative treatment of psoas, subspine, ischiofemoral, and greater trochanteric/pelvic impingement. *Arthroscopy* 2014;30(08):1026–1041
- 22 Cvetanovich GL, Harris JD, Erickson BJ, Bach BR Jr, Bush-Joseph CA, Nho SJ. Revision hip arthroscopy: a systematic review of diagnoses, operative findings, and outcomes. *Arthroscopy* 2015;31(07):1382–1390
- 23 Sutter R, Pfirrmann CWA. Atypical hip impingement. *AJR Am J Roentgenol* 2013;201(03):W437–42
- 24 Hapa O, Bedi A, Gursan O, et al. Anatomic footprint of the direct head of the rectus femoris origin: cadaveric study and clinical series of hips after arthroscopic anterior inferior iliac spine/subspine decompression. *Arthroscopy* 2013;29(12):1932–1940
- 25 Matsuda DK, Calipusan CP. Adolescent femoroacetabular impingement from malunion of the anteroinferior iliac spine apophysis treated with arthroscopic spinoplasty. *Orthopedics* 2012;35(03):e460–e463
- 26 Nwachukwu BU, Chang B, Fields K, et al. Outcomes for Arthroscopic Treatment of Anterior Inferior Iliac Spine (Subspine) Hip Impingement. *Orthop J Sports Med* 2017;5(08):2325967117723109