


Diabetic Foot. Part 2: Charcot Neuroarthropathy*

Pé diabético. Parte 2: Neuroartropatia de Charcot

Ricardo Cardenuto Ferreira¹ 

¹Foot and Ankle Surgery Group, Department of Orthopedics and Traumatology of Santa Casa da Misericórdia de São Paulo, São Paulo, SP, Brazil.

Address for correspondence Ricardo Cardenuto Ferreira, MD, Rua Barata Ribeiro, 380, Cj 64, 6°. Andar, Bela Vista, São Paulo SP, 01308-000, Brazil (e-mail: ricardocardenuto@gmail.com).

Rev Bras Ortop 2020;55(4):397–403.

Abstract

Keywords

- ▶ diabetes
- ▶ foot
- ▶ arthropathy, neurogenic/ complications
- ▶ amputation

Charcot neuroarthropathy (CN) is an unfortunate and common complication of patients with diabetes, most likely resulting from a lack of proper understanding of the disease, which leads to late diagnosis. It is commonly misdiagnosed as infection and treated with antibiotics and a frustrated attempt of surgical drainage, which will reveal only debris of the osteoarticular destruction. Proper education of diabetic patients and of the health care professionals involved in their treatment is essential for the recognition of the initial signs of CN. The general orthopedic surgeon is usually the first to treat these patients in the early stages of the disease and must be aware of the signs of CN in order to establish an accurate diagnosis and ensure proper treatment. In theory, this would make it possible to decrease the morbidity of this condition, as long as proper treatment is instituted early.

Resumo

A neuropatia de Charcot (NC) é uma complicação lamentável e comum de pacientes com diabetes, provavelmente resultante de uma falta de entendimento adequado dessa condição, que leva ao diagnóstico tardio. A confusão diagnóstica com quadro infeccioso contribui para que o tratamento inicialmente indicado seja equivocado ao prescrever medicação antibiótica ou, eventualmente, drenagem cirúrgica. Não é infrequente que a drenagem inadvertida do suposto abscesso revele que na verdade seu conteúdo é formado apenas de partículas provenientes da destruição osteoarticular. A educação adequada, tanto dos pacientes diabéticos quanto dos médicos responsáveis por prestar atendimento primário a estes pacientes, é fundamental para a correta compreensão das principais características relacionadas ao desenvolvimento da NC. O ortopedista geral é quem, na maioria das vezes, recebe no pronto atendimento os pacientes que se encontram na fase aguda inicial da doença. Por esta razão, esses profissionais devem estar extremamente alertas e serem capazes de identificar os primeiros sinais que permitem diagnosticar precocemente a NC. Em tese, isto possibilitaria reduzir a morbidade desta afecção na medida em que o tratamento adequado venha a ser precocemente instituído.

Palavras-chave

- ▶ diabetes
- ▶ pé
- ▶ artropatia neurogênica/ complicações
- ▶ amputação

* Study developed at Foot and Ankle Surgery Group, Department of Orthopedics and Traumatology of Santa Casa de Misericórdia de São Paulo, SP, Brazil.



Introduction

Obesity and diabetes mellitus (DM) are part of the worldwide epidemic directly linked to physical inactivity and poor eating habits, whose incidence has been increasing in an unprecedented manner in history, affecting the world population globally. The International Diabetes Federation estimated that as of the 2nd decade of the 21st century, there would be 415 million diabetics worldwide, meaning that the number of patients would have doubled since the year 2000.¹ In the United States, data relative to the year of 2010 indicated that over 73,000 lower-limb amputations associated with diabetes were performed that year.² Statistical data for the year 2014 estimated that 9.3% of the US population was diabetic.² An even darker outlook is estimated for the year 2040, when it is believed that there will be 642 million diabetics in the world, which is to say that approximately 10% of the entire population of the planet will be diabetic.¹

It is necessary to consider DM as a malignant condition, in which multisystem involvement of various organs of the body is very frequent and whose result, in the medium and long term, involves substantial morbidity and mortality.³⁻⁵ Foot involvement in diabetic patients is associated with a chronic process, in which neuropathy accompanied by loss of protective sensitivity, peripheral arterial disease (PAD) and biomechanical changes caused by osteoarticular destruction and deformities resulting from Charcot neuroarthropathy (CN) constitute favorable conditions for the emergence of ulcers.^{4,5} In addition, the disease-associated chronic metabolic disorder is directly responsible for bone healing and bone consolidation deficits, besides compromising the immune system, increasing the risk of widespread infection due to the contamination of deep ulcers in the feet.^{4,5} Diabetic patients with foot impairment present a high incidence of premature death, but an even more frequent concern is the high risk of major amputation in at least one of the lower limbs throughout life.⁶

In addition to the high morbidity associated with foot problems in diabetic patients, there are other impacting socioeconomic complications. The high cost of hospitalizations for the treatment of foot ulcers is very concerning from the point of view of public health expenses.

The aim of this review is to highlight the pathophysiology, clinical evaluation, treatment, and prevention of major CN-related diabetes complications that contribute to the poor quality of life of the patients, reducing their ability to walk independently, and are directly or indirectly associated with the high risk of lower extremity amputation.

Etiopathogenesis of Diabetes Mellitus

Diabetes mellitus is a disease of the neurovascular system, and neuropathic changes are probably mediated by neuroischemia.⁷ Peripheral nerve neuropathy (PN) results in loss of sensitivity, of motor capacity (especially intrinsic foot muscles) and autonomic deficit. In addition, it is undoubtedly the main cause involved in diabetic foot ulcers (DFU) and, almost invariably, present in cases of CN.^{3,4,8} Approximately

75% of diabetic patients undergoing foot and ankle surgery already have some degree of PN.⁹

Charcot Neuroarthropathy

The typical patient who develops CN is in the 6th decade of life, has been diagnosed with DM for at least 10 years and is morbidly obese.¹⁰⁻¹² It is estimated that 0.2 to 0.3 per 1,000 diabetic patients develop CN.^{13,14} The destructive process triggered by CN has a profound and negative impact on health, with severe repercussions on the quality of life of the patient, particularly with regard to physical activity and lower-limb function.¹⁵⁻¹⁸ The diagnosis of CN reduces the life expectancy of diabetic patients by 14 years, and approximately 19% of patients die within 2 years, on average.¹⁹ Local foot trauma, whose magnitude and intensity may vary, appears to be involved in the beginning of the destructive process.^{4,5,20} Eventually, CN can be triggered by repetitive trauma that causes stress fractures in previously osteopenic bones (neurotrauma theory).²¹ In contrast, peripheral arterial vasodilation, due to paralysis of the smooth muscle of the blood vessel wall (autosympathectomy), is directly responsible for the reduction in blood flow velocity, and, apparently, it is involved in the increase in bone resorption rate, thus contributing to the installation of the destructive process of CN (neurovascular theory).²¹

Anatomical considerations are important in the diagnosis of CN, as shown by the Brodsky classification⁴ modified by Trepman et al.²² (→ **Table 1**). The vast majority of patients with CN present symptoms related to pain in the midfoot, as well as edema and erythema.^{20,21} However, as in the early acute phase of the disease no noticeable deformity is present yet, many patients are misdiagnosed as having cellulitis, gout, or tenosynovitis.²³ Due to misdiagnosis, many patients are mistakenly treated with antibiotics, corticosteroids or even with surgery indicated for "abscess drainage".²¹ In most cases, only when the acute condition subsides and the edema disappears, can the patient, and often the doctor himself, be able to detect the presence of residual deformities already installed in the sequela phase of the disease.^{20,21} As many of these deformities are of minor magnitude, it is possible to accommodate the feet in therapeutic shoes suitable for

Table 1 Evolutionary classification of Eichenholtz²⁶ for Charcot neuroarthropathy (CN)

Evolutionary Stage	Presentation
0: Patient at risk	Diabetic neuropathy and acute trauma Normal radiography
I: Fragmentation	Edema and erythema Radiograph: bone fragmentation
II: Coalescence	Decrease of phlogistic signals Radiography: coalescence of fragments
III: Consolidation	Absence of phlogistic signs Radiography: fracture remodeling

insensitive feet together with specially made insoles.^{20,21} Some patients, whose protective foot sensitivity is more seriously compromised due to peripheral neuropathy, continue to walk leaning on the foot affected by the destructive process of CN, and this further accelerates osteoarticular deformation.²⁰⁻²² Approximately 40% of patients with CN arrive at the first medical care already presenting plantar ulcer located under the bony prominence on the midfoot, especially when it is affected, and there is collapse of the lateral plantar arch.²⁴ The presence of an ulcer is a poor prognostic factor regarding the risk of extremity amputation, since it increases in six times the chance of this occurrence in diabetic patients with CN.²⁵

There are three distinct phases of CN defined and popularized by Eichenholtz:²⁶ 1) acute; 2) subacute or fragmentation with deformity development; and 3) chronic or consolidation with fixed deformities as sequelae (► **Table 2**). Clinical examination characterizes the acute phase of fragmentation as intense foot edema, increased local temperature and diffuse erythema. Simple radiographic examination is often normal, suggesting the inflammatory nature of this condition. In the acute phase of fragmentation, there may be diagnostic confusion mainly with infection, since both processes cause bone destruction.^{21,27} Differentiation can be made with observation based on clinical evaluation, taking into account that in cases of infection the diabetic patient's blood glucose is abnormally high, and even with the increase in insulin dose, it tends to remain elevated²⁸; in addition, the general condition of the patient with an infectious condition is marked by numbness.^{21,22} The same is not observed when it comes to CN. Another important indication relates to the fact that both edema and erythema, observed at clinical examination, in the presence of CN, undergo significant reduction when the affected extremity is elevated for approximately 5 minutes, which does not occur when those symptoms are caused by infection.²¹ One of the major diagnostic dilemmas between CN and infection occurs when there is severe osteoarticular destruction on radiographic examination, and clinical examination shows marked edema and erythema in the presence of ulcer located under bony prominence.^{21,25} Often, other imaging exams such as bone scintigraphy (BS), computed tomography (CT), and magnetic resonance imaging (MRI) are inconclusive in assisting in differential diagnosis in circumstances such as the one mentioned above.⁷

Table 2 Anatomical classification of Brodsky⁴ and Trepman²² for Charcot neuroarthropathy (CN)

Type	Joints involved
1	Tarsometatarsal and naviculocuneiform
2	Subtalar, talonavicular or calcaneocuboid
3A	Tibiotalar
3B	Previous calcaneal tuberosity fracture
4	Combination of affected areas (mixed)
5	Forefoot

Conservative Treatment of Charcot Neuroarthropathy

The primary goal of CN treatment is to obtain a stable, ulcer-free plantigrade foot. The classic treatment of CN consists of immobilization with total contact casting (TCC) during the acute phase of bone fragmentation, followed by the use of ankle-foot orthosis (AFO)-type molded polypropylene orthosis during the subacute phase of consolidation and, finally, accommodating the deformity with therapeutic footwear and custom-made insole adjusted to fit the residual deformities in the chronic sequelae phase.^{20,29-31} Surgery is usually an exception in the treatment of CN, and its main indication is related to the failure of conservative treatment when: 1) there is frankly unstable deformity affecting the ankle and hindfoot; 2) recurrent plantar ulcers persist due to bony prominences that cannot be adequately accommodated with custom-made insoles or orthoses; and 3) there is osteomyelitis infection from a contaminated ulcer. There is currently a trend, supported by some medical specialists, to recommend surgical treatment to correct deformities and stabilize the foot in order to allow the patient to be able to wear commercially available shoes without the need for accommodative orthoses.^{12,32-35} The supposed advantage advocated by those who endorse the indication of corrective surgery is the improvement in the ambulation ability and quality of life of the patient.³⁶ To consider surgery a viable alternative, many variables must be considered, among which the main are: 1) extremity perfusion; 2) bone quality; 3) glycemic control; 4) nutritional status; 5) presence of ulcer; 6) infection; and 7) osteoarticular stability.¹²

Surgical Treatment of Charcot Neuroarthropathy

The three modalities often used in the surgical treatment of CN are: 1) resection of plantar bony prominence located under chronic ulcer, a technique known as exostectomy; 2) modeling arthrodesis used to correct gross deformities and stabilize severely unstable joints; 3) combination of prominent infected bone resection with modeling arthrodesis.^{20,21} There is still controversy as to whether the latter surgical modality should be performed at a single surgical time, or at two separate moments, consisting of the first time in the debridement of the infected bone and the second time in the actual modeling arthrodesis.³⁴

The extent of arthrodesis basically depends on the degree of installed deformity, the location of the joints involved, and the required size of the planned wedges to allow the correction of the main deviations and to obtain a plantigrade foot.^{20,31-39} The choice of access route(s) depend(s) on the type of deformity installed (varus/valgus, adduction/abduction, pronation/supination); the degree of arc collapse; and the location of the plantar bone prominence(s). The ideal time to indicate surgery is still controversial, while the selection of the type of bone fixation basically depends on the presence or absence of ulcer at the time of surgery, as well as its degree of preexisting contamination.³⁰⁻⁴² Internal fixation is generally indicated in arthrodesis without the presence of previous bone contamination (preexisting chronic ulceration).^{19,30-33,35-38,40-42} The different devices most recently developed for internal fixation of the modeling arthrodesis in CN are: 1) plates with locking screws specially designed

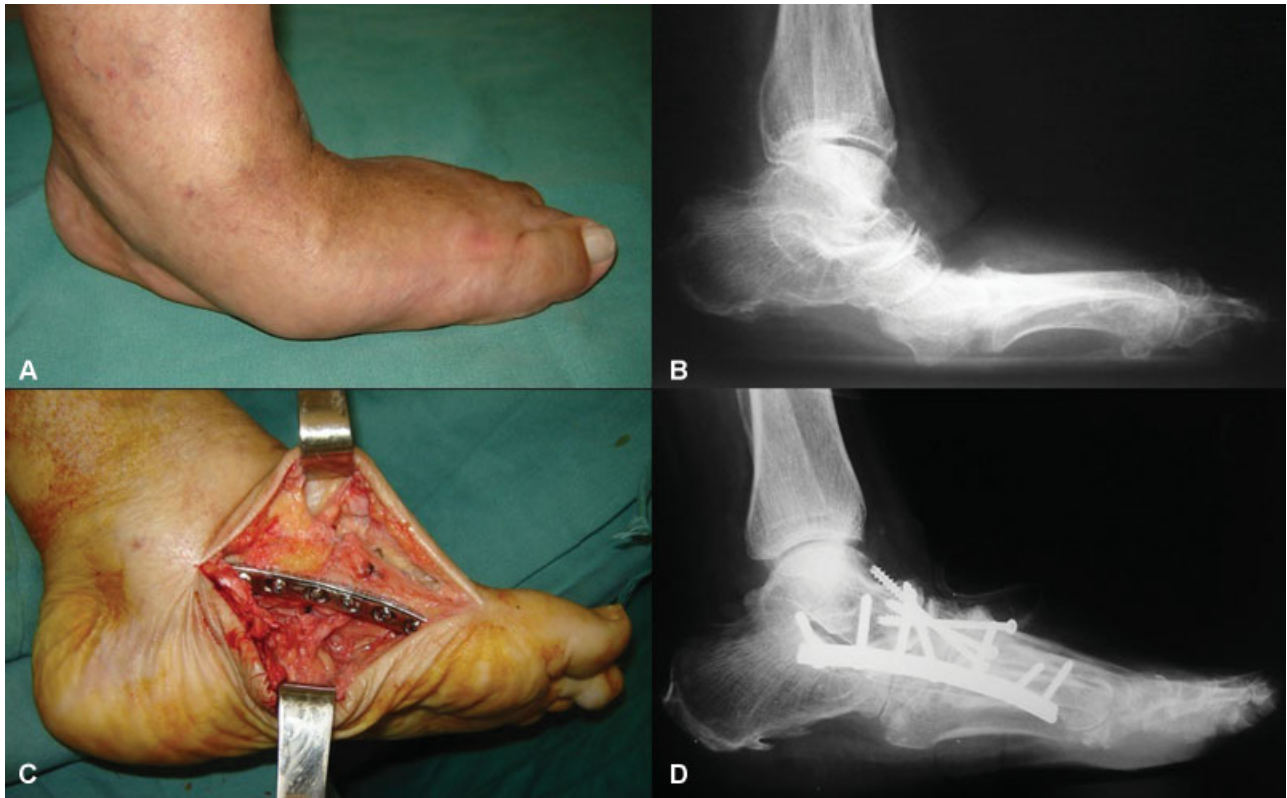

Fig. 1 Clinical aspect (A) and radiographic image of a patient with Charcot neuroarthropathy, in lateral view of the left foot, with a support base (B), affecting the midfoot (type I of the anatomical classification of Brodsky⁴ and Trepman²²). Note the pronounced abduction deformity (A) and severe collapse of the arch with plantar bony prominence (A and B). Surgical treatment consisted of modeling midfoot arthrodesis through medial approach for bone wedge resection and correction of deformities (C), followed by internal fixation with plate and screws (D).

to fix osteopenic bones in the medial spine of the foot (→ **Figure 1**); 2) Cannulated headless screws for longitudinal fixation through midfoot bones (*intramedullar beaming*) (→ **Figure 2**); 3) intramedullary nail blocked for hindfoot (→ **Figure 3**); 4) plates with locking screws specially designed for fixation of the hindfoot. It is extremely important to emphasize that the use of internal fixation does not, in any way, discard the long-term use of TCC. Plaster immobilization should be maintained until clear and unambiguous signs of complete bone healing of the arthrodesis are identified on radiographic images taken during outpatient follow-up. In the presence of bone contamination due to chronic ulceration, the recommended bone fixation, during the modeling arthrodesis, is restricted to the circular external fixator.^{20,34,39,43}

Amputations

The cost of treating joint reconstruction surgery as an option to attempt salvage of a CN-affected limb extremity is 15 to 20% higher compared to the cost of treatment with transtibial amputation, including rehabilitation and prosthesis expenses.^{44,45} However, the duration of treatment aimed at joint reconstruction as an attempt to salvage the extremity may vary, on average, from 12 to 18 months.⁴⁶ In cases of NC whose extremity presents recurrent ulceration besides considerable deformity and instability, it is necessary to discuss openly with the patient the pros and cons of considering transtibial amputation, as it can offer to a selected patient

group a faster recovery opportunity, besides improving function and quality of life.^{47,48}

Final Thoughts

Charcot neuroarthropathy (CN) is a systemic disease that causes fractures and dislocations involving the foot and ankle in patients who already have late complications of DM, specifically PN. Its main consequence is to significantly increase the risk of ulceration and deep infection in the foot, which contributes to the high risk of a major extremity amputation. The goal of both surgical and non-surgical treatments is to obtain a stable, ulcer-free plantigrade foot. Primary indications for surgical treatment are severe foot deformities, coarse hindfoot joint instability, recurrent ulceration located under bony prominences, or deep infection. Surgical procedures aimed at avoiding amputation and preserving a functional extremity are known as “salvage surgeries”. These usually involve resection of bony prominences associated, or not, with the modeling arthrodesis of foot and ankle. However, complications of surgical treatment are frequent and involve: 1) pseudarthrosis; 2) dehiscence of the surgical wound; and 3) deep infection. Even with surgical treatment, the high risk of amputation of the extremity persists, especially in the presence of postoperative complications.

Conflict of Interests

The authors declare that have no conflict of interests.

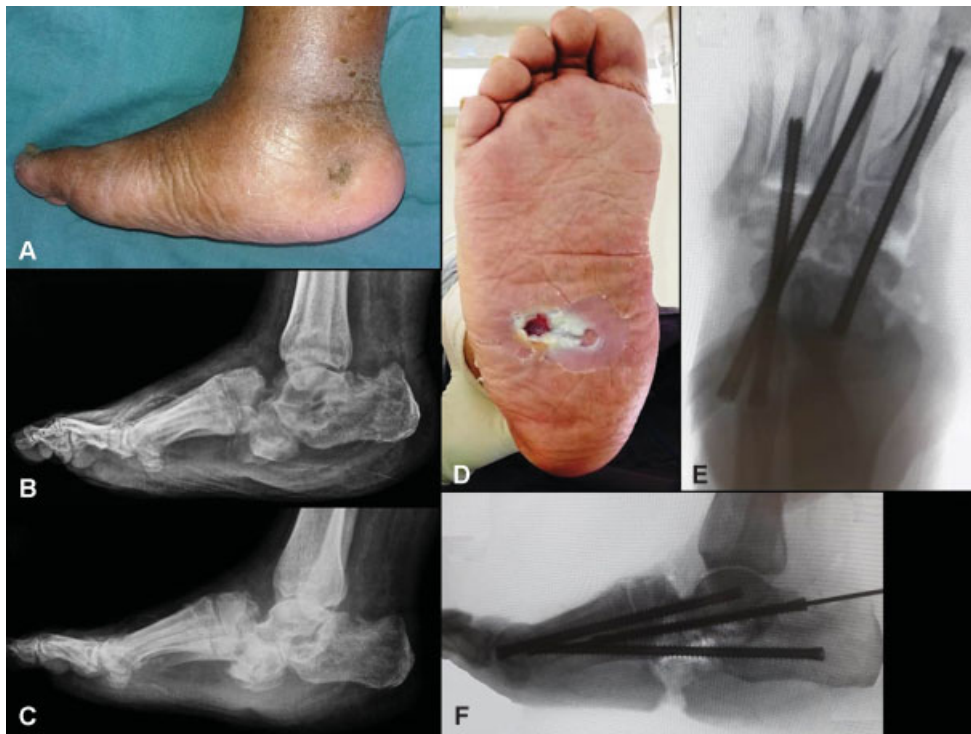

Fig. 2 Clinical aspect (A and D) of the right foot in a patient with Charcot neuroarthropathy affecting the midfoot. Radiographic images of the lateral view of the foot and ankle show that this is a type II lesion, according to the anatomical classification of de Brodsky⁴ and Trepman²² (B and C). Both upon patient arrival (B) and 4 months after the start of treatment with total contact casting (C), we can observe the presence of a pressure ulcer (D) caused by cuboid plantar bony prominence (C). The surgical treatment consisted of complete resection of the cuboid, followed by modeling midfoot arthrodesis using screws for internal fixation, according to the *intramedullary beaming* technique (E and F).

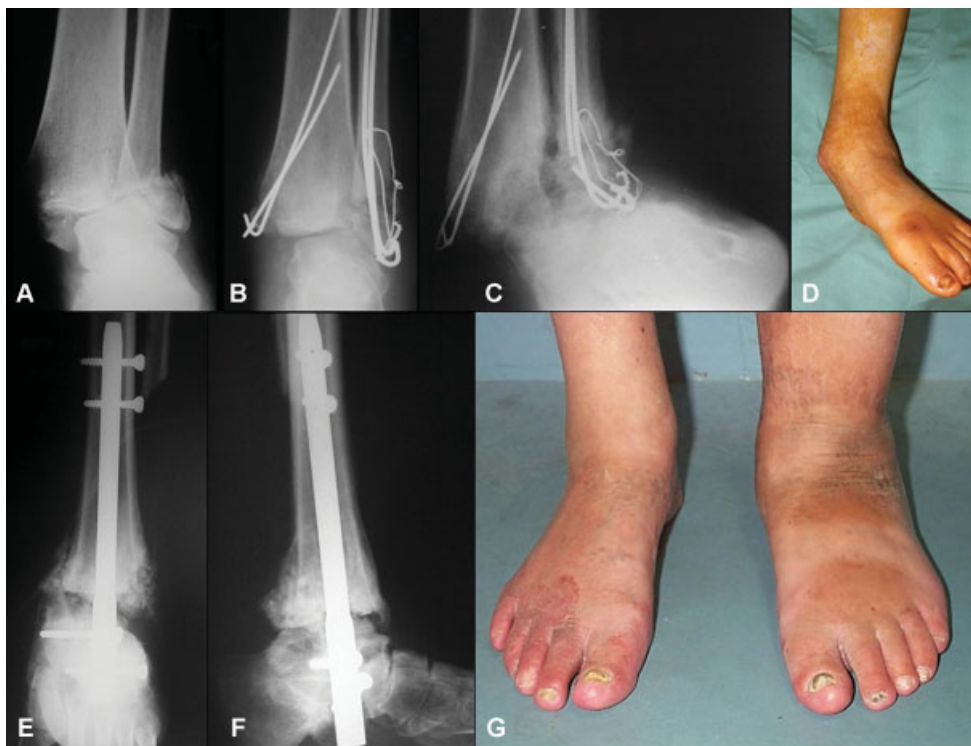

Fig. 3 Anteroposterior radiographic aspect of the left ankle showing unstable bimalleolar fracture (A), initially treated with open reduction followed by internal fixation by cerclage (B). During the postoperative follow-up, typical osteoarticular destruction of Charcot neuroarthropathy type IIIa, according to the anatomical classification of Brodsky⁴ and Trepman,²² occurred (C). Clinical aspect shows major ankle valgus deviation (D). Modeling tibiotalar calcaneal arthrodesis was indicated both to correct deformity and to stabilize the hindfoot. Radiographic images of the ankle, carried out with a support base, show that both in the anteroposterior (E) and lateral (F) incidences, bone healing of arthrodesis is ongoing. Proper alignment and stability for support could be achieved, as the clinical image demonstrates (G).

References

- 1 Hu FB. Globalization of diabetes: the role of diet, lifestyle, and genes. *Diabetes Care* 2011;34(06):1249–1257
- 2 Centers for Disease Control and Prevention. National Diabetics Statistics Report 2017. Department of Health and Human Services, Center for Disease Prevention and Control; 2017
- 3 Del Core MA, Ahn J, Lewis RB 3rd, et al. The evaluation and treatment of diabetic foot ulcers and diabetic foot infections. *Foot Ankle Int* 2018;3(1S):13S–23S
- 4 Brodsky JW. The diabetic foot. In: Mann RA, Coughlin MJ, editors. *Surgery of the Foot and Ankle*. 6th ed. St Louis, MO: Mosby; 1993: 278–283
- 5 Brodsky JW. Outpatient diagnosis and care of the diabetic foot. *Instr Course Lect* 1993;42:121–139
- 6 Wukich DK, Raspovic KM, Suder NC. Patients with diabetic foot disease fear major lower-extremity amputation more than death. *Foot Ankle Spec* 2018;11(01):17–21
- 7 Peterson N, Widnall J, Evans P, Jackson G, Platt S. Diagnostic imaging of diabetic foot disorders. *Foot Ankle Int* 2017;38(01): 86–95
- 8 Gibbons GW, Habershaw GM. Diabetic foot infections. Anatomy and surgery. *Infect Dis Clin North Am* 1995;9(01):131–142
- 9 Suder NC, Wukich DK. Prevalence of diabetic neuropathy in patients undergoing foot and ankle surgery. *Foot Ankle Spec* 2012;5(02):97–101
- 10 Game FL, Catlow R, Jones GR, et al. Audit of acute Charcot's disease in the UK: the CDUK study. *Diabetologia* 2012;55(01): 32–35
- 11 Gouveri E, Papanas N. Charcot osteoarthropathy in diabetes: A brief review with an emphasis on clinical practice. *World J Diabetes* 2011;2(05):59–65
- 12 Rogers LC, Frykberg RG, Armstrong DG, et al. The diabetic Charcot foot syndrome: a report of the joint task force on the Charcot foot by the American Diabetes Association and the American Podiatric Medical Association. *Diabetes Care* 2011; 34(09):2123–2129
- 13 Fabrin J, Larsen K, Holstein PE. Long-term follow-up in diabetic Charcot feet with spontaneous onset. *Diabetes Care* 2000;23(06): 796–800
- 14 Stuck RM, Sohn MW, Budiman-Mak E, Lee TA, Weiss KB. Charcot arthropathy risk elevation in the obese diabetic population. *Am J Med* 2008;121(11):1008–1014
- 15 Raspovic KM, Wukich DK. Self-reported quality of life and diabetic foot infections. *J Foot Ankle Surg* 2014;53(06): 716–719
- 16 Dhawan V, Spratt KF, Pinzur MS, Baumhauer J, Rudicel S, Saltzman CL. Reliability of AOFAS diabetic foot questionnaire in Charcot arthropathy: stability, internal consistency, and measurable difference. *Foot Ankle Int* 2005;26(09):717–731
- 17 Raspovic KM, Hobizal KB, Rosario BL, Wukich DK. Midfoot Charcot neuroarthropathy in patients with diabetes: the impact of foot ulceration on self-reported quality of life. *Foot Ankle Spec* 2015;8 (04):255–259
- 18 Pinzur MS, Evans A. Health-related quality of life in patients with Charcot foot. *Am J Orthop* 2003;32(10):492–496
- 19 van Baal J, Hubbard R, Game F, Jeffcoate W. Mortality associated with acute Charcot foot and neuropathic foot ulceration. *Diabetes Care* 2010;33(05):1086–1089
- 20 Ferreira RC, Gonçalves DH, Filho JM, Costa MT, Santin RAL. Midfoot Charcot arthropathy in diabetic patients: complication of an epidemic disease. *Rev Bras Ortop* 2015;47(05): 616–625
- 21 Pinzur MS. An evidence-based introduction to Charcot foot arthropathy. *Foot Ankle Int*. 2018;3(1S):24S–31S
- 22 Trepman E, Nihal A, Pinzur MS. Current topics review: Charcot neuroarthropathy of the foot and ankle. *Foot Ankle Int* 2005;26 (01):46–63
- 23 Pinzur MS, Kernan-Schroeder D, Emanuele NV, Emanuel M. Development of a nurse-provided health system strategy for diabetic foot care. *Foot Ankle Int* 2001;22(09):744–746
- 24 Myerson MS, Henderson MR, Saxby T, Short KW. Management of midfoot diabetic neuroarthropathy. *Foot Ankle Int* 1994;15(05): 233–241
- 25 Wukich DK, Sadoskas D, Vaudreuil NJ, Fourman M. Comparison of diabetic Charcot patients with and without foot wounds. *Foot Ankle Int* 2017;38(02):140–148
- 26 Eichenholtz SN. Charcot Joints. Springfield, IL: C.C.Thomas; 1966
- 27 Lepäntalo M, Apelqvist J, Setacci C, et al. Chapter V: Diabetic foot. *Eur J Vasc Endovasc Surg* 2011;42(Suppl 2):S60–S74
- 28 Maloney N, Britt RC, Rushing GD, et al. Insulin requirements in the intensive care unit in response to infection. *Am Surg* 2008;74(09): 845–848
- 29 de Souza LJ. Charcot arthropathy and immobilization in a weight-bearing total contact cast. *J Bone Joint Surg Am* 2008;90(04): 754–759
- 30 Pinzur MS. Current concepts review: Charcot arthropathy of the foot and ankle. *Foot Ankle Int* 2007;28(08):952–959
- 31 Johnson JE. Surgical treatment for neuropathic arthropathy of the foot and ankle. *Instr Course Lect* 1999;48:269–277
- 32 Simon SR, Tejwani SG, Wilson DL, Santner TJ, Denniston NL. Arthrodesis as an early alternative to nonoperative management of charcot arthropathy of the diabetic foot. *J Bone Joint Surg Am* 2000;82-A(07):939–950
- 33 Pinzur M. Surgical versus accommodative treatment for Charcot arthropathy of the midfoot. *Foot Ankle Int* 2004;25(08): 545–549
- 34 Pinzur MS, Gil J, Belmares J. Treatment of osteomyelitis in charcot foot with single-stage resection of infection, correction of deformity, and maintenance with ring fixation. *Foot Ankle Int* 2012;33 (12):1069–1074
- 35 Strotman PK, Reif TJ, Pinzur MS. Current concepts: Charcot arthropathy of the foot and ankle. *Foot Ankle Int* 2016;37(11): 1255–1263
- 36 Kroin E, Chaharbakshi EO, Schiff A, Pinzur MS. Improvement in quality of life following operative correction of midtarsal Charcot foot deformity. *Foot Ankle Int* 2018;39(07):808–811
- 37 Sammarco VJ, Sammarco GJ, Walker EW Jr, Guiao RP. Midtarsal arthrodesis in the treatment of Charcot midfoot arthropathy. *J Bone Joint Surg Am* 2009;91(01):80–91
- 38 Schon LC, Easley ME, Weinfeld SB. Charcot neuroarthropathy of the foot and ankle. *Clin Orthop Relat Res* 1998;(349): 116–131
- 39 Pinzur MS. Neutral ring fixation for high-risk nonplantigrade Charcot midfoot deformity. *Foot Ankle Int* 2007;28(09): 961–966
- 40 Fonseca Filho FF, Ferreira RC, Stéfani KC, Costa MC. A haste intramedular bloqueada na fixação da artrodese tibiotarsal. *Rev Bras Ortop* 2001;36(09):352–355
- 41 Ferreira RC, Silva AP, Costa MC, et al. Aspectos epidemiológicos das lesões no pé e tornozelo do paciente diabético. *Acta Ortop Bras* 2010;18(03):135–141
- 42 Schneckloth BJ, Lowery NJ, Wukich DK. Charcot neuroarthropathy in patients with diabetes: an update systematic review of surgical management. *J Foot Ankle Surg* 2016;55(03):586–590
- 43 Ferreira RC, Mercadante MT. Artrodese do tornozelo com fixador externo de Ilizarov. *Rev Bras Ortop* 2004;39(03): 75–92
- 44 Gershater MA, Löndahl M, Nyberg P, et al. Complexity of factors related to outcome of neuropathic and neuroischaemic/ischaemic diabetic foot ulcers: a cohort study. *Diabetologia* 2009;52(03): 398–407
- 45 Gil J, Schiff AP, Pinzur MS. Cost comparison: limb salvage versus amputation in diabetic patients with charcot foot. *Foot Ankle Int* 2013;34(08):1097–1099

- 46 Robinson AH, Pasapula C, Brodsky JW. Surgical aspects of the diabetic foot. *J Bone Joint Surg Br* 2009;91(01):1-7
- 47 Wukich DK, Ahn J, Raspovic KM, La Fontaine J, Lavery LA. Improved quality of life after transtibial amputations in patients with diabetes-related foot complications. *Int J Low Extrem Wounds* 2017;16(02):114-121
- 48 Wukich DK, Pearson KT. Self-reported outcomes of trans-tibial amputations for non-reconstructable Charcot neuroarthropathy in patients with diabetes: a preliminary report. *Diabet Med* 2013; 30(03):e87-e90