







# Argon Beam Coagulation as an Adjuvant for Extended Curettage for Giant Cell Tumors of the Bone: A Study of 50 Cases

## Coagulação por plasma de argônio como adjuvante à curetagem estendida em tumores de células gigantes do osso: Um estudo de 50 casos

Sumedh Kumar<sup>1</sup> Brajesh Nandan<sup>1</sup> Ravi Chauhan<sup>1</sup> Manish Dhawan<sup>1</sup> Siddharth Agrawal<sup>1</sup>  
Sijal Rivi<sup>1</sup>

<sup>1</sup> Department of Orthopedics, Sir Ganga Ram Hospital, New Delhi, India

Endereço para correspondência Sumedh Kumar, MBBS, DNB (Orthopaedics), MNAMS, Senior Resident, Room 1218a, Second Floor, Sir Ganga Ram Hospital, New Delhi 110060, India (e-mail: Sumedh.4.kumar@gmail.com).

Rev Bras Ortop 2023;58(2):211–221.

### Abstract

**Objective** Extended curettage with adjuvants of giant cell tumors of bone is associated with a lower rate of recurrence of the tumor while preserving the adjacent joint. The present study was conducted to estimate the recurrence rate and functional outcome after using argon beam as an adjuvant for extended curettage.

**Methods** We selected 50 patients with giant cell tumors, meeting all the inclusion criteria, who underwent extended curettage using high speed burr and argon beam photocoagulation between July 2016 to January 2019. On their follow-up visit, they were assessed for any complaints of pain and signs like tenderness, locally raised temperature, and decreased range of motion of the adjacent joint. Radiologically, the patients were assessed for any increased lucency around the cement mantle and uptake of the subarticular graft. Musculoskeletal Tumor Society Score (MSTS) was administered to the patients, and range of motion of the adjacent joint was compared with the contralateral joint.

**Results** Recurrence was found in 4 patients, that is, an 8% recurrence rate. Twenty-six out of 28 patients with a tumor in the lower limb had a grade-5 weight bearing status

### Keywords

- ▶ argon plasma coagulation
- ▶ giant cell tumor of bone
- ▶ bone neoplasms
- ▶ chemoradiotherapy, adjuvant
- ▶ orthopedics

Work developed at Dept of Orthopaedics, Sir Ganga Ram Hospital, New Delhi, India.

received  
June 12, 2021  
accepted after revision  
November 22, 2021  
article published online  
February 15, 2022

DOI <https://doi.org/10.1055/s-0042-1742600>.  
ISSN 0102-3616.

© 2022. Sociedade Brasileira de Ortopedia e Traumatologia. All rights reserved.  
This is an open access article published by Thieme under the terms of the Creative Commons Attribution-NonDerivative-NonCommercial-License, permitting copying and reproduction so long as the original work is given appropriate credit. Contents may not be used for commercial purposes, or adapted, remixed, transformed or built upon. (<https://creativecommons.org/licenses/by-nc-nd/4.0/>)  
Thieme Revinter Publicações Ltda., Rua do Matoso 170, Rio de Janeiro, RJ, CEP 20270-135, Brazil

6 months from the surgery, and their range of motion was comparable to contralateral healthy joint with an average MSTS score of 27 (18–30).

**Conclusion** Extended curettage of giant cell tumors using argon beam coagulation is associated with low recurrence rates of the tumor and is an effective modality in the treatment of these tumors besides having a functional outcome comparable to the healthy limb.

## Resumo

**Objetivo** A curetagem estendida com adjuvantes de tumores de células gigantes do osso está associada a uma menor taxa de recidiva da neoplasia e à preservação da articulação adjacente. Este estudo foi feito para estimar a taxa de recidiva e o resultado funcional após o uso de plasma de argônio como adjuvante à curetagem estendida.

**Métodos** Cinquenta pacientes com tumores de células gigantes que atendiam a todos os critérios de inclusão foram selecionados para o estudo e submetidos à curetagem estendida com broca de alta velocidade e fotocoagulação com plasma de argônio entre julho de 2016 e janeiro de 2019. À consulta de acompanhamento, os pacientes foram avaliados quanto a quaisquer queixas de dor e sinais como sensibilidade, aumento local da temperatura e diminuição da amplitude de movimento da articulação adjacente. Radiologicamente, os pacientes foram avaliados quanto à presença de qualquer aumento de radiotransparência ao redor do manto de cimento e incorporação do enxerto subarticular. O questionário *Musculoskeletal Tumor Society Score* (MSTS) foi administrado aos pacientes e a amplitude de movimentação da articulação adjacente foi comparada à articulação contralateral.

**Resultados** Quatro pacientes apresentaram recidiva, o que corresponde a uma taxa de 8%. Seis meses após a cirurgia, 26 de 28 pacientes com tumor no membro inferior tinham capacidade de sustentação de peso de grau 5 e amplitude de movimento comparável à articulação saudável contralateral, com pontuação MSTS média de 27 (intervalo de 18 a 30).

**Conclusão** A curetagem estendida de tumores de células gigantes com coagulação por plasma de argônio está associada a baixas taxas de recidiva da neoplasia; é uma modalidade eficaz no tratamento desses tumores e o resultado funcional é comparável ao do membro saudável.

## Palavras-chave

- ▶ coagulação com plasma de argônio
- ▶ tumor de células gigantes do osso
- ▶ neoplasias ósseas
- ▶ quimiorradioterapia adjuvante
- ▶ ortopedia

## Introduction

Giant cell tumor (GCT) of the bone was described by Cooper for the first time in 1818. Thereafter, Nelaton showed their local aggressiveness, and Virchow described their malignant potential. These tumors represent approximately 5% of all primary bone tumors. In most cases, adults between the ages of 20 and 40 years old are affected. It has been observed that this tumor can extend to the articular subchondral bone or even abut the articular cartilage, but the joint and/or its capsule are rarely invaded.<sup>1</sup> The symptoms are generally non-specific, and patients present with local swelling, warmth, and pain radiating independently of weight-bearing. Pathological fracture is seen in about 15% of cases.<sup>2</sup> On x-ray, GCT appears as a purely lytic lesion in the epi-metaphyseal region of the bone; further, the overlying bone may be expanded, and cortical thinning may be seen. Typically, there is a lack of periosteal reaction, except when there is a breach of cortical bone by the tumor.

The treatment of choice in most GCTs is curettage, some adjuvant method, and bone grafting. Simple curettage is seen to have a high rate of recurrence (30–50%). In order to overcome this, different adjuvants have been introduced. These adjuvants, when used with curettage, remove the remainder of the tumor cells because of their thermal (liquid nitrogen, polymethylmethacrylate) or chemical (phenol, hydrogen-peroxide, alcohol) effects.<sup>3</sup>

Argon plasma coagulation (APC) provides hemostasis and tissue coagulation, which uses argon gas to deliver plasma of evenly distributed thermal energy with the help of a probe to a field of tissue adjacent to it. The gas is then ionized by 6,000 volts delivered across the tungsten wire at the tip of the probe. This ionized gas or plasma then seeks a ground in the nearest tissue, delivering the thermal energy with a depth of penetration of roughly 2 to 3.5 mm. Argon gas further has an advantage that it is non-flammable and relatively inexpensive to refill.<sup>4</sup>

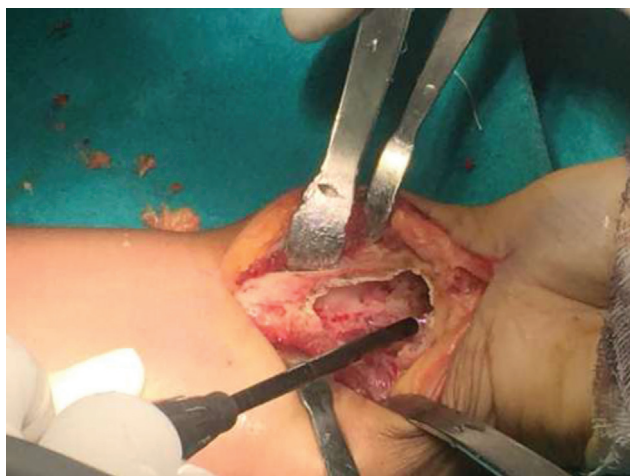
The objective of the present study is to assess the rate of recurrence after doing extended curettage of benign aggressive bone tumors in which argon beam was used as an adjuvant to minimize recurrence and improve the postsurgery functional outcome.

## Methodology

A retrospective observational study of all cases of GCTs of the bone undergoing extended curettage with argon beam coagulation between July 2016 to January 2019 was done. Fifty patients, of both genders, 18 years or older, whose articular surface of the joint adjacent to the tumor was intact on x-ray, were included. The criteria of exclusion were patients with extensive soft-tissue involvement and cortical destruction (breach of > 50% of the area of the cortical bone overlying the tumor), patients with articular surface disruption, and patients younger than 18 years.

All records of the patients, that is, pre and intraoperative findings, old radiographs (x-ray), computed tomography (CT) scan and magnetic resonance imaging (MRI) films were thoroughly checked. Recurrence of tumor was assessed by clinical examination at the time of follow-up, and an X-ray of the operated area was done. Contrast enhanced CT of the chest was done for assessment of metastatic disease.

The surgeries had been performed by the same surgical and anesthetic team, using the same pre and postoperative protocol for all patients. Patients had been operated under general or spinal anesthesia depending on the anesthetist's decision. Incision and soft-tissue dissection had been planned to include the biopsy incision in the incision for the definitive surgery. After thorough curettage and removal of visible tumor tissue, high speed burr was applied to the margins of the cavity, except for the subarticular region, followed by thorough saline wash of the cavity. Once this was done, setting the argon beam machine at 100 watts, argon beam photocoagulation of the cavity walls was performed throughout the cavity (►Figure 1), including



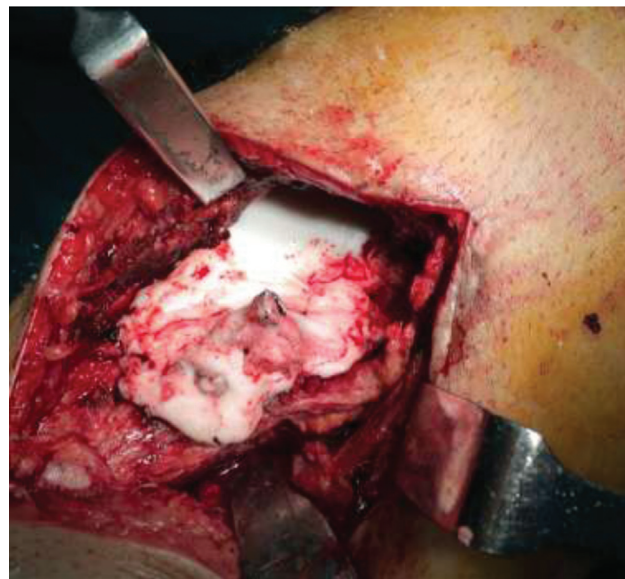
**Fig. 1** Intraoperative photograph of application of argon beam to walls of curetted cavity in a case of giant cell tumor of distal radius (Left).

the subarticular region till the bone cavity walls were blackened, keeping that as the end point. Autograft was harvested from the iliac crest and, if required, from the fibula also, taking care to use a fresh set of instruments in order to avoid implanting any tumor cells at the graft site. Fibula cortical struts along with iliac crest graft were used when there was a large cavity involving nearly all of the cross-section of the bone after curettage of the tumor in order to provide greater strength and stability. A bed of the harvested graft was placed in the subarticular region and covered with Gel-Foam. An implant (in most cases, partially threaded 6.5-mm cancellous screws) was fixed to one of the walls of the cavity to anchor the PMMA cement and avoid its dislodgement. The PMMA cement was prepared, and the cavity was filled with the prepared bone cement (►Figure 2).

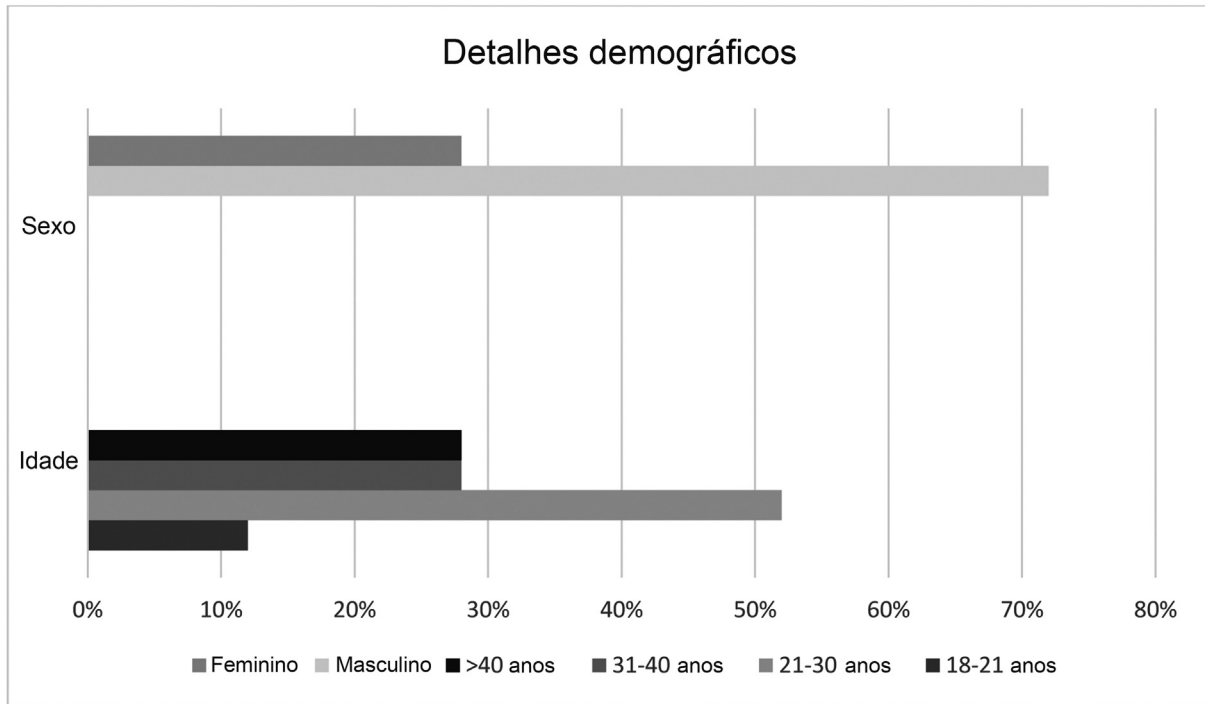
The MSTS score was applied to each of these patients on their follow-up visit, depending on the site of involvement along with assessment of range of motion and weight bearing status.

## Results

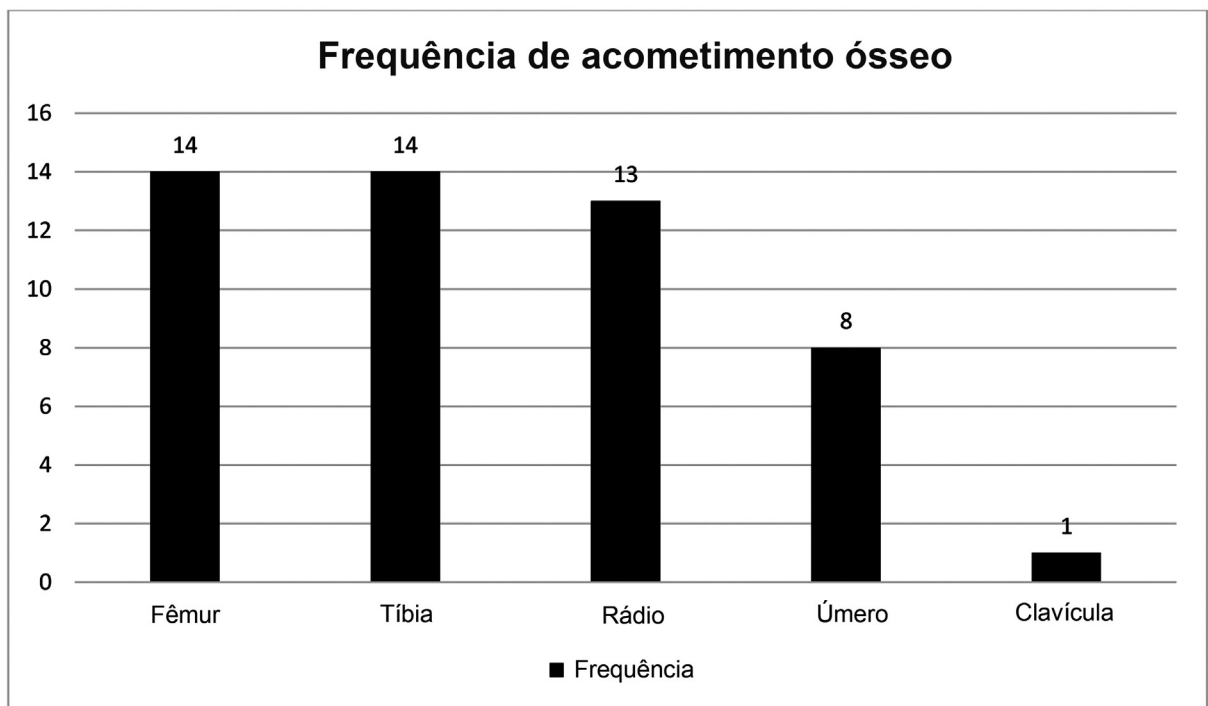
In this series of 50 cases, we found that the average age of the patients was 28.8 years old, with a median age of 26 years old (►Figure 3). The mean duration of complaints at the time of the first presentation was 6.64 months, with a range of 1 to 18 months. Fourteen patients had the GCT in the distal femur and the proximal tibia each (►Figure 4). Males were found to be more frequently affected as there were 36 male patients and 14 female patients. The most frequently encountered Campanacci grade was grade 2, with 22 patients being detected at that stage. There were 14 patients presenting with Campanacci grade 1, and 14 patients with Campanacci grade 3. There were 4 patients in whom the tumor had



**Fig. 2** Application of polymethyl methacrylate cement after fixing the cavity with cancellous screw.



**Fig. 3** Graph showing demographic details of patients.



**Fig. 4** Graph showing frequency of site of tumor.

**Table 1** Table showing domains of Musculoskeletal Tumor Society Score and its application

MSTS Common Domains	Lower extremity specific domains	Upper extremity specific domains
Pain Function Emotional Acceptance	Use of support Walking ability Gait	Hand position Dexterity Lifting ability
Depending on the extremity affected a score of 0–5 is given by the patient for each domain		

recurred after being treated elsewhere prior to presenting to us. Recurrence of the tumor was found in 4 (8%) patients on the follow-up visit. The average follow-up period was 38 months (range 28–58 months). The average MSTs was found to be 27 at follow-up (range: 18–30) (► **Table 1**).

The patients who were treated for lower limb GCTs, returned to full weight bearing ambulation 6 months from the date of surgery. The most common complaint of patients in the postoperative period was pain at the graft site, which was seen in 6 of the 50 patients, 4 patients had superficial surgical site infections, and 4 patients had numbness and tingling in the distal area of the tumor excision (► **Table 2**).

## Discussion

The treatment modalities for GCT are either wide resection of the tumor with a safe margin, which usually sacrificed the adjacent joint, markedly deteriorating the patient's quality of life or curettage with an adjuvant method.<sup>5</sup>

When compared to other adjuvants, like phenol, argon beam coagulation is not associated with soft-tissue damage due to spillage and is relatively easier to apply to the cavity.<sup>6</sup> Complications, like intraoperative fractures and avascular necrosis of bone, are rarely seen and are associated with cryotherapy using liquid nitrogen as an adjuvant.<sup>7</sup> These advantages in addition to the relatively low recurrence rate make argon beam coagulation a desirable adjuvant modality.

In the current series of 50 patients treated with argon beam as an adjuvant, we found that 4 patients had a recurrence, which was observed on the follow-up visit. The patients underwent re-surgery, curing which an extended curettage of the area of recurrence was done and PMMA was applied in the curetted cavity after treating the area of recurrence with argon beam photocoagulation. This brings the recurrence rate to 8%, which is comparable to the modalities in other published studies (► **Table 3**).<sup>8–22</sup>

We came across 4 patients (8%) who presented to us with recurrence of symptoms after being operated previously. When treated with extended curettage with argon beam, none of them had evidence of recurrence in the follow-up visit.

Four of our patients presented to us with preexisting medical comorbidities. One of the findings was that two

**Table 2** Table showing the complications faced after modified extended curettage

Complication	Frequency
Graft site	6
Superficial infection	4
Neurological symptoms	4
No complications	36

patients with diabetes developed superficial surgical site infections. The infections were controlled by intravenous and oral antibiotics, but it prolonged their hospital stay and increased their morbidity. As part of our surgical procedure, placement of the bone graft in the subarticular region to protect the articular cartilage was essential in every case. Bone graft from the iliac crest, fibula, or from both these sites was taken. Graft from only the iliac crest was used in 34 cases (68%), only the fibula was used in 2 patients (4%), and graft from both sites was needed in 14 of our patients (28%). The average duration of hospital stay was 7.76 days, with the maximum duration of hospital stay being 40 days and the minimum being 3 days.

In terms of functional recovery, the MSTs was done for all the patients on follow-up, and the average score was found to be 27 (range 18–30). On examination, it was found that the functional range of motion was maintained in all patients, and they were able to do their activities of daily living. The PMMA cement has its advantages of reducing recurrence and, along with the implant, provide mechanical stability (► **Figure 5**). The disadvantage of the cement is that it can lead to articular cartilage damage and further worsen the joint range of motion. In order to avoid this, a thick subarticular graft was given, which separated the articular cartilage from the bone cement. This helped to keep the articular cartilage intact and protect the joint. The subarticular graft was further covered with Gel-Foam in order to avoid any damage to the graft by the thermal effect of the bone cement. Ultimately, an improved range of motion of the joint was seen, which was significant, consistent, and comparable to the joint on the unaffected side (► **Figures 6–8**). This reduced the postoperative rehabilitation time and allowed the patient to resume daily activities soon after the surgery. Subarticular graft uptake was seen on radiographs in all 50 cases which had been taken at 6 months from surgery, and graft resorption was not encountered in this series. In 2018, Wang et al.<sup>23</sup> published a study in which they found that the graft uptake in a curetted cavity ranged from 5 to 9 months. Our study is in agreement with the previous literature.

Six out of 50 patients (12%) complained of pain at the graft site in the immediate postoperative period. The pain subsided in 3 to 5 days with analgesics. Another complaint of the patients was scar marks at the graft site (► **Table 3**). None of the patients had severe complaints, such as

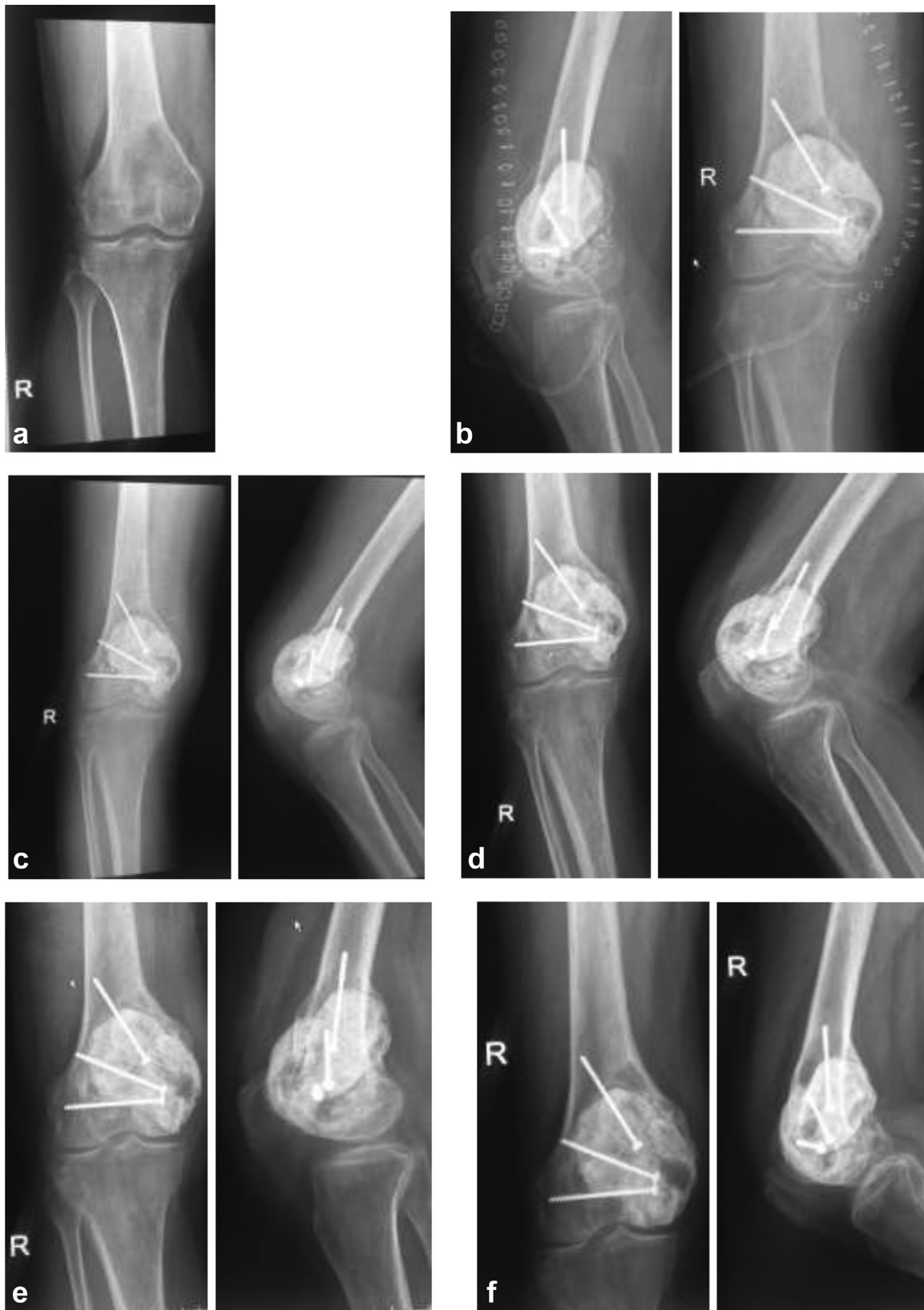**Table 3** Comparative table showing various studies and the rates of recurrences of giant cell tumor with their treatment modality

S. no.	Study	Year	Follow up	Patients	Surgical treatment	Recurrences
1.	McDonald et al. <sup>8</sup>	1986	84 months	146	Wide resection curettage + burr	7% 34%
2.	Campanacci et al. <sup>9</sup>	1987	2-44 years	280	Wide resection	0%
					Marginal excision	8%
					Intralesional excision	27%
3.	O'Donnel et al. <sup>10</sup>	1994	4 Years	60	Curettage + PMMA	42%
					Curettage + PMMA + burr	17%
4.	Blackley et al. <sup>11</sup>	1999	80 months	59	Curettage + burr	12%
5.	Trieb et al. <sup>6</sup>	2001	11 years	47	Curettage + burr	21%
					Curettage + burr + phenol	25%
6.	Turcotte et al. <sup>12</sup>	2002	60 months	156	Wide resection	16%
					Curettage +/- burr +/- Phenol	18%
7.	Saiz et al. <sup>1,3</sup>	2004	76 months	40	Curettage+ burr + phenol + PMMA	13%
8.	Su et al. <sup>1,4</sup>	2004	62 months	87	Wide resection	3%
					Curettage + phenol + burr	18%
9.	Prosser et al. <sup>1,5</sup>	2005	70 months	137	Curettage+ burr	19%
10.	Malek et al. <sup>1,6</sup>	2006	48 months	40	Curettage+ burr	33%
11.	Lewis et al. <sup>17</sup>	2007	73 months	37	Curettage + argon beam + PMMA	8.3%
13.	Balke et al. <sup>18</sup>	2008	60 Months	214	Wide resection	0%
					Curettage	65%
					Curettage + burr	22%
					Curettage + PMMA + burr	18%
					Curettage + PMMA + burr + H2O2	12%
14.	Kivioja et al. <sup>1,9</sup>	2008	5 years	294	Wide\marginal Excision	12%
					Curettage	51%
					Curettage + PMMA	23%
15.	Errani et al. <sup>20</sup>	2010	91 months	349	Wide resection	12%
					Curettage + burr + phenol	51%
					Curettage + burr + phenol + PMMA	22%
16.	Klenke et al. <sup>21</sup>	2011	108 months	118	Wide resection	5%
					Curettage + burr	32%
					Curettage + phenol + burr	34%
					Curettage + PMMA + burr + phenol	15%
17.	Benevenia et al. <sup>22</sup>	2012	10 months	93	Curettage + phenol	17.1%
					Curettage + argon beam	14.8%

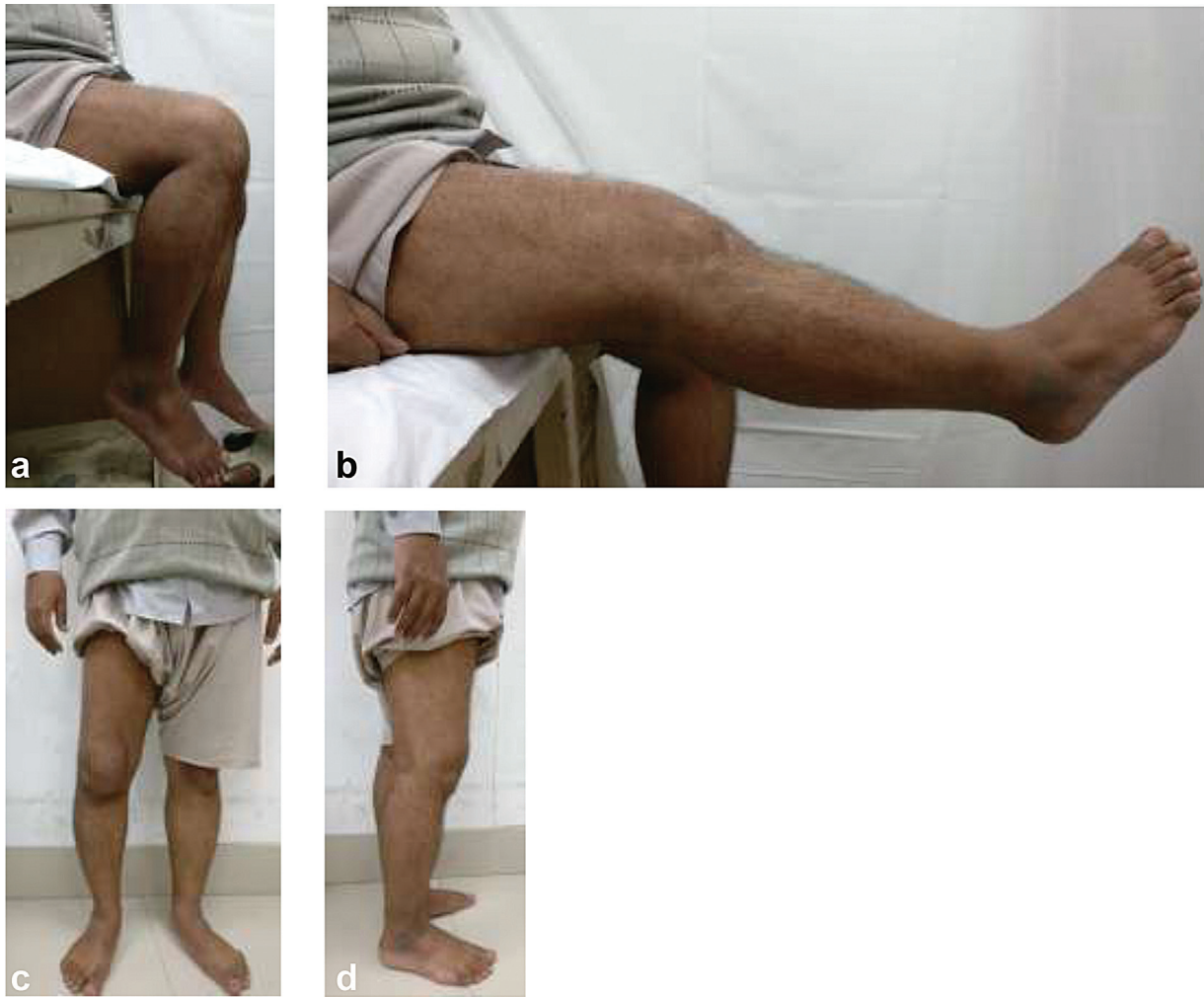Abbreviation: PMMA, polymethyl methacrylate.

herniation at the graft site or complaints suggestive of meralgia paraesthetica. Summers B. N. and Eisenstein S. M. conducted a study in 1989 which revealed 'significant' donor site pain in 25% of patients, 'acceptable' pain in 24%, and no pain in 51% of patients that had bone grafts taken from the iliac crest. The reason for a significantly reduced graft site morbidity was the surgical technique, in which we preferred taking a bicortical iliac crest graft as compared to

a tricortical bone graft; besides, we left the inner table of the iliac crest intact and closed the surgical wound in a layered, tension-free manner. Four out of the 50 patients (8%) in our study developed a superficial surgical site infection, which manifested as erythema and induration around the stitch line on the 2<sup>nd</sup> postoperative day. Intravenous antibiotics along with regular dressings allowed the infection to resolve completely by the 5<sup>th</sup> postoperative day.



**Fig. 5 a-f** showing x-ray series of patient with giant cell tumor of the distal femur. (a) preoperative x-ray. (b) immediate postoperative x-ray. (c) 1 month postoperative x-ray. (d) 3 month postoperative x-ray. (e) 6 month postoperative x-ray. (f) clinical pictures at follow-up visit suggestive of recurrence.



**Fig. 6 a-d** Clinical pictures showing range of motion at follow up visit. (a) knee flexion. (knee extension). ► **Fig 6 c, d.** unassisted weight bearing.

All the patients who developed the infections were diabetics. Four (8%) patients in our study complained of tingling and numbness over the distal area of the tumor in the postoperative period. Both these patients were operated for a tumor in the medial condyle of the distal femur. Their complaints had subsided with oral neuromodulators like gabapentin. Takeuchi et al.<sup>24</sup> published a study in 2018 in which they investigated 26 patients with at least 36 months of follow-up and found that osteoarthritis, chronic synovitis, and fracture were observed in one case each (3.8%), which were managed conservatively.

## Conclusion

The present study reviewed the data of 50 patients who underwent an extended curettage using argon beam photocoagulation with high-speed burr and PMMA cement. The recurrence rate of the tumor was 8% along with a good functional outcome, since the adjacent joint was not sacrificed. This rate of recurrence was among the lowest in the

existing literature. In spite of a small sample size, we can still draw an inference from our study that combining argon beam photocoagulation with extended curettage is an effective modality for the treatment of GCTs and is associated with a significantly reduced rate of recurrence. Its precision, ease of use, and low complication rate make it a valuable adjuvant treatment alternative.

### Financial Support

There was no financial support from public, commercial, or non-profit sources.

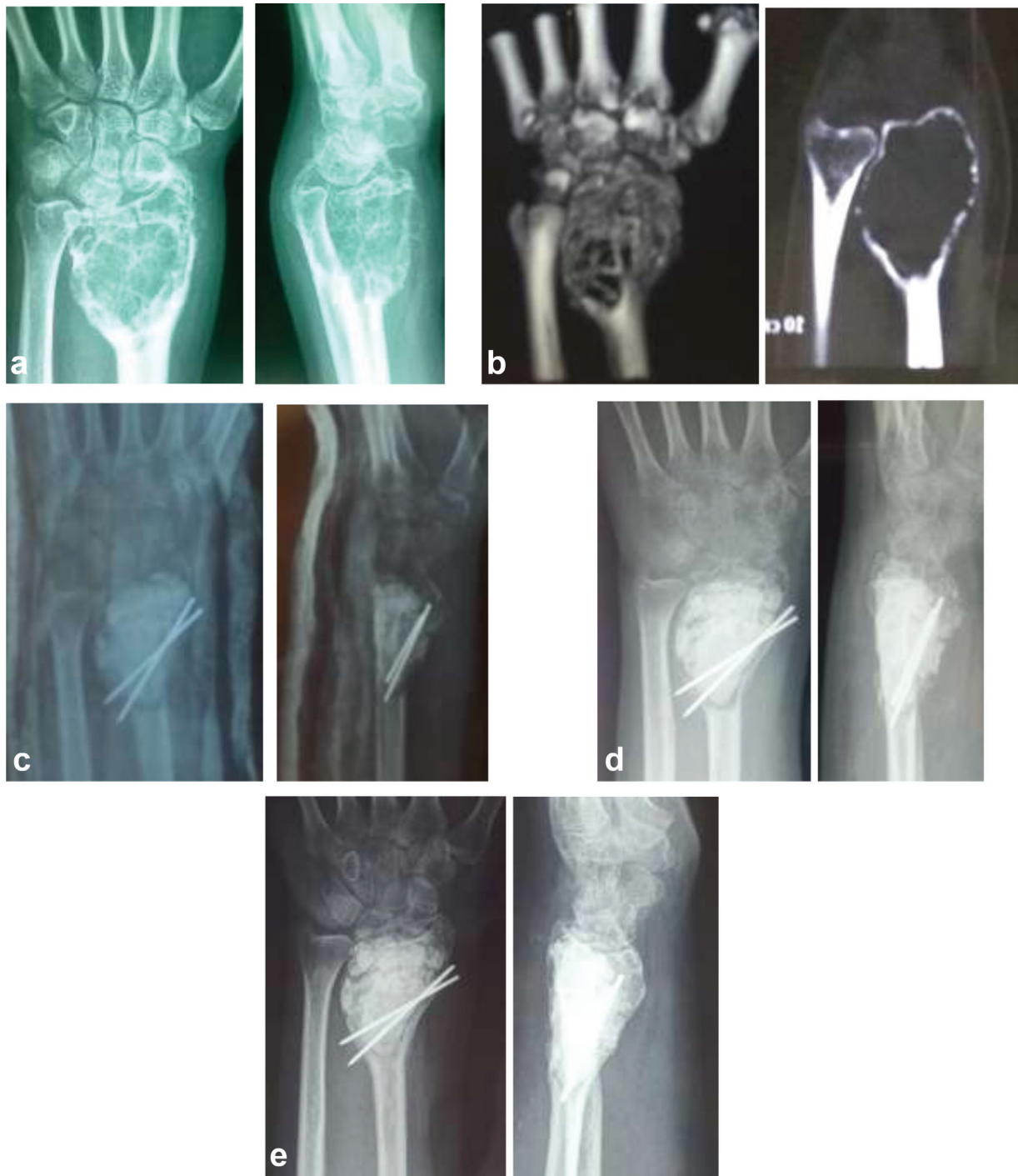
### Conflict of Interests

The authors declare that there are no conflicts of interest.

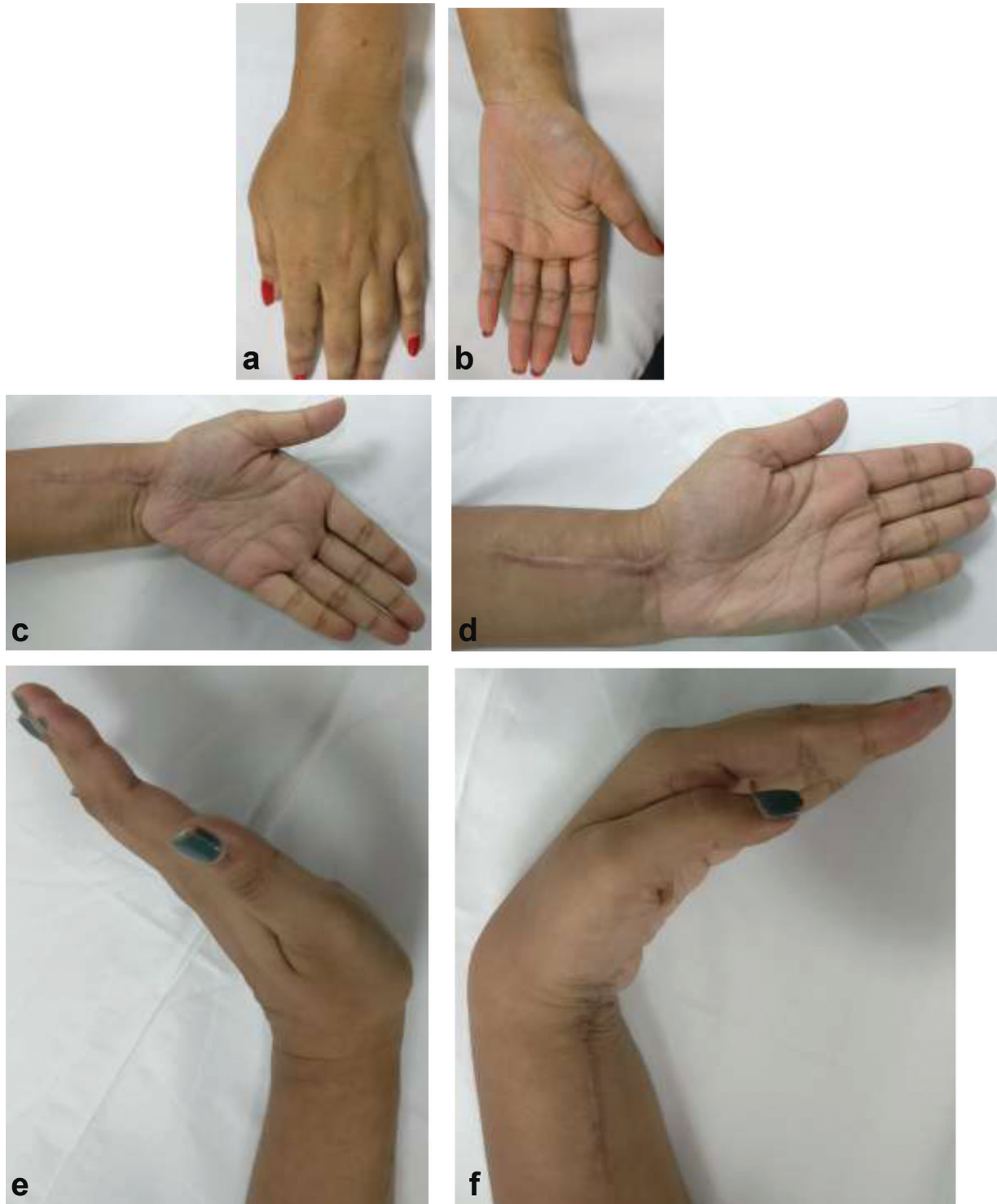
## Referências

- 1 Sobti A, Agrawal P, Agarwala S, Agarwal M. Giant Cell Tumor of Bone - An Overview. *Arch Bone Jt Surg* 2016;4(01):2-9
- 2 Dreinhöfer KE, Rydholm A, Bauer HC, Kreicbergs A. Giant-cell tumours with fracture at diagnosis. Curettage and acrylic cementing in ten cases. *J Bone Joint Surg Br* 1995;77(02):189-193





**Fig. 7 a-e** showing x-ray series of patient with giant cell tumor of the distal radius. (a). **preoperative** x-ray. (b) preoperative computed tomography scan. (c) immediate postoperative x-ray. (d) 3 months follow up X-ray. (e) Clinical pictures at follow-up visit.



**Fig. 8 a-f** Showing clinical pictures of patient with giant cell tumor of the distal radius. (a) preoperative clinical pictures. (f) clinical pictures at follow-up visit.

- 3 Campanacci M. Giant-cell tumor and chondrosarcomas: grading, treatment and results (studies of 209 and 131 cases). *Recent Results Cancer Res* 1976;(54):257–261
- 4 Cohen J, Abedi M, Haber G, et al. Argon plasma coagulation: a new effective technique of non-contact thermal coagulation. Experience in 44 cases of GI angiomata. *Gastrointest Endosc* 1996;43:293
- 5 Schajowicz F. Giant-Cell Tumor (Osteoclastoma). In: *Tumors and Tumorlike Lesions of Bone and Joints*. New York: Springer; 1981: 301–367
- 6 Trieb K, Bitzan P, Lang S, Dominkus M, Kotz R. Recurrence of curetted and bone-grafted giant-cell tumours with and without adjuvant phenol therapy. *Eur J Surg Oncol* 2001;27(02): 200–202
- 7 Malawer MM, Bickels J, Meller I, Buch RG, Henshaw RM, Kollender Y. Cryosurgery in the treatment of giant cell tumor. A long-term followup study. *Clin Orthop Relat Res* 1999;(359): 176–188
- 8 McDonald DJ, Sim FH, McLeod RA, Dahlin DC. Giant-cell tumor of bone. *J Bone Joint Surg Am* 1986;68(02):235–242
- 9 Campanacci M, Baldini N, Boriani S, Sudanese A. Giant-cell tumor of bone. *J Bone Joint Surg Am* 1987;69(01):106–114
- 10 O'Donnell RJ, Springfield DS, Motwani HK, Ready JE, Gebhardt MC, Mankin HJ. Recurrence of giant-cell tumors of the long bones after curettage and packing with cement. *J Bone Joint Surg Am* 1994;76 (12):1827–1833
- 11 Blackley HR, Wunder JS, Davis AM, White LM, Kandel R, Bell RS. Treatment of giant-cell tumors of long bones with curettage and bone-grafting. *J Bone Joint Surg Am* 1999;81(06):811–820
- 12 Turcotte RE, Wunder JS, Isler MH, et al; Canadian Sarcoma Group. Giant cell tumor of long bone: a Canadian Sarcoma Group study. *Clin Orthop Relat Res* 2002;(397):248–258
- 13 Saiz P, Virkus W, Piasecki P, Templeton A, Shott S, Gitelis S. Results of giant cell tumor of bone treated with intralesional excision. *Clin Orthop Relat Res* 2004;(424):221–226
- 14 Su YP, Chen WM, Chen TH. Giant-cell tumors of bone: an analysis of 87 cases. *Int Orthop* 2004;28(04):239–243
- 15 Prosser GH, Baloch KG, Tillman RM, Carter SR, Grimer RJ. Does curettage without adjuvant therapy provide low recurrence rates in giant-cell tumors of bone? *Clin Orthop Relat Res* 2005;(435): 211–218
- 16 Malek F, Krueger P, Hatmi ZN, Malayeri AA, Faezipour H, O'Donnell RJ. Local control of long bone giant cell tumour using curettage, burring and bone grafting without adjuvant therapy. *Int Orthop* 2006;30(06):495–498
- 17 Lewis VO, Wei A, Mendoza T, Primus F, Peabody T, Simon MA. Argon beam coagulation as an adjuvant for local control of giant cell tumor. *Clin Orthop Relat Res* 2007;454(454):192–197
- 18 Balke M, Schremper L, Gebert C, et al. Giant cell tumor of bone: treatment and outcome of 214 cases. *J Cancer Res Clin Oncol* 2008;134(09):969–978
- 19 Kivioja AH, Blomqvist C, Hietaniemi K, et al. Cement is recommended in intralesional surgery of giant cell tumors: a Scandinavian Sarcoma Group study of 294 patients followed for a median time of 5 years. *Acta Orthop* 2008;79(01):86–93
- 20 Errani C, Ruggieri P, Asenzio MA, et al. Giant cell tumor of the extremity: A review of 349 cases from a single institution. *Cancer Treat Rev* 2010;36(01):1–7
- 21 Klenke FM, Wenger DE, Inwards CY, Rose PS, Sim FH. Giant cell tumor of bone: risk factors for recurrence. *Clin Orthop Relat Res* 2011;469(02):591–599
- 22 Benevenia J, Patterson FR, Beebe KS, Abdelshahed MM, Ugliandolo AD. Comparison of phenol and argon beam coagulation as adjuvant therapies in the treatment of stage 2 and 3 benign-aggressive bone tumors. *Orthopedics* 2012;35(03):e371–e378
- 23 Wang YL, Min L, Duan H, et al. [Therapeutic Effect of Uncemented Allograft-prosthetic Composite for the Reconstruction of Tumorous Bone Defect]. *Sichuan Da Xue Xue Bao Yi Xue Ban* 2018;49 (01):129–132
- 24 Takeuchi A, Suwanpramote P, Yamamoto N, et al. Mid- to long-term clinical outcome of giant cell tumor of bone treated with calcium phosphate cement following thorough curettage and phenolization. *J Surg Oncol* 2018;117(06):1232–1238