



RBO  
REVISTA BRASILEIRA DE ORTOPEDIA

www.rbo.org.br/



## Updating Article

# Congenital deformities of the upper limbs. Part II: failure of formation and duplications

Edgard Novaes França Bisneto<sup>1\*</sup>

<sup>1</sup>Attending Physician in the Hand Group, Institute of Orthopedics and Traumatology, Hospital das Clinicas, School of Medicine, Universidade de São Paulo; Care Association for Disabled Children of São Paulo (AACD), São Paulo, SP, Brazil.

Work performed jointly by the Hand Group of the AACD São Paulo and the Group of the Institute of Orthopedics and Traumatology, Hospital das Clinicas, School of Medicine, Universidade de São Paulo, São Paulo, SP, Brazil.

### ARTICLE INFO

#### Article history:

Received January 31 2012

Approved October 2012

#### Keywords:

Congenital Abnormalities

Upper Extremity

Upper Extremity Congenital

Deformities/history

### A B S T R A C T

This article, presented in three sections, review the most common upper limb malformations and their treatments. In this section two there's a discussion about failure of formation and duplication of the parts. The bibliography is continuous since section one.

© 2013 Sociedade Brasileira de Ortopedia e Traumatologia. Published by Elsevier Editora Ltda. All rights reserved.

\*Corresponding author at: Rua Dr. Ovídio Pires de Campos, 333, Cerqueira Cesar, São Paulo, SP, Brazil. CEP: 05403-010.

Tel: (+55 11) 99631-3043.

E-mail: edgard.franca@hc.fm.usp.br

## Introduction

This second article of a series of three covers the guidelines for treating failure of differentiation and duplication, in accordance with the classification of the IFSSH (International Federation of Societies for Surgery of the Hand).

### II Failure of differentiation of parts

#### II.1 Synostosis

This is a generic term that indicates bone union between bones that are normally separated.<sup>25</sup> It can occur in any location, but it has greatest clinical importance when in the elbow. Radiographs may be normal at birth, but the range of motion is smaller than in normal elbows and may go unnoticed in newborns.<sup>25</sup>

Radiohumeral synostosis, which is generally associated with ulnar club hand, may form part of the multiple synostosis syndrome. In cases of stiff elbow, the functional capacity of the upper limb will depend on the position of the elbow and the functional capacity of the hand and shoulder.<sup>25</sup> Bilateral impairment occurs most commonly. There is no specific treatment, and in most cases occupational therapy is advised. Derotation osteotomy and bone stretching can be used in well-selected cases that present large deformities.<sup>14,25</sup>

Proximal radioulnar synostosis is bilateral in 50% of the cases and may not be recognized until adolescence.<sup>14,25</sup> Pronation-supination is absent and the movement of the upper limb is compensated by the wrist and shoulder.<sup>25</sup> Generally, this is an isolated deformity, but it may be associated with hypoplasia of the thumb, symphalangism, congenital clubfoot, arthrogryposis and Apert syndrome.<sup>14</sup> Cases in mid-pronation position or small degrees of pronation or supination do not require treatment. Hyperpronation or hypersupination should be treated by means of derotation osteotomy in synostosis, seeking a position with 30° of pronation in unilateral cases, while for bilateral cases, mid-pronation is sought in the non-dominant limb and 20° of pronation in the dominant limb.<sup>14,25</sup>

#### II.2 Dislocation of the radial head

Congenital dislocation of the radial head (Fig. 12) may occur in isolation or in association with proximal radioulnar synostosis and other syndromes, including Cornelia de Lange, Klinefelter, etc.<sup>25</sup> The dislocation is generally posterior or posterolateral, while in one third of the cases it is anterior.<sup>14,25</sup>

There may be limitation of extreme movements, but in most cases no dysfunction is noted.<sup>14</sup> There is great difficulty in differentiating chronic traumatic dislocation from congenital dislocation, since radiographs are in many cases



Fig. 12 - Congenital dislocation of the radial head.

produced because of trauma.<sup>25</sup> Congenital dislocation is generally bilateral, the radial head is flattened, associated anomalies are present, the capitellum is hypoplastic and the ulna and radius may be shortened.<sup>14,25</sup>

Treatment is rarely necessary during childhood. Resection of the radial head may be indicated during adolescence or in adulthood, always after skeletal maturity, in painful cases.<sup>14,25</sup>

#### II.3 Symphalangism

This is characterized by stiffness or fusion of the interphalangeal joints. Surgical treatment is uniformly reported as being disappointing, although there have been descriptions of arthroplasty. At adult ages, arthrosis may occur in the distal interphalangeal or metacarpophalangeal joint due to mechanical overload.<sup>10</sup>

#### II.4 Syndactyly

This can be defined as variable fusion between two adjacent fingers. It is one of the most common congenital deformities, occurring in 1:2,000 live births.<sup>26,27</sup> There are several classification systems, which will not be covered in this chapter, but classically these cases are divided into the following types:<sup>26</sup>

*Simple*: fusion only through the skin;

*Complex*: when there is a bone connection.

*Complete*: the entire commissure is involved, as far as the nail bed;

*Incomplete*: the nail bed is not involved.

*Complicated*: involvement of vascular tissues, tendons or nerves.

It can occur separately or as a manifestation of a syndrome, such as Streeter, Apert or Poland, in which the severity of the syndactyly is greater.

Practically all patients with syndactyly have surgical indications and, if possible, the surgery should be done before the age of two years,<sup>26,27</sup> in order to avoid angular deformities between the fingers.

The initial treatment consists of reconstruction of the digital commissure, with adequate skin coverage and reconstruction of the nail bed.<sup>26</sup> Several designs for commissure flaps have been described, and planning needs to be done for each case. Skin grafting is not always necessary,<sup>26</sup> particularly in cases of incomplete syndactyly. However, in the present author's opinion, it should always be performed in cases of complete, complex and complicated syndactyly. There are several graft donor areas: inguinal region, hypothernar, antecubital region, feet, etc.<sup>26</sup> (Fig. 13).

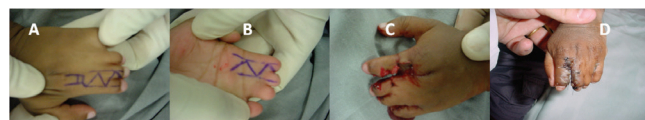

Fig. 13 - Simple/complete syndactyly (A, B). After the operation (C, D).

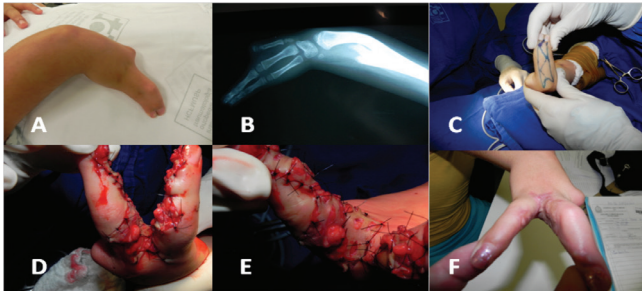
It is always prudent to avoid releasing two adjacent commissures, so as to avoid vascular complications.<sup>10</sup>

The approach is surgical in most cases, and it is seen that the integration of skin grafts is significantly better, the younger the child is. In particular, the present author chooses to use larger skin flaps in cases of zigzag incisions, which also facilitates graft integration (Fig. 14). Care regarding postoperative dressings is essential for success in the operation.

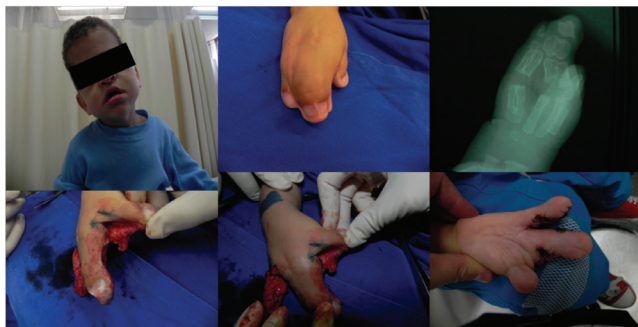Apert syndrome (Fig. 15) is characterized by craniosynostosis, midfacial hypoplasia, syndactyly and visceral abnormalities. The syndactyly is complex and complicated. The initial objective of the treatment is to provide a thumb so the digital pincer movement can be made.<sup>26,27</sup>

Experiences using external fixators for detensioning of fingers with severe syndactyly, so as to avoid skin grafting (Fig. 16).<sup>28</sup>

The Poland syndrome or sequence (Fig. 17) is an abnormality of the subclavian artery, in the embryological phase, which gives rise to several types of hypoplasia in the upper limbs.



**Fig. 14 - Ulnar club hand with syndactyly. Before operation (A, B); during operation with skin graft (C, D, E); after operation (F).**



**Fig. 15 - Apert syndrome and complex syndactyly.**



**Fig. 16 - Use of external fixators for treating syndactyly.<sup>28</sup>**

It is characterized by aplasia of the pectoralis major muscle, brachydactyly, hypoplasia of the hand and syndactyly. The syndactyly cases tend to be of simple type and follow the normal treatment pattern.<sup>27</sup>

**II.5 Contractures**

**II.5A Soft tissues**

**II.5A 1 Pterygium**

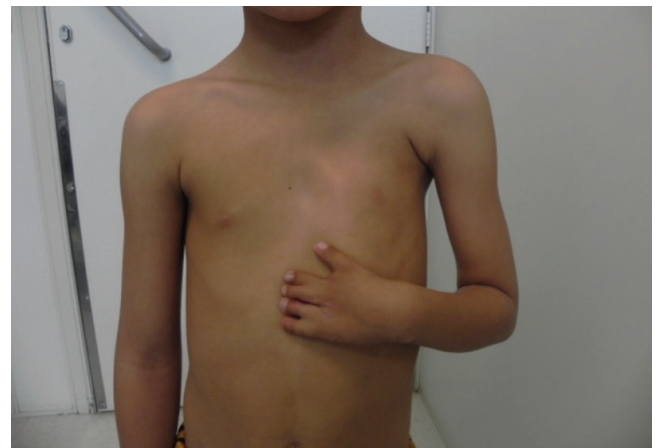
The pterygium, or presence of a band of skin in the cubital fossa, may occur in isolation or in association with syndromes. The elbow is frequently stiff and surgical treatment to increase its range of motion is discouraged because of the lack of success in the literature.<sup>25</sup>

Plastic surgery on the skin band can be performed by means of Z-plasty for cosmetic purposes, given that cavities influence the range of motion of the elbow (Fig. 18).

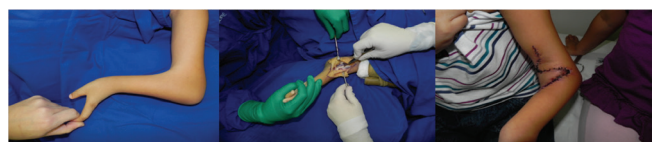**II.5A 2 Congenital trigger finger**

There are differences between the congenital trigger condition in the thumb and in the other fingers.<sup>29</sup> The congenital trigger condition is rare in the ulnar fingers and is associated with other malformations of the superficial and deep flexors. It generally presents with sporadic locking. Release of the A1 pulley alone tends not to produce results, and tenoplasty of the chiasm and partial opening of the A2 pulley are necessary.<sup>29</sup>

Congenital trigger thumb has been considered by some authors to be an acquired condition, given that it may not be present at birth, although abnormalities of the A1 pulley have been described. It generally presents as a contracture of the interphalangeal joint of the thumb, in fixed flexion. Its treatment is initially conservative. After one year of age, if conservative treatment fails, opening the A1 pulley is indicated.<sup>29</sup>



**Fig. 17 - Poland syndrome. Note aplasia of the pectoralis major muscle.**



**Fig. 18 - Zetaplasty of pterygium.**



### II.5A 3 Hypoplastic thumb

Hypoplasia of the thumb consists of a set of abnormalities that go from a thumb that is slightly smaller to its complete absence.<sup>30</sup> It may occur in isolation or together with longitudinal deficiencies of the radius.<sup>15</sup>

The Blauth classification modified by Manske is the one most used, as follows:<sup>15,31</sup>

*Type I:* slightly hypoplastic thumb with short abductor opposing the hypoplastic thumb or absent.

*Type II:* hypoplastic thumb, with narrowing of the first commissure, absence or hypoplasia of the short abductor opposing the thumb; metacarpophalangeal joint instability through absence of the ulnar collateral ligament; and inability to perform digital pincer movement.

*Type III:* greater instability and insufficiency of the first commissure. There are abnormalities of the extrinsic musculature through absence of the extensor and long flexor of the thumb, or abnormal connections between these, the pollex abductus and the base of the first metacarpal. Manske divided this type as follows. IIIA: presence of the base of the metacarpal, and therefore with a stable carpometacarpal joint; and IIIB: absence of the base of the metacarpal joint, with an unstable metacarpophalangeal joint.

*Type IV:* floating thumb, without bone or tendon structures connecting the thumb to the hand.

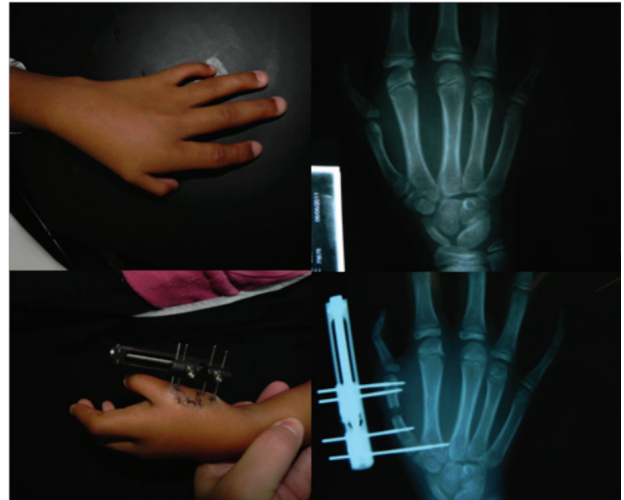*Type V:* complete absence of the thumb.

Conservative treatment should be recommended only for type I thumbs with pincer function and grip preserved.<sup>30,31</sup> Type I, with functional deficits, and types II and IIIA should be reconstructed.<sup>15,30,31</sup> The surgical procedures involved in reconstruction of the thumb include:

- bone stretching (Fig. 19);
- opponensplasty: superficial flexor of the fourth finger or abductor of the fifth finger;
- zetaplasty of the first commissure;
- reconstruction of the ulnar collateral ligament;
- tendon transfers: extensor proprius of the index finger to the long extensor of the thumb; superficial flexor of the fourth finger to the long flexor of the thumb.

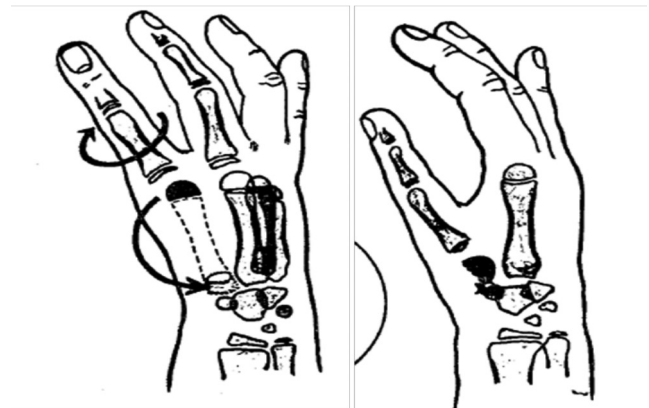
The main surgical indication for types IIIB, IV and V consists of pollicization of the second finger.<sup>15,30-32</sup> For type IIIB, there are surgical options consisting of creation of bone bridges between the first and second metacarpals, with the aim of stabilizing the thumb. Microsurgical transfers for reconstruction of the thumb have been described in case reports, but there is still room for discussion because of the inconstancy of the vessels and receptor structures.<sup>15,30,31,33</sup>

Pollicization is still the preferred treatment for hypoplasia of the thumb, from type IIIB onwards. This was described by Buck-Gramcko and has the aims of providing digital pincer capability, cosmetic improvement and the ability to grasp large objects.<sup>15,32</sup> The presence of an index finger without abnormalities is fundamental for indicating pollicization, since the greater its stiffness is, the worse the digital pincer function will be.<sup>15</sup>



**Fig. 19 - Stretching of first metacarpal. Type II hypoplastic thumb.**

The Buck-Gramcko technique (Fig. 20) enables construction of skin flaps, resection of the diaphysis of the second metacarpal, protection of the venous drainage, release of the radial digital artery of the third finger, maximum extension and fixation of the metacarpal head on its base at 45° of abduction and 100° of pronation.<sup>30,32</sup> The new tendon functions recommended by Buck-Gramcko are as follows: the common extensor of the fingers goes to the long extensor of the thumb; the extensor proprius of the index finger goes to the long abductor of the thumbs; the first interosseous palmar tendon goes to the adductor of the thumb; and the first interosseous dorsal tendon goes to the short abductor of the thumb (Figs. 21 and 22). There is no need for shortening of the extrinsic tendons.<sup>30</sup>



**Fig. 20 - Buck-Gramcko pollicization method.<sup>31</sup>**

**II.5A 4 Absence of extensors**

This is a rare deformity that can be presented as:

Absence of extensors of one finger, generally the proximal interphalangeal;

Absence of extensors from all the fingers.

In these cases, tendon transfers are indicated, after the age of five years, because of the size of the tendons. So far, surgery is recommendable, with use of orthoses.<sup>10</sup>

**II.5A 5 Thumb adduction contracture**

This is generally associated with other symptoms. Thumbs with adduction contracture are divided as follows:<sup>30</sup>

Type I: thumb is generally flexible and condition occurs through absence or hypoplasia of the extensor tendon;

Type II: thumb is stiff; there are associations with joint malformations, the thenar musculature and insufficiency of the first commissure;

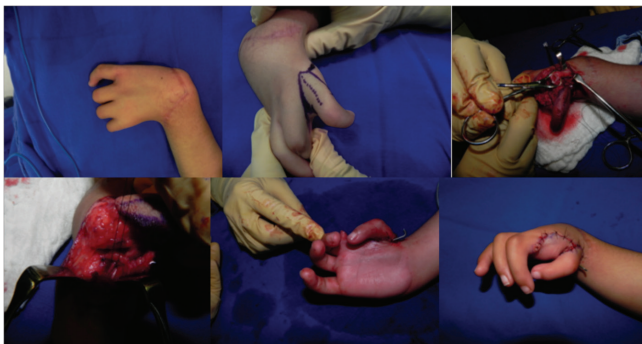Type III: association with arthrogryposis, without alteration of the extensor tendon.

Initial use of orthoses is recommended. For type I thumbs, tendon transfers after the age of two years, with prior conservative treatment, is recommended.<sup>30</sup>

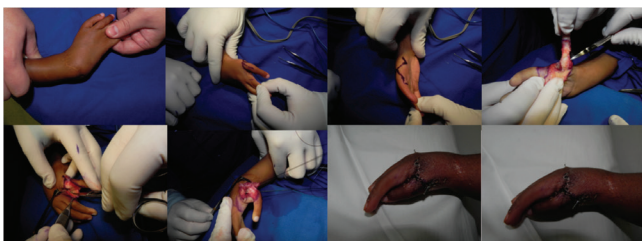
The surgical treatment for types II and III will be covered in the section on arthrogryposis.

**II.5A 6 Camptodactyly**

This is defined as a painless and progressive non-traumatic contracture of the proximal interphalangeal.<sup>29,34</sup> It affects



**Fig. 21 - Pollicization.**



**Fig. 22 - Pollicization. Note interosseous repair for transfer.**

around 1% of the population and the great majority of the cases are extremely mild and asymptomatic.<sup>29,34</sup>

There are three types of camptodactyly:

Type I: child or congenital form; this is the classic form of camptodactyly, which affects one or both of the fifth fingers, without any difference between males and females.

Type II: adolescent form; more frequent in women and generally evolves to severe contractures.

Type III: the most severe form, associated with systemic syndromes.

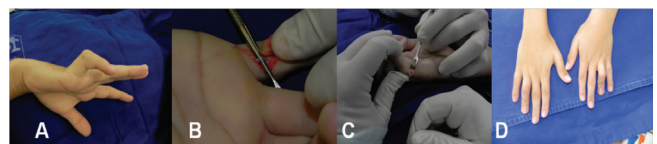
The cause of the contracture is controversial. There have been descriptions of malformations of the superficial flexor of the fingers, lumbrical muscles and the transverse and oblique retinacular ligaments.<sup>34</sup> There may also be alterations to the configurations of the proximal interphalangeal joint.

The following are differential diagnoses with camptodactyly: pterygium syndrome, arthrogryposis, symphalangism, boutonniere lesion, Marfan syndrome, absence of extensor tendons, etc.<sup>34</sup>

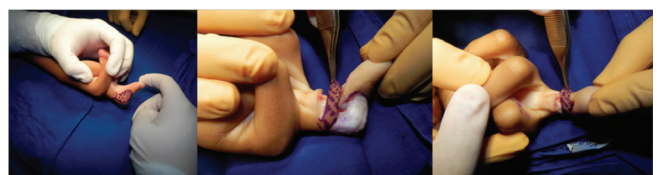
The treatment for type I is conservative, with orthoses and manipulation. Some authors have believed that a few degrees of flexion of the proximal interphalangeal joint are beneficial for grasping objects, particularly in the fourth and fifth fingers.<sup>29,34</sup>

For types II and III the following have been described: osteotomy of the proximal phalangeal extensor;<sup>10</sup> tenoplasty or reconstruction of the extensor tendon;<sup>34</sup> resection of the anomalous lumbrical;<sup>29,34</sup> transfer of the superficial flexor of the fingers to be an extensor<sup>29,34</sup> (Fig 23); and arthrodesis of the proximal interphalangeal joint.<sup>34</sup> Skin flaps can be used for reconstructing severe contractures<sup>35</sup> (Fig 24).

The results are very variable, but joint stiffness of different degrees is common.<sup>29,34</sup>



**Fig. 23 - Camptodactyly. Transfer of flexor digitorum superficialis to extensor and lateral flap: before operation (A); during operation (B, C); after operation, note the difference between the operated and non-operated sides (D)..**



**Fig. 24 - Detail of lateral flap.**

### II.5A 7 Ulnar deviation of the fingers

This is present from the time of birth and is characterized by progressive flexed contracture of the metacarpophalangeal joint and ulnar deviation of the fingers. There is an association with thumb adduction contracture. The initial treatment should consist of use of an orthosis until surgical treatment becomes possible. Zetaplasty, skin grafting, capsuloplasty and tendon realignment are used.<sup>10</sup>

### II.5B Skeletal

#### II.5B 1 Clinodactyly and delta phalange

The term clinodactyly refers to radioulnar deformity of the phalanges, with angular deviation, distally to the metacarpophalangeal joint.<sup>27,29</sup> It may or may not be associated with systemic syndromes. It is more common than camptodactyly and its incidence in the population ranges from 1 to 20%.<sup>3,27,29</sup> It typically affects the middle phalange of the fifth finger with deviation of up to 10°.<sup>3</sup> The physiopathology of the deformity is based on a C-shaped abnormality of the epiphysis of the middle phalange.<sup>3,27,29</sup>

Most cases of clinodactyly do not require treatment, or orthoses because of their lack of efficacy.<sup>3</sup> In cases of severe deformity, partial epiphysiodesis or osteotomy are indicated to correct the angular deviation.<sup>27,29</sup>

The presence of abnormal phalanges of triangular shape, called delta phalanges, is associated with severe angular deformities, although delta phalanges may not produce angular deformities in some cases.<sup>27</sup>

When a delta phalange is associated with angular deformity, surgical treatment is indicated. Opening or closing-wedge osteotomy and partial epiphysiodesis are indicated<sup>27</sup> (Fig. 25). Resection of the delta phalange is indicated in children up to the age of four years (Fig. 26). Above this age, there is a risk of finger instability.

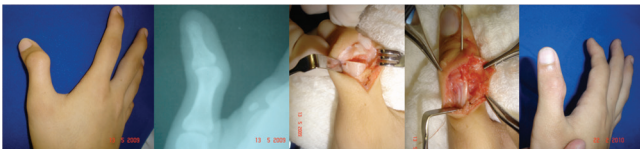

Fig. 25 - Clinodactyly. Wedge osteotomy for closure and realignment of extensor tendon.

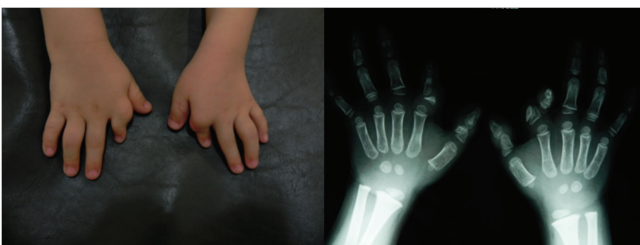

Fig. 26 - "Delta" phalange associated with hypoplasia of the second finger, bilaterally. Right side operated with osteotomy of the "delta" phalange.

#### II.5B 2 Kirner deformity

This is characterized by volar-radial deviation of the distal interphalangeal joint of the fifth finger.<sup>27</sup> It affects between 0.15 and 0.25% of the population, and is twice as common among women. It commonly first appears during adolescence. It is attributed to non-traumatic alterations during the growth phase.<sup>27</sup>

It rarely affects hand function, and treatment is only rarely necessary. For conservative treatment, orthoses can be put in place when it is observed at an early age, before the growth spurt of puberty. Surgery is more indicated in relation to the appearance of the finger, and can be done by means of partial osteotomy of the distal phalange.<sup>27</sup> Indications for surgical treatment are exceptional and should be exhaustively discussed with the patient.

### III Duplication failure

#### III.1 Thumb

Pre-axial (radial) polydactyly occurs more frequently in whites and is unilateral, sporadic and not associated with systemic syndromes in the great majority of the cases.<sup>29</sup> It is considered to be the second most common congenital deformity, occurring in 1:3,000 live births.<sup>35</sup> Some authors have taken the view that this deformity is not a duplication, since neither of the thumbs is normal, and have preferred to name them half-thumbs.<sup>29,36</sup> Wassel's classification is the best-known system.<sup>29,35,36</sup> (Fig. 27).

The principle of the treatment is to provide a single thumb of adequate volume, without nail deformities, which is mobile and stable.<sup>40</sup> Simple resection of the duplicate thumb is reserved solely for cases in which this duplication is a floating thumb.<sup>29,35,36</sup>

Reconstruction techniques:

a) Tendon and ligament reinsertions. In duplications at the level of the joints, the collateral ligaments are inserted in different phalanges. The long abductor of the thumb and the short flexor of the thumb are inserted in the radial phalanges. The extensor tendons tend to be inserted eccentrically.<sup>35</sup>

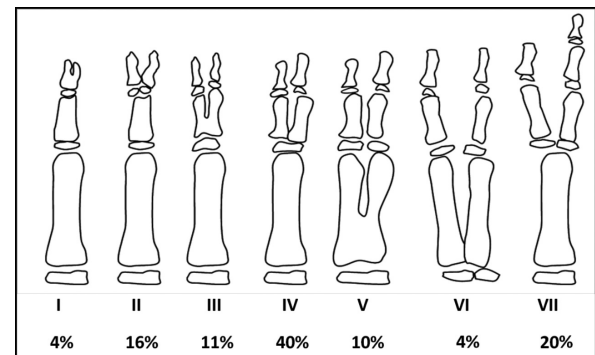


Fig. 27 - Wassel's classification<sup>36</sup> and incidence of each type.<sup>35</sup>



b) Osteotomy, in order to maintain the normal axis of the thumb, particularly in asymmetrical thumbs, in which the smaller one tends to cause angular deformity in the larger one<sup>36</sup> (Fig. 28).

c) Joint realignment in cases of two epiphyses.<sup>36</sup>

In thumbs in which there is clear asymmetry, the preferred treatment consists of resection of the more hypoplastic thumb, which in most cases is the radial thumb, followed by ligament and tendon reconstruction<sup>29,35,36</sup> (Fig. 29).

In situations of symmetrical thumbs, the Bilhaut-Cloquet procedure and its variations has been described. This was first described for types I and II, but can also be used for types III, IV and V<sup>29,35-37</sup> (Figs. 30 and 31).

Classically, this consists of wedge osteotomy, performed symmetrically on the two thumbs, with central resection and suturing of the lateral edges. Thumbs of adequate size and good alignment are obtained, but growth plate lesions and nail deformities are common. For this reason, variations of the technique have been described with the aim of diminishing these problems.<sup>36-39</sup>

To treat type VI thumbs and some special situations, "on-top-plasty" has been described. In this, the distal portion of one thumb is transposed to the base of the other.<sup>39,40</sup> This procedure is done by dissecting a vascular pedicle from the distal portion that is to be transferred.

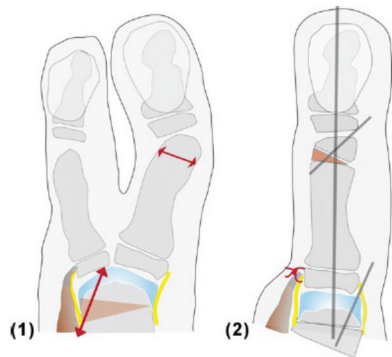


Fig. 28 - Ligament reconstruction scheme, with or without osteotomy and joint realignment.<sup>36</sup>

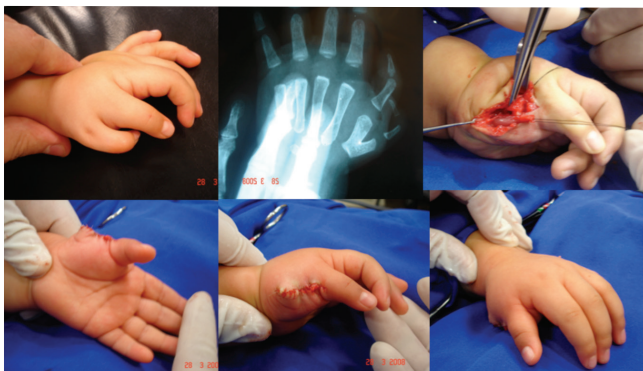

Fig. 29 - Type V duplicated thumb. Resection of hypoplastic thumb with reinsertion of ligament and long abductor of the thumb.

**Type VII duplicate thumbs and triphalangism**

Triphalangeal thumbs may arise in isolation, or in association with duplication of the thumb (type VII), or in association with systemic syndromes.<sup>29</sup> They are divided into two distinct group. In the first group, there is a thumb that resembles a normal one, but with an extra phalange, which may vary in shape: rectangular, trapezoid or delta. In the second group, there is a fifth finger aligned with the others, which in reality is a probably duplication of the second finger, in the absence of the thumb, without any opposing function.<sup>29</sup>

For triphalangeal thumbs in the first group, the treatment varies according to whether angular deviation is present and according to thumb length. Osteotomy, resection or shortening of anomalous phalanges (Fig. 32), reconstruction of the first commissure and tendon realignments are indicated, according to each case. For thumbs in the

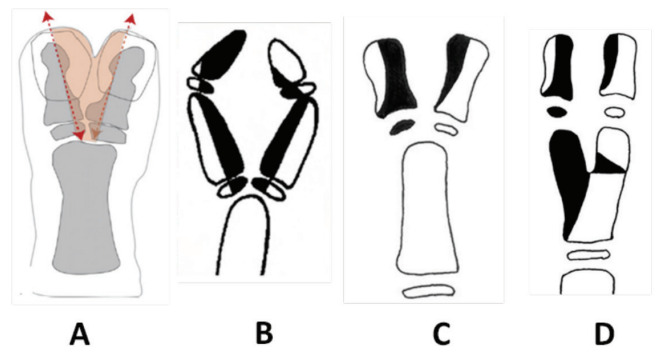


Fig. 30 - Bilhaut-Cloquet: classic (A) and variations (B, C, D).<sup>36,38-43</sup>

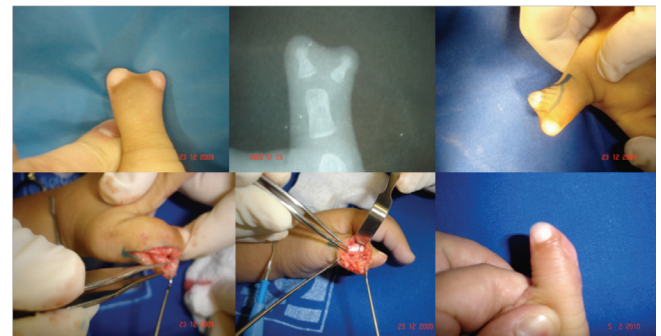


Fig. 31 - Modified Bilhaut-Cloquet.

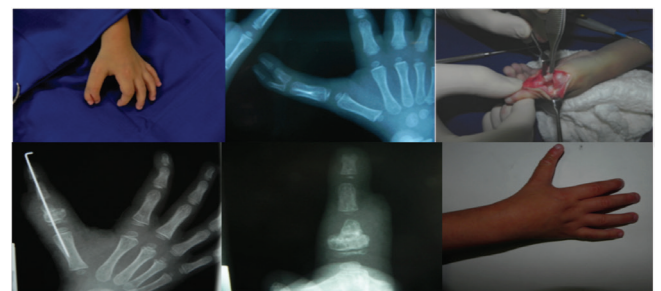


Fig. 32 - Triphalangeal duplicated thumb. This case underwent resection of the radial thumb, ligament realignment and partial resection of the proximal phalange.

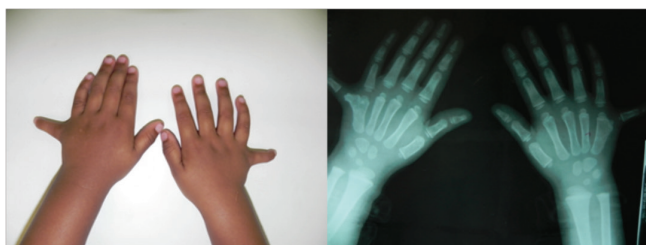second group, pollicization of these fingers and possibly opponensplasty are indicated.<sup>29</sup>

In cases of duplication of type VII thumbs, the choice of which thumb to keep is not directly related to the presence of triphalangism but, rather, to assessment of which thumb is more functional. The triphalangeal thumb may indeed be retained and reconstructed.<sup>36</sup>

### III.2 Ulnar

Postaxial duplications are more common in blacks and generally consist of isolated congenital deformities.<sup>35</sup> They can be divided into two groups: in the first, there is true duplication; and in the second, there is a rudimentary bud of a finger, which can even be tied off after birth, so that it undergoes necrosis and falls off, painlessly for the patient.<sup>3</sup>

In the great majority of cases, simple resection of the extraneous finger is sufficient (Fig. 33).



**Fig. 33 - Ulnar duplication.**

### III.4 Central duplications

These are duplications of the second, third and fourth fingers and are very rare in comparison with radial and ulnar duplications.<sup>35</sup> Their treatment varies greatly, from reconstructions to amputations of the radius. Individual assessment of each case is required.<sup>35</sup>

### III.5 Mirror hand

This is perhaps the greatest example of duplication and is characterized by ulnar dimyelia, in which there is duplication of the ulna, absence of the radius and thumb and duplication of the ulnar fingers. It has variations that may reach duplication of the hand.<sup>35</sup>

It is extremely rare and its treatment consists of creating a hand of acceptable and functional esthetic appearance. Resection of the fingers and reconstruction of the thumb are the initial guidelines.<sup>35</sup>

### Conflicts of interest

The authors declare that there was no conflict of interests in conducting this study.

### R E F E R E N C E S

3. Kozin SH. Upper-extremity congenital anomalies. *J Bone Joint Surg Am.* 2003;85-A(8):1564-1576.
10. Mattar Jr, R. Deformidades congênitas do membro superior. *Acta Ortop Bras.* 1995;3(2):77-92.
14. James M, Bednar M. Deformities of the wrist and forearm. In: Green DP, Pederson MD, Hotchkiss RN, Wolf SW (Eds). *Green's operative hand surgery.* 5<sup>a</sup> ed. Philadelphia: Elsevier Churchill Livingstone; 2005. p. 1469-79.
15. Manske PR, Goldfarb CA. Congenital failure of formation of the upper limb. In: *Congenital hand differences.* *Hand Clin.* 2009;25(2):157-70.
25. Kozin SH. Congenital differences about the elbow. In: *Congenital hand differences.* *Hand Clin.* 2009;25(2):277-91.
26. Tonkin MA. Failure of differentiation Part I: Syndactyly. In: *Congenital hand differences.* *Hand Clin.* 2009;25(2):171-93.
27. Kay SP, McCombe D, Kozin SH. Deformities of the hand and the fingers. In: Green DP, Pederson MD, Hotchkiss RN, Wolf SW (Eds). *Green's operative hand surgery.* 5<sup>a</sup> ed. Philadelphia: Elsevier Churchill Livingstone; 2005. p. 1381-444.
28. Shevtsov VI, Danilkin MY. Application of external fixation for management of hand syndactyly. *Intern Orthop.* 2008;32(4):535-9.
29. Kozin SH. Deformities of the thumb. In: Green DP, Pederson MD, Hotchkiss RN, Wolf SW (Eds). *Green's operative hand surgery.* 5<sup>a</sup> ed. Philadelphia: Elsevier Churchill Livingstone; 2005. p. 1445-68.
30. Katarincic JA. Congenital disorders: hypoplastic thumb. In: Berger RA, Weiss APC (Eds). *Hand surgery.* Philadelphia: Lippincott Williams & Williams; 2004. p. 1445-51.
31. Buck-Gramcko D. Pollicization of the index finger. *J Bone Joint Surg.* 1971;53-A(8):1605-16.
32. Shibata M, Yoshizu T, Seki T, Goto M, Saito H, Tajima T. Reconstruction of a congenital hypoplastic thumb with use of a free vascularized metatarsophalangeal Joint. *J Bone Joint Surg.* 1998;80-A(10):1469-76.
33. Kozin SH, Kay SP, Griffin JR, Ezaki M. Congenital contracture. In: Green DP, Pederson MD, Hotchkiss RN, Wolf SW (Eds). *Green's operative hand surgery.* 5<sup>a</sup> ed. Philadelphia: Elsevier Churchill Livingstone; 2005. p. 1507-26.
34. Ulkür E, Acikel C, Karagoz H, Celikoz B. Treatment of severely contracted fingers with combined use of cross-finger and side finger transposition flaps. *Plast Reconstr Surg.* 2005;116(6):1709-14.
35. Watt AJ, Chung KC. Duplication. In: *Congenital hand differences.* *Hand Clin.* 2009;25(2):215-27.
36. Dautel G, Barbary S. Duplications du pouce. *Chir main.* 2008;27(Suppl 1):S82-99. Epub 2008 Aug 22.:82-99.
37. Tonkin MA, Bulstrode NW. The Bilhaut-Cloquet procedure for wassel types III, IV, and VII thumb duplication. *J Hand Surg Eur Vol.* 2007;32E(6):684-93.
38. Abid A, Knorr G, Darodes P, Cahuzac JP, Sales de Gauzy J. Type IV-D thumb duplication: a new reconstruction method. *Orthop Traumatol Surg Res.* 2010;96(5):521-4.
39. Baek GH, Gong HS, Chung MS, Oh JH, Lee YH, Lee SK. Modified Bilhaut-Cloquet procedure for wassel type-ii and iii polydactyly of the thumb. *J Bone Joint Surg.* 2007;89-A(3):534-41.
40. Carty MT, Taghinia A, Uton J. Overgrowth conditions: a diagnostic and therapeutic conundrum. In: *Congenital hand differences.* *Hand Clin.* 2009;25(2):229-45.
41. Nguyen ML, Jones NF. Undergrowth: brachydactyly. In: *Congenital hand differences.* *Hand Clin.* 2009;25(2):247-55.
42. Samson P, Mevio G. Symbrachydactylie. *Chir Main.* 2008;27(Suppl 1):S229-45.
43. Kawamura K, Chung KC. Constriction band syndrome. In: *Congenital hand differences.* *Hand Clin.* 2009;25(2):257-63.