

# Ilizarov Technique with Proximal Femoral and Triple Pelvic Osteotomy for the Treatment of Adolescent Developmental Dysplasia of the Hip\*

## *Técnica de Ilizarov nas osteotomias do fêmur proximal e pélvica tripla para o tratamento da displasia do desenvolvimento do quadril em adolescentes*

Mikhail Teplenky<sup>1</sup> Waleed Mekki<sup>1</sup>  Evgenii Oleinikov<sup>1</sup>

<sup>1</sup>Department of Pediatric Orthopedics No. 11, Russian Ilizarov Scientific Center for Restorative Traumatology and Orthopedics, Kurgan, Russia

Address for correspondence Waleed Mekki, MBBS, MSC, MD, Department of Pediatric Orthopedics No. 11, Russian Ilizarov Scientific Center for Restorative Traumatology and Orthopaedics, 6, M. Ulyanova Street, Kurgan, 640014, Russia (e-mail: waleedmekki@excite.com).

Rev Bras Ortop 2020;55(2):232–238.

### Abstract

**Objective** The significance of pelvic osteotomies in developed coxarthrosis is still disputable. Some authors believe that incongruence and early osteoarthritis of the articular surfaces are contraindications for joint-preserving surgery and will stimulate further progression. The opposite view is that triple pelvic osteotomy can be an alternative to early joint replacement. The present study reports the mid to long term results of adolescent patients with developed coxarthrosis treated by proximal femoral and triple pelvic osteotomies and fixed by the Ilizarov technique.

**Methods** A retrospective review between 2002 and 2014 of the treatment of 26 patients with coxarthrosis due to developmental dysplasia of the hip (DDH). The sample was composed of 22 female and 4 male subjects with a mean age at operation of 14.7 years (range: 12–18 years) and mean follow-up of 5.9 years (range: 3–13 years).

**Results** The initial functional results according to the Merle d'Aubigné and Postel criteria were: pain –  $4.3 \pm 0.05$  points; range of motion –  $3.6 \pm 0.3$  points; and gait –  $4 \pm 0.15$  points. The average index of the weight bearing zone (WBZ) was of  $38.7^\circ \pm 2.721^\circ$ . The acetabular coefficient (AC) was of  $162 \pm 6.8$ , the center–edge angle (CEA) of Wiberg was of  $3^\circ \pm 0.2^\circ$ . The outcomes were followed up from 3 to 13 years. At the final follow-up, the radiographic outcomes showed that the value of the WBZ decreased to  $8.2^\circ \pm 1.293^\circ$  ( $0$ – $15^\circ$ ), and that the AC increased to  $249 \pm 12.05$ . The average neck–shaft angle (NSA) was of  $115^\circ \pm 4^\circ$ , the articulo-trochanteric distance (ATD) was of  $8,5 \pm 1,5$  mm, and the CEA of Wiberg was of  $28^\circ \pm 1.6^\circ$  at the final follow-up. The distribution of the joints according to Tönnis et al was: grade I – 17 joints; grade II – 8 joints; and grade III – 1 joint. The outcomes were good for 14 patients (54%), fair for 10 patients (34.5%), and poor for 2 (11.5%) patients.

### Keywords

- ▶ hip dysplasia
- ▶ hip osteoarthritis
- ▶ osteotomy
- ▶ adolescent

\* Study conducted at the Department of Pediatric Orthopedics, Russian Ilizarov Scientific Center for Restorative Traumatology and Orthopedics, Kurgan, Russia.

**Conclusion** The treatment of adolescent hip dysplasia requires a proper assessment of the degree of dysplasia and the surgery needed to redirect pelvic components to achieve suitable conditions for hip remodeling, and our mid- to long-term results showed very good outcomes when applying these principles using the Ilizarov technique.

## Resumo

**Objetivo** A importância das osteotomias pélvicas na coxartrose desenvolvida ainda é discutível. Alguns autores acreditam que a incongruência e a osteoartrite inicial das superfícies articulares são contraindicação para a cirurgia de preservação articular e estimularão maior progressão. A visão oposta é a de que a osteotomia pélvica tripla pode ser uma alternativa à substituição articular precoce. Este estudo relata resultados de médio a longo prazo de pacientes adolescentes com coxartrose desenvolvida, tratados por osteotomias proximais do fêmur e pélvica tripla, fixados pela técnica de Ilizarov.

**Métodos** Revisão retrospectiva entre 2002 e 2014 do tratamento de 26 pacientes com coxartrose devido a displasia do desenvolvimento do quadril. A amostra continha 22 mulheres e 4 homens. A idade média na operação foi de 14,7 anos (variação: 12–18 anos), e o acompanhamento médio foi de 5,9 anos (variação: 3–13).

**Resultados** Os resultados funcionais iniciais de acordo com o método de Merle d'Aubigné e Postel foram: dor –  $4,3 \pm 0,05$  pontos; mobilidade –  $3,6 \pm 0,3$  pontos; e marcha –  $4 \pm 0,15$  pontos. O valor médio do índice da zona de carga (ZC) foi  $38,7^\circ \pm 2,721^\circ$ . O coeficiente acetabular (CA) foi de  $162 \pm 6,8$ , e o ângulo centro-borda (ACB) de Wiberg foi de  $3^\circ \pm 0,2^\circ$ . Os resultados foram acompanhados por 3 a 13 anos. No acompanhamento final, os resultados radiográficos mostraram que o valor do índice da ZC diminuiu para  $8,2 \pm 1,293^\circ$  ( $0^\circ$ – $15^\circ$ ), e o CA aumentou para  $249 \pm 12,05$ . A média do ângulo cervicodiafisário (ACD) foi  $115^\circ \pm 4^\circ$ , a distância articulo-trocantérica (DAT) foi de  $8,5 \pm 1,5$  mm, e o ACB de Wiberg foi  $28^\circ \pm 1,6^\circ$  no acompanhamento final. A distribuição das articulações segundo Tönnis et al foi: grau I – 17 articulações; grau II – 8 articulações; e grau III – 1 articulação. O resultado foi bom em 14 pacientes (54%), razoável em 10 pacientes (34,5%), e ruim em 2 (11,5%).

## Palavras-chave

- ▶ displasia do quadril
- ▶ osteoartrite do quadril
- ▶ osteotomia
- ▶ adolescente

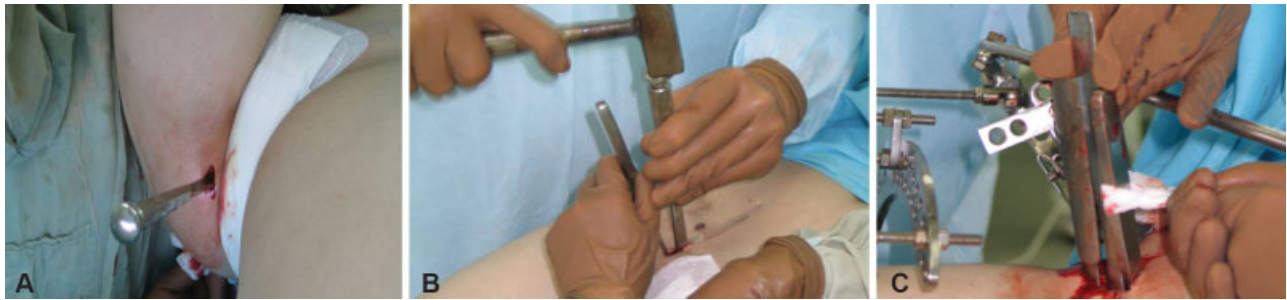**Conclusão** O tratamento da displasia do quadril na adolescência requer uma avaliação adequada do grau de displasia e a cirurgia necessária para reorientar os componentes pélvicos com o objetivo de alcançar condições adequadas para a remodelação do quadril. Nossos resultados de médio a longo prazo mostraram desfechos muito bons ao aplicarmos esses princípios usando a técnica de Ilizarov.

## Introduction

Redirecting triple pelvic and other osteotomies around the hip gained popularity long ago with the aim of decreasing or preventing further progression of congenital dysplastic hip osteoarthritis; these procedures also have successful short-, mid- and long-term results in terms of symptom relief for most patients, but a small proportion of patients does not show any improvement, and an even smaller proportion shows progression of their symptoms despite the operative intervention.<sup>1–12</sup>

Incongruence and early osteoarthritic symptoms of the articular surfaces are considered by some authors as negative predictors for joint preserving surgery.<sup>9,13</sup> The opposite

point of view is that triple pelvic osteotomy can be an alternative to the early joint-replacement surgery.<sup>12,14</sup> The increase in the contact area between the congruent head and the acetabulum can promote remodeling of the degenerating cartilage.<sup>10</sup> Some authors<sup>8</sup> believe that technical complexity and corrective potentials are correlated. However, triple pelvic osteotomy is a reliable method to reconstruct residual acetabular dysplasia, and it promotes future pelvic remodeling and femoral head containment in young and adolescent patients.<sup>15</sup> With over 25 years of experience using the Ilizarov technique for hip reconstruction in children, we report our mid- to long-term results regarding hip reconstruction in adolescents with dysplastic hips due to developmental dysplasia.



**Fig. 1** Steel<sup>18</sup> triple osteotomy. (A) Ischial bone osteotomy. (B) Pubic bone osteotomy. (C) Iliac bone osteotomy.

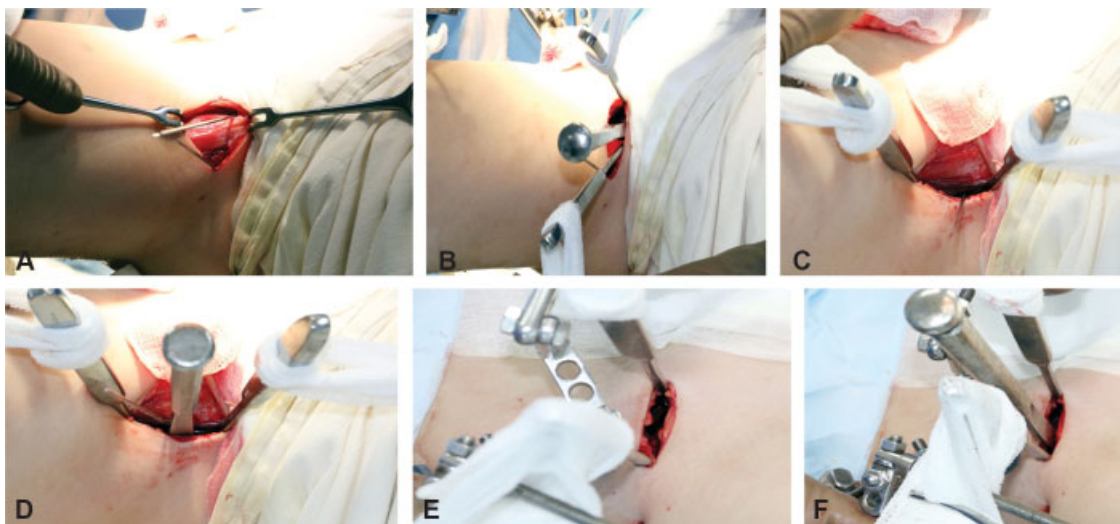
## Materials and Methods

Between 2002 and 2014, with the approval of our Institutional Review Board (IRB) and Ethical Committee, the results of the treatment of 26 patients with dysplastic coxarthrosis were analyzed. The mean age at the intervention was 14.7 years (range: 12–18 years). The sample was composed of 22 female and 4 male patients. The mean follow-up was 5.9 years (range: 3–13). Our inclusion criteria were: 1) patients aged > 12 and < 19 years; 2) with grades I or II of developmental dysplasia of the hip (DDH) according to Tönnis et al<sup>16</sup>; 3) with grades II, III and IV of articular congruence according to the Coleman criteria; and 4) follow-up period  $\geq$  3 years. The exclusion criteria were: 1) patients aged < 12 and > 19 years; 2) with grades 0 and II of DDH according to Tönnis et al<sup>16</sup>; 3) with grade I of articular congruence according to Coleman; and 4) dysplastic hips with causes other than DDH.

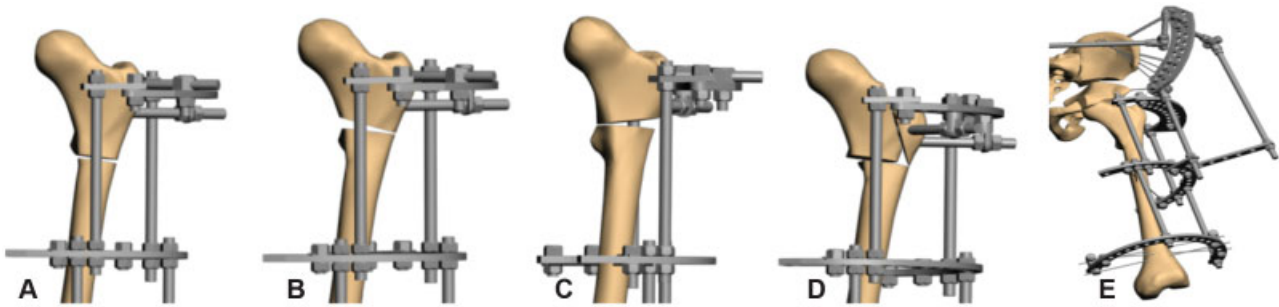
The clinical history and examination, in addition to plain pelvic radiographs, were used for the preoperative diagnosis and to follow up on the functional results. The clinical outcome was assessed using the Merle d'Aubigné and Postel<sup>17</sup> criteria, and the radiographic improvement, by the Severin criteria. The qualitative assessment of the condition of the hip was made in accordance with the criteria by Tönnis et al<sup>16</sup> and Coleman. The radiographs of the hip joint analyzed were performed in

anteroposterior and profile projections before the operation, during the treatment, and all throughout the follow-up period. Manual drawing on X-rays was used to assess the radiographic parameters. The following radiographic parameters were calculated: index of the weight bearing zone (WBZ); acetabular coefficient (AC); neck–shaft angle (NSA); artculo–trochanteric distance (ATD); center–edge angle (CEA) of Wiberg; vertical–center–anterior (VCA) angle; and the migration index (MI).

All of the patients underwent extra-articular hip reconstruction with the Ilizarov apparatus for correction of the acetabular dysplasia, and pelvic osteotomies such as those described by Carliz et al<sup>1</sup> and Steel<sup>18</sup> were performed ( $\rightarrow$  Fig. 1 and 2). In six cases, the pelvic osteotomy was supplemented with incomplete periacetabular osteotomy to change the shape of the cavity arch. We performed pelvic osteotomies in all of the 26 study patients. As well as the pelvic correction, correction of the proximal femur deformity was performed in 22 cases, the details of which are as follows: in 5 cases we performed detorsion osteotomy; in 8 cases, varus derotation osteotomy; in 4 cases, valgus derotation osteotomy; and, in 5 cases, double transtrochanteric osteotomy ( $\rightarrow$  Fig. 3). The remaining four cases were only submitted to pelvic osteotomies. The Ilizarov apparatus was used to fix the osteotomized fragments. Over the course of the treatment, supportive distraction between the



**Fig. 2** Carliz et al<sup>1</sup> osteotomy. (A, B) Pubic bone osteotomy. (C, D) Ischial bone osteotomy. (E, F) Iliac bone osteotomy.



**Fig. 3** Techniques for reconstruction of the femoral and pelvic components of the hip. (A) Detorsion subtrochanteric osteotomy. (B) Valgus derotation subtrochanteric osteotomy. (C) Varus derotation subtrochanteric osteotomy. (D) Double transtrochanteric osteotomy. (E) Pelvic osteotomy connected to the frame.

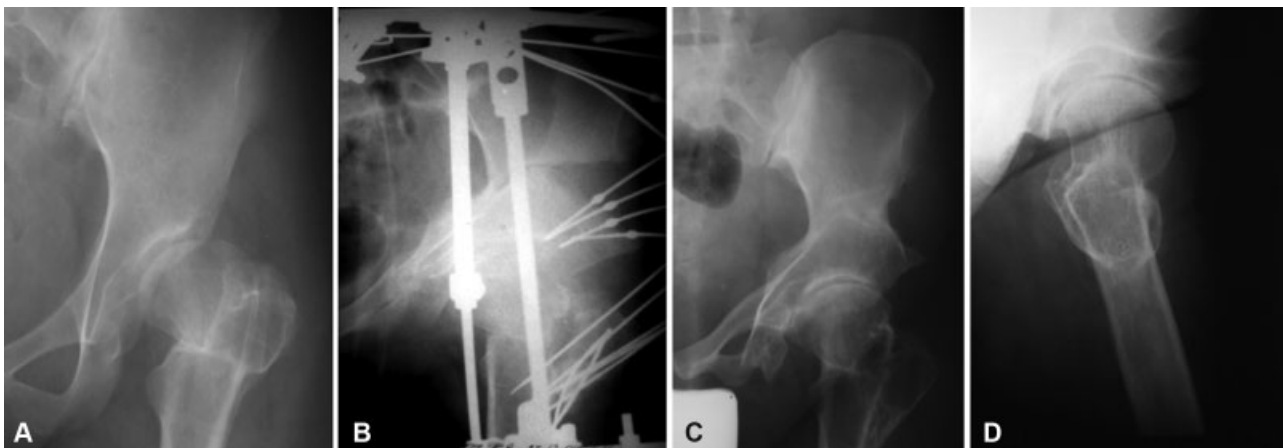
articular surfaces was performed to provide a mode of decompression.

The radiographic results were analyzed using the Microsoft Excel 2007 (Microsoft Corp., Redmond WA, US) software. The angles and other parameters were calculated as means  $\pm$  standard deviations, and the *p*-value of statistical significance was calculated using data dispersion, and the Student *t*-test. Values of *p* < 0.05 were considered significant. Consent was taken from the patients or their guardians for the purpose of the study without personal identification.

### Surgical Technique

In the operating room under general anesthesia, 5 Kirschner wires (k-wires) with olives are passed through the iliac wing, at least one of them in the opposite direction, and another 4 k-wires are passed to the distal femoral metaphysis. All wires are then connected to the Ilizarov apparatus by arches that are joined together by rods (**Fig. 3**). Using the Steel<sup>18</sup> method (**Fig. 1a-c**), we perform a longitudinal incision of 3–4 cm laterally from the ischial tuberosity to osteotomize the ischium, an incision of 2–3 cm medial to the neurovascular bundle, and, below the inguinal ligament, we perform a pubic osteotomy and a 3–4-cm incision above the anterior superior iliac spine to

perform an iliac osteotomy. After mobilizing the fragments in a favorable position for anterolateral head coverage, the acetabular fragment is fixed to the pelvic frame by means of wires or Schanz screws (**Fig. 4**) in the supra-acetabular region. If the Carlioz et al<sup>1</sup> technique is used, an incision of 5–6 cm on the inner surface of the thigh is made 1 cm distal to the inguinal fold, and, between the adductor longus and pectineus muscles, we perform a blunt dissection to reach the pubic bone and perform an osteotomy (**Fig. 2a,b**). Then, through the same incision and between the adductor longus and magnus muscles, we reach the sciatic bone to perform a transverse osteotomy distal to the sciatic spine (**Fig. 2c,d**). Osteotomy of the ilium and acetabular coverage are performed just as in the Steel<sup>18</sup> osteotomy. If necessary, an incomplete periacetabular osteotomy can be performed by making a 5–6 cm incision along the inguinal crease between the origins of the sartorius and tensor fasciae latae muscles. Care should be taken not to breach the articular cartilage. The supra-acetabular fragment is then connected to the frame via wires or Schanz pins. Corrective surgery on the femur is performed 2 weeks after the pelvic osteotomy. It is worth noting that, when using the Ilizarov technique, and when the pelvic and femoral osteotomies are performed separately, they become relatively simple and less traumatic interventions. However, simultaneous surgery is



**Fig. 4** 16 year-old female with left dysplastic coxarthrosis. (A) X-ray with grade-I osteoarthritis, Coleman type-II congruence of articular surfaces, weight-bearing zone (WBZ): 28°, acetabular coefficient (AC): 190, center–edge angle (CEA): 5°, vertical-center-anterior (VCA) angle: 5°, and migration index (MI): 32%. (B) Pelvic anteroposterior radiograph of hip reconstruction with closed reduction pelvic triple and double transtrochanteric osteotomies. (C,D) 12-year follow-up anteroposterior and lateral radiographs with femoral head containment and Coleman grade-I congruence, WBZ: 0°, AC: 210, CEA: 30°, VCA angle: 20°, and MI: 0% .

possible, but, in this case the duration and aggressiveness of the operation increases. Therefore, the two-stage treatment is accepted at our center. When performing hip surgery two weeks after pelvic osteotomy, the total period of hardware treatment does not change, as it is determined primarily by the period of consolidation of the pelvic bones. With respect to the studied group, it is also important to mention that in the case of initial incongruence and deformation of the joint components, a two-stage reconstruction significantly facilitates the adaptation of joint surfaces.

## Results

The duration of the treatment was of  $76 \pm 2.2$  days. The duration of the rehabilitation was of  $9 \pm 1.5$  months. The initial functional results in accordance with the Merle d'Aubigné and Postel<sup>17</sup> criteria were: pain –  $4.3 \pm 0.05$  points; range of motion (RoM) –  $3.6 \pm 0.3$  points; and gait –  $4 \pm 0.15$  points. The leading radiographic signs in all of the joints were acetabular dysplasia and subluxation of the femoral head. The average index of the WBZ was of  $38.7^\circ \pm 2.72^\circ$ , and the AC was of  $162 \pm 6.8$ . The CEA of Wiberg was of  $3^\circ \pm 0.2^\circ$ , the VCA was of  $10^\circ \pm 1.5^\circ$ , and the MI was of  $38\% \pm 4.5\%$ . In every case, there was an excessive femoral neck anteversion ( $41.6 \pm 1.24$ ). In 22 cases, various types of proximal femur deformities were observed, which were corrected accordingly (►Fig. 3). In 8 cases, there was valgus deformity of the neck with NSA of  $142.4^\circ \pm 1.44^\circ$ . In 9 cases, there was marked coxa vara, with NSA of  $96.5^\circ \pm 2.344^\circ$ , and shortening of the neck, with ATD of  $9.8 \pm 2.01$  mm. In five cases there was only deviation of the neck in the horizontal plane.

The distribution of joints by the degree of dislocation according to Tönnis et al<sup>16</sup> was: grade I – 10 cases; grade II – 13 cases; and grade III – 3 cases. The grade of coxarthrosis was also assessed according to Tönnis et al<sup>16</sup>: grade I – 16 cases; and grade II – 10 cases. The type of congruence of the articular surfaces was assessed according to Coleman: grade II – 7 cases; grade III – 8 cases; and grade IV – 11 cases.

The outcomes were followed up from 3 to 13 years. The functional results according to Merle d'Aubigné and Postel<sup>17</sup> were: pain –  $4.7 \pm 0.1$  points; RoM –  $4.1 \pm 0.2$  points; and gait –  $4.6 \pm 0.1$  points. According to the radiographic outcomes, the value of the WBZ decreased to  $8.2^\circ \pm 1.293^\circ$ , and the AC increased to  $249 \pm 12.05$ . The average NSA was of  $115^\circ \pm 4^\circ$ , and the ATD,  $8.5 \pm 1.5$  mm. The average reduction indices improved with the CEA of Wiberg of ( $28^\circ \pm 1.6^\circ$ , VCA angle of  $26^\circ \pm 1.5^\circ$ , and MI of  $12.6 \pm 1.5$ ). There was a significant difference between all of the preoperative and postoperative values (►Table 1). The radiographic findings according to the Severin criteria were: grade IIa – 14 cases; grade IIb – 8 cases; and grade III – 4 cases. According to the Coleman criteria, they were: grade I – 6 cases; grade II – 5 cases; grade III – 12 cases; and grade IV – 3 cases. The distribution of the joint according to Tönnis et al<sup>16</sup> was: grade I – 17 joints; grade II – 8 joints; and grade III – 1 joint. There was an improvement in the congruence of the articular surfaces, and at the final follow-up, the grade of arthrosis remained unchanged in 20 cases, had reduced in 4 joints, and had progressed by 1 grade

**Table 1** Radiographic parameters, preoperatively and postoperatively, and last follow-up results

Parameters	Treatment intervals		
	Preoperative	After frame removal	Last follow-up
NSA (°)	$118.5 \pm 3.9$	$121 \pm 1.0^*$	$116 \pm 1.0^*$ $p < 0.05$
AA (°)	$41.6 \pm 1.6$	$15 \pm 0.8^*$ $p < 0.001$	$16 \pm 0.8$
ATD (mm)	$7.2 \pm 2.8$	$13.7 \pm 0.3^*$ $p < 0.05$	$11.5 \pm 0.4^*$
WBZ	$39 \pm 1.6$	$9 \pm 0.7^*$ $p < 0.001$	$8.2 \pm 0.8$
AC	$162 \pm 1.9$	$190 \pm 7.5^*$ $p < 0.01$	$249 \pm 6.6$ $p < 0.01$
CEA (°)	$3 \pm 0.8$	$30.5 \pm 1.4^*$ $p < 0.001$	$28 \pm 1.8$
MI (%)	$38 \pm 1.5$	$8.5 \pm 1.5^*$ $p < 0.001$	$12.6 \pm 1.8$
VCA (°)	$10 \pm 0.7$	$27 \pm 0.8^*$ $p < 0.01$	$26 \pm 0.9$

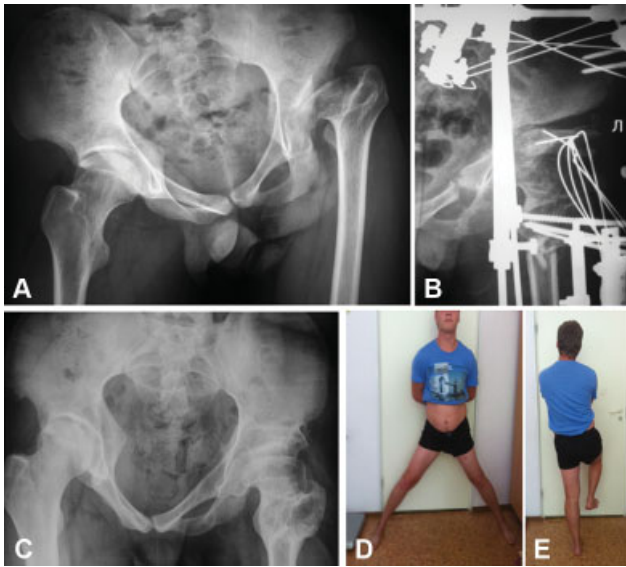
Abbreviations: AA, epiphysis-shaft angle of Alsborg; AC, acetabular coefficient; ATD, articular-trochanteric distance; CEA, center-edge angle; migration index (MI); neck-shaft angle (NSA); VCA, vertical-center-anterior angle; WBZ, weight-bearing zone (WBZ).

Note: \*Statistically significant *p*-value.

in 2 joints. Overall, the outcomes were good for 14 patients (54%), fair for 10 patients (34.5%), and poor for 2 patients (11.5%), which means that positive results with halting of the osteoarthritis progression were observed in 24 patients (88.5%) (►Figs. 4 and 5).

## Discussion

In hip dysplasia, the acetabular component is usually affected, as well as the femoral component, but to a lesser extent. In the shallow acetabulum, the femoral head is lateralized and dislocated with abnormal anatomical ratios of the hip components, disturbed biomechanics and peri-articular muscular and ligamentous contracture.<sup>2,19</sup> The long-term results of many pelvic reorientation osteotomies for symptomatic hip dysplasia are satisfactory.<sup>5,16,18–22</sup> The increase in the contact area between the congruent head and the acetabulum can promote remodeling of the degenerated cartilage.<sup>10</sup> Pelvic osteotomy can even prevent the further development of second-stage coxarthrosis<sup>12,23</sup> and promote its regression.<sup>7</sup> Different pelvic reorientation osteotomy techniques have been studied and compared,<sup>24</sup> including the Bernese periacetabular osteotomy,<sup>25</sup> and some of them enable rotation in unwanted directions and result in inferior outcomes. When comparing the Ganz, Carliz et al<sup>1</sup> and Tönnis et al<sup>16</sup> osteotomies, the Carliz et al<sup>1</sup> osteotomy provided less motion, with predictable displacement of osteotomy fragments in the proposed directions. The Tönnis et al<sup>16</sup> and Ganz osteotomies enabled unrestrained motion in different directions.<sup>24</sup> The Carliz et al<sup>1</sup> osteotomy was used



**Fig. 5** 19 year-old male with left dysplastic coxarthrosis. (A) X-ray with grade-I osteoarthritis and grade-II dislocation, Coleman type-IV incongruence. WBZ: 43°, AC: 160, CEA: 0°, VCA angle: 0°, and MI: 48%. (B) Pelvic anteroposterior radiograph of hip reconstruction with closed reduction pelvic triple and double transtrochanteric osteotomies. (C) 4-year follow-up anteroposterior radiograph with reduction, WBZ: 8°, AC: 210, CEA: 20°, VCA angle: 22°, and MI: 16%. (D, E) Abduction and negative Trendelenburg test.

together with the Steel<sup>18</sup> osteotomy in the present study. Young patients with dysplastic hips due to DDH may benefit from intertrochanteric and pelvic osteotomies to postpone or eliminate the need for total hip replacement (THR).<sup>2,4,6,12,14</sup> The use of the Ilizarov technique for hip dysplasia reduction and fixation of multiple osteotomies at the same time without the need for open reduction and femoral shortening have shown good outcomes, with a lower prevalence of avascular necrosis.<sup>26</sup>

We believe that the age of the patient at the operation plays an important role in the final outcome, with patients who have completed their skeletal maturity having less favorable outcomes. Some studies<sup>2,4,27</sup> were performed with broader age groups, and some of the patients needed conversion to THR earlier. Okano et al<sup>14</sup> showed progression in 11 (25%) patients in their sample; however, the mean age of their patients at the operation was 43.4 years (range: 30–59 years). Average outcomes were observed by Böhm et al,<sup>6</sup> in a study in which mean age of the patients at the operation was 24.8 years (range: 19–35 years); the authors observed average results, with a decrease in the coxarthrosis in 11 hips, no change in 17 hips, and worsening of the condition in 5 hips. In contrast, our sample only included adolescent patients (12–18 years), and resulted in 88.5% of positive outcomes, with worsening only in 2 cases (11.5%); similar results were obtained by other authors,<sup>3,18</sup> who conducted studies with younger samples.

Regarding the degree of preoperative osteoarthritis, in a study performed by Van Hellemond et al<sup>11</sup> (although their significant negative factors for good long-term results were the presence of osteoarthritic changes and a fair or poor preoperative clinical score), the authors reported their

results after triple pelvic osteotomy of 48 hips: 42 (88%) patients with long-term follow-up of 15 years did not have progression of their osteoarthritis, and 27 (64%) patients had good to excellent clinical results. Interestingly, Johnsen et al<sup>22</sup> found that, among the Sâmi population of Norway, a hip with DDH has low predictive value for concurrent radiographic osteoarthritis. Thus, radiographic indices cannot predict the rate at which the hip joint will develop osteoarthritis; however, we believe there is no contraindication per se to perform reorientation pelvic osteotomies in patients with dysplastic radiographic changes. Regarding our choice of osteotomy, we prefer the Carlizot et al<sup>1</sup> technique if a considerable transposition of the acetabulum is required.

Regarding the method of fixation after osteotomy, the conventional methods of fixation are more likely to be strong k-wires or pins and plates, and some authors<sup>4,27,28</sup> have reported a higher incidence of nonunion, which is associated with patient dissatisfaction. In the present study, we did not observe any case of nonunion, probably because of the relative stability of the frame. However, were this to occur, we could still modify the frame and add or remove wires to make the bone fragments more dynamic as needed. Other complications, like infection, bleeding and postoperative pain can be bothersome, and Trousdale et al<sup>4</sup> reported pain related to the hardware that led to its removal in 9 patients (21%) in their series. Regarding the complications observed by us, there were two cases of pin-tract infection (PTI), which were treated with intravenous (IV) cefazolin and frequent dressing changes. We also observed two cases of rapid development of the osteoarthritis during the first two years of follow-up: one patient had overcorrection of the femoral head, but this has been refuted by Klein et al,<sup>15</sup> who found in their study that 33 (80.5%) hips with overcorrection in the 3 planes showed no significant differences when compared with hips with normal parameters. We think the cause was femoroacetabular impingement and narrowing of the joint space, as it appeared on the radiograph. The other patient had under-coverage of the femoral head by osteotomy, which probably played a role in the progression of the osteoarthritis. In our opinion, the advantages of our technique are primarily due to the use of the Ilizarov apparatus, with great versatility of correction and movement of the acetabular fragments, and it is less invasive, and results in lower blood loss, which might be associated with better outcomes.<sup>3,29</sup> The use of the Ilizarov technique also enables early rehabilitation, with the patients being able to walk on the second postoperative day.

The use of the Ilizarov technique for correction and lengthening in hip ischemic deformities has been reported with good mid-term results.<sup>30</sup> However, some patients might be uncomfortable with the bulky frame, but in time they will get used and comfortable with it, focusing on their treatment. Another limitation is that it requires experience on the part of the surgeon with the use of the Ilizarov technique, which takes some time to acquire.

## Conclusion

Application of the Ilizarov technique for reconstructive pelvic surgery due to congenital hip dysplasia in adolescents has proven to be a successful and reliable method. The technique can be an alternative to joint replacement in adolescents and young adults, and it provides sufficient function to the affected joint. Overall, the outcomes in the present study were good for 14 patients (54%), fair for 10 patients (34.5%), and poor for 2 (11.5%) patients, which means that positive results, with halting of the osteoarthritis progression, were observed in 24 patients (88.5%).

### Conflict of Interests

The authors have no conflict of interests to declare.

## References

- Carloz H, Khouri N, Hulin P. [Triple juxtacotyloid osteotomy]. *Rev Chir Orthop Repar Appar Mot* 1982;68(07):497–501
- Haverkamp D, Marti RK. Intertrochanteric osteotomy combined with acetabular shelfplasty in young patients with severe deformity of the femoral head and secondary osteoarthritis. A long-term follow-up study. *J Bone Joint Surg Br* 2005;87(01):25–31
- Lehman WB, Mohaideen A, Madan S, Atar D, Feldman DS, Scher D. Surgical technique for an ‘almost’ percutaneous triple pelvic osteotomy for femoral head coverage in children 6–14 years of age. *J Pediatr Orthop B* 2004;13(01):57–62
- Trousdale RT, Ekkernkamp A, Ganz R, Wallrichs SL. Periacetabular and intertrochanteric osteotomy for the treatment of osteoarthritis in dysplastic hips. *J Bone Joint Surg Am* 1995;77(01):73–85
- de Kleuver M, Kooijman MA, Pavlov PW, Veth RP. Triple osteotomy of the pelvis for acetabular dysplasia: results at 8 to 15 years. *J Bone Joint Surg Br* 1997;79(02):225–229
- Böhm P, Klinger HM, Küsswetter W. The Salter innominate osteotomy for the treatment of developmental dysplasia of the hip in young adults. *Arch Orthop Trauma Surg* 1999;119(3–4):186–189
- Sen C, Sener N, Tozun IR, Boynuk B. Polygonal triple (Kotz) osteotomy in the treatment of acetabular dysplasia: 17 patients (19 hips) with 4–9 years of follow-up. *Acta Orthop Scand* 2003;74(02):127–132
- Gillingham BL, Sanchez AA, Wenger DR. Pelvic osteotomies for the treatment of hip dysplasia in children and young adults. *J Am Acad Orthop Surg* 1999;7(05):325–337
- Søballe K. Pelvic osteotomy for acetabular dysplasia. *Acta Orthop Scand* 2003;74(02):117–118
- Shimogaki K, Yasunaga Y, Ochi M. A histological study of articular cartilage after rotational acetabular osteotomy for hip dysplasia. *J Bone Joint Surg Br* 2005;87(07):1019–1023
- van Hellemond G, Sonneveld H, Schreuder MH, Kooijman MA, de Kleuver M. Triple osteotomy of the pelvis for acetabular dysplasia: results at a mean follow-up of 15 years. *J Bone Joint Surg Br* 2005;87(07):911–915
- Janssen D, Kalchschmidt K, Katthagen BD. Triple pelvic osteotomy as treatment for osteoarthritis secondary to developmental dysplasia of the hip. *Int Orthop* 2009;33(06):1555–1559
- Yasunaga Y, Ochi M, Terayama H, Tanaka R, Yamasaki T, Ishii Y. Rotational acetabular osteotomy for advanced osteoarthritis secondary to dysplasia of the hip. *J Bone Joint Surg Am* 2006;88(09):1915–1919
- Okano K, Enomoto H, Osaki M, Shindo H. Rotational acetabular osteotomy for advanced osteoarthritis secondary to developmental dysplasia of the hip. *J Bone Joint Surg Br* 2008;90(01):23–26
- Klein C, Fontanarosa A, Khouri N, et al. Anterior and lateral overcoverage after triple pelvic osteotomy in childhood for developmental dislocation of the hip with acetabular dysplasia: Frequency, features, and medium-term clinical impact. *Orthop Traumatol Surg Res* 2018;104(03):383–387
- Tönnis D, Arning A, Bloch M, Heinecke A, Kalchschmidt K. Triple pelvic osteotomy. *J Pediatr Orthop B* 1994;3:54–67
- d’Aubigné RM, Postel M. The classic: functional results of hip arthroplasty with acrylic prosthesis. 1954. *Clin Orthop Relat Res* 2009;467(01):7–27
- Steel HH. Triple osteotomy of the innominate bone. A procedure to accomplish coverage of the dislocated or subluxated femoral head in the older patient. *Clin Orthop Relat Res* 1977;(122):116–127
- Millis MB, Kim YJ. Rationale of osteotomy and related procedures for hip preservation: a review. *Clin Orthop Relat Res* 2002;(405):108–121
- Millis MB, Poss R, Murphy SB. Osteotomies of the hip in the prevention and treatment of osteoarthritis. *Instr Course Lect* 1992;41:145–154
- Tönnis D. Congenital dysplasia and dislocation of the hip. Berlin: Springer-Verlag; 1987
- Johnsen K, Goll R, Reikerås O. Acetabular dysplasia as an aetiological factor in development of hip osteoarthritis. *Int Orthop* 2009;33(03):653–657
- Okano K, Enomoto H, Osaki M, Shindo H. Outcome of rotational acetabular osteotomy for early hip osteoarthritis secondary to dysplasia related to femoral head shape: 49 hips followed for 10–17 years. *Acta Orthop* 2008;79(01):12–17
- Aminian A, Mahar A, Yassir W, Newton P, Wenger D. Freedom of acetabular fragment rotation following three surgical techniques for correction of congenital deformities of the hip. *J Pediatr Orthop* 2005;25(01):10–13
- Leunig M, Siebenrock KA, Ganz R. Rationale of periacetabular osteotomy and background work. *Instr Course Lect* 2001;50:229–238
- Teplenky M, Mekki W. Reduction by pelvic external fixator followed by innominate and derotational femoral osteotomies for late presenting bilateral developmental dysplasia of the hip. *J Orthop Trauma Rehabil*. 2018;25:76–81
- Hailer NP, Soykaner L, Ackermann H, Rittmeister M. Triple osteotomy of the pelvis for acetabular dysplasia: age at operation and the incidence of nonunions and other complications influence outcome. *J Bone Joint Surg Br* 2005;87(12):1622–1626
- Tschauner C, Sylkin A, Hofmann S, Graf R. Painful nonunion after triple pelvic osteotomy. Report of five cases. *J Bone Joint Surg Br* 2003;85(07):953–955
- Wall EJ, Kolata R, Roy DR, Mehlman CT, Crawford AH. Endoscopic pelvic osteotomy for the treatment of hip dysplasia. *J Am Acad Orthop Surg* 2001;9(03):150–156
- Teplenky M, Mekki W. Pertrochanteric osteotomy and distraction femoral neck lengthening for treatment of proximal hip ischemic deformities in children. *J Child Orthop* 2016;10(01):31–39