



RBO

REVISTA BRASILEIRA DE ORTOPEDIA

www.rbo.org.br



## Original Article

# Analysis on the results from percutaneous extensor osteotomy of the distal femur in patients with amyoplasia ☆,☆☆

Marcus Vinicius Moreira \*, André Casari Rimoldi, Solange Aoki

Associação de Assistência à Criança Deficiente, São Paulo, SP, Brazil

## ARTICLE INFO

## Article history:

Received 10 March 2013

Accepted 8 October 2013

Available online 5 May 2014

## Keywords:

Arthrogyposis

Osteotomy

Knee

## Palavras-chave:

Artrogrípese

Osteotomia

Joelho

## ABSTRACT

**Objective:** to review the medical files of 19 patients with a diagnosis of amyoplasia, who underwent percutaneous extensor osteotomy of the distal femur to correct deformities in whom the knees were fixed in flexion.

**Methods:** we analyzed 37 osteotomy procedures on 35 knees that presented an initial deformity in which the knees were fixed in flexion at 33.8°. All of these knees underwent percutaneous extensor osteotomy of the distal femur and were followed up for a mean period of 73.7 months.

**Results:** we observed recurrence of the deformity in 29 osteotomy cases, i.e. in 78.4% of them. The mean recurrence velocity of the deformity was 0.69°/month.

**Conclusion:** percutaneous extensor osteotomy of the distal femur provided sufficient correction of deformities in which the knee was fixed in flexion in these amyoplasia cases, but there was a significant degree of recurrence among the patients analyzed.

© 2014 Sociedade Brasileira de Ortopedia e Traumatologia. Published by Elsevier Editora Ltda. All rights reserved.

## Análise de resultados da osteotomia extensora percutânea de fêmur distal em pacientes com amioplasia

## RESUMO

**Objetivo:** revisar os prontuários de 19 pacientes com diagnóstico de amioplasia, submetidos à osteotomia extensora percutânea de fêmur distal, para correção de deformidade fixa em flexão dos joelhos.

**Métodos:** analisamos 37 osteotomias em 35 joelhos com média de deformidade fixa inicial média em flexão dos joelhos de 33,8°, todos submetidos à osteotomia percutânea extensora do fêmur distal e acompanhados em média de 73,7 meses.

**Resultados:** observamos recidiva da deformidade em 29 osteotomias, ou seja, 78,4% delas. A velocidade média de recidiva da deformidade foi de 0,69°/mês.

\* Please cite this article as: Moreira MV, Rimoldi AC, Aoki S. Análise de resultados da osteotomia extensora percutânea de fêmur distal em pacientes com amioplasia. Rev Bras Ortop. 2014;49:345-349.

☆☆ Work performed at the Congenital Malformation Clinic, Associação de Assistência à Criança Deficiente, São Paulo, SP, Brazil.

\* Corresponding author.

E-mail: [vini.moreira@yahoo.com.br](mailto:vini.moreira@yahoo.com.br) (M.V. Moreira).

**Conclusão:** a osteotomia extensora percutânea do fêmur distal forneceu correção suficiente da deformidade fixa em flexão dos joelhos na amíoplasia, porém apresentou significativo grau de recidiva nos pacientes analisados.

© 2014 Sociedade Brasileira de Ortopedia e Traumatologia. Publicado por Elsevier Editora Ltda. Todos os direitos reservados.

## Introduction

The term arthrogryposis describes a group of diseases that are characterized by their presentation of multiple joint contractures, with involvement of two or more joints in different areas of the body.<sup>1</sup>

Arthrogryposis affects 1:3000 live births and its etiology is multifactorial. There is a consensus that it is related to restriction of fetal movements after the tenth week of pregnancy. This process is known as a fetal akinesia/hypokinesia sequence.<sup>2,3</sup>

Amyoplasia is the commonest type of arthrogryposis syndrome, and occurs in 38–47% of the cases.<sup>2</sup> It is characterized by joint contractures that affect all four limbs, symmetrically (84% of the cases), with replacement of the muscle tissue with fibrotic tissue and with hemangioma on the face.<sup>1</sup>

The contractures may affect both the upper and the lower limbs. The knee joints contribute to the general incidence and prevalence of the deformities, and such deformities are present in 70% of the children with amyoplasia. Of these, 48% of the knees present abnormalities of flexion, 21% extension and 4% dislocation.<sup>1</sup>

The treatment for patients with amyoplasia is complex and multidisciplinary. The aims are to stimulate improved joint mobility, achieve and maintain alignment so that less energy is expended during mobilization, promote the use of orthoses, stimulate walking at different levels when possible; and attain independence in activities of daily living.<sup>4</sup>

Fixed deformities in which the knee is flexed are an obstacle to the use of orthoses and lead to greater energy expenditure in patients who can walk, especially when the deformity is greater than 20°. Such deformities may also become factors that are harmful to seated postures and transfers, and may make hygiene difficult.

For fixed deformities comprising knee flexion, the treatment should vary according to the degree of flexed contracture. Deformities of up to 20° generally allow the use of orthoses and therefore maintenance of qualities is proportional to the patient's capacity to move around. Mild deformities of between 20° and 40° impede orthosis use and commonly require surgical treatment. The possibilities for intervention include posterior soft-tissue release, percutaneous extensor osteotomy of the distal femur, serial plaster casts or a combination of surgical techniques and serial plaster casts. Contractures of greater severity, greater than 40°, require not only soft-tissue release but also extensor osteotomy of the distal femur, with shortening, because of the risk of stretching of the soft tissues and neurovascular lesions. Deformities of greater severity may require soft-tissue release in association with gradual correction using an external fixator.<sup>1,5-7</sup> Percutaneous extensor osteotomy of the distal femur becomes an option particularly for fixed deformities

of between 20° and 40°, and has the advantage of minimal soft-tissue injury, which favors the consolidation process and reduces the chances of infection.<sup>8</sup>

The aim of the present study was to analyze the surgical results from patients with a diagnosis of amyoplasia who underwent correction of knee flexion deformities solely by means of the technique of percutaneous extensor osteotomy of the distal femur.

## Materials and methods

This was a retrospective study in which we analyzed the medical files of patients who were followed up at the Congenital Malformation Clinical of the Association for the Care of Disabled Children (Associação de Assistência à Criança Deficiente, AACD), with a diagnosis of amyoplasia and fixed knee flexion deformity. These patients underwent operations on the distal femur by means of the percutaneous extensor osteotomy technique between 1998 and 2009.

The data on extension deficits reported before and after the surgical procedure for correction of the knee flexion deformity were used, along with data from the outpatient follow-up. The degree of knee flexion used as a parameter for the study was measured from the observed deficit in complete knee extension.

In analyzing the medical files, we did not see any descriptions regarding residual deformity during the immediate postoperative period. Thus, all the knees operated reached complete extension during the surgical procedure. Therefore, we classified fixed knee flexion deformities acquired after the surgery as recurrence.

Patients with postoperative follow-up of less than 18 months and patients who underwent other surgical procedures with the same purpose, with the exception of posterior release of knee soft tissues, were excluded. We also excluded patients who underwent the proposed procedure in other institutions or whose postoperative follow-up was irregular.

The prescribed surgical technique used for correction of the deformity began with a 1 cm incision in the lateral distal third of the thigh, at the level of the upper border of the patella. Holes were drilled in the distal femur, concentrated on the convex side of the deformity, proximally to the growth plate. The aim was to produce a greenstick fracture in the dorsal cortical bone by means of osteoclasia, while preserving the cortical bone of the opposite side. The knee was then forced to extend, using the undamaged posterior cortical bone as the fulcrum, thereby achieving limb extension. The reduction could be maintained by means of a plaster-cast splint going from the groin to the foot, or by fixation of the focus of the osteoclasia, in extension, using two crossed Kirschner wires.<sup>8</sup>

For statistical analysis on the data, we used the test of equality of two proportions, the correlation test, Pearson's correlation, the Kaplan–Meier curve and the *p*-value.

**Table 1 – Clinical data.**

|    | Osteotomy | Knee | Age at time of surgery (years + months) | Sex    | Preoperative FFK (in degrees) | Final FFK (in degrees) | Length of follow-up (months) |
|----|-----------|------|---|--------|-------------------------------|------------------------|------------------------------|
| 1  | 1         | R    | 3 + 1                                   | Female | 20                            | 0                      | 165                          |
|    | 2         | L    |   |        | 10                            | 0                      |                              |
| 2  | 3         | R    | 3                                       | Female | 35                            | 10                     | 133                          |
|    | 4         | L    |   |        | 60                            | 30                     |                              |
| 3  | 5         | R    | 9                                       | Male   | 70                            | Lost                   | –                            |
|    | 6         | L    |   |        | 90                            | Lost                   |                              |
| 4  | 7         | R    | 10                                      | Male   | 55                            | 0                      | 122                          |
|    | 8         | L    |   |        | 55                            | 0                      |                              |
| 5  | 9         | R    | 3                                       | Female | 70                            | 0                      | 91                           |
|    | 10        | L    |   |        | 50                            | 0                      |                              |
| 6  | 11        | R    | 7 + 5                                   | Male   | 20                            | 40                     | 48                           |
|    | 12        | L    |   |        | 30                            | 20                     |                              |
| 7  | 13        | R    | 3 + 10                                  | Male   | 10                            | 15                     | 81                           |
|    | 14        | L    |   |        | 90                            | 15                     |                              |
| 8  | 15        | R    | 2 + 3                                   | Female | 10                            | 5                      | 78                           |
|    | 16        | L    |   |        | 20                            | 15                     |                              |
| 9  | 17        | R    | 10 + 10                                 | Male   | 20                            | Lost                   | –                            |
| 10 | 18        | R    | 4 + 8                                   | Female | 30                            | 30                     | 43                           |
|    | 19        | L    |   |        | 50                            | 40                     |                              |
|    | 20        | R    | 7                                       |        | 30                            | 40                     | 49                           |
|    | 21        | L    |   |        | 40                            | 50                     |                              |
| 11 | 22        | R    | 12                                      | Female | 20                            | Lost                   | –                            |
|    | 23        | L    |   |        | 20                            | Lost                   |                              |
| 12 | 24        | R    | 10                                      | Female | 30                            | 20                     | 99                           |
|    | 25        | L    |   |        | 0                             | 10                     |                              |
| 13 | 26        | R    | 7 + 10                                  | Male   | 20                            | 15                     | 43                           |
|    | 27        | L    |   |        | 5                             | 5                      |                              |
| 14 | 28        | R    | 5                                       | Female | 30                            | 10                     | 97                           |
| 15 | 29        | R    | 5                                       | Male   | 30                            | 20                     | 45                           |
|    | 30        | L    |   |        | 30                            | 20                     |                              |
| 16 | 31        | R    | 6                                       | Male   | 30                            | 0                      | 85                           |
| 17 | 32        | R    | 4                                       | Female | 15                            | 30                     | 70                           |
|    | 33        | L    |   |        | 40                            | 70                     |                              |
| 18 | 34        | R    | 3                                       | Female | 60                            | 90                     | 54                           |
|    | 35        | L    |   |        | 65                            | 90                     |                              |
| 19 | 36        | R    | 8 + 5                                   | Female | 20                            | 30                     | 45                           |
|    | 37        | L    |   |        | 20                            | 15                     |                              |
| 20 | 38        | R    | 3                                       | Male   | 50                            | 20                     | 48                           |
|    | 39        | L    |   |        | 50                            | 10                     |                              |
| 21 | 40        | L    | 3                                       | Male   | 20                            | 0                      | 45                           |
| 22 | 41        | R    | 2                                       | Female | 10                            | 10                     | 32                           |
|    | 42        | L    |   |        | 40                            | 40                     |                              |

FFK, fixed flexion of the knee.  
p-Value = 0.05.

We found that 202 patients with a diagnosis of amyoplasia had been followed up at the institution. Of these, 65 had undergone a surgical procedure to correct knee flexion deformity.

Among these 65 patients, 19 were treated surgically by means of correction using an external fixator, 10 underwent extensor osteotomy of the distal femur, with shortening, two underwent posterior soft-tissue release alone and 34 underwent percutaneous extensor osteotomy of the distal femur, in order to correct the knee flexion deformity.

Among the 34 patients who underwent the procedure that was the focus of this study, 10 presented insufficient length of postoperative follow-up and two underwent the procedure at other services.

Therefore, our sample included 22 patients with 42 osteotomies who fulfilled the criteria for this study. However, three patients who underwent osteotomy did not maintain their postoperative follow-up and were excluded from the analysis on the final results.

In the end, our analysis on the final results was based on 19 operated patients (37 osteotomies).

## Results

We selected 22 patients who met the criteria established for this study, i.e. 42 knees (Table 1). Among these patients, 10 were boys and 12 were girls; 18 had bilateral deformities and

**Table 2 – Distribution of recurrences.**

| Recurrence | N  | %    | p-Value |
|------------|----|------|---------|
| No         | 8  | 21.6 | < 0.001 |
| Yes        | 29 | 78.4 |         |

**Table 3 – Correlation between degree of recurrence and age.**

|             | Age    |
|-------------|--------|
| Correlation | -12.4% |
| p-Value     | 0.466  |

four had a unilateral deformity. One of the patient presented recurrence of the deformity three years after the first procedure and underwent a new surgical procedure. Three patients who underwent osteotomy were not followed up at our institution. Thus, there was no record of postoperative data in their cases.

Out of the 37 osteotomies performed and analyzed, we observed recurrence of the deformity in 29 of them, i.e. 78.4% (Table 2). The mean velocity of recurrence in the present study was 0.69°/month, ranging from 0.07° to 2.09°/month.

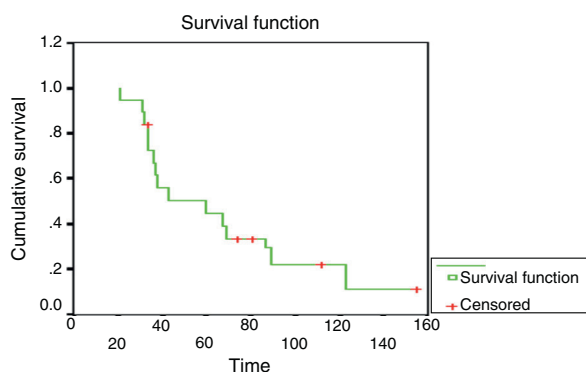
We used the Kaplan–Meier estimator to calculate nonparametric reliability values for a set of data with multiple failures. In this study, the Kaplan–Meier survival curve (Fig. 1) showed that 50% of the patients who underwent the surgical procedure studied here experienced recurrence before reaching the 48th month after the operation.

The patients' mean age at the time of the surgery was 5.8 years, with a range from 2 to 12. Before the surgical procedure, the mean fixed flexion of the knees among the patients analyzed was 33.8°, ranging from 5° to 90°. The mean degree of flexion after postoperative recurrence was 22°, ranging from 5° to 90°.

The mean postoperative follow-up period was 73.7 months, with a range from 32 to 165 months.

From analysis on the correlation between the degree of recurrence and age (Table 3), the value obtained was -12.4%, which indicates that the variables were inversely proportional and the correlation was classified as “poor”, without statistical significance ( $p=0.466$ ).

The correlation between the degree of recurrence and the length of postoperative evolution showed a value of -39.3%,

**Fig. 1 – Kaplan–Meier survival curve.****Table 4 – Correlation between degree of recurrence and length of evolution.**

|             | Evolution (months) |
|-------------|--------------------|
| Correlation | -39.3%             |
| p-Value     | 0.016              |

which indicates that the correlation was “poor”, without statistical significance (Table 4).

## Discussion

Knee flexion deformity is one of the most challenging problems for orthopedic surgeons who treat patients with amyoplasia. Mild contractures of up to 20° do not stop patients from walking, but they tend to increase the energy expenditure that is usually necessary for walking the same distance. Contractures of greater intensity not only present increased energy expenditure but also routinely make it difficult to use orthoses or impede their use for independent walking. Thus, surgical procedures aim to reestablish alignment, so as to correct and stimulate functional development.<sup>9</sup>

In our series of cases, we found 202 patients with a diagnosis of amyoplasia. Of these, 65 (32%) had knee flexion deformities that required surgical treatment. In a case series, Carlson et al.<sup>10</sup> found that 19.2% of the patients had amyoplasia that required surgical treatment for correction of knee flexion. Svartman et al.<sup>11</sup> found that 10 patients (17.8%) needed knee surgery, out of a total of 56.

Percutaneous extensor osteotomy of the distal femur is generally applicable for correction of deformities less than 40°. Thus, this is a good option, given that the training for this technique is easy and the surgical materials that might be used are widely available. Its advantages include a lower level of soft-tissue aggression (because of the smaller incision and lower need for dissection); smaller alterations to muscle and periosteal vascularization, with maintenance of a satisfactory blood supply to the surgical site; lower risk of tissue adherence; greater stability at the focus of the osteotomy; greater potential for consolidation; and lower risk of infection of the operative wound.<sup>5,8,9,12</sup>

The disadvantages of this technique include lower ability to view the operation and impossibility of promoting shortening of the femur with the aim of avoiding stretching of the neurovascular structures. These considerably limit the applicability of the technique and its potential for correcting the deformity.

There is also an important mechanical factor; the center of the flexion deformity is in the femorotibial joint and includes joint structures in its physiopathology, such as the posterior joint capsule and the respective ligament, in association with shortening of the knee flexors. The technique analyzed here provides correction that occurs at an extra-articular site because of the extension of the distal femur in the sagittal plane. Thus, it is outside of the center of deformity and does not address the structures that give rise to the structured flexion.

The degree of recurrence of the deformity that we found in our study was significant, affecting 78.4% of the osteotomies

performed. We believe that recurrence of the deformity may be multifactorial, caused by nonuse of orthoses during the postoperative period, the great potential for bone remodeling in immature skeletons, lack of soft-tissue release in the posterior region of the knees, or even variations in the surgical technique. Svartman et al.<sup>11</sup> mentioned that deformities in cases of amyoplasia were of recurrent nature, especially when treated in patients of young age.

The recurrence rate was also highlighted by means of the Kaplan-Meier curve, in which 50% of the patients experienced recurrence of the deformity within the first 48 months after the operation. The data showed that there was a failure to maintain the correction that had been made, for a long-lasting period.

The velocity of recurrence encountered in this study was 0.69°/month. Bevan et al.<sup>1</sup> reported a 1°/month and Delbello and Watts<sup>5</sup> found 0.9°/month, which were both for extensor osteotomy with femoral shortening.

In our study, there was a negative correlation between age and degree of recurrence. This shows that the variables were inversely proportional, i.e. the younger the patient's age, the greater was the degree of recurrence of the deformity. However, the coefficient of correlation was found to be -12.4%, which received a classification of "poor" on the correlation scale, without statistical significance ( $p=0.466$ ). Delbello and Watts<sup>5</sup> also correlated young age with the deformity recurrence rate and found a negative relationship. Although our case series did not show any significant correlation, our clinical practice suggests that young age is related to a greater deformity recurrence rate.

We believe that this medium-term follow-up analysis on our patients was sufficient to show whether recurrence of the deformity or maintenance of the correction would occur. The mean follow-up period was 73.7 months. There was no significant correlation between the degree of recurrence and the length of the postoperative follow-up.

There was no intention with this study to compare this surgical method with other methods used for the same purpose, which limits the applicability of the results to only the technique analyzed here. We take the view that studies using other surgical techniques and subsequent comparison between them would be of great importance for providing more objective guidance regarding the characteristics of recurrence of deformities in cases of amyoplasia. Such recurrences could be due as much to variations in operative technique as to the recurrent nature of the deformities in this disease. Delbello and Watts<sup>5</sup> highlighted the difficulty maintaining the correction obtained during the postoperative period and emphasized that a new procedure at an older age might be needed.

Despite the results obtained, we believe that there is no justification for postponing the corrective procedure until an age closer to when skeletal maturity is reached. At that time, the potential for bone remodeling would be lower. The benefits, with regard not only to functional and independent walking but also to social interaction in performing activities of daily living, exceed the risks of undertaking a new surgical approach.

## Conclusion

Percutaneous extensor osteotomy of the distal femur provided correction of the sagittal alignment of deformed knees that were fixed in flexion, albeit through creating a compensatory deformity of extension of the femur. There was a significant degree of recurrence of the deformity during the follow-up period analyzed.

The planning of treatment for this group of patients needs to take into consideration the benefits of the corrections proposed and the improvements in alignment, functional results and risks of recurrence of deformities.

## Conflicts of interest

The authors declare no conflicts of interest.

## REFERENCES

1. Bevan WP, Hall JG, Bamshad M, Staheli LT, Jaffe KM, Song K. Arthrogryposis multiplex congenita (amyoplasia): an orthopaedic perspective. *J Pediatr Orthop.* 2007;27(5): 594-600.
2. Filho OB, Santos CE. Artrogripose múltipla congênita. In: Fernandes AC, Ramos AC, Casalis ME, Herbert SK, editors. *AACD medicina e reabilitação - Princípios e prática.* São Paulo: Artes Médicas; 2007. p. 69-76.
3. Alman BA, Goldberg MJ. Síndromes de importância ortopédica. In: Morrissy RT, Weinstein SL, editors. *Ortopedia pediátrica de Lovell e Winter.* 5ª ed. Barueri: Manole; 2005. p. 317-27.
4. Bamshad M, Van Heest AE, Pleasure D. Arthrogryposis: a review and update. *J Bone Joint Surg Am.* 2009;91 Suppl. 4:4-6.
5. DelBello DA, Watts HG. Distal femoral extension osteotomy for knee flexion contracture in patients with arthrogryposis. *J Pediatr Orthop.* 1996;16(1):122-6.
6. Staheli LT, Hall JG, Jaffe KM, Paholke DO. *Arthrogryposis: a text atlas.* Cambridge: Cambridge University Press; 1998.
7. Thomas B, Schopler S, Wood W, Oppenheim WL. The knee in arthrogryposis. *Clin Orthop Relat Res.* 1985;(194):87-92.
8. Iacovone M. Osteoclasia com perfurações ósseas: método para correção de deformidades dos membros inferiores: estudo baseado em 44 operações [tese]. São Paulo: Faculdade de Medicina da Universidade de São Paulo; 1981.
9. Zimmerman MH, Smith CF, Oppenheim WL. Supracondylar femoral extension osteotomies in the treatment of fixed flexion deformity of the knee. *Clin Orthop Relat Res.* 1982;(171):87-93.
10. Carlson WO, Speck GJ, Vicari V, Wenger DR. Arthrogryposis multiplex congenita. A long-term follow-up study. *Clin Orthop Relat Res.* 1985;(194):115-23.
11. Svartman C, Fucs PM, Kertzman PF, Kampe PA, Rossetti F. Artrogripose múltipla congênita - Revisão de 56 pacientes. *Rev Bras Ortop.* 1995;30(1/2):45-52.
12. Södergård J, Ryöppy S. The knee in arthrogryposis multiplex congenita. *J Pediatr Orthop.* 1990;10(2):177-82.