



Original Article

High congenital hip dislocation in adults – arthroplasty and functional results[☆]



Diogo Lino Moura^{*}, António Figueiredo

Serviço de Ortopedia, Centro Hospitalar e Universitário de Coimbra, Coimbra, Portugal

ARTICLE INFO

Article history:

Received 13 December 2016

Accepted 21 February 2017

Available online 23 February 2018

Keywords:

Hip congenital dislocation

Hip arthroplasty

Hip joint

Adult

Osteotomy

ABSTRACT

Objective: Retrospective case-control study on the authors' experience regarding arthroplasty in high congenital dislocations of the hip in adults.

Methods: Sample with 11 high congenital hip dislocations (Hartofilakidis type C) that occurred in seven patients, who were submitted to hip arthroplasty by the same surgeon and with the same surgical technique. Mean follow-up period was 4.32 ± 2.67 years (minimum one year) and all patients were evaluated by the same examiner.

Results: All the arthroplasties had cementless fixation, with application of screwed acetabular cups, conical femoral stems, and a metal-polyethylene articular pars. In every patient, shortening femoral osteotomies were performed at subtrochanteric or supracondylar locations. The mean Harris Hip Score at the last evaluation was 88.55 ± 4.50 (range 81–94). The mean time with high dislocation of the hip (42.91 ± 14.59 years, range 19–68) showed a significant inverse correlation with Harris Hip Score ($r=0.80$; $p=0.003$). All patients reported important relief of pain complaints and are capable of ambulation without any external support. In the unilateral dislocations, leg length discrepancies were fully corrected; in the bilateral cases, isometric limbs were achieved in all patients. All osteotomies consolidated, with a mean interval of 3.27 ± 0.47 months. There were complications in 18.18% of the sample: one iatrogenic intraoperative fracture of the greater trochanter and a transitory sciatic neurapraxia.

Conclusion: Despite being a demanding surgery with a reportedly high complication rate, total hip arthroplasty in high congenital dislocations, when properly indicated and technically correctly performed, allows an improvement in function and quality of life.

© 2017 Sociedade Brasileira de Ortopedia e Traumatologia. Published by Elsevier Editora Ltda. This is an open access article under the CC BY-NC-ND license (<http://creativecommons.org/licenses/by-nc-nd/4.0/>).

[☆] Study conducted at Centro Hospitalar e Universitário de Coimbra, Serviço de Ortopedia, Coimbra, Portugal.

^{*} Corresponding author.

E-mail: dfilmoura@gmail.com (D.L. Moura).

<https://doi.org/10.1016/j.rboe.2017.02.008>

2255-4971/© 2017 Sociedade Brasileira de Ortopedia e Traumatologia. Published by Elsevier Editora Ltda. This is an open access article under the CC BY-NC-ND license (<http://creativecommons.org/licenses/by-nc-nd/4.0/>).

Luxações congênicas altas da anca no adulto – Artroplastia e resultados funcionais

R E S U M O

Palavras-chave:

Luxação congênita de anca
Artroplastia de anca
Articulação da anca
Adulto
Osteotomia

Objetivo: Estudo retrospectivo sobre a experiência dos autores no uso de artroplastias para o tratamento de luxações congênicas altas da anca.

Métodos: Amostra com 11 luxações congênicas altas da anca (Hartofilakidis tipo C) verificadas em sete pacientes, que foram submetidos a artroplastia da anca pelo mesmo cirurgião com a mesma técnica cirúrgica. O tempo de seguimento médio foi de $4,32 \pm 2,67$ anos (mínimo um ano) e todos os pacientes foram avaliados pelo mesmo médico.

Resultados: Todas as próteses tiveram fixação não cimentada, usaram-se cúpulas acetabulares aparafusadas, hastas femorais cônicas e par articular metal-polietileno. Em todos os pacientes foram efetuadas osteotomias de encurtamento femoral no nível subtrocantérico ou supracondiliano. O *Harris Hip Score* médio no momento da última avaliação clínica foi de $88,55 \pm 4,50$ (intervalo 81-94). O tempo de duração da luxação alta da anca ($42,91 \pm 14,59$ anos, intervalo 19-68) demonstrou uma correlação inversa significativa com o *Harris Hip Score* ($r = 0,80$; $p = 0,003$). Todos os pacientes relataram alívio importante das queixas álgicas e todos são capazes de deambular sem qualquer apoio exterior. Nas luxações unilaterais, conseguiu-se correção completa da dismetria e nas bilaterais, membros isométricos em todos os pacientes. Todas as osteotomias consolidaram em tempo médio de $3,27 \pm 0,47$ meses. Verificaram-se complicações em 18,18% da amostra: uma fratura iatrogênica intraoperatória do grande trocânter e uma neuropráxia transitória do ciático.

Conclusão: Apesar de ser uma cirurgia exigente e com elevado índice de complicações relatado, a artroplastia da anca na luxação congênita alta, quando devidamente indicada e tecnicamente bem executada, permite melhorar a funcionalidade e qualidade de vida dos pacientes.

© 2017 Sociedade Brasileira de Ortopedia e Traumatologia. Publicado por Elsevier Editora Ltda. Este é um artigo Open Access sob uma licença CC BY-NC-ND (<http://creativecommons.org/licenses/by-nc-nd/4.0/>).

Introduction

High dislocation of the hip, also described by Hartofilakidis as type 3 or type C dislocation, is a rare clinical entity, representing the most severe type in the spectrum of congenital hip dysplasia. Typically, patients present after decades of evolution and adaptation to the abnormal hip position in the neoacetabulum or false acetabulum, with disabling complaints of pain and functional limitation due to the development of early secondary coxarthrosis (whose symptoms are typically observed in the fourth and fifth decades of life).¹⁻⁹ Arthroplasty reconstruction at the correct center of rotation of the hip, at the level of the true acetabulum or paleoacetabulum, has been shown to have superior biomechanical results (among which, the increase in the lever arm and in the strength of the abductor muscles), and superior arthroplasty duration when compared with the more cephalic application of the arthroplasty.^{6,10-15} In order to bring the femur into the paleoacetabulum and prevent or minimize the occurrence of neurovascular injuries due to excessive stretching, a femoral shortening osteotomy is usually required in high dislocations.^{6,15-18} Hip arthroplasty in cases of high dislocation is considered one of the most demanding surgeries in orthopedics, mainly due to the following reasons: need for reconstruction of the center of rotation in the paleoacetabulum, with risk of neurovascular lesions by stretching; need

for femoral shortening osteotomy; distortion of the muscular, neurovascular, and bone anatomy (reduced paleoacetabular bone stock and narrow femoral canal); and need to restore isometry of the lower limbs.^{5,6,15,19,20} The authors describe the arthroplastic technique that they use in high congenital dislocations of the hip in adults; subsequently, the results of their experience are presented.

Material and methods

The authors retrospectively presented 11 cases of high congenital dislocations of the hip (Hartofilakidis type C),^{3,7} in seven patients who underwent hip arthroplasty by the same surgeon using the same surgical technique over eight years. The mean follow-up time was 4.32 ± 2.67 years (minimum one, range 1-8). Data on the duration of high hip dislocation, symptoms that led to arthroplasty, the type of prosthesis applied, length of hospital stay, complications, and level of satisfaction (scale from 0 to 5) were collected. A clinical and radiographic evaluation was performed at the time of follow-up of each patient (1-8 years postoperatively). The functional score used was the Harris Hip Score²¹; Trendelenburg sign was classified in accordance with Kuhfuss.²² Patients were also assessed for improvement in pain complaints, gait function, and whether or not they would undergo a new surgical intervention. Radiographic evaluation included the search for signs of loosening

and prosthetic migration, as well as periarticular heterotopic ossification. Regarding the time of osteotomy consolidation, it was considered equal to the date of the consultation in which radiologically for the first time, the disappearance of the hypotransparency of the osteotomy cut and the presence of bone callus was observed. The variables were statistically analyzed using SPSS^v.²³ Pearson's correlation test was used for quantitative variables. All patients signed the Informed Consent Form and the present study was approved by this institution.

Arthroplasty technique in high congenital hip dislocations in adults

The arthroplasty technique used by the authors aims at positioning the acetabular component in the center of rotation of the hip, i.e., in the paleoacetabulum or true acetabulum, and at the same time correcting the lower limb dysmetria. In the preoperative period, if the distance between the location of the femoral head in the neoacetabulum or false acetabulum and the paleoacetabulum is greater than 4 cm, which happens in most cases of congenital hip dislocation, the authors use femoral shortening osteotomy (which can be performed at the subtrochanteric or supracondylar level) to bring the hip into the paleoacetabulum, thus reducing the risk of neurovascular injuries due to excessive stretching.^{16,17} Careful preoperative planning of the amount of femoral bone to be resected at the site of the osteotomy for shortening is paramount in order to correct the dysmetria. It should be noted that, although a femoral shortening osteotomy is performed, after the hip arthroplasty applied on the paleoacetabulum, these patients become taller than in the preoperative period, as the dislocated femoral head in the high position is reduced to a caudal position; this hip reduction distance from the high position corresponds to the amount of bone that is resected at the osteotomy. The first intravenous cefazolin dose is administered approximately 30 min prior to surgery, and continues for the first 48 h. For this surgery, the authors prefer the posterior access route, in which the patient is positioned in a lateral decubitus position. After removal of the hypertrophic and redundant joint capsule, an *in situ* femoral neck osteotomy is performed. Subsequently, the femoral head is extracted and the paleoacetabulum is exposed; the latter can be recognized through the identification of the following references: greater sciatic notch, radiological U, anterior/posterior acetabular columns, and obturator foramen. In order to determine how far to advance acetabular milling in the dysplastic paleoacetabulum, the authors progressively drill the center of the acetabular cavity with a fine drill until bone consistency can no longer be felt. The length of the drill in the intraosseous position will correspond to the remaining bone quantity in the acetabulum to an intrapelvic position; the milling should be less deep than this measured length. Intraoperative fluoroscopy may be useful to identify the level of the femoral neck osteotomy and of the true acetabular fundus. The next goal is to reconstruct a cavity in a dysplastic acetabulum and at the same time preserve as much of the native bone as possible, which is achieved by extended milling (with small mills – 40–44 mm) in the thicker posterior acetabular wall and less milling in the anterior, dysplastic wall. The existing bone bridge between the neo and paleoacetabulum should be

preserved; although fragile, it corresponds to the roof of the paleoacetabulum. In cases of severe acetabular dysplasia, in which more than one-third of the acetabular dome is uncovered, a femoral head graft is used to reconstruct the acetabular wall (acetabuloplasty). After adequate acetabular preparation, the uncemented acetabular component is implanted, and then secured with screws (usually two) and their respective polyethylene inserts.

In high hip dislocations, soft tissue release is often insufficient to achieve a reduction from the femoral head to the paleoacetabulum. Thus, in order to avoid neurovascular lesions due to excessive stretching, in cases of high dislocations the authors opt for a transverse femoral shortening osteotomy (which may or may not be associated with soft tissue release, including iliopsoas, rectus femoris, hamstring and long adductor tenotomies); these osteotomies can be performed at a subtrochanteric (Fig. 1) or supracondylar level. A partial correction of the dysmetria is preferred to a neurovascular injury by excessive tension. Currently, the authors prefer subtrochanteric femoral osteotomies to the detriment of the supracondylar type. After the acetabular component is applied, femoral milling begins; special mills may be required due to the narrow dysplastic intramedullary canal. The surgeon should pay special attention to this milling, due to the frequent fragility of the cortical bone and the high risk of iatrogenic fracture. The subtrochanteric osteotomy level is then marked with the test stem; the first osteotomy cut is performed approximately 1 cm distal to the small trochanter. The remaining milling of the proximal and distal femur is performed; then, a clamp is applied on the distal femur and the test stem is passed through the proximal femur. The stem in the proximal femur is reduced to the acetabular component, and its distal portion overlaps the distal femur, thus marking the amount of femur that needs to be removed (in most cases, 2–3 cm; Fig. 1). The second cut of the femoral shortening osteotomy is performed at the subtrochanteric level, followed by the application of the definitive non-cemented conical femoral stem that passes first through the femoral fragment proximal to the osteotomy and then through the distal fragment; subsequently, the prosthesis is reduced. The type of implant used and the method of fixation depend on the quality and quantity of bone stock. Since patients with high hip dislocations are typically young, with acceptable bone stock, the prosthetic fixation is preferably non-cemented. The elective implants chosen by the authors for these arthroplasties are trabecular metal acetabular domes with screw fixation and conical femoral stems. The main advantages of the non-cemented conical stems include their better adaptation to the dysplastic femoral canals that these patients typically present, and greater stability of the subtrochanteric osteotomy due to their diaphyseal fixation capacity and consequent higher contact stress at the osteotomy level (an effect caused by a rotationally stabilized center-medullary stem, due to its porosity and bone contact stress), which often saves fixation material.^{23–27} In cases of hip abduction insufficiency and prosthetic instability, the use of a constrained or a dual mobility prosthesis is recommended to ensure the stability of the neo-articulation. In situations of scarce acetabular bone stock or absent walls, the cavity can be constructed with an autograft extracted from the femoral head; the acetabular

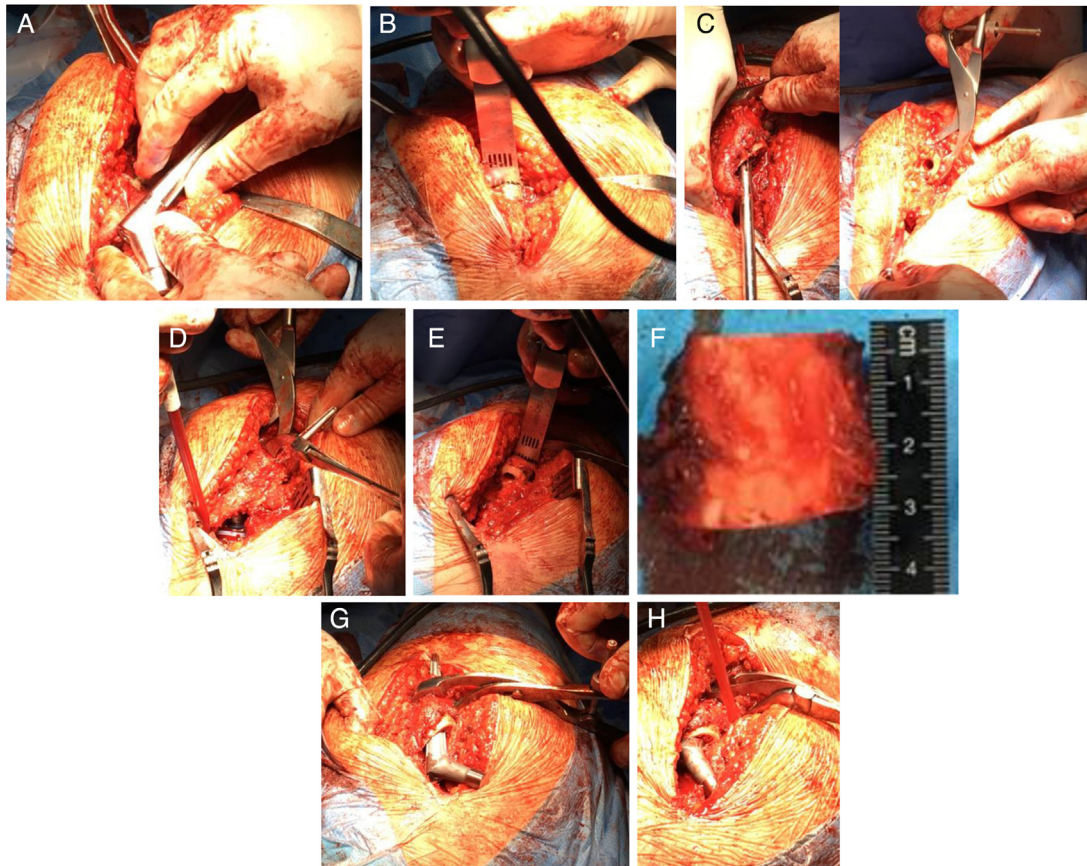


Fig. 1 – Subtrochanteric osteotomy technique. (A) Marking the level of the first cut of the subtrochanteric osteotomy with the test stem; (B) first cut of the subtrochanteric osteotomy; (C) proximal and distal femur milling and clamping of the distal femur; (D) reduction of the stem applied in the proximal femur to the previously applied acetabular component and its overlap with the distal femur, marking the amount of femur to be removed; (E) second cut of subtrochanteric osteotomy, in this case with an excision of about 3 cm of femur length (F); (G) application of the definitive conical femoral stem, passing first through the femoral fragment proximal to the osteotomy; (H) application of the definitive conical femoral stem through the distal femoral fragment; subsequently, prosthesis reduction is performed.

fundus can be reinforced with impacted granulated bone graft, followed by the application of the non-cemented acetabular dome or reconstruction rings in the remaining host bone. In most subtrochanteric osteotomies, after the non-cemented conical stem is applied, the osteotomy is stable enough to avoid the need for more fixation material. However, if this stability is not observed, particularly at a rotational level, the osteotomy should be stabilized with a plate or steel cables. In the supracondylar osteotomies, plate and screw stabilization is always necessary. The surgical time of this high hip dislocation total arthroplasty technique is between two and three hours, with an approximate blood loss of 600 ml. The postoperative period of these patients includes walking with crutches without weight-bearing on the operated limb until osteotomy consolidation, followed by a rehabilitation protocol that focuses on the abductor apparatus. The main steps of this intervention are: ensuring good surgical exposure in order to recognize the anatomical references, adequate acetabular milling at the center of rotation of the paleoacetabulum, adequate restoration of soft tissue tension, stable reconstruction

of the neo-articulation, and adequate rehabilitation of the abductor apparatus.

Results

The seven patients (all females) were submitted to total hip arthroplasty after a mean of 42.91 ± 14.59 years (range 19–68) with high congenital hip dislocations classified as Hartofilakidis type C (Table 1). Of the total, 57% of the patients had bilateral high dislocations, while the remainder had unilateral high dislocations; one patient (VAPS) had a Hartofilakidis type 2 low dislocation on the contralateral side.

In all patients, the complaints that led to arthroplasty were the combination of disabling pain in the affected hips and functional limitation, in particular gait ability (Table 2; Fig. 2). The posterior approach of the hip was used in all cases. Femoral shortening osteotomy was performed on all hips; these procedures were done at a subtrochanteric level in 72.72% of the cases, and at the supracondylar level in

Table 1 – Descriptive analysis of the sample.

	CMPB	CMPB	RMSA	RMSA	VAPS		
Gender	♀	♀	♀	♀	♀		
Side	L (bilateral dislocation)	R (bilateral dislocation)	R (bilateral dislocation)	L (bilateral dislocation)	L (bilateral dislocation, but only high on the left)		
Dislocation time – age at surgery (years)	26	27	44	45	19		
Follow-up time (years)	8	7	7	6	7		
	MHMT	MALS	MMMM	MMMM	MFDF	MFDF	Summary
Gender	♀	♀	♀	♀	♀	♀	100%♀
Side	R (Unilateral dislocation)	L (Unilateral dislocation)	L (bilateral dislocation)	R (bilateral dislocation)	L (bilateral dislocation)	R (bilateral dislocation)	54.54% L; 45.44% R; 57.14% patients with bilateral high dislocations, 42.86% unilateral high dislocations
Dislocation time – age at surgery (years)	55	68	40	41	53	54	Mean 42.91 ± 14.59
Follow-up time (years)	3	2	3	2	1.5	1	Mean 4.32 ± 2.67
R, right; L, left.							

the remaining patients. All supracondylar osteotomies were secured with plate and screws. No extra fixation was used in subtrochanteric osteotomies that remained stable after the application of the femoral stem; this was observed in half of these osteotomies. In the other half, due to insufficient stability after placement of the femoral stem, it was reinforced with plate and screws and/or steel cables. No further soft tissue release was required to achieve an arthroplasty with acceptable mobility. All prostheses had non-cemented fixation; acetabular domes with screw fixation and conical femoral stems were used in all patients. The articular pars applied was the metal-polyethylene in all hips. In one patient (VAPS), for accentuated paleoacetabular dysplasia and insufficient walls, shelf acetabuloplasty was performed with autograft extracted from the femoral head itself, in order to increase supralateral acetabular coverage. None of the cases required constrained or double mobility prostheses.

The mean hospitalization time for surgery was 9.63 ± 2.87 days (range 6–14); in 63.63% of the patients, postoperative transfusion of erythrocyte concentrate was required (Table 3).

The mean Harris Hip Score at the time of clinical evaluation was 88.55 ± 4.50 (range 81–94; Table 4). The duration of the high hip dislocation had a significant inverse correlation with the Harris Hip Score ($r=0.80$; $p=0.003$).

All patients are currently able to walk without any support; 57.14% of the sample present a slight Trendelenburg sign. All patients reported significant relief from pain complaints; in 14.29% of the patients, this relief was partial.

In unilateral dislocations, a complete correction of the dysmetria was achieved; in bilateral cases, isometric limbs were achieved in all patients. All femoral osteotomies consolidated, with a mean time of 3.27 ± 0.47 months.

Complications were observed in 18.18% of the sample (Table 5), namely: one intraoperative iatrogenic fracture of

the great trochanter, which was secured with Kirschner wires and a tension band; and one neurapraxia of the sciatic nerve, which reverted completely after two months. No cases of prosthetic loosening, infection or heterotopic ossification were recorded until the date of this study.

All patients, including those with complications, indicated that they would undergo a new arthroplasty (mean satisfaction level of 4.86 ± 0.3 with a range of 4–5, on a scale of 0 to 5), mainly due to the relief of painful complaints, recovery of hip mobility, and correction of dysmetria, which allowed them to carry out activities of daily living that were previously not possible and thus substantially improved their quality of life.

Discussion

Arthroplasty in congenital hip dislocations is a challenging and technically demanding surgery. The anatomy is distorted by decades of possible mobilization of the dislocated hip in the neoacetabulum, and the soft tissues are retracted due to joint elevation. High dislocations (Hartofilakidis type C) are the most extreme of the congenital hip dislocations, as there is a long distance from the hip to its correct center of rotation. In most cases, the rotation center can only be corrected by femoral shortening osteotomy.¹⁻⁵ Even after osteotomy, the necessary stretching to reconstruct the hip in the paleoacetabulum may cause neurovascular injuries, most of which are sciatic neurapraxia. In the present study, the authors used transverse osteotomies at the subtrochanteric and also at the supracondylar level. However, despite good results with both techniques, aiming at reducing surgical aggressiveness and to have only one incision, subtrochanteric osteotomies are currently preferred, in lieu of supracondylar osteotomies.

The functional results (mean Harris Hip Score of 88.55 ± 4.50), gait functionality, and symptomatic relief

Table 2 – Surgical intervention.

	CMPB	CMPB	RMSA	RMSA	VAPS	MHMT
Reason for wanting arthroplasty	Hip pain, functional limitation	Hip pain, functional limitation	Hip pain, functional limitation	Hip pain, functional limitation	Hip pain, functional limitation	Hip pain, functional limitation
Access route	Posterior	Posterior	Posterior	Posterior	Posterior	Posterior
Type of femoral osteotomy	Subtrochanteric, secured with 1 plate and 2 steel cables	Supracondylar, secured with plate and 1 steel cable	Supracondylar, secured with plate	Supracondylar, secured with plate	Subtrochanteric, secured with steel cables	Subtrochanteric, no extra fixation
Prosthesis	Non-cemented, acetabulum with screw fixation, conical stem	Non-cemented, acetabulum with screw fixation, conical stem	Non-cemented, acetabulum with screw fixation, conical stem	Non-cemented, acetabulum with screw fixation, conical stem	Non-cemented, acetabulum with screw fixation, conical stem, shelf acetabuloplasty	Non-cemented, acetabulum with screw fixation, conical stem
Articular pars	Metal-polyethylene	Metal-polyethylene	Metal-polyethylene	Metal-polyethylene	Metal-polyethylene	Metal-polyethylene
	MALS	MMMM (Fig. 2)	MMMM (Fig. 2)	MFDF	MFDF	Summary
Reason for wanting arthroplasty	Hip pain, functional limitation	Hip pain, functional limitation	Hip pain, functional limitation	Hip pain, functional limitation	Hip pain, functional limitation	100% Pain + Functional limitation in ADLs
Access route	Posterior	Posterior	Posterior	Posterior	Posterior	100% Posterior
Type of femoral osteotomy	Subtrochanteric, secured with steel cables	Subtrochanteric, no extra fixation	Subtrochanteric, secured with steel cables and cortical autograft	Subtrochanteric, no extra fixation	Subtrochanteric, no extra fixation	72.72% subtrochanteric; 27.27% supracondylar
Prosthesis	Non-cemented, acetabulum with screw fixation, conical stem	Non-cemented, acetabulum with screw fixation, conical stem	Non-cemented, acetabulum with screw fixation, conical stem	Non-cemented, acetabulum with screw fixation, conical stem	Non-cemented, acetabulum with screw fixation, conical stem	100% non-cemented, acetabulum with screw fixation, and conical stems
Articular pars	Metal-polyethylene	Metal-polyethylene	Metal-polyethylene	Metal-polyethylene	Metal-polyethylene	100% metal-polyethylene

AVDs, activities of daily living.

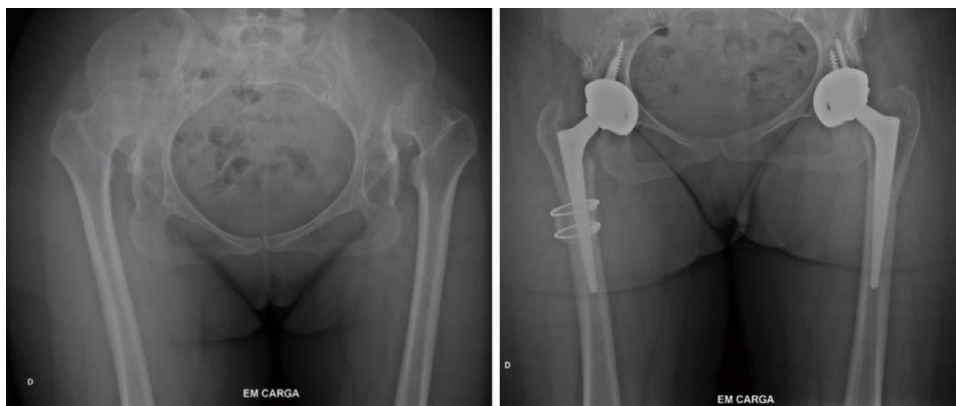**Fig. 2 – Example of patient MMMM. Radiographs before and after arthroplasties due to bilateral high dislocation.**

Table 3 – Postoperative period.

	CMPB	CMPB	RMSA	RMSA	VAPS	MHMT	MALS	MMMM	MMMM	MFDF	MFDF	Summary
Length of stay (days)	11	11	13	12	7	7	14	6	7	7	11	Mean 9.63 ± 2.87
Transfusion of erythrocyte concentrate (EC)	Yes	Yes	No	Yes	No	Yes	Yes	Yes	No	No	Yes	63.63% yes

observed in the patients in the present sample are in agreement with those in the scientific literature; in major studies on arthroplasties in high hip dislocations, the mean Harris Hip Score ranges between 83 and 95.^{5,6,20,27-32} Although satisfactory functional results have been observed, the literature reports important surgical complication rates in high hip dislocations (between 9% and 43%); these values are generally higher than those found in the present sample (complication rate of 18.18%). The main complications reported are prosthetic aseptic loosening, which ranges from 4.7% to 16%, and is more frequent for acetabular domes than for femoral stems, intraoperative fracture, neurovascular lesions, dislocation, infection, heterotopic ossification, non-consolidation of the osteotomy, and abductor apparatus insufficiency, among others.^{5,6,20,28-32} The two complications observed in the sample were due to traction movements or excessive traction of soft tissues during surgery, resulting in intraoperative fracture and neurapraxia. No cases of prosthetic loosening, infection, heterotopic ossification, or non-consolidation of the femoral osteotomy were observed in the present sample. As a consequence, while in the literature the revision rate of these arthroplasty ranges up to 26%, in the present sample none of the prostheses required revision to date.^{5,20,28-32} In turn, the care taken during surgery not to injure the retracted abductors (in particular gluteus medius, avoiding direct divulsion over it) and adequate rehabilitation of the abductor muscles allowed an important degree of functional recovery; it also caused the Trendelenburg sign recorded in this sample to be only slight, and likely recoverable after a period of progressive rehabilitation, which is in agreement with other similar studies.^{6,23,28} In addition, this study statistically demonstrated that the longer the duration of the hip dislocation, the lower the functional indexes of the Harris Hip Score after the mean follow-up time of this study (4.32 ± 2.67 years), which is probably due to the greater atrophy and retraction of the abductor muscles in a hip dislocated for a longer time and consequent greater difficulty in its rehabilitation when compared with dislocations with lower evolution time.

Long-term studies on arthroplasties in congenital hip dislocations using non-cemented prostheses are scarce; some of them are summarized below. Reikerås et al.,²⁰ in a prospective study over a mean follow-up time of 13 years (range 8-18) in 65 non-cemented arthroplasties in high hip dislocations using a subtrochanteric shortening femoral osteotomy, observed a mean Harris Hip Score of 87 and a complication rate of only 9%. Complications included 10 acetabular dome revisions due to aseptic loosening (that was not observed in any of the femoral stems), one case of recurrent dislocation, two cases of common fibular nerve neurapraxia, and one case of non-consolidation of the osteotomy. In turn, Ollivier et al.,⁵ in their retrospective study with a mean follow-up time of ten years (range 0.8-14.5) with 28 non-cemented arthroplasties

performed in high hip dislocations, concluded that although some complications were observed (29% complication rate), long-term outcomes were satisfactory (a statistically significant improvement in the mean Harris Hip Score from 43 in the preoperative period to 87), achieving a 10-year arthroplasty survival rate of 89%. Similarly, Eskelinen et al.²⁷ retrospectively studied 64 high dislocations that underwent non-cemented arthroplasties, with a mean follow-up time of 12.3 years, and obtained a statistically significant improvement in the mean Harris Hip Score from 54.2 in the preoperative period to 83.9 at the end of the follow-up time. Two-thirds of the patients in their sample presented total relief from pain complaints and only 8% of the patients had a positive Trendelenburg sign (compared to 84% preoperatively). The rate of perioperative complications was 19% and included three cases of common fibular nerve neurapraxia, one of the femoral nerve, and one of the gluteal nerve, four intraoperative fractures, one poorly positioned stem, one superficial infection, and two early dislocations. The 10-year survival rate of the femoral stems was 93.7% and of the acetabular domes, 87.8%. The authors identified significantly higher aseptic loosening rates in the non-cemented acetabular domes with screw fixation when compared with compared domes with porous coating; the 10-year survival rate of the latter was 94.9%. Only three cases of heterotopic ossification were observed.

Some studies report cases of non-consolidation of transverse osteotomies, probably due to insufficient rotational stability, and therefore recommend oblique rather than transverse osteotomies and some form of fixation.^{5,18,20,30,33} In the present study, all osteotomies were transverse and consolidated in a mean time of 3.27 ± 0.47 months. This rate is probably due to the quality of the stability achieved in osteotomies, either with the non-cemented conical stem (considered by the authors the stabilization of choice in osteotomy, without the need for osteosynthesis material due to its characteristics, which have already been described in the surgical technique), or with the use of fixation material; the rate is also probably due to the appropriate interval until weight-bearing on the operated limb was authorized, which happened only after consolidation of the osteotomy.

The main limitations of the present study are its retrospective nature, which did not allow a rigorous preoperative functional evaluation, the small sample size, and the short follow-up time. In turn, the fact that the arthroplasties were all performed by the same surgeon using the same surgical technique decreases some biases dependent on these factors.

Adequate indication, a technically well-performed surgery, without injury to the abductors, and the correct application of non-cemented prosthetic components to achieve a stable arthroplasty and obtain isometry of the lower limbs, as well as an adequate rehabilitation focused on the abductor apparatus, may be some factors that explain the satisfactory results

Table 4 – Clinical and functional results.						
	CMPB	CMPB	RMSA	RMSA	VAPS	MHMT
Harris Hip Score	94	91	85	87	93	83
Gait	Yes, without support		Yes, without support, slight Trendelenburg sign		Yes, without support	Yes, without support, slight Trendelenburg sign
Pain Relief Satisfaction index (1-5)	Yes, complete 5		Yes, incomplete 5		Yes, complete 5	Yes, complete 5
Osteotomy consolidation	Yes, 3 months	Yes, 3 months	Yes, 4 months	Yes, 3 months	Yes, 3 months	Yes, 4 months
	MALS	MMMM	MMMM	MFDF	MFDF	Summary
Harris Hip Score	81	93	91	85	91	Mean 88.55 ± 4.50
Gait	Yes, without support, slight Trendelenburg sign	Yes, without support	Yes, without support, slight Trendelenburg sign		100% without support; 57.14% slight Trendelenburg sign	
Pain relief Satisfaction index (1-5)	Yes, complete 5	Yes, complete 5	Yes, complete 4	100% yes, 85.71% complete and 14.29% incomplete Mean 4.86 ± 0.3		
Osteotomy consolidation	Yes, 3 months	Yes, 3 months	Yes, 3 months	Yes, 4 months	Yes, 3 months	100% yes, mean 3.27 ± 0.47

Table 5 – Complications.

CMPB	CMPB	RMSA	RMSA	VAPS	MHMT	MALS	MMMM	MMMM	MFDF	MFDF	Summary
No	No	Intraoperative fracture of the great trochanter, fixation with K-wire and tension band	No	No	No	No	Sciatic neurapraxia (pain and paresthesias that disappeared within two months)	No	No	No	18.18% complications: 9.09% iatrogenic fracture of the great trochanter; 9.09% sciatic neurapraxia

obtained in this series. The main surgical challenges in cases of high hip dislocation are the identification and creation of the acetabular cavity at the center of hip rotation (in the paleoacetabulum) and the femoral shortening osteotomy required to reduce the hip to the paleoacetabulum, while the greatest challenge in the postoperative period is the rehabilitation of abductor muscles that have atrophied, retracted, and weakened for decades due to the dislocated hip.⁶

Conclusion

Despite being a demanding surgery with a reported high rate of complications, hip arthroplasty in high congenital dislocation, when correctly indicated and technically well performed, allows an improvement in the functionality and quality of life of these patients.

Conflicts of interest

The authors declare no conflicts of interest.

REFERENCES

- Hartofilakidis G, Stamos K, Ioannidis TT. Low friction arthroplasty for old untreated congenital dislocation of the hip. *J Bone Joint Surg Br.* 1988;70(2):182-6.
- Hartofilakidis G, Stamos K, Karachalios T, Ioannidis TT, Zacharakis N. Congenital hip disease in adults. Classification of acetabular deficiencies and operative treatment with acetabuloplasty combined with total hip arthroplasty. *J Bone Joint Surg Am.* 1996;78(5):683-92.
- Hartofilakidis G, Karachalios T, Georgiades G, Kourlaba G. Total hip arthroplasty in patients with high dislocation: a concise follow-up, at a minimum of fifteen years, of previous reports. *J Bone Joint Surg Am.* 2011;93(17):1614-8.
- Hartofilakidis G, Babis GC, Lampropoulou-Adamidou K, Vlamis J. Results of total hip arthroplasty differ in subtypes of high dislocation. *Clin Orthop Relat Res.* 2013;471(9):2972-9.
- Ollivier M, Abdel MP, Krych AJ, Trousdale RT, Berry DJ. Long-term results of total hip arthroplasty with shortening subtrochanteric osteotomy in Crowe IV developmental dysplasia. *J Arthroplasty.* 2016;31(8):1756-60.
- Erdemli B, Yilmaz C, Atalar H, Güzel B, Cetin I. Total hip arthroplasty in developmental high dislocation of the hip. *J Arthroplasty.* 2005;20(8):1021-8.
- Hartofilakidis G, Yiannakopoulos CK, Babis GC. The morphologic variations of low and high hip dislocation. *Clin Orthop Relat Res.* 2008;466(4):820-4.
- Boyle MJ, Frampton CM, Crawford HA. Early results of total hip arthroplasty in patients with developmental dysplasia of the hip compared with patients with osteoarthritis. *J Arthroplasty.* 2012;27(3):386-90.
- Park MS, Kim KH, Jeong WC. Transverse subtrochanteric shortening osteotomy in primary total hip arthroplasty for patients with severe hip developmental dysplasia. *J Arthroplasty.* 2007;22(7):1031-6.
- Pagnano W, Hanssen AD, Lewallen DG, Shaughnessy WJ. The effect of superior placement of the acetabular component on the rate of loosening after total hip arthroplasty. *J Bone Joint Surg Am.* 1996;78(7):1004-14.
- Yoder SA, Brand RA, Pedersen DR, O'Gorman TW. Total hip acetabular component position affects component loosening rates. *Clin Orthop Relat Res.* 1988;(228):79-87.
- MacKenzie JR, Kelley SS, Johnston RC. Total hip replacement for coxarthrosis secondary to congenital dysplasia and dislocation of the hip. Long-term results. *J Bone Joint Surg Am.* 1996;78(1):55-61.
- Linde F, Jensen J. Socket loosening in arthroplasty for congenital dislocation of the hip. *Acta Orthop Scand.* 1988;59(3):254-7.
- Desteli EE, Imren Y, Tan E, Erdoğan M, Özcan H. Clinical results of cementless total hip arthroplasty with shortening osteotomy for high dislocation with developmental dysplasia. *Acta Orthop Belg.* 2015;81(1):30-5.
- Hartofilakidis G, Karachalios T. Total hip arthroplasty for congenital hip disease. *J Bone Joint Surg Am.* 2004;86(2):242-50.
- Cameron HU, Eren OT, Solomon M. Nerve injury in the prosthetic management of the dysplastic hip. *Orthopedics.* 1998;21(9):980-1.
- Edwards BN, Tullos HS, Noble PC. Contributory factors and etiology of sciatic nerve palsy in total hip arthroplasty. *Clin Orthop Relat Res.* 1987;(218):136-41.
- Krych AJ, Howard JL, Trousdale RT, Cabanela ME, Berry DJ. Total hip arthroplasty with shortening subtrochanteric osteotomy in Crowe type-IV developmental dysplasia: surgical technique. *J Bone Joint Surg Am.* 2010;92 Suppl 1 Pt 2:176-87.
- Argenson JN, Flecher X, Parratte S, Aubaniac JM. Anatomy of the dysplastic hip and consequences for total hip arthroplasty. *Clin Orthop Relat Res.* 2007;465:40-5.
- Reikerås O, Haaland JE, Lereim P. Femoral shortening in total hip arthroplasty for high developmental dysplasia of the hip. *Clin Orthop Relat Res.* 2010;468(7):1949-55.
- Harris WH, McCarthy JC Jr, O'Neill DA. Femoral component loosening using contemporary techniques of femoral cement fixation. *J Bone Joint Surg Am.* 1982;64(7):1063-7.
- Kuhfuss W, Grundlagen. Diagnostik, konservative und operative Behandlung. In: Tönnis D, editor. *Die angeborene Hüft-dysplasie und Hüftluxation im Kindes- und Erwachsenenalter.* Berlin Heidelberg, New York: Springer Verlag; 1984. p. 88.

23. Zagra L, Bianchi L, Mondini A, Ceroni RG. Oblique femoral shortening osteotomy in total hip arthroplasty for high dislocation in patients with hip dysplasia. *Int Orthop*. 2015;39(9):1797-802.
24. Wagner H, Wagner M. Cone prosthesis for the hip joint. *Arch Orthop Trauma Surg*. 2000;120(1-2):88-95.
25. Faldini C, Nanni M, Leonetti D, Miscione MT, Acri F, Giannini S. Total hip arthroplasty in developmental hip dysplasia using cementless tapered stem. Results after a minimum 10-year follow-up. *Hip Int*. 2011;21(4):415-20.
26. Yasgur DJ, Stuchin SA, Adler EM, DiCesare PE. Subtrochanteric femoral shortening osteotomy in total hip arthroplasty for high-riding developmental dislocation of the hip. *J Arthroplasty*. 1997;12(8):880-8.
27. Eskelinen A, Helenius I, Remes V, Ylinen P, Tallroth K, Paavilainen T. Cementless total hip arthroplasty in patients with high congenital hip dislocation. *J Bone Joint Surg Am*. 2006;88(1):80-91.
28. Sofu H, Kockara N, Gursu S, Issin A, Oner A, Sahin V. Transverse subtrochanteric shortening osteotomy during cementless total hip arthroplasty in Crowe type-III or IV developmental dysplasia. *J Arthroplasty*. 2015;30(6):1019-23.
29. Zhu J, Shen C, Chen X, Cui Y, Peng J, Cai G. Total hip arthroplasty with a non-modular conical stem and transverse subtrochanteric osteotomy in treatment of high dislocated hips. *J Arthroplasty*. 2015;30(4):611-4.
30. Baz AB, Senol V, Akalin S, Kose O, Guler F, Turan A. Treatment of high hip dislocation with a cementless stem combined with a shortening osteotomy. *Arch Orthop Trauma Surg*. 2012;132(10):1481-6.
31. Hasegawa Y, Iwase T, Kanoh T, Seki T, Matsuoka A. Total hip arthroplasty for Crowe type IV developmental dysplasia. *J Arthroplasty*. 2012;27(9):1629-35.
32. Charity JA, Tsiridis E, Sheeraz A, Howell JR, Hubble MJ, Timperley AJ, et al. Treatment of Crowe IV high hip dysplasia with total hip replacement using the Exeter stem and shortening derotational subtrochanteric osteotomy. *J Bone Joint Surg Br*. 2011;93(1):34-8.
33. Semenowicz J, Szymański S, Walo R, Czuma P, Pijet B. Total hip arthroplasty with shortening subtrochanteric Z osteotomy in the treatment of developmental dysplasia with high hip dislocation. *Ortop Traumatol Rehabil*. 2012;14(4):341-9.