



Original Article

Reliability of the radiographic union scale in tibial fractures (RUST)[☆]



Fernando Antonio Silva de Azevedo Filho^{a,b,*}, Ricardo Britto Cotias^a,
Matheus Lemos Azi^b, Armando Augusto de Almeida Teixeira^a

^a Hospital do Subúrbio, Salvador, BA, Brazil

^b Hospital Manoel Victorino, Salvador, BA, Brazil

ARTICLE INFO

Article history:

Received 13 April 2016

Accepted 3 May 2016

Available online 15 December 2016

Keywords:

Tibia

Fracture healing

Radiography

ABSTRACT

Objective: This study aimed to evaluate the inter- and intra observer reproducibility of the radiographic score of consolidation of the tibia shaft fractures.

Methods: Fifty-one sets of radiographs in anteroposterior (AP) and profile (P) of the tibial shaft treated with intramedullary nail were obtained. The analysis of X-rays was performed in two stages, with a 21-day interval between assessments by a group of nine evaluators. To evaluate the reproducibility of RUST score between the evaluators, the intra-class correlation coefficient (ICC) with a 95% confidence interval was used. ICC values range from +1, representing perfect agreement, to -1, complete disagreement.

Results: There was a significant correlation among all evaluators: ICC = 0.87 (95% CI 0.81 to 0.91). The intraobserver agreement proved to be substantial with ICC = 0.88 (95% CI 0.85 to 0.91).

Conclusion: This study confirms that the RUST scale shows a high degree of reliability and agreement.

© 2016 Sociedade Brasileira de Ortopedia e Traumatologia. Published by Elsevier Editora Ltda. This is an open access article under the CC BY-NC-ND license (<http://creativecommons.org/licenses/by-nc-nd/4.0/>).

Reprodutibilidade do escore radiográfico de consolidação das fraturas da tíbia (RUST)

RESUMO

Objetivo: Avaliar a reprodutibilidade inter e intraobservador do escore radiográfico de consolidação das fraturas (RUST) da diáfise da tíbia.

Métodos: Foram obtidos 51 conjuntos de radiografias nas incidências anteroposterior (AP) e perfil (P) da diáfise da tíbia tratadas com haste intramedular. A análise das radiografias foi feita em dois momentos, com intervalo de 21 dias entre as avaliações, por nove avaliadores.

Palavras-chave:

Tíbia

Consolidação da fratura

Radiografia

[☆] Study conducted at Hospital do Subúrbio, Salvador, BA, Brazil.

* Corresponding author.

E-mail: azevedofilho@gmail.com (F.A. Azevedo Filho).

<http://dx.doi.org/10.1016/j.rboe.2016.05.006>

2255-4971/© 2016 Sociedade Brasileira de Ortopedia e Traumatologia. Published by Elsevier Editora Ltda. This is an open access article under the CC BY-NC-ND license (<http://creativecommons.org/licenses/by-nc-nd/4.0/>).

Para avaliar a reprodutibilidade do escore RUST entre os avaliadores foi usado o coeficiente de correlação intraclasse (CCI) com intervalo de confiança de 95%. O valor do CCI varia de +1, que representa concordância perfeita, a -1, que corresponde a total discordância.

Resultados: Houve uma concordância significativa entre todos os avaliadores: CCI=0,87 (IC 95% 0,81 a 0,91). A concordância intraobservador mostrou-se substancial, com CCI=0,88 (IC 95% 0,85 a 0,91).

Conclusão: Este trabalho confirma que a escala RUST apresenta um elevado grau de confiabilidade e concordância.

© 2016 Sociedade Brasileira de Ortopedia e Traumatologia. Publicado por Elsevier Editora Ltda. Este é um artigo Open Access sob uma licença CC BY-NC-ND (<http://creativecommons.org/licenses/by-nc-nd/4.0/>).

Introduction

Tibial shaft fracture is the most common among those of long bones; it has a high incidence and mainly affects young males of working age. These injuries result from high-energy kinetic trauma, such as fall from height and car accidents; the latter are a major cause of fractures and lead to disability, with high socioeconomic costs.¹⁻⁶

The use of reamed locked intramedullary nails for the internal fixation in the treatment of tibia shaft fractures is well established in the literature.² Despite advances in surgical techniques, local anatomical conditions may contribute to the onset of complications, such as delayed consolidation and pseudoarthrosis.^{7,8}

The incidence of pseudoarthrosis after internal fixation with intramedullary nail has been reported in the literature as ranging from 5% to 33%, which often results in the need for secondary intervention or additional treatment to stimulate bone union.^{2,3,9,10}

Bone consolidation process is a simple biological phenomenon that occurs in stages: hematoma, inflammation, angiogenesis, cartilage formation (with subsequent calcification, cartilage removal, and then bone formation), and bone remodeling. Complete fracture healing may take several months, and only occurs after the completion of all stages.^{2,4,11}

From a clinical standpoint, a fracture can be considered consolidated at the end of the repair phase. The criteria used for this definition can be subdivided into clinical examination data (e.g., weight bearing without local pain and lack of mobility at the fracture site) and patient-related factors (quality of life).^{4,7,12,13}

Corrales et al.,¹³ in a review of 77 clinical studies that used clinical criteria to define the consolidation of long bone fractures, found that the three most commonly used criteria were absence of pain or tenderness with weight bearing, absence of pain or tenderness at the fracture site during the examination.

For the radiological evaluation of fractures, plain radiography remains the most common method to assess healing.⁷ Some authors suggest as a criterion to determine fracture consolidation the presence of at least three consolidated cortices observed in two radiographic views (anteroposterior [AP] and lateral [L]).¹⁴

Panjabi et al.,¹⁵ in an experimental study, demonstrated that cortical continuity was the best predictor of fracture healing, while callus area was the least important predictor.

McClelland et al.,¹⁵ when studying patients with tibial fractures treated with external fixation, observed a moderate correlation between radiographic healing and stiffness at the fracture site. These authors suggested that the presence of bone callus in two cortices was the best indicator to consider a fracture as healed.

Various scales and classifications have been proposed to define fracture consolidation, with a combination of radiographic criteria.^{5,7,9,10,16}

Kooistra et al.² recommend the use of the Radiographic Union Scale for Tibial Fractures (RUST) for assessing consolidation. This method evaluates two orthogonal radiographic views; each cortex is attributed points ranging from 1 to 3. A fracture in the immediate postoperative period will receive the minimum score, 4, and a fully consolidated considered fracture will be assigned the maximum score, 12. Studies show that RUST is a simple, systematic, and continuous indicator in the evaluation of tibial fractures treated with intramedullary nail.²

This study aimed to evaluate the inter- and intraobserver reproducibility of the RUST scale in patients treated with reamed locked intramedullary nail.

Material and methods

A retrospective study was conducted to evaluate the intra- and interobserver reproducibility of the RUST scale.

The study included radiographs of patients with fractures of the tibial shaft treated with reamed locked intramedullary nail, aged over 16 years, of both sexes; the exams had good technical quality, and were made during the follow-up period (eight weeks to nine months) in AP and L. Patients with pathological fractures, who presented infection or consolidation delay, or who evolved to pseudoarthrosis and needed a new procedure were excluded.

A total of 77 sets of AP and L radiographs of the tibial shaft of outpatients treated with intramedullary nails in 2014 were retrieved; 51 sets met all inclusion criteria. Exams were selected from the electronic hospital records, in various stages of consolidation.

Radiographs were made in two stages, with an interval of 21 days between assessments by nine evaluators: two first-year orthopedic and traumatology residents, two second-year residents, two third-year residents, and three traumatologists with over ten years of specialization.

Table 1 – Radiographic scale of tibial fracture consolidation.

Cortex	Visible fracture line, without callus Score = 1	Visible fracture line, with callus Score = 2	No fracture line, with visible callus Score = 3	Total score Minimum 4 Maximum 12
Lateral				
Medial				
Anterior				
Posterior				

Images were simultaneously presented to all evaluators in an air-conditioned environment using Sony VPL-DX130B® image projector. Radiographs in AP and L of each patient were projected simultaneously, with one minute for each evaluation.

The RUST scale assigns a score for a given set of AP and L radiographs, based on the assessment of healing in each of the four cortices visible on these projections (medial and lateral cortices in AP, and anterior and posterior cortices in L). Each cortex is assigned 1 point if a fracture line without the presence of callus is observed; 2, if there is callus, but a fracture line is still visible; and 3, if there is callus with no evidence of fracture line (Table 1).

The scores on each cortex are added, resulting in a total value for each set of radiographs; 4 is the minimum score, indicative that the fracture is not healed and 12 is the maximum score, indicating that the fracture completely cured.^{2,10,17} A score ≥ 7 is equivalent to a minimum of three

cortices with bone callus. A fracture with this score can be considered as radiologically consolidated¹⁷ (Fig. 1).

The examiners did not have access to patient history, age, fracture time, and any other clinical information. Radiographs were identified by numbers and only the main researcher had access to this identification.

The interobserver reproducibility was assessed by comparing the total scores of each observer obtained in the initial visualization of the radiographs. The intraobserver reproducibility was determined by the comparison of the scores of the first and second evaluation by each participant.

To evaluate the reproducibility of the RUST score among raters, the intraclass correlation coefficient (ICC) was used with a 95% confidence interval. ICC values range from +1, representing perfect agreement, to -1, complete disagreement.

The study was approved by the Research Ethics Committee of the Health Secretariat of the State of Bahia, Opinion No. 788,655.

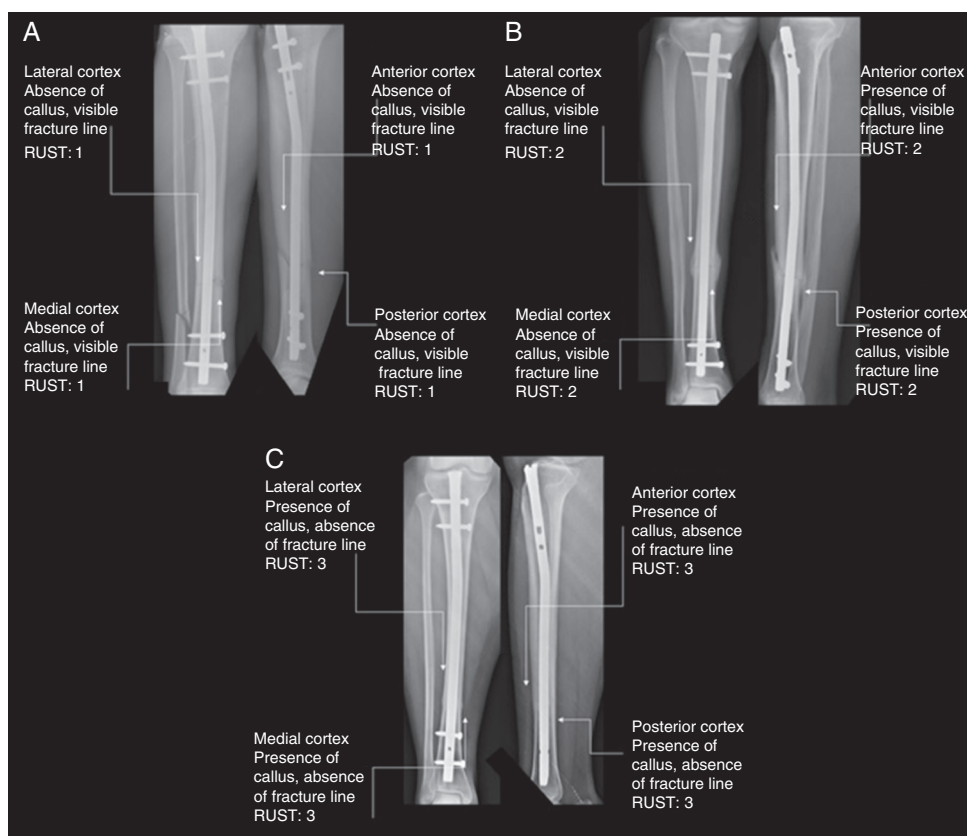


Fig. 1 – RUST score in three phases of consolidation: A = 4; B = 8; C = 12.

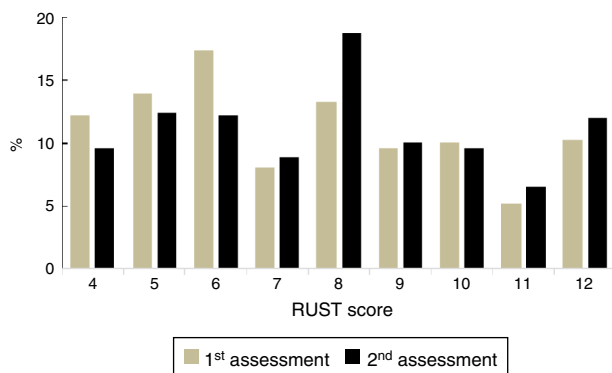


Fig. 2 – Distribution of the RUST score in the 1st and 2nd assessment.

Table 2 – RUST score inter- and intra-observer interclass correlation coefficient.

	Inter-observer ICC 95% CI	Intra-observer ICC 95% CI
Traumatologists	0.94 (0.90–0.96)	0.94 (0.91–0.95)
3rd year-resident	0.90 (0.84–0.94)	0.83 (0.71–0.90)
2nd year-resident	0.92 (0.87–0.95)	0.89 (0.84–0.93)
1st year-resident	0.80 (0.67–0.88)	0.87 (0.79–0.90)
General	0.87 (0.81–0.91)	0.89 (0.85–0.91)

Results

The RUST score of the 51 sets of radiographs (AP and L) ranged from 4 to 12, with a score of 7.53 ± 2.53 (median 7) in the first assessment and 7.88 ± 2.49 (median 8) in the second (Figs. 2 and 3).

There was a significant correlation among the evaluators, with ICC of 0.87 (95% CI: 0.81–0.91). Among traumatologists, there was greater reliability when compared with first-, second-, and third-year residents (ICC: 0.94, 0.80, 0.92, and 0.90, respectively; Table 2).

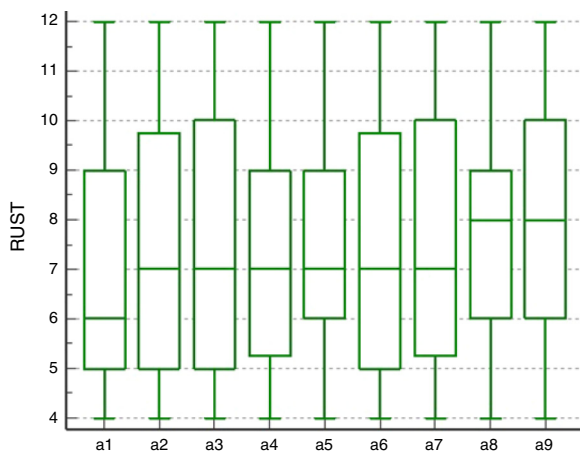


Fig. 3 – Comparison of the mean RUST score among evaluators. a1, a2, a3; traumatologists; a4, a5, third-year residents; a6, a7, second-year residents; a8, a9, first-year residents.

Intraobserver agreement was substantial, with ICC of 0.88 (95% CI: 0.85–0.91). By analyzing the evaluators according to the degree of training, it was observed that traumatologists showed a near-perfect reproducibility (ICC 0.94; 95% CI 0.91 to 0.95). Among the residents, the highest ICC was observed for second-year residents (ICC 0.89), followed by first-year (ICC 0.87) and finally third-year (ICC 0.83; Table 2).

Discussion

Despite the numerous studies related to the development of scales to assess the radiographic consolidation of tibial fractures, a reliable and effective method, a gold standard, is not yet established in the literature.^{18,19}

The definition of radiological union is inconsistent due to the degree of imprecision of the selected variables. Some investigations use a single parameter, such as the presence of callus in at least two cortices.⁵

Several variables are observed when analyzing the evolution of fracture healing, including number of consolidated cortices and presence of bone callus and fracture line.^{17,18} Based on these parameters, Kooistra et al.² developed a radiographic scale to determine the consolidation of tibial shaft fractures, the RUST scale. Using the presence of callus in each cortex, associated with the presence of a fracture line, the hypothesis that the RUST scale would present greater validity and reliability than other proposed systems was raised.

The RUST scale assesses the fracture unequivocally and completely. It presents some advantages when compared with other methods, among which stands out the fact that each cortex is evaluated separately, making the scale more reliable, since each individual cortex contributes to the final score. This classification is easy to apply, with high inter- and intraobserver agreement.^{2,10,17-19}

Whelan et al.¹⁰ assessed the reproducibility of the RUST scale when using radiographs of 45 patients treated with locked intramedullary nails. They observed a correlation among all evaluators (ICC: 0.86, 95% CI: 0.79 to 0.91), with a trend toward greater reliability for traumatologists when compared with orthopedic surgeons and residents, a result similar to that found in the present study. Ali et al.¹⁸ corroborated these results when assessing the reproducibility between orthopedic surgeons and radiologists. When evaluating radiographs with conservative treatment for fractures of the tibia, they observed a significant interobserver correlation. Macri et al.¹⁷ observed an interobserver agreement, assessed by ICC, of 0.93 (95% CI: 0.89 to 0.96).

The ability to bear weight on the fractured limb is directly related to the bone consolidation phase. This inability can cause changes in gait; therefore, gait pattern may be a practical way of monitoring fracture healing. A strong association between gait pattern and RUST score has been observed.¹⁷

By correlating the clinical and radiological criteria, Cekic et al.¹⁹ observed that the RUST score corresponds directly to the clinical conditions of the patients. Callus in two or three cortices were not observed in the images of patients who had a high pain index, indicating the accuracy of this score regarding both the clinical and radiological consolidation.

Conclusion

The present study confirmed that the RUST score features a high degree of reliability and compliance. As there is no gold standard radiographic classification to evaluate the healing of tibial fractures, the authors suggest that this is a useful functional tool, but more research relating the radiographic findings on clinical examination is needed to establish it as an essential tool in daily practice.

Conflicts of interest

The authors declare no conflicts of interest.

REFERENCES

- Court-Brown CM, Rimmer S, Prakash U, McQueen MM. The epidemiology of open long bone fractures. *Injury*. 1998;29(7):529-34.
- Kooistra BW, Dijkman BG, Busse JW, Sprague S, Schemitsch EH, Bhandari M. The radiographic union scale in tibial fractures: reliability and validity. *J Orthop Trauma*. 2010;24 Suppl. 3:S81-6.
- Chua W, Murphy D, Siow W, Kagda F, Thambiah J. Epidemiological analysis of outcomes in 323 open tibial diaphyseal fractures: a nine-year experience. *Singapore Med J*. 2012;53(6):385-9.
- Kojima KE, Ferreira RV. Fraturas da diáfise da tibia. *Rev Bras Ortop*. 2011;46(2):130-5.
- Whelan DB, Bhandari M, McKee MD, Guyatt GH, Kreder HJ, Stephen D, et al. Interobserver and intraobserver variation in the assessment of the healing of tibial fractures after intramedullary fixation. *J Bone Joint Surg Br*. 2002;84:15-8.
- Zeckey C, Mommsen P, Andruszkow H, Macke C, Frink M, Stübig T, et al. The aseptic femoral and tibial shaft non-union in healthy patients – an analysis of the health-related quality of life and the socioeconomic outcome. *Open Orthop J*. 2011;5:193-7.
- Dijkman BG, Sprague S, Schemitsch EH, Bhandari M. When is a fracture healed? Radiographic and clinical criteria revisited. *J Orthop Trauma*. 2010;24 Suppl. 3:S76-80.
- Antonova E, Kim Le T, Burge R, Mershon J. Tibia shaft fractures: costly burden of nonunions. *BMC Musculoskelet Disord*. 2013;14:42.
- Davis BJ, Roberts PJ, Moorcroft CI, Brown MF, Thomas PB, Wade RH. Reliability of radiographs in defining union of internally fixed fractures. *Injury*. 2004;35(6):557-61.
- Whelan DB, Bhandari M, Stephen D, Kreder H, McKee MD, Zdero R, et al. Development of the radiographic union score for tibial fractures for the assessment of tibial fracture healing after intramedullary fixation. *J Trauma*. 2010;68(3):629-32.
- Phillips AM. Overview of the fracture healing cascade. *Injury*. 2005;36 Suppl. 3:S5-7.
- Bhandari M, Guyatt GH, Swiontkowski MF, Tornetta P 3rd, Sprague S, Schemitsch EH. A lack of consensus in the assessment of fracture healing among orthopaedic surgeons. *J Orthop Trauma*. 2002;16(8):562-6.
- Corrales LA, Morshed S, Bhandari M, Miclaui T 3rd. Variability in the assessment of fracture-healing in orthopaedic trauma studies. *J Bone Joint Surg Am*. 2008;90(9):1862-8.
- Hungria JOS, Mercadante MT. Fratura exposta da diáfise da tibia – Tratamento com osteossíntese intramedular após estabilização provisória com fixador externo não transfixante. *Rev Bras Ortop*. 2013;48(6):82-90.
- Panjabi MM, Walter SD, Karuda M, White AA, Lawson JP. Correlations of radiographic analysis of healing fractures with strength: a statistical analysis of experimental osteotomies. *J Orthop Res*. 1985;3(2):212-8.
- Freedman EL, Johnson EE. Radiographic analysis of tibial fracture malalignment following intramedullary nailing. *Clin Orthop Relat Res*. 1995;(315):25-33.
- Macri F, Marques LF, Backer RC, Santos MJ, Belangero WD. Validation of a standardised gait score to predict the healing of tibial fractures. *J Bone Joint Surg Br*. 2012;94(4):544-8.
- Ali S, Singh A, Agarwal A, Parihar A, Mahdi AA, Srivastava RN. Reliability of the RUST score for the assessment of union in simple diaphyseal tibial fractures. *IJBR*. 2014;5(5):333-5.
- Çekic E, Alici E, Yesil M. Reliability of the radiographic union score for tibial fractures. *Acta Orthop Traumatol Turc*. 2014;48(5):533-40.