



Original article

Evaluation of postoperative results from videoarthroscopic treatment for recurrent shoulder dislocation using metal anchors[☆]



Éder Menegassi Martel*, Airton Rodrigues, Francisco José dos Santos Neto, Cleiton Dahmer, Abel Ranzzi, Rafaella Scuzziato Dubiela

Hospital Ortopédico de Passo Fundo, Passo Fundo, RS, Brazil

ARTICLE INFO

Article history:

Received 23 February 2015

Accepted 31 March 2015

Available online 13 January 2016

Keywords:

Suture anchors

Shoulder dislocation

Recurrence

Osteoarthritis

ABSTRACT

Objective: To clinically and radiologically evaluate the results from videoarthroscopic treatment using metal anchors in patients with recurrent shoulder dislocation and its complications.

Methods: This was a retrospective study on 47 patients (47 shoulders) operated by the shoulder group of the orthopedic hospital between February 2010 and February 2012. A questionnaire, interview and physical and radiographic examinations were used, with the classification of Samilson and Pietro. The mean postoperative follow-up was 33 months (range 12–47 months). The statistical analysis consisted of using Fisher's exact test through the IBM SPSS 22 statistical software. The significance level used was 5%.

Results: Recurrence was observed in nine cases. The patients were, on average, 26.5 years old at the first episode, and 19.1% were aged 20 years or under. Among these, 55.6% presented recurrence. In relation to age at the time of the surgical procedure, the average age was 27 years, and 12.8% were aged 20 years or under. Nineteen patients presented prominent anchors and, of these, 21% manifested arthrosis.

Conclusion: There was a statistically identified correlation between the recurrence rate and age less than or equal to 20 years at the times of first dislocation and the surgical procedure. Further studies should be conducted in order to compare the use of absorbable anchors, which despite higher cost, may provide lower risk of developing glenohumeral arthrosis in some cases.

© 2016 Sociedade Brasileira de Ortopedia e Traumatologia. Published by Elsevier Editora Ltda. All rights reserved.

[☆] Work performed in the Shoulder and Elbow Group, Hospital Ortopédico de Passo Fundo, Passo Fundo, RS, Brazil.

* Corresponding author.

E-mail: ombro.psf@gmail.com (É.M. Martel).

<http://dx.doi.org/10.1016/j.rboe.2015.03.015>

2255-4971/© 2016 Sociedade Brasileira de Ortopedia e Traumatologia. Published by Elsevier Editora Ltda. All rights reserved.

Avaliação de resultados pós-operatórios do tratamento videoartroscópico para luxação recidivante de ombro com o uso de âncoras metálicas

R E S U M O

Palavras-chave:

Âncoras de sutura
Luxação do ombro
Recidiva
Osteoartrite

Objetivos: Avaliar clínica e radiologicamente os resultados do tratamento videoartroscópico com uso de âncoras metálicas em pacientes com luxação recidivante de ombro e suas complicações.

Métodos: Estudo retrospectivo de 47 pacientes (47 ombros) operados de fevereiro de 2010 a fevereiro de 2012 pelo grupo do ombro do hospital ortopédico, por meio de questionário, entrevista, exame físico e radiográfico, com o uso da classificação de Samilson e Pietro. O seguimento médio no pós-operatório foi de 33 meses (variação de 12-47). A análise estatística consistiu no uso do teste exato de Fisher por meio do pacote estatístico IBM SPSS 22, com o uso de um nível de significância de 5%.

Resultados: Recidiva foi observada em nove casos. Os pacientes tinham, em média, 26,5 anos no primeiro episódio, dos quais 19,1% apresentavam idade menor ou igual a 20 anos. Dentre estes, 55,6% apresentaram recidiva. Em relação à idade no procedimento cirúrgico, foi encontrada uma média de 27 anos; 12,8% apresentavam idade menor do que ou igual a 20 anos; 19 pacientes apresentaram âncoras salientes e desses 21% manifestavam artrose.

Conclusão: Houve correlação estatisticamente identificada entre o índice de recidiva e a idade menor ou igual a 20 anos no momento da primo-luxação e do procedimento cirúrgico. Mais estudos devem ser feitos para comparar uso de âncoras absorvíveis, que, apesar de ter um custo mais elevado, podem ter um risco menor de desenvolvimento de artrose glenoumeral em alguns casos.

© 2016 Sociedade Brasileira de Ortopedia e Traumatologia. Publicado por Elsevier Editora Ltda. Todos os direitos reservados.

Introduction

Primary anterior shoulder dislocation usually occurs among young adults during contact sports or among elderly individuals due to low-energy falls. Anterior dislocation among elderly people has peculiar complications, while recurrent instability is a particular problem of young adults.¹

Instability symptoms develop during the first two years after the primary dislocation, and this is considered to be the main prognostic factor in determining the risk of recurrent instability. The exact recurrence rate remains uncertain, but it ranges from 3.9% to 3.0% in the literature.²⁻⁸

Over the last three decades, there have been great advances in the development of videoarthroscopy techniques. The improvements in the quality of the surgical implants and the increasing level of experience of surgeons have contributed toward obtaining results from treating shoulder instability that are more satisfactory.¹

The advent of metal anchors has made it possible to replace the transosseous suturing technique, especially in cases of glenohumeral instability and rotator cuff injuries.^{9,10} However, this material does not inherently lead to complications such as loosening, breakage, migration and, especially incorrect positioning inside the joint, which gives rise to friction against the humeral head or glenoid cavity and causes varying degrees of chondral lesion and early glenohumeral arthrosis.^{11,12}

The present study comprised a retrospective evaluation of factors that might influence the surgical results among patients undergoing videoarthroscopic treatment of recurrent shoulder dislocation with use of metal anchors. The findings

and clinical repercussions reported in the literature were discussed.

Methods

In this retrospective study, 47 patients (47 shoulders) out of the 60 operated by the shoulder and elbow group of an orthopedic hospital were evaluated. The other 17 patients were lost during the follow-up (Fig. 1). The medical files of patients who underwent videoarthroscopic treatment using metal anchors between February 2010 and February 2012 were reviewed.

Patients with recurrent shoulder instability and a minimum postoperative follow-up of 12 months were included in the study, without regard for sex. Patients who received absorbable anchors, cases of osteoarthrosis seen on radiographs before the operation and cases presenting other pathological conditions of the rotator cuff, neck or brachial plexus were excluded.

The patients were attended by or underwent surgery performed by three physicians in the shoulder and elbow group, at their places of attendance in Passo Fundo (Rio Grande do Sul). The patients were classified according to the presence or absence of recurrence after the treatment. The mean length of postoperative follow-up was 33 months, with a range from 12 to 47. All the patients underwent a preoperative clinical evaluation for their instability to be diagnosed and classified, and also a radiographic evaluation in anteroposterior view (true AP) and lateral view (scapular and axillary). The technique used was videoarthroscopic repair of the lesion using metal anchors, along with capsuloplasty.^{13,14}

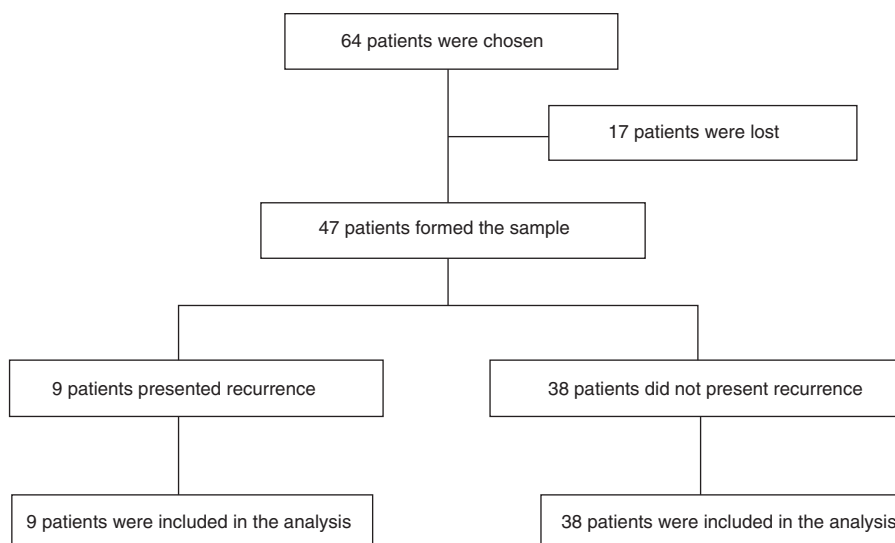


Fig. 1 – Characteristics of the study.

During the evaluation, a questionnaire was applied to the patients to characterize the sample. The issues addressed included personal data, age, occupation, sports practice, dominance, number of anchors, traumatic or non-traumatic preoperative episodes of dislocation and a visual pain scale. The physical examination consisted of bilateral evaluation of the range of motion, apprehension test, relocation test, sulcus test, anterior and posterior drawer test, hyperlaxity (lateral rotation $>85^\circ$) and hyperabduction test. The patients were also evaluated radiographically regarding the positioning of the anchors, existence of bone alterations in the glenohumeral cavity and signs of arthrosis as described by Samilson and Prieto¹⁵ (Table 1).

All the participants signed a free ad informed consent statement before any evaluation relating to the study was performed. The project was properly approved by the Research Ethics Committee of the University of Passo Fundo, through the Brazil Platform, on January 8, 2014 (CAAE: 19258813.1.0000.5342).

Surgical technique

The surgical procedure was performed with the patient under general anesthesia and brachial plexus block, positioned in lateral decubitus on the side opposite to the affected shoulder. On the surgical table, vertical and longitudinal traction

were applied and the limb was kept positioned in abduction of approximately 30° and flexion of 15° .

A posterior portal was used for videoarthroscopy, located 2 cm distally and 2 cm medially to the posterolateral angle of the acromion. In the anterior region of the shoulder, another two portals were opened in order to place cannulae. These were always kept laterally to the coracoid process in order to minimize possible vessel and nerve lesions. Before the cannulae were emplaced, the joint was investigated, taking the reference point of the long tendon of the biceps and its superior labral insertion. The anterior, inferior and posterior labra, joint surfaces, ligaments, capsule, recesses and rotator cuff were then evaluated.

Following this, the optical device was taken to the antero-superior portal and the irrigation was moved to the posterior portal, for a wider view of the anterior labrum, which was highlighted and then opened up using a shaver blade in order to obtain a bed suitable for healing of the reinserted capsulolabral complex. The same procedure was performed on the surface of the glenoid border, from where the labrum had originally been deinserted. In this, in addition to debridement of the remaining soft tissues, we also used an abrasion blade to scarify the subchondral bone.

After the debridement that was necessary had been performed, the labrum was reinserted into its origin, by means of a suturing technique using anchors. We preferentially used three metal anchors of dimensions 2.7 mm \times 5.0 mm loaded with Fiber Wire[®] no. 2. Plication of the capsule was done in conjunction with the labral suturing technique in the cases that presented with three or more episodes of dislocation. Sliding Giant knots were used for fixation.¹⁶

Following this, the portals were sutured, dressings were applied and immobilization using a Velpeau sling for 30 days was implemented. The rehabilitation program was started after the 30th postoperative day. Non-steroidal anti-inflammatory drugs were prescribed for five days, along with non-opioid analgesics and opioid analgesics in cases of post-operative pain.

Table 1 – Radiological classification of Samilson and Pietro.

Type I	Mild arthrosis: inferior humeral exostosis and/or glenoid exostosis measuring <3 mm in height.
Type II	Moderate arthrosis: inferior humeral exostosis and/or glenoid exostosis measuring 3 mm to 7 mm with slight glenohumeral irregularity.
Type III	Severe arthrosis: inferior humeral exostosis and/or glenoid exostosis measuring >7 mm with joint narrowing and glenohumeral sclerosis.

Table 2 – Patients' characteristics.

Characteristics	Recurrence (n = 9)	Non-recurrence (n = 38)	Total (n = 47)	p
<i>Age at time of first episode – n (%)</i>				
≤20 years	5 (55.6)	4 (44.4)	9 (19.1)	0.007 ^a
>20 years	4 (10.5)	34 (89.5)	38 (80.9)	
<i>Age at the time of the surgery – n (%)</i>				
≤20 years	4 (66.7)	2 (33.3)	6 (12.8)	0.009 ^a
>20 years	5 (12.2)	36 (87.8)	41 (87.2)	
<i>Sex – n (%)</i>				
Male	8 (18.6)	35 (81.4)	43 (91.5)	1.000
Female	1 (25.0)	3 (75.0)	4 (8.5)	
<i>Dominance – n (%)</i>				
Yes	4 (20.0)	16 (80.0)	20 (42.5)	1.000
No	5 (18.5)	22 (81.5)	27 (57.5)	
<i>Episodes of instability – n (%)</i>				
≤3	1 (7.7)	12 (92.3)	13 (27.7)	0.41
>3	8 (23.5)	26 (76.5)	34 (72.3)	
<i>Sport – n (%)</i>				
Contact/throwing	4 (14.8)	23 (85.2)	27 (57.4)	0.465
Others	5 (25.0)	15 (75.0)	20 (42.6)	
<i>Competition – n (%)</i>				
Professional	2 (33.3)	4 (66.7)	6 (12.8)	0.322
Recreational	7 (17.1)	34 (82.9)	41 (87.2)	
<i>Reoperation</i>				
Yes	6 (66.7)	2 (5.3)	8 (17.0)	0.004 ^a
No	3 (33.3)	36 (94.7)	39 (83.0)	

Fisher's exact test.
^a Significant value, for $p \leq 0.05$.

Methodology of the statistical analysis

The data analysis was done by means of the IBM SPSS 22 statistic package. Fisher's exact test was used to analyze associations between the variables. The significance level used was $p \leq 0.05$.

Results

During the study period, 47 patients were analyzed. Among these, nine (19.1%) presented recurrence. The patients' mean age at the time of the first episode was 26.5 years, and 19.1% of them were of ages less than or equal to 20 years. Among these patients whose ages were less than or equal to 20 years at the time of the first dislocation, 55.6% presented recurrence. This was statistically significant: $p = 0.007$; $RR = 5.278$; $95\% \text{ CI} = [1.764; 15.789]$ (Table 2).

The patients' mean age at the time of the surgical procedure was 27 years, with a minimum age of 17 years and a maximum of 52 years; 12.8% presented ages less than or equal to 20 years. These patients represented 66.7% of the group that presented recurrence, and this proportion was statistically significant, with a chance of recurrence that was approximately 5.5 times greater: $p = 0.009$; $RR = 5.467$; $95\% \text{ CI} = [2.016; 14.821]$.

In this sample, four women and 43 men underwent operations, and this did not shown any statistically significant difference through Fisher's exact test. Eight cases of

recurrence ($n = 9$) were among men; 81.4% of the men and 75% of the women did not present recurrence. The dominant side was involved in 20 patients (42.5%). There was no association, from a statistical point of view, between recurrence and dominance ($p = 1.000$).

Regarding the number of episodes of instability, 34 patients presented more than three episodes and, of these, 23.5% presented recurrence. However, 92.3% of the patients with three or fewer episodes did not present recurrence. No statistical difference was found.

In analyzing the relationship between the presence of bone lesions in the glenoid and recurrences, 90.5% of the patients who presented lesions were among those who did not present. There was no statistically significant correlation ($p = 0.519$). Equally, there was no statistical significance with regard to shoulders that presented Hill-Sachs lesion. Only 12% were in the group that presented recurrence ($p = 0.216$) (Table 3). One patient presented a diagnosis of associated SLAP lesion, which was repaired at the time of the surgery and presented good evolution.

There were reports of pain in 31.9% of the cases. The mean number of anchors was 3.1 (range from 2 to 5). In the group with recurrences, the number of anchors ranged from two to three (mean of 2.9). Five of the new recurrences were associated with trauma.

Among the complications, the presence of postsurgical osteoarthritis and salient anchors (Table 3) and the presence of salient anchors in shoulders with arthrosis (Table 4) were

Table 3 – Complications/radiographic findings.

Complications/radiographic findings	Recurrence (n=3)	Non-recurrence (n=38)	Total (n=41)	p
<i>Salient anchor – n (%)</i>				
Yes	1 (5.3)	18 (94.7)	19 (46.3)	0.556
No	2 (9.1)	20 (90.9)	22 (53.7)	
<i>Arthrosis/Samilson I – n (%)</i>				
Yes	0 (0.0)	4 (100.0)	4 (9.8)	0.729
No	3 (8.1)	34 (91.9)	37 (90.2)	
<i>Glenoid lesions</i>				
Yes	2 (9.5)	19 (90.5)	21 (51.2)	0.519
No	1 (5.0)	19 (95.0)	20 (48.8)	
<i>Hill-Sachs</i>				
Yes	3 (12.0)	22 (88.0)	25 (61.0)	0.216
No	0 (0.0)	16 (100.0)	16 (39.0)	

Fisher's exact test.
Significant value, for $p \leq 0.05$.

Table 4 – Arthrosis in shoulders with salient anchors.

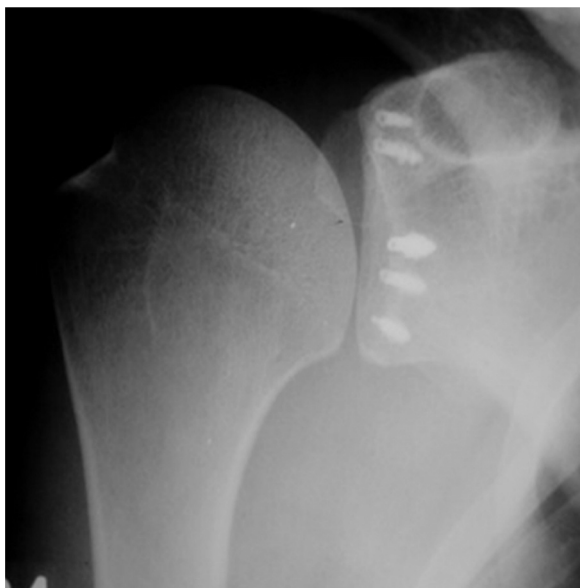
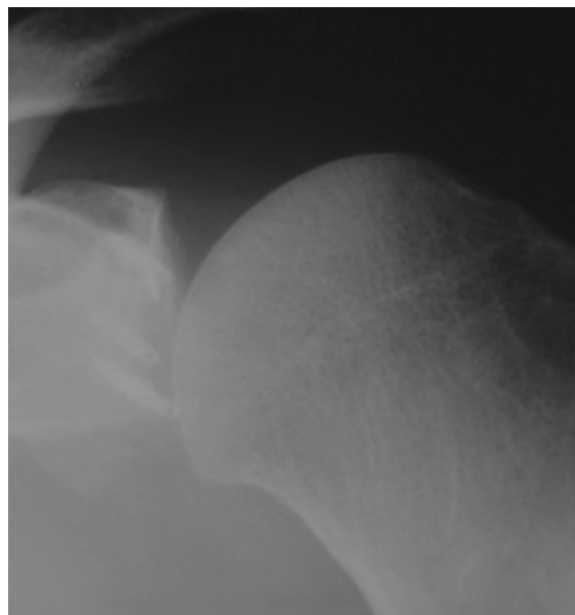
Characteristic	Arthrosis/Samilson I- n (%)		Total	p
	Yes	No		
<i>Salient anchor – n (%)</i>				
Yes	4 (21.1)	15 (78.9)	19 (46.3)	0.038 ^a
No	0 (0.0)	22 (100.0)	22 (53.7)	

Fisher's exact test.
^a Significant value, for $p \leq 0.05$.

analyzed. We also found one patient with a broken anchor, who presented good evolution.

Furthermore, in relation to the presence of prominent intra-articular anchors (Fig. 2), the results did not show statistically significant values among the variables tested. It should be noted that only one case of prominence of an anchor was

found in the group of recurrences, and there were 19 cases in total. Among the 19 patients who presented salient anchors, 21.1% (four) presented arthrosis (Fig. 3), which was statistically significant, with $p=0.038$ (RR=0.789; 95% CI=[0.626; 0.996]). Thus, presence of a salient anchor represented a risk factor for development of arthrosis after the operation.

**Fig. 2 – View of intra-articular salient anchors.****Fig. 3 – Initial arthrosis due to salient anchors.**

Discussion

Videarthroscopic treatment for anterior shoulder dislocation is a matter of controversy. Thus, any procedure that has the aim of stabilizing the glenohumeral joint should do so with a minimum of loss of movement.¹⁴

In the present study, nine patients (19.1%) presented recurrence. Three of them have so far chosen not to undergo a new surgical intervention and six have undergone open repair using a bone graft. In a sample of 106 patients treated using the stapling technique in 1982, Johnson¹⁷ (who was one of the pioneers of videarthroscopic repair for traumatic anterior instability) showed a recurrence rate of 21%. Koss et al.⁶ studied 27 patients who underwent arthroscopic repair of Bankart lesions and reported that the recurrence rate was 30%. Following the same trend, Sadvovsk et al.⁷ reviewed 77 patients who had been treated videarthroscopically and found a recurrence rate of 3.9%. Tan et al.⁸ found that videarthroscopic anterior stabilization of the shoulder seemed to be effective, with a failure rate of 9%; 85% of their patients returned to their sports activities. They observed that absorbable and non-absorbable anchors seemed to be equally effective, without any significant differences.

We found that failure of postoperative stabilization occurred in 19.1%. This percentage was in line with the literature with regard to repairs using anchors, given that the rates presented have ranged from 3.9% to 30%.⁶⁻⁸ Among the patients who presented recurrence and underwent open repair, the Latarjet technique was applied in five cases and the Bristow technique in one case, so far without any recurrences. However, Griesser et al.¹⁸ conducted a systematic review on the original or modified procedures of Bristow and Latarjet, which are currently considered to be the gold standard for repairing bone lesions, and found that there was a substantial risk of complications (30%), including recurrent dislocation (2.9%) and reoperation (6.9%).

In a randomized prospective series of 40 patients, Magnusson et al.¹⁹ compared two different videarthroscopic techniques for treating Bankart lesions using bioabsorbable and non-absorbable implants, in relation to function and arthropathy. The patients were evaluated six and 24 months after the operation, and recurrence of dislocation was found in 5%. Arthropathy was reported in 30% (five mild cases and one moderate case) in the non-absorbable group and in 33% in the absorbable group (six mild cases).

In a systematic review with meta-analysis on 62 studies with 3044 videarthroscopy procedures, Hobby et al.²⁰ concluded that the most effective techniques for videarthroscopic stabilization had failure rates similar to that of open stabilization, after two years of follow-up.

In a retrospective review article on 570 patients, Buscayret et al.²¹ reported that the incidence of glenohumeral arthropathy was 19.7% after a mean follow-up of 6.5 years, subsequent to an operation to obtain anterior shoulder stabilization using a variety of metal anchors. Kaar et al.¹¹ described eight cases of complications from use of metal anchors: three of these evolved with chondral lesions of the humeral head, among which two were due to mechanical friction from the anchors and one was due to associated infection.

Table 5 – Instability Severity Index Score (ISIS), from preoperative evaluation.

Prognostic factors	Points
<i>Age at time of surgery (years)</i>	
≤ 20 years	2
> 20 years	0
<i>Degree of participation in sports^a</i>	
Competitive	2
Recreational or none	0
<i>Type of sport^a</i>	
Contact	1
Other	0
<i>Hyperlaxity</i>	
Hyperlaxity (anterior or inferior)	1
Normal laxity	0
<i>Hill-Sachs on AP radiographs</i>	
Visible through external rotation	2
Not visible through external rotation	0
<i>Loss of outline of glenoid on AP radiographs</i>	
Loss of outline	2
No lesion	0
Total (points)	10

AP, anteroposterior.

^a Degree of participation in sports and type of sport were evaluated before the operation.

In a retrospective study on eight patients, Ejnisman et al.²² concluded that improper insertion of metal anchors in glenohumeral surgical procedures for fixation of labral lesions could lead to extensive arthropathy of the shoulder joint. Thus, with delays in reaching the correct diagnosis, this could lead to early glenohumeral arthropathy.

In our study, we found four patients (21.1%) with arthropathy. We only found type I arthropathy, probably because of the short postoperative period of up to 47 months. Two patients evolved with arthropathy, even after repositioning of the anchors. The interval between the first and second surgical procedures was six to eight months. Furthermore, presence of salient anchors was shown on radiographs in the cases of 19 patients (46.3%). However, only four patients (21.1%) developed arthropathy. This suggests that salient anchors seen on radiographs are not a good predictor for evolution of glenohumeral arthropathy. Thus, videarthroscopy would be the preferred method for diagnosing poorly placed anchors, since this provides direct viewing of the glenohumeral joint.

Burkhart and De Beer²³ analyzed 194 cases of videarthroscopic repairs of Bankart lesions and concluded that patients who were candidates for videarthroscopic surgery needed to be free from significant bone failures (Hill-Sachs or Bankart lesions in which the glenoid has the shape of an inverted pear), and that contact athletes without bone lesions could be treated using this method. They also concluded that the Latarjet procedure should be reserved for patients with significant bone loss from the glenoid.

Balg et al.²⁴ conducted a prospective case-control study on 131 patients who underwent videarthroscopic reconstruction to treat anterior shoulder instability using sutures with anchors, among whom there was a recurrence rate

of 14.5%. They identified six risk factors that predicted an increased recurrence rate and created the Instability Severity Index Score (ISIS), which ranged from 0 to 10 points (Table 5). They concluded that scores greater than six points represented a recurrence risk of 70% after videoarthroscopic repair.

In a recent review of ten articles that compared absorbable and non-absorbable anchors, Papalia et al.²⁵ concluded that it was not possible to suggest which method would be the one recommended for routine use. Thus, the cost-benefit relationship would need to be taken into consideration.

Longo et al.²⁶ conducted a systematic review on 46 articles that dealt with different techniques for recurrent shoulder dislocation. They concluded that the Bristow and Latarjet procedures continued to be a good surgical option for treating post-traumatic anterior shoulder instability. The Bristow and Latarjet videoarthroscopic procedures seemed to have better results in relation to prevention of recurrence and rehabilitation, but randomized studies would be necessary in order to reach definitive conclusions.

The present study has some limitations, such as the short duration of the follow-up (ranging from 12 to 47 months) and the loss of 17 patients from the follow-up. We did not evaluate the UCLA scale or the Carter-Rowe score.

Conclusion

Use of metal anchors is no longer the best method to choose, given the potential risk of recurrence and arthrosis, and therefore other techniques need to be taken into consideration. Further studies are needed in order to compare the use of absorbable anchors, which despite having higher cost, may give rise to lower risk of development of glenohumeral arthrosis in some cases.

Conflicts of interest

The authors declare no conflicts of interest.

REFERENCES

- Godinho GG, França FO, Freitas JMA, Menezes CM, Freire SG, Wanderley AL, et al. Tratamento artroscópico da instabilidade anterior traumática do ombro: resultados a longo prazo e fatores de risco. *Rev Bras Ortop.* 2008;43(5):157-65.
- Checchia SL, Santos PD, Miyazaki AN, Silva LA, Fregonezi M. Afecções do ombro e cotovelo. In: Camargo OPA, Santin RAL, Ono NK, Kojima KE, editors. *Ortopedia e traumatologia: conceitos básicos, diagnóstico e tratamento.* São Paulo: Roca; 2004. p. 126-47.
- Robinson CM, Dobson RJ. Anterior instability of the shoulder after trauma. *J Bone Joint Surg Br.* 2004;86(4):469-79.
- Pötzl W, Witt KA, Hackenberg L, Marquardt B, Steinbeck J. Results of suture anchor repair of anteroinferior shoulder instability: a prospective clinical study of 85 shoulders. *J Shoulder Elbow Surg.* 2003;12(4):322-6.
- Itoi E, Hatakeyama Y, Sato T, Kido T, Minagawa H, Wakabayashi I, et al. Immobilization in external rotation after shoulder dislocation: an interim report of an ongoing trial [abstract]. In: 9th international congress on surgery of the shoulder. 2004.
- Koss S, Richmond JC, Woodward JS Jr. Two- to five-year follow-up of arthroscopic Bankart reconstruction using a suture anchor technique. *Am J Sports Med.* 1997;25(6):809-12.
- Sadovsk ĀP, Musil D, Stehl Āk J. Arthroscopic stabilization of the shoulder. *Acta Chir Orthop Traumatol Cech.* 2006;73(1):23-7.
- Tan CK, Guisasaola I, Machani B, Kemp G, Sinopidis C, Brownson P, et al. Arthroscopic stabilization of the shoulder: a prospective randomized study of absorbable versus nonabsorbable suture anchors. *Arthroscopy.* 2006;22(7):716-20.
- Barber FA, Herbert MA, Richards DP. Sutures and suture anchors: update 2003. *Arthroscopy.* 2003;19(9):985-90.
- Bacilla P, Field LD, Savoie FH 3rd. Arthroscopic Bankart repair in a high demand patient population. *Arthroscopy.* 1997;13(1):51-60.
- Kaar TK, Schenck RC Jr, Rockwood CA Jr. Complications of metallic suture anchors in shoulder surgery: a report of 8 cases. *Arthroscopy.* 2001;17(1):31-7.
- Silver MD, Daigneault JP. Symptomatic interarticular migration of glenoid suture anchors. *Arthroscopy.* 2000;16(1):102-5.
- Snyder SJ, Strafford BB. Arthroscopic management of instability of the shoulder. *Orthopedics.* 1993;16(9):993-1002.
- Almeida Filho IA, Veado MAC, Fim M, Correa LVS, Carvalho Junior ERA. Avaliação funcional do reparo artroscópico da instabilidade anterior recidivante do ombro. *Rev Bras Ortop.* 2012;47(2):214-21.
- Samilson RL, Prieto V. Dislocation arthropathy of the shoulder. *J Bone Joint Surg Am.* 1983;65(4):456-60.
- Fleega BA. The Giant Knot: a new one-way self-locking secured arthroscopic slip knot. *Arthroscopy.* 1999;15(4):451-2.
- Johnson LL. Arthroscopy of the shoulder. *Orthop Clin North Am.* 1980;11(2):197-204.
- Griesser MJ, Harris JD, McCoy BW, Hussain WM, Jones MH, Bishop JY, et al. Complications and re-operations after Bristow-Latarjet shoulder stabilization: a systematic review. *J Shoulder Elbow Surg.* 2013;22:286-92.
- Magnusson L, Ejerhed L, Rostgård-Christensen L, Sernert N, Eriksson R, Karlsson J, et al. A prospective, randomized, clinical and radiographic study after arthroscopic Bankart reconstruction using 2 different types of absorbable tacks. *Arthroscopy.* 2006;22(2):143-51.
- Hobby J, Griffin D, Dunbar M, Boileau P. Is arthroscopic surgery for stabilization of chronic shoulder instability as effective as open surgery? A systematic review and meta-analysis of 62 studies including 3044 arthroscopic operations. *J Bone Joint Surg.* 2007;89-B:1188-96.
- Buscayret F, Edwards TB, Szabo I, Adeleine P, Coudane H, Walch G. Glenohumeral arthrosis in anterior instability before and after surgical treatment: incidence and contributing factors. *Am J Sports Med.* 2004;32(5):1165-72.
- Ejnisman B, Andreoli CV, Pochini AC, Monteiro GC, Faloppa F, Cohen M. Artropatia glenoumeral pós-tratamento de lesões labiais com implantes metálicos. *Rev Bras Ortop.* 2006;41(5):167-72.
- Burkhart SS, De Beer JF. Traumatic glenohumeral bone defects and their relationship to failure of arthroscopic Bankart repairs: significance of the inverted-pear glenoid and the humeral engaging Hill-Sachs lesion. *Arthroscopy.* 2000;16(7):677-94.
- Balg F, Boilcau P. The instability severity index score – a simple pre-operative score to select patients for arthroscopic or open shoulder stabilization. *J Bone Joint Surg Br.* 2007;89:1470-7.

25. Papalia R, Franceschi F, Balzani LD, D'Adamio S, Denaro V, Maffulli N. The arthroscopic treatment of shoulder instability: bioabsorbable and standard metallic anchors produce equivalent clinical results. *Arthroscopy*. 2014;30(9):1173-83.
26. Longo UG, Loppini M, Rizzello G, Ciuffreda M, Maffulli N, Denaro V. Latarjet, Bristow, and Eden-Hybinette Procedures for anterior shoulder dislocation: systematic review and quantitative synthesis of the literature. *Arthroscopy*. 2014;30(9):1184-211.