

Closing-Wedge Distal Femoral Osteotomies— Retrospective Study*

Osteotomias femorais distais com cunha de fechamento medial—estudo retrospectivo

Pedro Barreira Cabral¹ Diego Costa Astur² Eduardo Vasconcelos Freitas¹ Bruno Silveira Pavei¹
Camila Cohen Kaleka¹ Moises Cohen²

¹Instituto Cohen São Paulo, São Paulo, SP, Brazil

²Orthopedics and Traumatology Department, Escola Paulista de Medicina, Universidade Federal de São Paulo, São Paulo, SP, Brazil

Address for correspondence Pedro Barreira Cabral, Instituto Cohen São Paulo, São Paulo, SP, Brazil (e-mail: pedro.barreira.c@gmail.com).

Rev Bras Ortop 2019;54:198–201.

Abstract

Objective To describe the surgical technique of distal closing-wedge femoral osteotomy and a cases series submitted to this technique.

Methods A total of 26 patients submitted to medial closing-wedge distal femoral osteotomy from 2002 to 2013 were evaluated. All of the patients had their medical files and imaging exams reviewed to evaluate the degree of correction and their current state.

Results Out of the 26 patients, 12 were male and 14 were female. Their mean age was 47.15 years old. In all of the cases, a neutral alignment related to the anatomical axis was achieved. Most of the patients presented bone healing at 6 weeks. There were no cases of bleeding during the surgery. One patient presented with delayed bone healing. One patient complained of plaque-related discomfort, requiring the removal of the device. One patient had a superficial infection, but no osteotomy revision was needed. There were no cases of deep venous thrombosis or of pulmonary thromboembolism. To date, there has been no conversion to total knee replacement.

Conclusion Treatment with medial closing-wedge distal femoral osteotomy sustained the proposed correction in patients with up to 15 years of follow-up.

Keywords

- ▶ osteotomy
- ▶ femur
- ▶ knee
- ▶ osteoarthritis
- ▶ genu valgum

Resumo

Objetivo Descrever a técnica cirúrgica da osteotomia femoral com cunha de fechamento medial e uma série de casos submetidos a essa técnica.

Métodos Foram avaliados 26 pacientes submetidos a osteotomia femoral distal com cunha de fechamento medial de 2002 a 2013. Os prontuários e exames de imagem de todos os pacientes foram revisados para avaliação do grau de correção e estado atual.

* Work developed at the Centro de Traumatologia do Esporte, Departamento de Ortopedia e Traumatologia, Escola Paulista de Medicina, Universidade Federal de São Paulo, São Paulo, SP, Brazil.

Palavras-chave

- ▶ osteotomia
- ▶ fêmur
- ▶ joelho
- ▶ osteoartrite
- ▶ geno valgo

Resultados Dos 26 pacientes operados, 12 eram do sexo masculino e 14 do feminino. A idade média foi de 47,15 anos. Em todos os casos, obteve-se alinhamento neutro em relação ao eixo anatômico. A maioria dos pacientes alcançou a consolidação óssea da osteotomia com seis semanas. Não foram observados casos de sangramentos durante a cirurgia. Um paciente apresentou retardo da consolidação óssea. Um paciente apresentou desconforto sobre a placa, foi necessária sua retirada. Um paciente apresentou infecção superficial sem necessidade de revisão da osteotomia. Não foram observados casos de trombose venosa profunda e tromboembolismo pulmonar. Até o momento não houve conversão para artroplastia total de joelho.

Conclusão O tratamento com osteotomia femoral distal com cunha de fechamento medial manteve a correção proposta em pacientes com seguimento de até 15 anos.

Introduction

Osteoarthritis (OA) is a degenerative joint disease observed in the general population. The knee is the main peripheral joint affected, resulting in progressive functional loss, joint pain, and stiffness. It is estimated that ~ 10% of the population > 50 years old will be affected by this condition.¹

The surgical osteotomy technique for long bones on the lower limbs (the femur and the tibia) aims to change the alignment of the affected limb, slowing down the evolutionary process of OA. As a result, it improves pain and limb function, and it can postpone knee replacement procedures, such as knee arthroplasty, for up to 10 years.²

Distal femoral osteotomy is a well-accepted procedure for the treatment of unicompartmental OA in the early stages of valgus knee. Chahla et al report that the best outcomes are obtained when osteotomies are performed in patients < 55 years old.^{1,3-5}

Femoral osteotomy may be performed as lateral opening-wedge or medial closing-wedge. On average, the deformity must be corrected to obtain a neutral anatomical alignment. However, there is no evidence in the literature about the superiority of the medial closing-wedge technique over the lateral opening-wedge.^{4,6}

The present study aims to describe the surgical technique and a case series submitted to femoral osteotomy with medial closing-wedge in a referral service, and to evaluate the current characteristics resulting from this procedure in up to 15 years of follow-up.

Materials and Methods

The present study was evaluated and approved by the Ethics and Research Committee of this institution under the number CAAE 01609812.9.0000.5505.

A total of 26 patients who underwent a distal femoral osteotomy with medial closing-wedge from 2002 to 2013 were evaluated. One of the patients was submitted to bilateral osteotomy, with a total of 27 operated knees.

Medical files and imaging results from all of the patients were reviewed to collect data regarding gender, age at surgery, laterality, deformity, and intraoperative complications. Next, the patients were clinically analyzed with their

imaging results to characterize their current status: treatment failure, required conversion to total knee arthroplasty, and other complications.

Initial Evaluation

The main indication for the correction of the affected lower limb was valgus deformity > 12°. For the preoperative planning, radiographs of the affected side were taken in antero-posterior and lateral views, in addition to a panoramic lower limbs radiograph for the calculation of the valgus angle and to determine if the deformity was in the distal femur. The criteria for correction were the following: absence of diffuse or nonspecific knee pain or main pain complaint at the patellofemoral joint, previous meniscectomy in the weight-bearing compartment, weight-support compartment arthrosis, underlying diagnosis of inflammatory disease, and arc of movement ≥ 90° with contracture under flexion < 10°.

Surgical Technique

With the patient positioned in the supine position on a radiolucent table, the articular surface was identified by palpation and radioscopy. An incision of ~ 10 cm was performed, extending proximally from the medial knee joint line. Next, the vastus medialis was bluntly dissected to expose the condyle and the medial femoral cortex. Thus, no neurovascular structure was exposed or put at risk during the surgical access, and the bone surface required for osteotomy was safely approached. The diaphyseal midline was marked with an electrocautery and a Codman pen to avoid angular deviation during the stabilization of the plaque. With a guide plate, parallel pins were positioned to aid the wedge cut. Then, the proximal part of the osteotomy was performed. The wedge guidewire was positioned with the angular cut predefined for each case, and ~ 75% of the wedge was sectioned and removed; this was considered a partial procedure. The osteotomy was checked with radioscopy and stabilized with an angled blade plaque at 90° in older cases or locked with proximal and distal screws in the most recent ones (▶ Fig. 1).

Results

Out of the 26 patients, 12 were male and 14 were female. Their mean age was 47.15 years old (ranging from 25 to

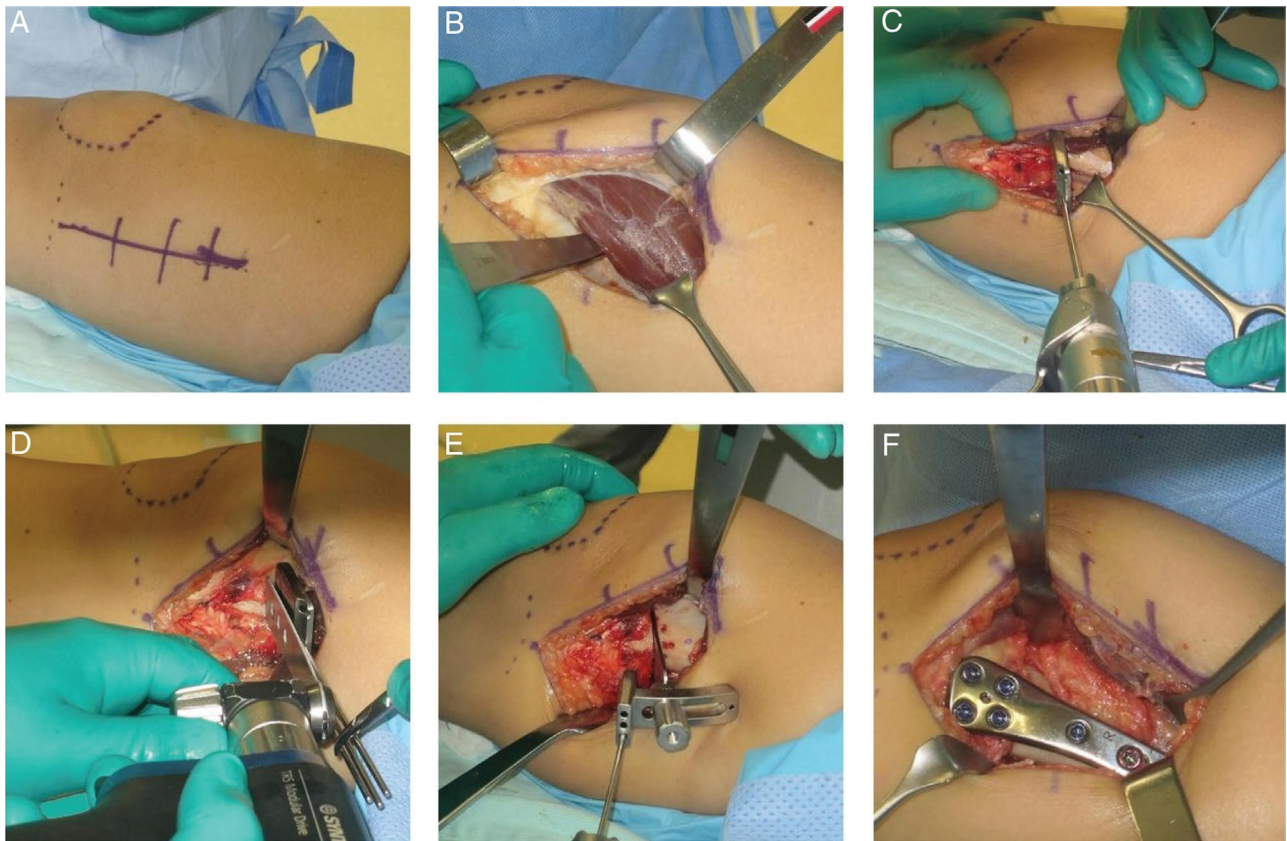


Fig. 1 A, joint line marking, patella and surgical access; B, subvastus retractor placement; C, parallel pins with guide plate placement; D, proximal part of the osteotomy; E, placement of pins on the wedge cutting guide to complete the osteotomy; F, plate placed after osteotomy.

61 years old). Regarding the side, 13 patients underwent left femur osteotomies, 12 underwent right femur osteotomies, and 1 patient underwent a bilateral osteotomy, totaling 27 distal femoral osteotomies.

The valgus deformity ranged from 13° to 18° before the surgery. After the osteotomy, all of the cases achieved a neutral anatomical alignment, with the valgus angle ranging from 0° to 1° .

There was no significant bleeding during the surgery. Neurovascular injuries due to surgical access were not reported.

In most patients, osteotomy bone healing occurred at 6 weeks (ranging from 6 to 16 weeks). Consolidation was defined according to the serial radiographic follow-up.

A female patient presented with delayed consolidation and with a fracture after falling from her own height. The lesion was submitted to medial and lateral stabilization for bone consolidation.

One patient presented with persistent discomfort on the plaque despite conservative treatment. After 1 year, we decided to remove the synthesis material. This surgical procedure lead to pain relief.

One patient had a superficial infection treated with cleansing and antibiotics, with no need for the removal of the plaque and of the screws.

There were no cases of deep venous thrombosis or of pulmonary thromboembolism. There was no conversion to total knee arthroplasty in a follow-up of at least 5 years.

Discussion

Femoral varization osteotomy is a surgical technique usually used to correct deformities in the knee valgus. This procedure can be performed in selected patients with lateral knee compartment overload to reduce the increased pressure between the lateral femoral condyle and the lateral tibial plateau. In 27 osteotomies, the mean age was 47.15 years old, ranging from 25 to 61 years old. The youngest osteotomy patient (25 years old) was a soccer player who had a previous lateral meniscectomy and evolved with rapid osteoarthritis progression, probably due to high sports demand.^{5,6} In the systematic review with 248 knees from Chahla et al,⁴ the mean age of the patients was 48.9 years old.

Although OA is more prevalent in females,⁶ the literature is inconclusive as to the gender in which the procedure is most frequently performed.^{6,7} In our study, 12 osteotomy patients were male, whereas 14 were female.

The main discussion about femoral distal varization osteotomy continues to be which technique should be applied: medial closing-wedge or lateral opening-wedge. The latter technique is more popular. This is probably because most surgeons consider it easier and safer due to their familiarity with the surgical access.^{4,8} Medial closing-wedge osteotomies seemed to have more complications, but a great deal of this information came from older studies, in which surgeons used clamping methods rather than

additional plates and screws.⁹ We believe that the medial closing-wedge technique allows a more anatomical correction with a shorter consolidation time. In addition, it eliminates the need for bone grafting and earlier loading on the operated limb. The neurovascular risk, commonly described as the main cause of the lack of popularity of this technique, is low when the surgical approach is properly made. In our series, there was no case of complication or of neurovascular involvement.^{4,8} Visser et al,⁸ in a cadaver study, corroborate this data and discuss about the safety of the medial approach for plaque placement. These authors also point out that vastus medialis damage and the risk of neurovascular lesions are marginal, even with the minimal-invasive technique.

In most patients, bone healing was achieved 6 weeks after the surgery. On average, studies cite that bone healing occurs in between 6 and 8 weeks. Only one patient presented with delayed consolidation. This patient was a long-time smoker and chose not to stop smoking during the postoperative period, which corroborates the increased risk of delayed bone healing.^{4,10,11}

In addition, plaque-related discomfort is a complication reported in the literature.⁴ One of our patients presented this complication. A probable reason for that was his low body weight and the fact that the muscular mass of the vastus medial would not properly cover the plaque, generating this discomfort.^{3,4} Forkel et al, in a follow-up of 23 patients submitted to femoral medial closing-wedge osteotomy, reported 16 individuals with plaque-related discomfort. We have decided to remove the synthesis material after the adequate time. The removal of the plaque resulted in the improvement of the symptoms.^{12,13}

Finally, surgical infection is an event that, despite preoperative, intraoperative, and postoperative measures, may occur in some cases. One patient from the present study had a superficial infection which was treated with antibiotic therapy and surgical cleaning. There was no need for synthesis material review.^{4,9-12}

Whenever required, pharmacological and nonpharmacological measures were used to avoid the most serious events reported in the literature, that is, deep vein thrombosis and pulmonary embolism. However, none of our patients had any of these complications.^{2,4}

Wylie et al,¹⁰ in another systematic review, showed that the 10-year survival rate after medial closing-wedge osteotomies was of 82%. Chahla et al⁴ showed that the mean survival rate ranged from 64 to 89.9% in the same 10-year follow-up period. In a follow-up of up to 15 years, this same study showed a much lower survival rate, from 45 to 78.9%. In our follow-up of up to 15 years, conversion to knee arthroplasty was not necessary until now.^{4,10}

Conclusion

Distal femoral medial closing-wedge osteotomy is a procedure that sustains the proposed correction in patients with up to 15 years of follow-up with very few complications resulting from the surgery.

Conflicts of Interest

The authors have no conflicts of interest to declare.

References

- Hussain SM, Neilly DW, Baliga S, Patil S, Meek R. Knee osteoarthritis: a review of management options. *Scott Med J* 2016;61(01):7-16
- Brouwer RW, Raaij van TM, Bierma-Zeinstra SM, Verhagen AP, Jakma TS, Verhaar JA. Osteotomy for treating knee osteoarthritis. *Cochrane Database Syst Rev* 2007;(03):CD004019
- Haviv B, Bronak S, Thein R, Thein R. The results of corrective osteotomy for valgus arthritic knees. *Knee Surg Sports Traumatol Arthrosc* 2013;21(01):49-56
- Chahla J, Mitchell JJ, Liechti DJ, Moatshe G, Menge TJ, Dean CS, et al. Opening- and closing-wedge distal femoral osteotomy: a systematic review of outcomes for isolated lateral compartment osteoarthritis. *Orthop J Sports Med* 2016;4(06):2325967116649901
- Hoorntje A, Witjes S, Kuijjer PPFM, Koenraadt KLM, van Geenen RCI, Daams JG, et al. High rates of return to sports activities and work after osteotomies around the knee: a systematic review and meta-analysis. *Sports Med* 2017;47(11):2219-2244
- Leone JM, Hansse AD. Osteotomia ao redor do joelho: perspectiva americana. In: Scott NW, ed. *Insall & Scott cirurgia do joelho*. 5a. ed. Rio de Janeiro: Elsevier; 2014:2070-2105
- Murphy GA. Total ankle arthroplasty. In: Azar FM, Beaty JH, Canale ST, eds. *Campbell's operative orthopaedics*. Philadelphia: Elsevier; 2017:508-534
- Visser J, Brinkman JM, Bleys RL, Castelein RM, van Heerwaarden RJ. The safety and feasibility of a less invasive distal femur closing wedge osteotomy technique: a cadaveric dissection study of the medial aspect of the distal femur. *Knee Surg Sports Traumatol Arthrosc* 2013;21(01):220-227
- Gardiner A, Richmond JC. Periarticular osteotomies for degenerative joint disease of the knee. *Sports Med Arthrosc Rev* 2013;21(01):38-46
- Wylie JD, Jones DL, Hartley MK, Kapron AL, Krych AJ, Aoki SK, et al. Distal femoral osteotomy for the valgus knee: medial closing wedge versus lateral opening wedge: a systematic review. *Arthroscopy* 2016;32(10):2141-2147
- Lobenhoffer P, Kley K, Freiling D, van Heerwaarden R. [Medial closed wedge osteotomy of the distal femur in biplanar technique and a specific plate fixator]. *Oper Orthop Traumatol* 2017;29(04):306-309
- Shantz JS, Marcucio R, Kim HT, Miclau T. Bone and cartilage healing. In: Court-Brown CM, Heckman JD, McQueen MM, Ricci WM, Tornetta P, eds. *Rockwood and Green's fractures in adults*. Philadelphia: Wolters Kluwer; 2015:109-125
- Forkel P, Achtnich A, Metzclaff S, Zantop T, Petersen W. Midterm results following medial closed wedge distal femoral osteotomy stabilized with a locking internal fixation device. *Knee Surg Sports Traumatol Arthrosc* 2015;23(07):2061-2067