



## Case Report

# Monosegmental combined anterior posterior instrumentation for the treatment of a severe lumbar tuberculous spondylodiscitis: case report and literature review<sup>☆</sup>



Petracchi Matias, Camino Willhuber Gaston\*, Tripodi Maria, Bassani Julio, Gruenberg Marcelo, Sola Carlos

Italian Hospital of Buenos Aires, Institute of Orthopedics "Carlos E. Ottolenghi", Buenos Aires, Argentina

### ARTICLE INFO

#### Article history:

Received 4 July 2016

Accepted 30 August 2016

Available online 29 December 2016

#### Keywords:

Discitis

Lumbar vertebrae

Tuberculosis, spinal

Thoracic vertebrae

Spinal fusion

Debridement

#### Palavras-chave:

Discite

Vértebras lombares

Tuberculose da coluna vertebral

Vértebras torácicas

### ABSTRACT

Spinal tuberculosis (Pott disease) can produce severe deformities when it is not properly treated. Long instrumentations through single or combined double approaches are usually required to prevent and correct the deformity. The authors present a case of severe deformity secondary to tuberculous spondylodiscitis in the lumbar spine treated with a monosegmental instrumentation through a double approach in a patient with idiopathic scoliosis. Deformity correction and infection resolution through debridement and arthrodesis is observed after one year of follow-up.

© 2016 Sociedade Brasileira de Ortopedia e Traumatologia. Published by Elsevier Editora Ltda. This is an open access article under the CC BY-NC-ND license (<http://creativecommons.org/licenses/by-nc-nd/4.0/>).

### Instrumentação monossegmentar anterior e posterior combinada para o tratamento de uma espondilodiscite tuberculosa severa: relato de caso e revisão da literatura

### RESUMO

A tuberculose espinhal (doença de Pott) pode produzir deformidades severas se não for tratada adequadamente. Instrumentações longas através de uma abordagem simples ou dupla geralmente são necessárias para corrigir a deformidade. Os autores apresentam um caso de deformidade severa em região lombar secundária a espondilodiscite tuberculosa tratada com instrumentação monossegmentar por dupla abordagem em um paciente com

<sup>☆</sup> Study conducted at the Italian Hospital of Buenos Aires, Institute of Orthopedics "Carlos E. Ottolenghi", Buenos Aires, Argentina.

\* Corresponding author.

E-mail: [gaston.camino@hospitalitaliano.org.ar](mailto:gaston.camino@hospitalitaliano.org.ar) (C.W. Gaston).

<http://dx.doi.org/10.1016/j.rboe.2016.12.010>

2255-4971/© 2016 Sociedade Brasileira de Ortopedia e Traumatologia. Published by Elsevier Editora Ltda. This is an open access article under the CC BY-NC-ND license (<http://creativecommons.org/licenses/by-nc-nd/4.0/>).

Fusão vertebral  
Debridamento

diagnóstico inicial de escoliose idiopática. A cirurgia corretiva e a resolução da infecção através de debridamento e artrodese é observada após um ano de acompanhamento.

© 2016 Sociedade Brasileira de Ortopedia e Traumatologia. Publicado por Elsevier Editora Ltda. Este é um artigo Open Access sob uma licença CC BY-NC-ND (<http://creativecommons.org/licenses/by-nc-nd/4.0/>).

## Introduction

Tuberculosis (TBC) disease is an unsolved problem in developing countries, more than 80% represent a pulmonary disease, tuberculous spondylitis (Pott disease) represent a site for extra-pulmonary tuberculosis, it occurs in less than 1% of patients with tuberculosis.<sup>1</sup>

Tuberculous spondylitis typical presentation can involve anterior elements, usually two adjacent vertebral bodies and the intervertebral disc, and forms a paravertebral abscess. It rarely involves the posterior elements (neural arch tuberculosis) in isolation or combination with lamina, spinous process, transverse process, articular process and pedicles, it can also make an epidural abscess and/or pyomyositis of the posterior spinal muscles.

The typical clinical presentation is back pain, but in those when it involves posterior elements also may lead to the sudden onset of a neurological deficit.<sup>2</sup>

The treatment of tuberculosis spondylitis is based on the structural damage secondary to bone and ligamentary destruction. In general; debridement and anterior or posterior fusion procedures are required. Approximately 5% of the Tuberculosis in the spine develops severe deformities<sup>3</sup> and surgical treatment represents a challenge in this scenario.

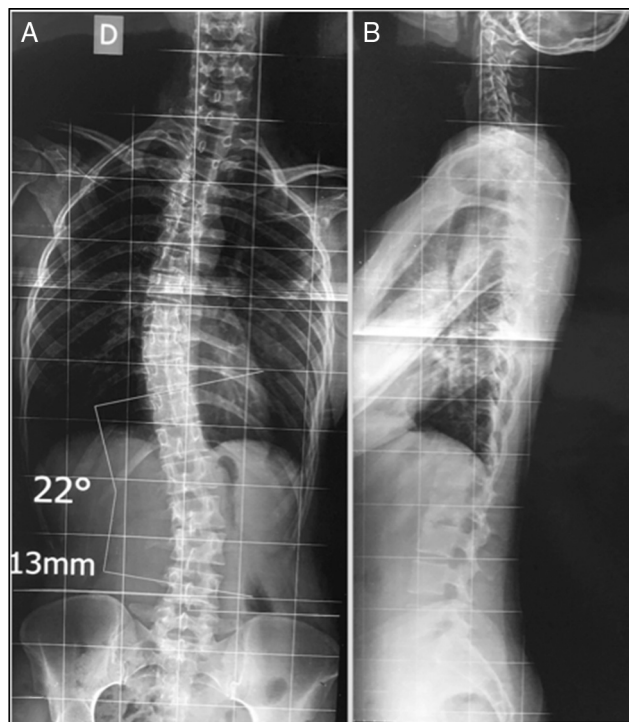
Short-instrumentation has been described previously for one level Tuberculosis spondylodiscitis and mild deformities,<sup>4</sup> however, to our knowledge, monosegmental instrumentation for the treatment of a severe deformity lumbar TBC has not been described previously.

We present the treatment of lumbar TBC treated by debridement and one-level anterior posterior arthrodesis of the lumbar spine in a patient with mild scoliosis.

## Case report

A 23-years old female was previously treated in other institution because of psoas tear during three months, because of progressive severe lumbar pain she consulted to our institution. There was no neurological compromise. Weight lost was not detected and any other symptom was associated to the lumbar pain. Previous spinal radiography analysis showed right thoracic idiopathic scoliosis with a 22 degrees lumbar compensatory curve (Fig. 1).

MRI was then performed showing L2 vertebral body, L2-L3 disc and right psoas compromise (Fig. 2). Spondylodiscitis was then suspected. CT-scan was performed in order to evaluate abdominal structures and to ruled-out another clinical problems related to this severe pain (Fig. 3). Severe L2-L3 compromise was observed on CT scan with increased curve deformity at this level.



**Fig. 1 – (A) Posterior view, thoracolumbar scoliosis with 22 grades at the lumbar region; (B) Lateral radiological view approximately one year before diagnosis.**

Percutaneous CT scan guided catheter intervention was performed with 60 cm<sup>3</sup> hematogenous material drainage (Fig. 3) but the cultures were negative.

Surgery was planned to stabilize and correct spinal deformity, drainage of necrotic and inflammatory component and prevent neurological compromise.

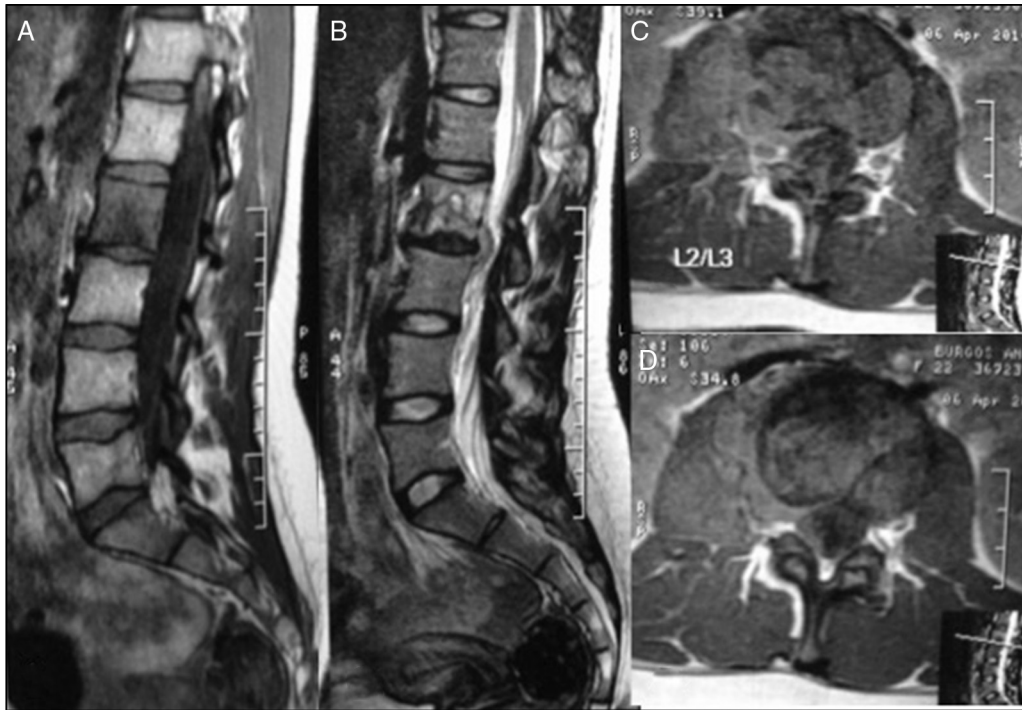
## Surgical treatment

Vertebral segmentary kyphosis and lateral angulation were 17 and 25 degrees respectively.

Monosegmentary instrumentation through a double antero-posterior approach was planned. First stage, a minimally invasive lateral right side approach for intersomatic and para-vertebral debridement was performed followed by a reconstruction with L2-L3 interbody titanium cage with rib bone autograft.

Posteriorly, with the same anesthesia, a posterior approach for L2-L3 pedicular instrumentation was performed and no normal spinal levels were instrumented (Fig. 4).

Estimated blood loss during the entire procedure was 850 ml. Both stages were performed under neurophysiologic



**Fig. 2 – (A) and (B) T1-T2 sagittal MRI showing L2-L3 compromise; (C) and (D) Axial MRI showing right psoas muscle compromise.**

monitoring including somatosensory evoked potentials (SSEPs) and motor evoked potentials (MEPs).

No complications were observed during the procedure.

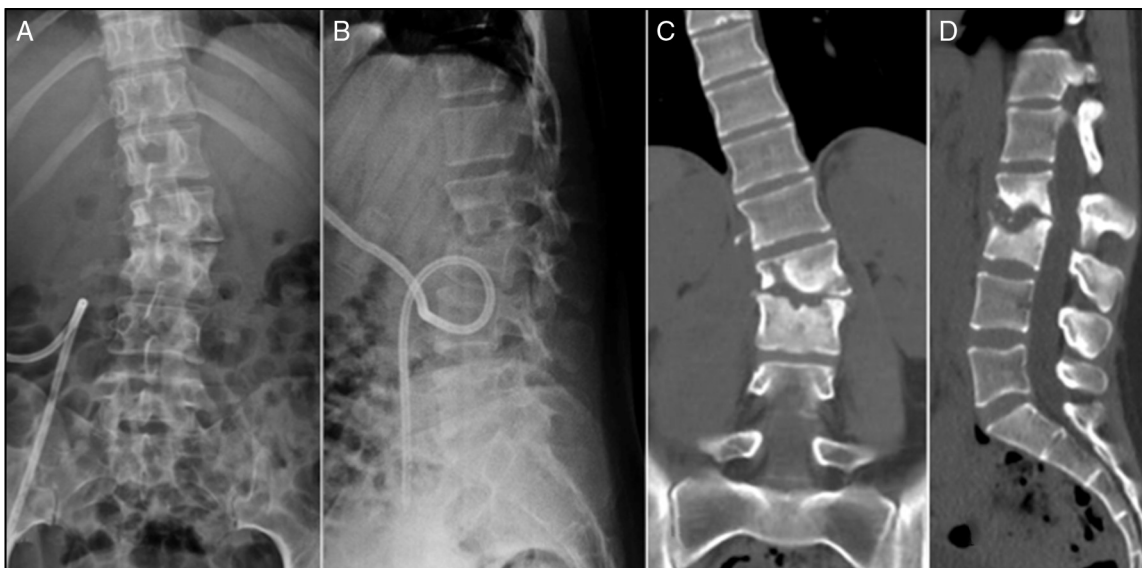
#### **Histological analysis**

Microscopic images (Fig. 5) showed granulomatous reaction with multinucleated cells. Ziehl Neelsen coloration technique was negative, however, polymerase chain reaction (PCR) was positive for tuberculosis.

#### **Postoperative treatment and follow up**

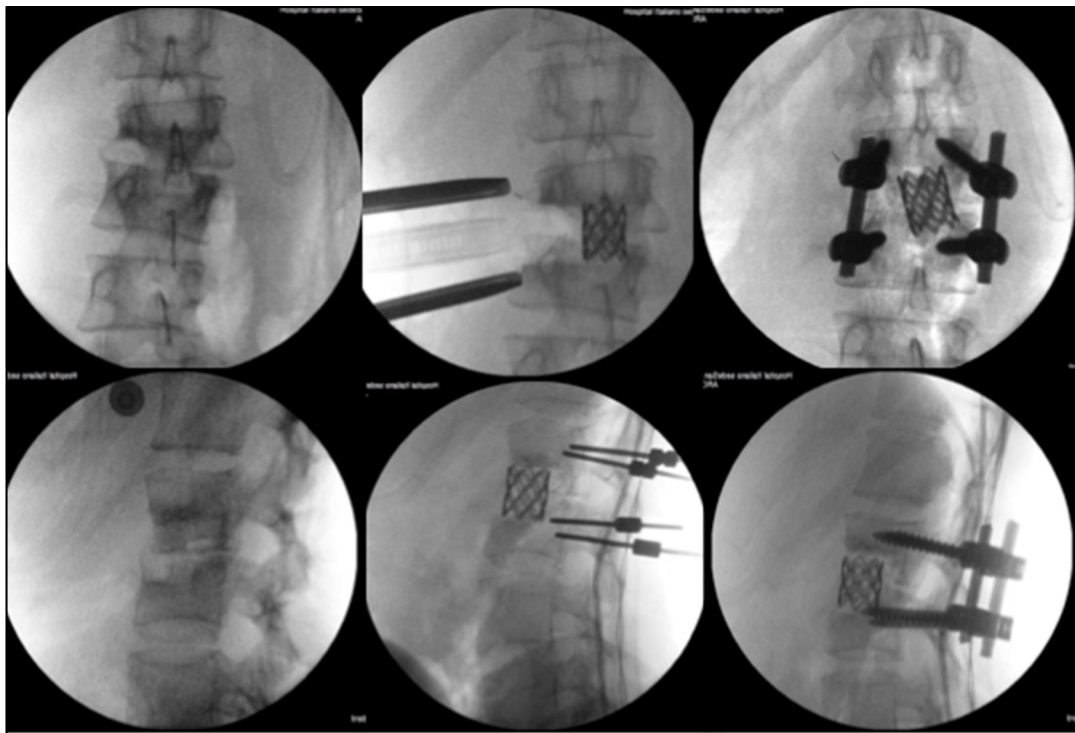
A Thoraco-lumbo-sacral orthosis (TLSO) was indicated and used during three months.

Clinical and radiological control was performed every three months, no deformities during follow up were observed, post-operative anterior and lateral segmental angles were 1 and 2 degrees respectively. Clinical parameters were improved and antituberculosis therapy was successful after 12 months of treatment (Fig. 6).



**Fig. 3 – (A) and (B) Anterior and lateral lumbar radiological images with a percutaneous catheter utilized to drain right psoas abscess; (C) and (D) CT-scan showing severe compromise of L2-L3 disk space and vertebral bony destruction.**





**Fig. 4 – Intraoperative radioscopic steps for the anterior and posterior arthrodesis, lateral mini invasive approach, vertebral and psoas debridement followed by interbody cage instrumentation and postoperative posterior instrumentation.**

Postoperative protocol included four anti tuberculosis agents for two months (Isoniazide, Ethambutol, Pirazinamide, Rifampin) followed by two drugs for ten months (Isonizide, Rifampin).

## Discussion

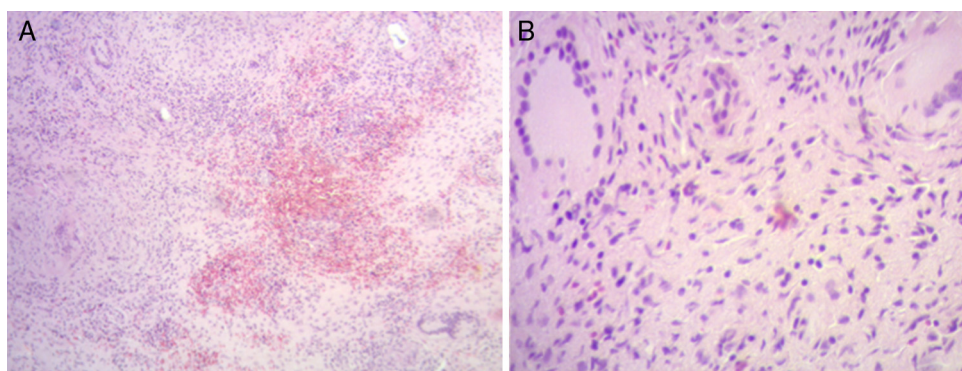
The treatment of spinal tuberculosis usually is non-surgical, by the administration of four anti-tuberculosis drugs and bracing.<sup>5</sup> There are some situations in which surgical treatment is required: loss of sagittal or coronal alignment of the spine due to extensive osteolysis and spread of an abscess into the para-spinal tissues and spinal canal, with progressive

neurologic deficit, failed conservative treatment or uncertain diagnosis.<sup>2</sup>

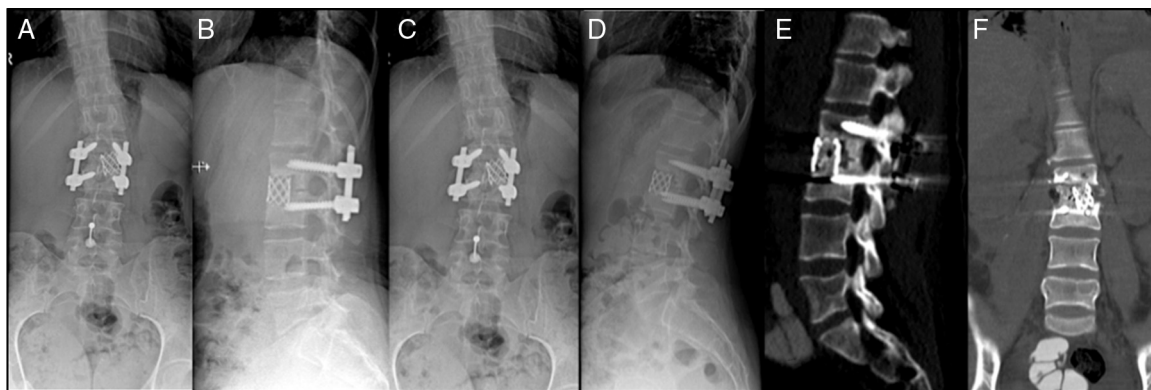
Posterior instrumentation with or without anterior fusion has demonstrated good clinical and surgical results.<sup>6,7</sup>

Anterior fusion alone, is generally indicated for patients with single level compromise and minor or mild deformities,<sup>8-10</sup> additional posterior instrumentation is considered in multilevel compromise or severe deformity, however, short or long instrumentations are performed in order to prevent early failure and obtain more correction.<sup>11</sup>

The anterior approach is possible only if the posterior column is intact, and it is demonstrated that can decrease the operating time, blood loss, and postoperative morbidity. However for a patient with pan vertebral disease, or with the need



**Fig. 5 – (A) Microscopical sample showing granulomatous tissue reaction; (B) Augmented microscopical multinucleated cell of granuloma.**



**Fig. 6 – (A) and (B) Immediate postoperative control; (C) and (D) One year postoperative control; (E) and (F) CT-scan showing L2-L3 interbody arthrodesis.**

for posterior column shortening to reduce kyphosis, or multi-level disease, posterior stabilization is necessary.<sup>12</sup>

We present a case of severe lumbar deformity secondary to spondylitis tuberculosis treated through a double anterior posterior approach with monosegmental instrumentation, arthrodesis was observed after a follow-up of one year. This technique should be attempted after a carefully patient selection. More cases are required to reinforce this recommendation.

To our knowledge combined monosegmental instrumentation for the treatment of a severe spinal deformity secondary to Tuberculosis spondylitis have not been described. More cases are needed to support this treatment.

### Conflicts of interest

The authors declare no conflicts of interest.

### REFERENCES

- Arora S, Sabat D, Maini L, Sural S, Kumar V, Gautam VK, et al. Isolated involvement of the posterior elements in spinal tuberculosis: a review of twenty-four cases. *J Bone Joint Surg Am.* 2012;94(20):e151.
- Kapoor SK, Garg V, Dhaon BK, Jindal M. Tuberculosis of the posterior vertebral elements: a rare cause of compression of the cauda equina. A case report. *J Bone Joint Surg Am.* 2005;87(2):391-4.
- Issack PS, Boachie-Adjei O. Surgical correction of kyphotic deformity in spinal tuberculosis. *Int Orthop.* 2012;36(2):353-7.
- Klößner C, Valencia R. Sagittal alignment after anterior debridement and fusion with or without additional posterior instrumentation in the treatment of pyogenic and tuberculous spondylodiscitis. *Spine (Phila Pa 1976).* 2003;28(10):1036-42.
- Moon MS, Kim I, Woo YK, Park YO. Conservative treatment of tuberculosis of the thoracic and lumbar spine in adults and children. *Int Orthop.* 1987;11(4):315-22.
- Mak KC, Cheung KM. Surgical treatment of acute TB spondylitis: indications and outcomes. *Eur Spine J.* 2013;22 Suppl. 4:603-11.
- Yang P, He X, Li H, Zang Q, Yang B. Clinical efficacy of posterior versus anterior instrumentation for the treatment of spinal tuberculosis in adults: a meta-analysis. *J Orthop Surg Res.* 2014;9(1):10.
- Dai LY, Jiang LS, Wang W, Cui YM. Single-stage anterior autogenous bone grafting and instrumentation in the surgical management of spinal tuberculosis. *Spine (Phila Pa 1976).* 2005;30(20):2342-9.
- Guerado E, Cerván AM. Surgical treatment of spondylodiscitis. An update. *Int Orthop.* 2012;36(2):413-20.
- Tosun B, Erdemir C, Yonga O, Selek O. Surgical treatment of thoracolumbar tuberculosis: a retrospective analysis of autogenous grafting versus expandable cages. *Eur Spine J.* 2014;23(11):2299-306.
- Hu J, Li D, Kang Y, Pang X, Wu T, Duan C, et al. Active thoracic and lumbar spinal tuberculosis in children with kyphotic deformity treated by one-stage posterior instrumentation combined anterior debridement: preliminary study. *Eur J Orthop Surg Traumatol.* 2014;24 Suppl. 1:S221-9.
- Yılmaz C, Selek HY, Gürkan I, Erdemli B, Korkusuz Z. Anterior instrumentation for the treatment of spinal tuberculosis. *J Bone Joint Surg Am.* 1999;81(9):1261-7.