



## Original article

# Subchondroplasty for treating bone marrow lesions in the knee – initial experience<sup>☆</sup>



Marcelo Batista Bonadio<sup>a,\*</sup>, Pedro Nogueira Giglio<sup>a</sup>, Camilo Partezani Helito<sup>a</sup>, José Ricardo Pécora<sup>b</sup>, Gilberto Luis Camanho<sup>b</sup>, Marco Kawamura Demange<sup>b</sup>

<sup>a</sup> Universidade de São Paulo, Instituto de Ortopedia e Traumatologia, Grupo de Joelho, São Paulo, SP, Brazil

<sup>b</sup> Universidade de São Paulo, Faculdade de Medicina, Departamento de Ortopedia e Traumatologia, São Paulo, SP, Brazil

## ARTICLE INFO

## Article history:

Received 22 June 2016

Accepted 18 July 2016

Available online 28 April 2017

## Keywords:

Bone cements

Bone substitutes/administration & dosage

Bone marrow/injuries

Edema

## ABSTRACT

**Objective:** To evaluate the use of subchondroplasty in the treatment of bone marrow lesions in an initial series of five cases.

**Methods:** The study included patients aged between 40 and 75 years old, with pain in the knee for at least six months, associated with high-signal MRI lesion on T2 sequences, on the tibia or femur. Patients were assessed using the visual analog pain scale and the KOOS score, one week before surgery and one, three, six, 12, and 24 weeks after the procedure. Subchondroplasty was performed with a technique developed for filling the area of the bone marrow lesion with a calcium phosphate bone substitute.

**Results:** The filling was performed on the medial femoral condyle in four patients and medial tibial plateau in one case. The assessment by the KOOS score presented a preoperative average of 38.44 points and 62.7, 58.08, 57.92, 63.34, and 71.26 points with one, three, six, 12, and 24 weeks after surgery, respectively. In the evaluation by the VAS, the average was 7.8 points preoperatively and 2.8, 3, 2.8, 1.8, and 0.6 points over the same periods. All patients were able to ambulate without additional support, on the first day after the procedure. One patient had a minimal graft dislocation to the soft tissue, with local pain, which resolved completely after a week.

**Conclusion:** The subchondroplasty technique provided significant improvements in the parameters of pain and functional capacity in the short-term assessment.

© 2016 Sociedade Brasileira de Ortopedia e Traumatologia. Published by Elsevier Editora Ltda. This is an open access article under the CC BY-NC-ND license (<http://creativecommons.org/licenses/by-nc-nd/4.0/>).

<sup>☆</sup> Study conducted at the Universidade de São Paulo, Faculdade de Medicina, Hospital das Clínicas, Instituto de Ortopedia e Traumatologia, Grupo de Joelho, São Paulo, Brazil.

\* Corresponding author.

E-mail: [bonadio@usp.br](mailto:bonadio@usp.br) (M.B. Bonadio).

<http://dx.doi.org/10.1016/j.rboe.2017.04.003>

2255-4971/© 2016 Sociedade Brasileira de Ortopedia e Traumatologia. Published by Elsevier Editora Ltda. This is an open access article under the CC BY-NC-ND license (<http://creativecommons.org/licenses/by-nc-nd/4.0/>).

## Subcondroplastia no tratamento de lesões medulares ósseas no joelho – Experiência inicial

### R E S U M O

#### Palavras-chave:

Cimentos para ossos  
Substitutos  
ósseos/administração &  
dosagem  
Medula óssea/lesões  
Edema

**Objetivo:** Avaliar o uso da técnica de subcondroplastia no tratamento das lesões medulares ósseas em série inicial de cinco casos.

**Métodos:** O estudo incluiu pacientes entre 40 e 75 anos, com dor em joelho com pelo menos seis meses de duração, associada à ressonância magnética com lesão hipercaptante em ponderação de T2 na tíbia ou no fêmur. Os pacientes foram avaliados segundo a escala visual analógica de dor (EVA) e pelo *Knee Injury and Osteoarthritis Outcome Score (KOOS)*, uma semana antes da cirurgia e uma, três, seis, 12 e 24 semanas após. A subcondroplastia foi feita com técnica desenvolvida para o preenchimento, guiado por radioscopia, da área de lesão óssea medular, com o uso de substituto ósseo em pasta à base de fosfato de cálcio.

**Resultados:** O preenchimento foi feito com sucesso em todos os casos, quatro no côndilo femoral medial e um no planalto tibial medial. A avaliação pelo KOOS apresentou uma média pré-operatória de 38,44 pontos e 62,7, 58,08, 57,92, 63,34 e 71,26 pontos com uma, três, seis, 12 e 24 semanas após a cirurgia, respectivamente. Na avaliação pela EVA, a média foi de 7,8 pontos no pré-operatório e 2,8, 3, 2,8, 1,8 e 0,6 pontos nos mesmos períodos. Todos os pacientes conseguiram deambular, sem apoio adicional, já no primeiro dia após o procedimento. Um paciente apresentou mínimo extravasamento de enxerto para partes moles, causou dor local que se resolveu completamente após uma semana.

**Conclusão:** A técnica de subcondroplastia desenvolvida proporcionou melhorias significativas nos parâmetros de dor e capacidade funcional na avaliação de curto prazo.

© 2016 Sociedade Brasileira de Ortopedia e Traumatologia. Publicado por Elsevier Editora Ltda. Este é um artigo Open Access sob uma licença CC BY-NC-ND (<http://creativecommons.org/licenses/by-nc-nd/4.0/>).

## Introduction

Osteoarthritis of the knee is currently accepted as a disease that affects the entire joint. It is interpreted as a multifactorial process involving cartilage, bone, meniscus, ligaments, synovial tissue, and musculature; it is difficult to define how much each of these factors contributes to each case. Changes in subchondral bone are currently recognized as an important factor in this arthritic process.<sup>1,2</sup>

Bone marrow lesions (BMLs) characterized by increased signal on T2-weighted sequences with fat suppression on magnetic resonance imaging (MRI), known as bone edema lesions, indicate a mechanically and histologically altered subchondral bone. Such lesions have been related to pain, joint surface deformation, and accelerated osteoarthritis progression.<sup>3-6</sup> Histological evaluations of these lesions demonstrate that these are not edema areas *per se*, but rather a set of nonspecific changes involving fibrosis, medullary fat necrosis, microfractures of the trabecular bone, and poor mineralization, confirming the hypothesis of areas of excessive bone remodeling without the ability to form bone with normal characteristics.<sup>7,8</sup>

Studies on natural history of arthritis demonstrate an accelerated progression to total knee arthroplasty (TKA) in patients with BML,<sup>9</sup> who are up to nine times more likely to undergo TKA in three years.<sup>10</sup> There is therefore an interest in therapies directed toward the subchondral bone that aim on preserving the joint.

The use of sodium alendronate and strontium ranelate has been investigated as an option, but the results regarding the control of disease progression are divergent.<sup>11-14</sup>

Subchondroplasty consists of the application of a synthetic bone substitute based on calcium phosphate in the BML for the treatment of lesions in which conservative treatment failed. The goal is to improve the structural quality of the affected subchondral bone and promote local bone remodeling, aiming to prevent bone collapse and the progression of arthritis.<sup>15,16</sup>

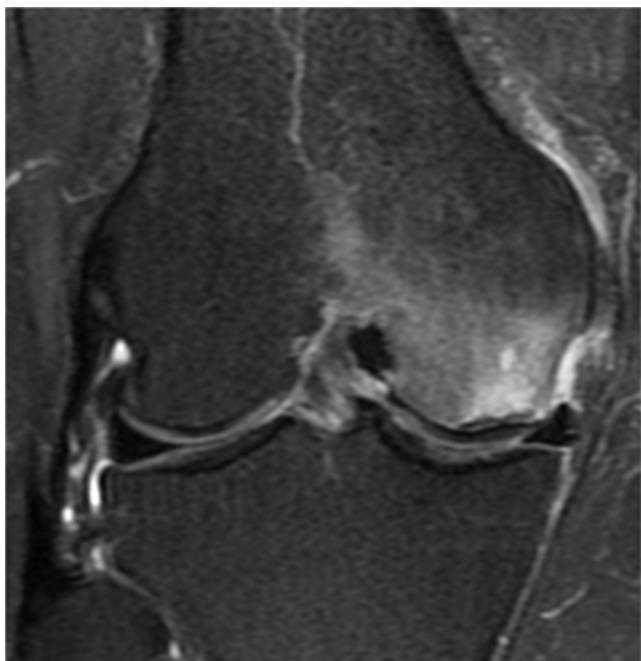Previous reports in the literature have demonstrated the feasibility and applicability of the technique to reduce pain and improve function, with a small risk of complications.<sup>17</sup> However, this is the first study to assess the reproducibility of the subchondroplasty technique with a different system and bone substitute, outside the United States.

Thus, the authors present the evaluation of the initial results of the treatment of BML with subchondroplasty, the applicability and viability of the surgical technique in Brazil, and the initial functional results.

## Material and methods

This study was approved by the Institutional Review Board under No. 859.206.

To be included in the study, patients had to be aged between 40 and 75 years, present knee pain for at least six months, and have a magnetic resonance imaging indicating a hypercaptating lesion in T2-weighted fat suppression images, located in the subchondral region of the tibial or femoral condyle (Fig. 1).



**Fig. 1 – Bone medullary lesion in medial femoral condyle, with hypersignal on T2-weighted magnetic resonance image.**

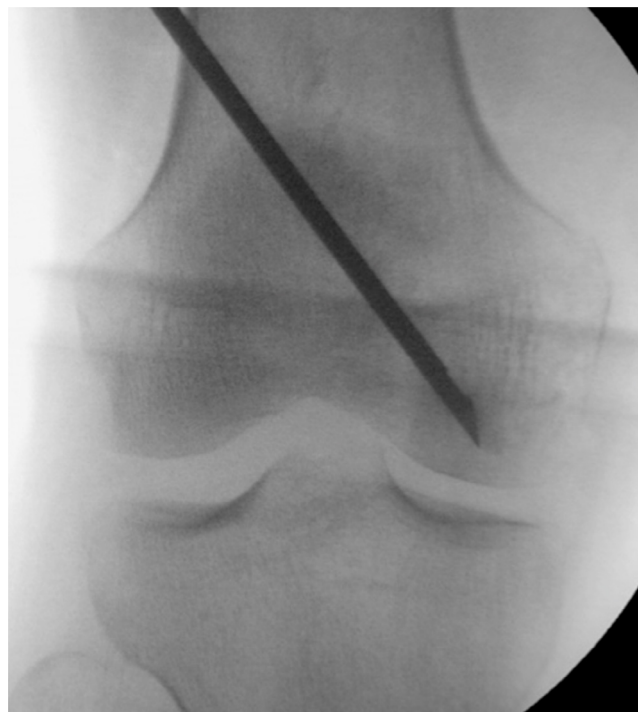The exclusion criteria were: autoimmune diseases, renal disease requiring dialysis, osteoarthritis radiographically classified in the Kellgren–Lawrence system<sup>18</sup> as greater than grade 3, diversion of the mechanical alignment of the lower limbs larger than 8 degrees, or radiographic alterations of the patellofemoral joint associated with symptoms of anterior pain in the knee.

MRI images were analyzed using the iSite PACS server (Philips, Amsterdam, Netherlands). Lesions were mapped and measured in the axial, coronal, and sagittal views to plan the injection site and the trajectory of the cannula used for the procedure. Radiographs using anteroposterior, profile, and Rosenberg views of the knee and lower limb were performed to classify the lesion according to the Kellgren–Lawrence classification and to assess lower limb alignment.

Patients were assessed one week prior to the procedure and one, three, six, 12, and 24 weeks after it, using the KOOS and the visual analog scale (VAS) for pain.

#### **Description of the surgical technique**

After mapping, patients underwent the subchondroplasty procedure, which was performed under spinal anesthesia, in an operating room, after conventional prepping techniques. Patients were placed on dorsal positioning on a radiolucent table, with a cushion under the ipsilateral hip for better control of the external rotation of the limb. Another cushion was also positioned under the knee to be operated, aiding in the lateral incidence of fluoroscopy and avoiding an overlap with the image of the contralateral knee. According to preoperative planning, the cannula entry point was demarcated with the aid of fluoroscopy in front and profile views. The cannula was



**Fig. 2 – Image of intraoperative radioscopy, with cannula positioning in a lesion mapped using magnetic resonance imaging.**

then introduced, with fluoroscopy control, toward the previously determined center of the lesion (Fig. 2). Progression was performed manually or with the use of a surgical mallet.

The paste bone substitute (graft) was then prepared until it reached liquid/pasty viscosity, and subsequently injected into the affected region. Through fluoroscopy, we were able to visualize the distribution of the product in the bone marrow, ensuring that the application followed the lesion mapping (Fig. 3). Graftys HBS<sup>®</sup> (Graftys, Aix en Provence, France) (ANVISA: 80517190001) was used.

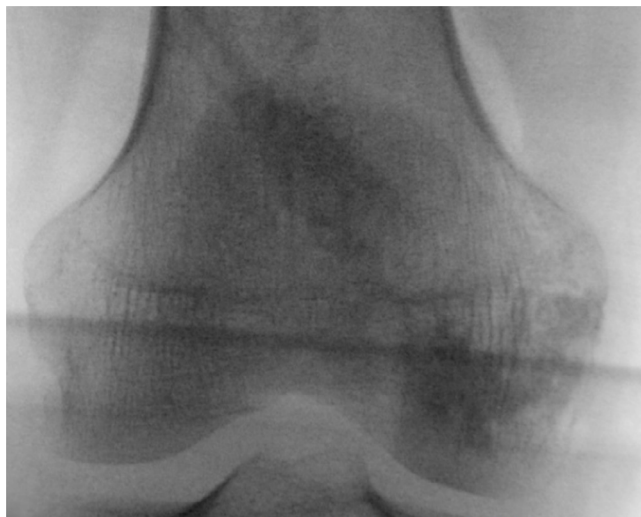The patients were hospitalized and discharged on the first postoperative day. After the procedure, patients were allowed to full weight bearing as tolerated, with free range of motion. During hospitalization, patients received analgesia with dipyrone 1 g intravenously every six hours combined with tramadol 100 mg intravenously every eight hours, on demand if they indicated pain higher than 6 on VAS. After hospital discharge, patients received analgesia with oral dipyrone 4 g daily (1 g every six hours) for seven days.

#### **Statistical analysis**

The quantitative values with normal distribution (parametric) were analyzed by Student's t-test; those with nonparametric distribution were analyzed using the Mann–Whitney test.

#### **Results**

Results presented are related to the initial sample of this prospective study, which is still in progress.



**Fig. 3 – Image of intraoperative radioscopy, with radiopacity after filling by subchondroplasty, in a region mapped using magnetic resonance imaging.**

Five patients were prospectively evaluated, four females and one male, with a mean of 67.7 ( $\pm 9.67$ ) years; they presented pain in one knee for at least six months, after a minimum of three months of conservative treatment without improvement. All patients had a MRI scan with a hypercapitating lesion in T2-weighted fat-suppression images in the subchondral region of the tibial plateau or femoral condyles.

Filling with bone substitute was performed in the medial femoral condyle in four patients and in the medial tibial plateau in one case.

Three patients were radiographically classified as Kellgren-Lawrence grade II and two grade patients as grade I. None of the patients presented lesion or previous surgery in the evaluated knee (Table 1).

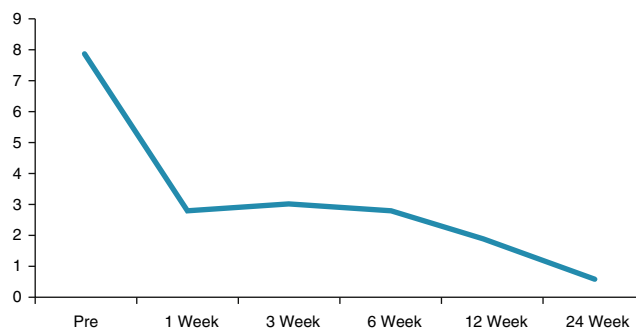
Evaluation using the KOOS showed a mean total score in the preoperative period of 38.44 points and of 62.7 ( $p < 0.05$ ), 58.08 ( $p < 0.05$ ), 57.92 ( $p < 0.05$ ), 63.34 ( $p < 0.07$ ), and 71.26 ( $p < 0.05$ ) points at one, three, six, 12, and 24 weeks after surgery, respectively. In the VAS assessment, mean was 7.8 points preoperatively and 2.8 ( $p < 0.05$ ), 3 ( $p < 0.05$ ), 2.8 ( $p < 0.05$ ), 1.8 ( $p < 0.05$ ), and 0.6 ( $p < 0.05$ ) points in the same periods (Fig. 4).

One of the patients had a minimal amount of graft extravasated into the soft tissue, upon the introduction of the cannula; local pain was observed for one week, and resolved

**Table 1 – Detail of the cases that underwent subchondroplasty: age, sex, laterality, lesion topography, and Kellgren-Lawrence classification of the radiograph.**

Patient	Age	Sex	Side	Topography of the lesion	Kellgren-Lawrence
1	61	F	R	Femoral medial	I
2	69	M	L	Tibial medial	II
3	58	F	L	Femoral medial	II
4	85	F	L	Femoral medial	I
5	70	F	R	Femoral medial	II

VAS for pain



**Fig. 4 – Mean visual analog scale (VAS) pain preoperatively (pre) and one, three, six, 12, and 24 weeks after subchondroplasty.**

completely after this period. The radiographic follow-up also demonstrated a progressive resorption of the product, which after six months of surgery was still partially identifiable on radiography. No patient required additional procedures during follow-up.

All patients were able to walk, without additional support, on the first day after the procedure.

### Discussion

The main finding of the present study was that patients who underwent subchondroplasty showed a significant improvement in functional capacity from the first week post procedure, which persisted in the subsequent six months. There was also a significant and quick pain improvement, which also continued during the six months of follow-up.

Osteoarthritis is a disease characterized by wear of hyaline cartilage; however, as this tissue does not have nerve pain fibers, the cause of the pain is still not completely clear.<sup>19</sup> Nonetheless, pain receptors are found in several other structures affected by the pathological process of osteoarthritis, such as joint capsule, ligaments surrounding the knee, and the peripheral portion of the meniscus. The periosteum and bone marrow are also richly innervated by nociceptive receptors.<sup>4</sup>

Studies have shown that the presence of BML in some patients with osteoarthritis is associated with pain, disease progression, joint deformation, and rapid progression to treatment with arthroplasty.<sup>3,5,10</sup>

Calcium phosphate-based bone substitute has been used primarily as a graft option in bone defects.<sup>20-22</sup> For this function, biphasic calcium phosphate ceramics show good osteoinductive and osteoconductive results.<sup>23,24</sup> Such properties may contribute to the balance of the bone mineralization that was lost in the areas of BML, and may modify the course of the disease. Unlike hydroxyapatite, which presents a very long reabsorption time, the degradation of biphasic calcium phosphate ceramics is more similar to that of autologous bone.<sup>25</sup>

Although not the central point of the present study, the analysis of other factors that may be associated with the presence of BML is paramount. For example, a careful assessment of limb alignment may indicate the need to associate

an osteotomy in order to reduce the overload of the affected compartment.

The present study demonstrated a simple and reproducible surgical technique, which succeeded in its objective of injecting calcium-phosphate-based bone substitute into BML areas. The only complication observed during the study, extravasation of the bone substitute, did not lead to significant consequences for the patient. A significant reduction of pain, assessed by VAS, and KOOS improvement after subchondroplasty were also evidenced.

The small number of patients and the absence of control group are important limitations of the present study, which reports an initial experience over a still short-term follow-up period. A larger study, with a long-term follow-up, is underway. Nevertheless, the present study is pioneering in the development and presentation of the surgical technique of subchondroplasty in the Brazilian literature.

## Conclusion

The developed subchondroplasty technique is safe, providing significant improvements in pain parameters and functional capacity in the short-term evaluation. Subchondroplasty may be a new treatment modality for early stage osteoarthritis when an associated bone marrow lesion is present.

## Conflicts of interest

The authors declare no conflicts of interest.

## REFERENCES

- Madry H, van Dijk CN, Mueller-Gerbl M. The basic science of the subchondral bone. *Knee Surg Sports Traumatol Arthrosc.* 2010;18(4):419-33.
- Orth P, Cucchiariini M, Wagenpfeil S, Menger MD, Madry H. PTH [1-34]-induced alterations of the subchondral bone provoke early osteoarthritis. *Osteoarthritis Cartilage.* 2014;22(6):813-21.
- Felson DT, Chaisson CE, Hill CL, Totterman SM, Gale ME, Skinner KM, et al. The association of bone marrow lesions with pain in knee osteoarthritis. *Ann Int Med.* 2001;134(7):541-9.
- Sowers MF, Hayes C, Jamadar D, Capul D, Lachance L, Jannausch M, et al. Magnetic resonance-detected subchondral bone marrow and cartilage defect characteristics associated with pain and X-ray-defined knee osteoarthritis. *Osteoarthritis Cartilage.* 2003;11(6):387-93.
- Roemer FW, Guermazi A, Javaid MK, Lynch JA, Niu J, Zhang Y, et al. Change in MRI-detected subchondral bone marrow lesions is associated with cartilage loss: the MOST Study. A longitudinal multicentre study of knee osteoarthritis. *Ann Rheum Dis.* 2009;68(9):1461-5.
- Kraus VB, Feng S, Wang S, White S, Ainslie M, Graverand MP, et al. Subchondral bone trabecular integrity predicts and changes concurrently with radiographic and magnetic resonance imaging-determined knee osteoarthritis progression. *Arthritis Rheum.* 2013;65(7):1812-21.
- Kazakia GJ, Kuo D, Schooler J, Siddiqui S, Shanbhag S, Bernstein G, et al. Bone and cartilage demonstrate changes localized to bone marrow edema-like lesions within osteoarthritic knees. *Osteoarthritis Cartilage.* 2013;21(1):94-101.
- Taljanovic MS, Graham AR, Benjamin JB, Gmitro AF, Krupinski EA, Schwartz SA, et al. Bone marrow edema pattern in advanced hip osteoarthritis: quantitative assessment with magnetic resonance imaging and correlation with clinical examination, radiographic findings, and histopathology. *Skeletal Radiol.* 2008;37(5):423-31.
- Tanamas SK, Wluka AE, Pelletier JP, Pelletier JM, Abram F, Berry PA, et al. Bone marrow lesions in people with knee osteoarthritis predict progression of disease and joint replacement: a longitudinal study. *Rheumatology.* 2010;49(12):2413-9.
- Scher C, Craig J, Nelson F. Bone marrow edema in the knee in osteoarthrosis and association with total knee arthroplasty within a three-year follow-up. *Skeletal Radiol.* 2008;37(7):609-17.
- Shirai T, Kobayashi M, Nishitani K, Satake T, Kuroki H, Nakagawa Y, et al. Chondroprotective effect of alendronate in a rabbit model of osteoarthritis. *J Orthop Res.* 2011;29(10):1572-7.
- Reginster JY, Badurski J, Bellamy N, Bensen W, Chapurlat R, Chevalier X, et al. Efficacy and safety of strontium ranelate in the treatment of knee osteoarthritis: results of a double-blind, randomised placebo-controlled trial. *An Rheum Dis.* 2013;72(2):179-86.
- Pelletier JP, Roubille C, Raynauld JP, Abram F, Dorais M, Delorme P, et al. Disease-modifying effect of strontium ranelate in a subset of patients from the Phase III knee osteoarthritis study SEKIOA using quantitative MRI: reduction in bone marrow lesions protects against cartilage loss. *Ann Rheum Dis.* 2015;74(2):422-9.
- Hayami T, Pickarski M, Wesolowski GA, McLane J, Bone A, Destefano J, et al. The role of subchondral bone remodeling in osteoarthritis: reduction of cartilage degeneration and prevention of osteophyte formation by alendronate in the rat anterior cruciate ligament transection model. *Arthritis Rheum.* 2004;50(4):1193-206.
- Sharkey PF, Cohen SB, Leinberry CF, Parvizi J. Subchondral bone marrow lesions associated with knee osteoarthritis. *Am J Orthop.* 2012;41(9):413-7.
- Farr J, Cohen SB. Expanding applications of the subchondroplasty procedure for the treatment of bone marrow lesions observed on magnetic resonance imaging. *Oper Techn Sport Med.* 2013;21(2):138-43.
- Cohen SB, Sharkey PF. Subchondroplasty for treating bone marrow lesions. *J Knee Surg.* 2016;29(7):555-63.
- Kellgren JH, Lawrence JS. Radiological assessment of osteoarthrosis. *Ann Rheum Dis.* 1957;16(4):494-502.
- Ulrich-Vinther M, Maloney MD, Schwarz EM, Rosier R, O'Keefe RJ. Articular cartilage biology. *J Am Acad Orthop Surg.* 2003;11(6):421-30.
- Evaniew N, Tan V, Parasu N, Jurriaans E, Finlay K, Dehesi B, et al. Use of a calcium sulfate-calcium phosphate synthetic bone graft composite in the surgical management of primary bone tumors. *Orthopedics.* 2013;36(2):e216-22.
- Kim JK, Kim NK. Curettage and calcium phosphate bone cement injection for the treatment of enchondroma of the finger. *Hand Surg.* 2012;17(1):65-70.
- Winge MI, Reikeras O, Rokkum M. Calcium phosphate bone cement: a possible alternative to autologous bone graft. A radiological and biomechanical comparison in rat tibial bone. *Arch Orthop Trauma Surg.* 2011;131(8):1035-41.
- Surmenev RA, Surmeneva MA, Ivanova AA. Significance of calcium phosphate coatings for the enhancement of new bone osteogenesis - a review. *Acta Biomater.* 2014;10(2):557-79.

24. Ko CL, Chen WC, Chen JC, Wang YH, Shih CJ, Tyan YC, et al. Properties of osteoconductive biomaterials: calcium phosphate cement with different ratios of platelet-rich plasma as identifiers. *Mater Sci Eng C Mater Biol Appl.* 2013;33(6):3537-44.
25. Jensen SS, Bornstein MM, Dard M, Bosshardt DD, Buser D. Comparative study of biphasic calcium phosphates with different HA/TCP ratios in mandibular bone defects. A long-term histomorphometric study in minipigs. *J Biomed Mater Res B Appl Biomater.* 2009;90(1):171-81.