



## Original Article

# Parsonage–Turner syndrome<sup>☆</sup>



Ricardo Barreto Monteiro dos Santos\*, Saulo Monteiro dos Santos,  
Flávio José Câmara Carneiro Leal, Otávio Gomes Lins, Carmem Magalhães,  
Ricardo Bruno Mertens Fittipaldi

Traumatology Service, Hospital das Clínicas, Universidade Federal de Pernambuco, Recife, PE, Brazil

### ARTICLE INFO

#### Article history:

Received 3 September 2013

Accepted 5 June 2014

Available online 17 April 2015

#### Keywords:

Neuritis of the brachial plexus

Shoulder

Electromyography

### ABSTRACT

**Objective:** To describe the clinical, electrophysiological and imaging findings from Parsonage–Turner syndrome and evaluate the results from conservative treatment.

**Methods:** Eight cases were studied between February 2010 and February 2012, with a minimum follow-up of one year (mean of 14 months). All the patients answered a clinical questionnaire and underwent functional evaluation using the Constant and Murley score. After clinical suspicion was raised, an electromyography examination was performed to confirm the diagnosis.

**Results:** Eight patients (mean age of 29 years) were evaluated. The right side was affected in 70% of the cases, and the dominant side in 80% of the cases. All the patients reported that their shoulder pain had started suddenly, lasting from one to five days in six cases and up to 15 days in two cases. In three cases, severe atrophy of the deltoid muscle was observed. Hypotrophy of the supraspinatus and infraspinatus muscles was observed in three cases. A winged scapula was observed in the two remaining cases. Electromyography demonstrated involvement of the long thoracic nerve in these last two cases and confirmed the involvement of the axillary and suprascapular nerves in the remaining six cases. The mean score on the Constant and Murley scale was 96 at the end of the conservative treatment with non-steroidal anti-inflammatory drugs and physiotherapy. Six of the eight patients presented good recovery of muscle strength.

**Conclusions:** In the majority of the cases, the functional recovery was good, although muscle strength was not completely restored in some of them.

© 2014 Sociedade Brasileira de Ortopedia e Traumatologia. Published by Elsevier Editora Ltda. All rights reserved.

### Síndrome de Parsonage–Turner

#### R E S U M O

**Objetivo:** Descrever os achados clínicos, eletrofisiológicos e de imagem na síndrome de Parsonage–Turner e avaliar os resultados do tratamento conservador.

#### Palavras-chave:

Neurite do plexo braquial

<sup>☆</sup> Work developed at the Traumatology Service, Hospital das Clínicas, Federal University of Pernambuco, Recife, PE, Brazil.

\* Corresponding author.

E-mail: ricardobms@hotmail.com (R.B. Monteiro dos Santos).

<http://dx.doi.org/10.1016/j.rboe.2015.04.002>

2255-4971/© 2014 Sociedade Brasileira de Ortopedia e Traumatologia. Published by Elsevier Editora Ltda. All rights reserved.

Ombro  
Eletromiografia

**Métodos:** Foram estudados oito casos entre fevereiro de 2010 e fevereiro de 2012, com seguimento mínimo de um ano (média de 14 meses). Todos os pacientes foram submetidos ao questionário clínico e avaliados funcionalmente com o escore de Constant e Murley. Após a suspeita clínica o exame de eletroneuromiografia foi feito para confirmação diagnóstica. **Resultados:** Oito pacientes (média de 29 anos) foram avaliados. O lado direito foi acometido em 70% dos casos e era o dominante em 80%. Todos os pacientes relataram um início súbito de dor no ombro, com duração de um a cinco dias em seis casos e de até 15 dias em dois casos. Em três casos foi observada atrofia severa do músculo deltoide. Hipotrofia dos músculos supraespinhal e infraespinhal foi observada em três casos. Escápula alada foi observada em dois casos restantes. A eletromiografia demonstrou envolvimento do nervo torácico longo nesses dois últimos casos e confirmou o envolvimento dos nervos axilar e supraescapular nos seis casos restantes. A pontuação média na escala de Constant e Murley foi de 96 no fim do tratamento conservador com medicamentos anti-inflamatórios não esteroides e fisioterapia. Seis dos oito pacientes apresentaram boa recuperação da força muscular. **Conclusão:** Na maioria dos casos a recuperação funcional foi boa, embora a força muscular não tenha sido completamente restaurada em alguns deles.

© 2014 Sociedade Brasileira de Ortopedia e Traumatologia. Publicado por Elsevier Editora Ltda. Todos os direitos reservados.

## Introduction

Parsonage–Turner syndrome (PTS) is also named acute idiopathic brachial neuritis, paralytic neuritis of the brachial plexus, cryptogenic brachial neuropathy and scapular belt syndrome. The first records of this syndrome date from 1887, described by Dreschfeld, and this was followed by many other reports: Feinberg<sup>1</sup> (1897), Bramwell and Struthers<sup>2</sup> (1903), Wyburn-Mason<sup>3</sup> (1941), Burnard<sup>4</sup> (1942) and Spillane<sup>5</sup> (1943). However, the clinical characteristics of this syndrome were only fully described in 1948, from a series of 136 cases reported by Parsonage and Turner. These authors named it “scapular belt syndrome”.<sup>6</sup>

This is a painful non-traumatic disorder that affects the scapular belt. Clinically, the patient presents a painful condition with localized upsurges in the shoulder that may last for some hours or up to two to three weeks, with spontaneous improvement. After the painful condition, muscle weakness appears, along with paralysis and atrophy of the innervated musculature in the segment affected.<sup>7</sup> Topographically, this neurological lesion impairs the peripheral nerves or part of the brachial plexus. In addition to the motor repercussions, there may be sensory losses.

Diagnosing the disease may give rise to certain anxieties both for the attending physician and for the patient, since some conditions with similar characteristics may be confounded with PTS and may need to be ruled out in making the differential diagnosis. These conditions include rotator cuff tears, calcareous tendinitis, adhesive capsulitis, cervical spondylopathy and neurological abnormalities such as compression of the peripheral nerve, acute poliomyelitis and lateral amyotrophic sclerosis. However, the diagnosis becomes probable when spontaneous improvement of the pain and progression of muscle weakness are observed.

The precise cause is unknown, but it has been attributed in the literature to viral infections and autoimmune processes,<sup>8,9</sup> such as after immunization. There are also reports of

hereditary forms with specific mutations<sup>10</sup> or even occurrences after strenuous physical exercise.<sup>11,12</sup> Some viral agents have been correlated with PTS, such as: smallpox, fever, typhoid, influenza, coxsackievirus, parvovirus B19, cytomegalovirus and human immunodeficiency virus, and also *Borrelia burgdorferi*.<sup>8,13-16</sup> There is strong evidence of an association with viral infections, since there are reports in the literature of epidemic outbreaks in isolated populations, such as one that occurred in an indigenous population in the southwestern United States, with eight cases of PTS.<sup>7</sup>

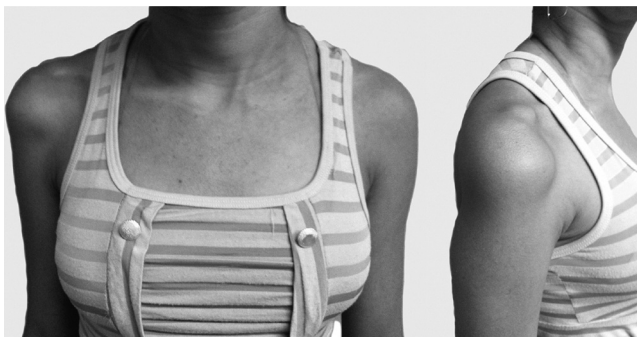
The incidence was found to be 1.64 cases per 100,000 inhabitants, in the population of Minnesota, United States, with occurrences predominantly between the third and seventh decades of life.<sup>17,18</sup> Men are more affected than women, with a ratio of between 2:1 and 11.5:1.<sup>11</sup> The prognosis is good in most cases, given that PTS is self-limiting and has a low recurrence rate.<sup>11</sup> The treatment is generally successful, with use of analgesics and physiotherapy in order to maintain the range of motion and strengthen muscles.

The objective of this study was to describe the clinical characteristics of PTS and evaluate the results from conservative treatment.

## Materials and methods

Eight cases of PTS that were diagnosed between February 2010 and February 2012 were studied prospectively. The patients were followed up for a minimum of one year (mean of 14 months). All the patients were asked to answer a clinical questionnaire on their symptoms and underwent a physical examination to assess function. At the end of the treatment, all the patients were graded using the Constant and Murley score.<sup>19</sup>

After the clinical suspicion of PTS was raised, all of these patients underwent electroneuromyography examination in order to register the peripheral nerve that was affected and confirm the diagnosis. However, in some cases, with the aims



**Fig. 1 – Fifteen years and three months after the start of the symptoms. Note the atrophy of the deltoid muscle in the right shoulder.**

of ruling out associated conditions and making a differential diagnosis, radiography and magnetic resonance examinations were used. The inclusion criteria were that the patients needed to have a history of acute shoulder pain with paresis or hypotrophy in the scapular belt. Patients with histories of trauma, previous shoulder surgery, rotator cuff tears or adhesive capsulitis were excluded. This study was approved by the ethics committee.

## Results

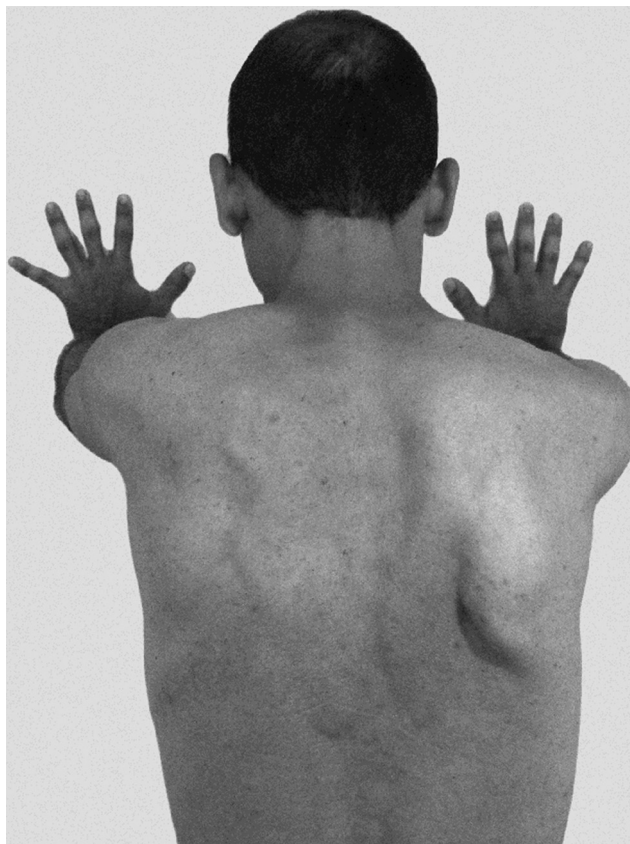
Eight patients were evaluated: three females and five males. Their mean age was 29 years (range from 15 to 41). The right side was affected in 70% of the cases and the dominant side in 80% (Table 1).

All the patients studied reported during the history-taking that they had experience a sudden condition of shoulder pain that lasted for an average of one to five days. In two cases, the pain lasted for 15 days. In three cases, there was spontaneous remission of the painful condition without any use of non-steroidal anti-inflammatory drugs (NSAIDs). In seven cases, remission occurred through use of NSAIDs and analgesics that were prescribed by doctors at the emergency service.

In the physical examination, which was performed on eight patients, three cases presented intense atrophy in the area of the deltoid muscle and one case showed hypoesthesia in the sensory area of the axillary nerve (Fig. 1). Three cases showed muscle hypotrophy in the supraspinous and infraspinous fossae, with positive Jobe tests, which were used to evaluate the functioning of the supraspinatus. The remaining two cases showed winged scapulae, which were more evident when the patients used force to push against a wall (Fig. 2).

Electroneuromyography examinations were performed on all the patients in order to confirm the diagnosis. All of these examinations demonstrated peripheral denervation (potential for prolonged action and latency). In one case (patient 4), a magnetic resonance examination was performed on the shoulder, which showed hypersignal with T2 weighting and atrophy of the deltoid musculature (Fig. 3).

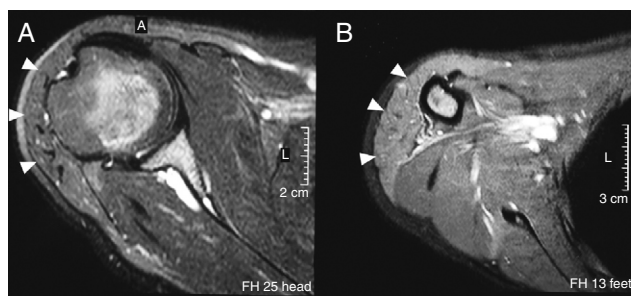
A physiotherapeutic rehabilitation program was started just after the diagnosis had been made. The protocol consisted



**Fig. 2 – Patient with right-side winged scapula, resulting from impairment of the long thoracic nerve.**

of analgesic electrotherapy with TENS in association with deep thermal therapy or cryotherapy during the painful phase, kinesiotherapy to maintain and gain range of motion and, when grades close to normality were reached, isometric or resistance exercises were started for the entire scapular belt. Functional electrical stimulation (FES) was also used with the aim of increasing muscle tonus.

All the patients presented improvements in pain, strength and muscle trophism (Fig. 4) over the course of the follow-up. The Constant and Murley scores obtained were between 94 and 100 points, with a mean of 96.37 points at the end of the follow-up (Table 2). Six of the eight patients treated presented



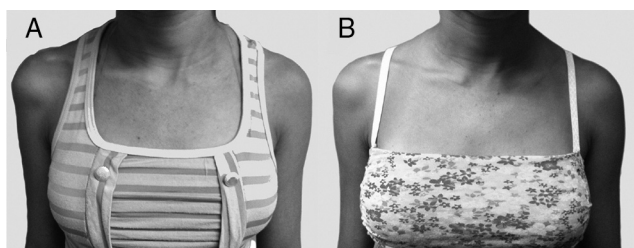
**Fig. 3 – Magnetic resonance imaging of the shoulder: axial slices with T2 weighting, (A) proximal and (B) distal. Hypersignal and atrophy of the deltoid musculature (arrow) can be seen, suggestive of denervation of the axillary nerve.**

**Table 1 – Age, sex and limb affected among the patients with PTS.**

Patient	Age	Sex	Side affected	Dominant side	Duration of pain outbreak	Peripheral nerve affected <sup>a</sup>
1	37	Male	Right	Right	24 h	Suprascapular
2	26	Male	Right	Right	48 h	Long thoracic
3	41	Male	Right	Right	3 days	Axillary
4	15	Female	Right	Right	15 days	Axillary
5	23	Male	Right	Right	5 days	Long thoracic
6	32	Male	Left	Right	24 h	Suprascapular
7	30	Female	Left	Right	48 h	Long thoracic
8	34	Female	Right	Right	15 days	Suprascapular

Source: research data.

<sup>a</sup> Based on clinical examination and complementary electroneuromyography examination.



**Fig. 4 – Patient with PTS in the right shoulder, affecting the axillary nerve. (A) Atrophy in the area of the deltoid: appearance at the time of the diagnosis. (B) Appearance after three months of physiotherapeutic rehabilitation.**

full recovery of muscle strength. In the other two patients, although muscle hypotrophy could still be seen, this did not have any repercussion on their daily and sports activities.

## Discussion

The etiology of PTS is not well defined, but it has been attributed to viral infections and autoimmune reactions. In some clinical reports, before the symptoms appeared, a period of fever or infection of the upper airways or even an immunological reaction after vaccination was described. No such association was determined in our study.

Males are more frequently affected, in proportions that according to the literature range from 2:1 to 11.5:1.<sup>11,18,20</sup> There is no preference regarding the laterality of the disorder, or any correlation with the dominant limb. However, one third of the patients may be affected bilaterally and asymmetrically.<sup>21</sup> Turner described a case of bilateral impairment, six months

after the start of the symptoms. Around one third of the patients develop PTS bilaterally.<sup>11</sup> In our study, the proportions relating to sex were 1.6 men to one woman. The mean age was 29 years and there were no cases of bilaterality.

There is no consensus regarding the peripheral nerve most frequently affected. According to Turner and Parsonage,<sup>11</sup> the long thoracic nerve is the one most affected. Magee and DeJong<sup>20</sup> and Tsairis et al.<sup>11</sup> reported that the suprascapular nerve was the one most frequently affected. According to Mulvey et al.,<sup>22</sup> even the phrenic nerve can be affected in cases of PTS. In our sample, it was seen that the long thoracic nerve ( $n=3$ ) and suprascapular nerve ( $n=3$ ) were equally affected, followed by the axillary nerve ( $n=2$ ).

The characteristic pattern of sudden pain with spontaneous improvement followed by weakness of the musculature of the scapular belt is the key to diagnosing this syndrome. In all of our patients, we identified this pattern. The pain has been described as severe and excruciating, and it may persist for hours or even up to three or four weeks.<sup>23</sup> In our patients, the pain lasted on average for five days, with a minimum of 24 h and maximum of 15 days. The consequences of impairment of the motor nerve fibers, such as weakness and muscle atrophy, were perceptible and constituted the patients' main complaint after the hyperalgesic phase. Regarding alterations to sensitivity, such as analgesia and hypoesthesia, these were minimal and often limited to a small area. These findings were compatible with the classical descriptions and also with more recent studies comprising case series with large numbers of patients.<sup>12,24,25</sup>

Electroneuromyography examinations are important for confirming the diagnosis. Alterations on these examinations are generally perceptible three weeks after the start of the symptoms.<sup>26,27</sup> These usually consist of acute denervation and indicate situations of axonal degeneration, with potential positive fibrillation spike waves. From magnetic resonance examinations, the following findings in the musculature affected have been described in the literature: intramuscular edema and muscle atrophy that may or may not be associated with fatty infiltration<sup>28,29</sup> (Fig. 3). The increased signal with T2 weighting is due to muscle edema. According to Wessig et al.,<sup>30</sup> there is an increase in capillary blood volume 48 h after muscle denervation, which favors extravasation from intracapillary sites to extracellular sites. These alterations, which have been described in magnetic resonance examinations, were consistent with what was observed in our patients (Fig. 3).

**Table 2 – Results from Constant and Murley scores at the end of the mean follow-up period of 14 months.**

Constant and Murley score	Mean (min-max)
Pain	15 (15-15)
Activities	20 (20-20)
Mobility	40 (40-40)
Strength	21.37 (19-25)
Total	96.37 (94-100)

Source: research data.

The treatment for PTS can be divided into two phases. In the first phase (hyperalgesia), analgesics and rest for the limb affected, with use of a sling, are prescribed. No corticosteroid anti-inflammatory agents were used, since the etiological identity of the syndrome could not be determined (i.e. viral or autoimmune). Thus, we do not recommend use of this class of drugs, although studies have shown that their use may shorten the time taken for recovery of strength to start and improve the pain during the acute phase.<sup>11,21</sup> After the pain has improved, the second phase can be started, which aims to reestablish and maintain the range of motion, followed by muscle strengthening. In 1960, Magee and DeJong<sup>20</sup> reported that full recovery might take as long as eight years. However, all the patients treated in our study over the 14-month period presented improvements in trophism and strength in the affected limb. Six of the eight patients declared that they did not feel any difference in relation to strength and pain, in comparison with the contralateral side.

Although Parsonage–Turner syndrome is not a common condition in clinical practice, it is important that orthopedists should become familiar with it and include it in the differential diagnosis when patients complain of pain and weakness in the scapular belt. The diagnosis is clinical and the electroneuromyography examination can be used to confirm it. Other examinations are only needed for the differential diagnosis. The prognosis is good, with spontaneous resolution of the pain in around 80–90% of the cases.<sup>11,31</sup> However, strength is not always fully recovered and the condition may present recurrence.<sup>11,12</sup> Conservative treatment, comprising use of analgesics and physiotherapeutic exercises, generally brings satisfactory results, but there have been reports of surgical treatment with tendon transfers, as late treatment for loss of strength.

The present study has the advantage of providing a report on a series of cases of a rare disease that needs to be remembered as a differential diagnosis for a painful shoulder condition, especially when associated with muscle weakness and hypotrophy. The main disadvantage was the small number of patients in the sample. Nonetheless, our findings did not diverge from the reports in the literature in other countries, with large samples of patients.

## Conclusion

Amyotrophic neuralgia is a pathological condition that is difficult to diagnose in the acute phase. It most often presents as an acute condition of intense pain in the scapular belt, which is generally self-limited and in most cases evolves to functional recovery. Careful clinical evaluation and early diagnosis using electroneuromyography help toward adequate management of the disease and bring reassurance for patients and their doctors, along with information regarding the recovery. Correct diagnosis also has the advantage of avoiding unnecessary examinations.

## Conflicts of interest

The authors declare no conflicts of interest.

## REFERENCES

1. Feinberg J. Fall von Erb-Klumpke scher: lahmung nach influenza. *Centralbl.* 1897;16:588–637.
2. Bramwell E, Struthers JW. Paralysis of the serratus magnus and lower part of the trapezius muscles. *Rev Neurol Psychiatr.* 1903;1:717–30.
3. Wyburn-Mason R. Brachial neuritis occurring in epidemic form. *Lancet.* 1941;1:662–3.
4. Burnard ED, Fox TG. Multiple neuritis of shoulder girdle: report of nine cases occurring in second New Zealand expeditionary force. *NZ Med J.* 1942:41.
5. Spillane JD. Localised neuritis of the shoulder girdle: a report of 46 cases in the MEF. *Lancet.* 1943;2:532–5.
6. Parsonage MJ, Turner JW. Neuralgic amyotrophy; the shoulder-girdle syndrome. *Lancet.* 1948;1(6513):973–8.
7. Auge WK 2nd, Velazquez PA. Parsonage–Turner syndrome in the Native American Indian. *J Shoulder Elbow Surg.* 2000;9(2):99–103.
8. Pellas F, Olivares JP, Zandotti C, Delarque A. Neuralgic amyotrophy after parvovirus B19 infection. *Lancet.* 1993;342(8869):503–4.
9. Suarez GA, Giannini C, Bosch EP, Barohn RJ, Wodak J, Ebeling P, et al. Immune brachial plexus neuropathy: suggestive evidence for an inflammatory-immune pathogenesis. *Neurology.* 1996;46(2):559–61.
10. Kuhlensäumer G, Hannibal MC, Nelis E, Schirmacher A, Verpoorten N, Meuleman J, et al. Mutations in SEPT9 cause hereditary neuralgic amyotrophy. *Nat Genet.* 2005;37(10):1044–6.
11. Tsairis P, Dyck PJ, Mulder DW. Natural history of brachial plexus neuropathy. Report on 99 patients. *Arch Neurol.* 1972;27(2):109–17.
12. Van Alfen N, van Engelen BGM. The clinical spectrum of neuralgic amyotrophy in 246 cases. *Brain.* 2006;129 Pt 2:438–50.
13. Bardos V, Somodska V. Epidemiologic study of a brachial plexus neuritis outbreak in northeast Czechoslovakia. *World Neurol.* 1961;2:973–9.
14. Seror P, Harbach S. Parsonage–Turner syndrome after cytomegalovirus infection. *Presse Med.* 1990;19(11):527–8.
15. Botella MS, Garcia M, Cuadrado JM, Martin R. Parsonage–Turner syndrome in positive HIV patients. *Rev Neurol.* 1997;25(137):143 [Letter].
16. Jiguet M, Troussier B, Phelip X. Parsonage and Turner syndrome. Apropos of a case, with demonstration of *Borrelia burgdorferi* infection. *Rev Rhum Mal Osteoartic.* 1991;58(5):409–11.
17. Beghi E, Kurland LT, Mulder DW, Nicolosi A. Brachial plexus neuropathy in the population of Rochester, Minnesota, 1970–1981. *Ann Neurol.* 1985;18(3):320–3.
18. Turner JW, Parsonage MJ. Neuralgic amyotrophy (paralytic brachial neuritis); with special reference to prognosis. *Lancet.* 1957;273(6988):209–12.
19. Constant CR, Murley AH. A clinical method of functional assessment of the shoulder. *Clin Orthop Relat Res.* 1987;(214):160–4.
20. Magee KR, Dejong RN. Paralytic brachial neuritis. Discussion of clinical features with review of 23 cases. *JAMA.* 1960;174:1258–62.
21. Van Alfen N. The neuralgic amyotrophy consultation. *J Neurol.* 2007;254(6):695–704.
22. Mulvey DA, Aquilina RJ, Elliott MW, Moxham J, Green M. Diaphragmatic dysfunction in neuralgic amyotrophy: an electrophysiologic evaluation of 16 patients presenting with dyspnea. *Am Rev Respir Dis.* 1993;147(1):66–71.

23. McCarty EC, Tsairis P, Warren RF. Brachial neuritis. *Clin Orthop Relat Res.* 1999;(368):37-43.
24. Favero KJ, Hawkins RH, Jones MW. Neuralgic amyotrophy. *J Bone Jt Surg Br.* 1987;69(2):195-8.
25. Misamore GW, Lehman DE. Parsonage-Turner syndrome (acute brachial neuritis). *J Bone Jt Surg Am.* 1996;78(9):1405-8.
26. Weikers NJ, Mattson RH. Acute paralytic brachial neuritis. A clinical and electrodiagnostic study. *Neurology.* 1969;19(12):1153-8.
27. Rubin DI. Neuralgic amyotrophy: clinical features and diagnostic evaluation. *Neurologist.* 2001;7(6):350-6.
28. Scalf RE, Wenger DE, Frick MA, Mandrekar JN, Adkins MC. MRI findings of 26 patients with Parsonage-Turner syndrome. *AJR Am J Roentgenol.* 2007;189(1):W39-44.
29. Gaskin CM, Helms CA. Parsonage-Turner syndrome: MR imaging findings and clinical information of 27 patients. *Radiology.* 2006;240(2):501-7.
30. Wessig C, Koltzenburg M, Reiners K, Solymosi L, Bendszus M. Muscle magnetic resonance imaging of denervation and reinnervation: correlation with electrophysiology and histology. *Exp Neurol.* 2004;185(2):254-61.
31. Tonali P, Uncini A, Di Pasqua PG. So-called neuralgic amyotrophy: clinical features and long term follow-up. *Ital J Neurol Sci.* 1983;4(4):431-7.