

# Intracapsular Femoral Neck Fractures in the Elderly\*

## *Fraturas intracapsulares do colo femoral no idoso*

Roberto Dantas Queiroz<sup>1,2</sup> Richard Armelin Borger<sup>1</sup> Lourenço Galizia Heitzmann<sup>1</sup>   
David Jeronimo Peres Fingerhut<sup>1</sup> Luiz Henrique Saito<sup>1</sup>

<sup>1</sup>Orthopedist and Traumatologist, Orthopedics and Traumatology Service, Hospital do Servidor Público Estadual de São Paulo – IAMSPE, São Paulo, SP, Brazil

<sup>2</sup>Director of the Orthopedics and Traumatology Service, Hospital do Servidor Público Estadual de São Paulo – IAMSPE, São Paulo, SP, Brazil

**Address for correspondence** Roberto Dantas Queiroz, PhD, Hospital do Servidor Público Estadual de São Paulo, Rua Borges Lagoa, 755, São Paulo, SP, 04038-034, Brazil (e-mail: robdanqueiroz@globo.com).

Rev Bras Ortop 2022;57(3):360–368.

### Abstract

#### Keywords

- ▶ hip fractures
- ▶ femoral neck fractures
- ▶ elderly

#### Resumo

#### Palavras-chave

- ▶ fraturas do quadril
- ▶ fraturas do colo femoral
- ▶ idoso

Currently, intracapsular femoral neck fracture (IFNF) is still a great challenge for orthopedists. In spite of the progress that has been made, a high mortality rate persists in the first year, especially in Brazil, where there is no awareness that such fractures in elderly patients should be treated as a medical emergency. The present article seeks to provide an update on the preoperative, surgical, and postoperative approaches.

Atualmente, a fratura intracapsular do colo femoral (FICF) ainda é um grande desafio para os ortopedistas. Apesar dos grandes avanços feitos, persiste uma grande taxa de mortalidade no primeiro ano, sobretudo no Brasil, onde não há uma conscientização de que tais fraturas nos pacientes idosos devem ser tratadas como uma urgência médica. O presente artigo busca fornecer uma atualização das condutas pré-operatórias, cirúrgicas e pós-operatórias.

## Introduction

The location and anatomy of the hip joint make the femoral neck prone to fractures. The blood supply to the femoral head

runs along the femoral neck, and it is essential for the irrigation of the femoral head. In patients with misplaced fractures, treated by internal fixation and open or closed reduction, avascular necrosis is the most common complication.<sup>1</sup>

The risk factors for femoral neck fractures (FNFs) include the female gender, reduced mobility, and low bone density.<sup>2,3</sup>

The typically patient has a history of recent trauma; however, in cases of dementia or cognitive impairment, there

\* *Work developed at the Orthopedics and Traumatology Service, Hospital do Servidor Público Estadual de São Paulo, Instituto de Assistência Médica ao Servidor Público Estadual (IAMSPE), São Paulo, SP, Brazil.*

received  
March 20, 2021  
accepted after revision  
May 18, 2021

DOI <https://doi.org/10.1055/s-0041-1736473>.  
ISSN 0102-3616.

© 2022. Sociedade Brasileira de Ortopedia e Traumatologia. All rights reserved.

This is an open access article published by Thieme under the terms of the Creative Commons Attribution-NonDerivative-NonCommercial-License, permitting copying and reproduction so long as the original work is given appropriate credit. Contents may not be used for commercial purposes, or adapted, remixed, transformed or built upon. (<https://creativecommons.org/licenses/by-nc-nd/4.0/>)

Thieme Revinter Publicações Ltda., Rua do Matoso 170, Rio de Janeiro, RJ, CEP 20270-135, Brazil

may be no history of trauma or osteoarticular degeneration. The patient will have pain with a decrease in the range of motion of the hip. In a non-displaced fracture, there may be no deformity, while displaced fractures may present with a shortened and laterally-rotated lower limb. In the history of low-energy trauma, the mechanism is essential, and the events around the fall should be questioned to rule out any possible cause of syncope. In cases of high-energy trauma, the Advanced Trauma Life Support (ATLS) protocol should be followed when indicated. First, any non-orthopedic injury and then ipsilateral injuries should be assessed, including femur fractures or knee injuries. It is also essential to know/assess the levels of cognition and activity, the use of aids to walk, the use of anticoagulants, and the history of cancer, pulmonary embolism, or deep vein thrombosis (DVT). The doctor should perform a complete neurovascular examination of the affected extremity. The medical evaluation should include basic laboratory tests (complete blood count, complete coagulogram, electrolytes, type-1 urine, renal and hepatic functions), as well as chest X-rays and electrocardiogram. Elderly patients with known or suspected heart disease may benefit from a preoperative cardiac evaluation. Preoperative medical optimization is vital in the geriatric population. There are many classifications for FNFs, and the Garden classification is the most used to identify the type of fracture. It is useful because it shows the severity of the fracture, assisting in the choice of surgical treatment. For the treatment, the classification is often simplified in stable (grades 1 and 2) versus unstable (grades 3 and 4) fractures (→Figure 1).<sup>4</sup> In FNFs in the elderly, unstable cases are preferably treated with hip arthroplasty, while, in stable cases, depending on factors such as osteo-

porosis and the level of activity of the elderly patient, osteosynthesis can be preferred. The non-surgical treatment is rarely indicated, only reserved for patients who are non-ambulators, those submitted to palliative care and/or with High surgical risk.

To be more didactic, we will divide the subject into three major topics that will be subdivided: preoperative, surgical, and postoperative managements.

## Methods

The literary support for the construction of this update article was collected in the Scientific Electronic Library Online (SciELO), Latin American and Caribbean Health Sciences Literature (Literatura Latino-Americana e do Caribe em Ciências da Saúde, LILACS, in Portuguese), Medical Literature Analysis and Retrieval System Online (MEDLINE), Pubmed, and Cochrane Library databases. Three descriptors were selected in the Descritores em Ciências de Saúde (Descriptors in Health Sciences)/Medical Subject Headings (DeCs/MeSH): femoral neck fracture, hip fracture and elderly.

In Pubmed, the terms were searched in isolation and in combinations of two of the three terms (*femoral neck fracture* and *elderly*; *hip fracture* and *elderly*). As inclusion criteria, we established original articles, practical guides and reviews published in Portuguese, Spanish and English in the period 2015 to 2020, and classic articles to make up the proposed objectives. The exclusion criterion was articles that were not directly about proximal femur intracapsular fractures in the elderly population, such as transtrochanteric fractures, osteoarthritis, and avascular necrosis.

In the Cochrane Library, the terms *femoral neck fracture* and *hip fracture* were used.

The selection of the articles found took place in three stages: 1) reading of titles and exclusion of those that did not fit the aforementioned criteria; 2) reading only the abstracts, excluding those that did not fit the criteria; and 3) reading the full text of all remaining articles.

## Results

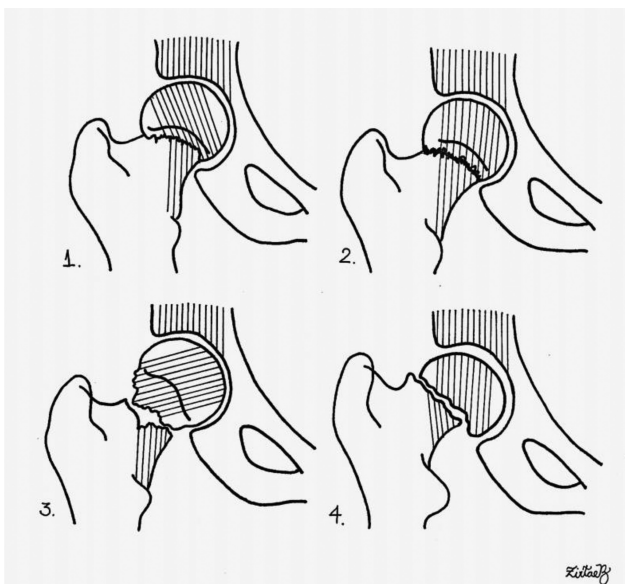
In the Pubmed database, 743 articles were found with the 3 combinations, 1,212 with the terms *femoral neck fracture* AND *hip fracture*, 937 with the terms *femoral neck fracture* AND *elderly*, and 4,570 with the terms *hip fracture* AND *elderly*. In the Cochrane Library, 23 review articles were found.

We selected the most relevant and updated articles to write the present update article.

## Discussion

### Preoperative Aspects

In relation to the preoperative management, the following is addressed: imaging tests, analgesia, use of traction, ideal moment to perform the surgery, and previous use of anticoagulants.



**Fig. 1** Garden classification for femoral neck fractures. 1–Grade 1: incomplete and impacted in valgus; 2–Grade 2: complete and without deviation; 3–Grade 3: complete, with deviation and acetabular trabeculae not aligned with those of the head; and 4–Grade 4: complete, with deviation and acetabular trabeculae aligned with those of the head.

### Imaging Exams

The imaging diagnosis of FNF is often performed on anteroposterior views of the pelvis and profiles of the hip, and it is easy in cases of partial or total displacement between the proximal and distal fragments. However, in cases with compatible history and negative radiographic examinations, it is necessary to expand the investigation with other tests. The literature is unanimous in stating that magnetic resonance imaging (MRI) is the most sensitive test in cases of so-called occult fractures, such as stress fractures in the young or elderly. To avoid underdiagnosis and the hasty conduction of these cases, we can use more refined tests than just anteroposterior radiographs of the pelvis. Foex and Russel<sup>5</sup> briefly reviewed six articles comparing computed tomography (CT) with MRI, concluding that CT is a valid first-line imaging technique in suspected hidden hip fractures, and is easily accessible in most centers. Early diagnosis is important for the patient. In cases of reports of CT variability, an experienced musculoskeletal radiologist should review negative or inconclusive CT scans. However, when clinical suspicion remains, in spite of normal or inconclusive results on the CT, an MRI scan is required.<sup>5</sup> In general, the diagnosis of FNF is made with simple radiographs of the pelvis and hip, as aforementioned, and the CT and MRI are used in inconclusive cases or in those that require a specific evaluation for preoperative planning.

### Preoperative Regional Analgesia

Blockage of peripheral nerves with local anesthetic agents can be used to reduce pain after hip fracture and subsequent surgery. High-quality evidence shows that regional block reduces movement-evoked pain 30 minutes after application. Moderate-quality evidence<sup>6</sup> shows reduced risk of pneumonia, reduced time until the first mobilization, and a reduction in the cost of hospitalization and in the use of analgesics in the postoperative period. The American Society of Regional Anesthesia suggests that regional anesthesia techniques should not be routinely performed in adult patients whose senses have been compromised by general anesthesia or deep sedation, but that adult patients with specific conditions (such as, developmental delay) may be appropriate exceptions to this recommendation after the risks and benefits have been considered.<sup>7</sup> Regional analgesia is not often performed. Preoperative analgesia is usually performed with dipyrone, paracetamol, and opioids. The use of non-hormonal anti-inflammatory drugs (NSAIDs) should be avoided in elderly patients due to the possibility of developing complications.

### Preoperative Traction

Numerous studies have shown that preoperative skin or skeletal traction does reduce pain OR the use of analgesics during hospitalization.<sup>8</sup> Neither there is evidence of improvement or ease in the reduction, fixation, or quality of the stabilization of fractures intraoperatively. The routine use of (cutaneous or skeletal) traction before surgery does not seem to have any benefits; however, the evidence is insufficient to rule out the advantages and potential

disadvantages of traction.<sup>8</sup> When traction is not used, the injured limb is usually placed on a pillow, and the patient is encouraged to adopt a position of greatest possible comfort, aiming at their well-being.

### Ideal Moment of Surgery

Femoral neck fractures should be treated as emergencies, and they should be resolved in a short time so that the elderly patient is no longer bedridden, because the complications, such as bedsores and bronchoaspiration pneumonia, increase morbidity and mortality, and should be avoided.

A great challenge was to define the ideal time to perform the surgery: immediately or after the clinical evaluations. Although several studies<sup>9,10</sup> have shown the benefits of performing surgery within 48 hours, one study<sup>9</sup> showed no damage with a delay of up to four days in total hip arthroplasty (THA) for patients fit for surgeries which were not postponed for medical reasons. Patients who had the surgeries postponed for medical reasons had the highest mortality, and it is this subset of patients that could benefit most from the earlier surgery. Maheshwari et al.<sup>10</sup> observed a linear relationship between these times and mortality at one year. Each 10-hour delay from admission to surgery was associated with an estimated 5% higher probability of mortality in 1 year. Therefore, the authors<sup>10</sup> suggest that hip fractures be treated urgently and like other time-sensitive pathologies, such as stroke and myocardial ischemia.

### Previous Use of Anticoagulants

There is a major concern regarding patients undergoing anticoagulant therapy (with clopidogrel, warfarin (factor Xa) inhibitors, including rivaroxaban, apixaban and dabigatran, dipidamol/aspirin, and aspirin 325 mg), and, due to seizure and indications by a multidisciplinary team, surgeons tend to delay surgeries in patients with fractures due to the use of these medications. However, there are studies that suggest that there is no advantage to this practice. The decision depends on the evaluation of the preoperative tests and on the possibility of using adjuvants to control the coagulation cascade.

Lott et al.<sup>11</sup> conducted a systematic review of studies on the following parameters: patients aged  $\geq 60$  years with isolated hip injury, time until surgery, length of hospitalization, transfusion rate, blood loss, length of the procedure, complication rate, need for admission to an intensive/semi-intensive care unit, discharge, and cost of admission. Since the main differences were regarding the indication of anesthesia, with a higher proportion of patients taking anticoagulants receiving general anesthesia, the time until surgery and the length of hospitalization were longer in the anticoagulated cohort (8.3 days versus 7.3 days;  $p=0.033$ ; and 1.9 days versus 1.6 days); however, after a comparison with the controls by age, Charlson comorbidity index and type of anesthesia, these differences were not significant. The surgical outcomes were equivalent, and the lengths of the procedures were similar procedure, as well as the level of blood loss and the requirement for transfusion. There was also a greater use of postacute care

in the anticoagulated cohort, with only 10.7% of patients discharged compared to 19.9% in the non-anticoagulated group ( $p=0.026$ ). Finally, there was no difference in the cost of care.<sup>11</sup>

According to Ginsel et al.,<sup>12</sup> it is safe to continue the administration of aspirin and clopidogrel before the FNF surgery. The risk of postponing the surgery outweighs the risk of perioperative bleeding.

### Surgical Aspects

In relation to the surgical approaches, the following aspects are addressed: anesthesia, tranexamic acid (TXA), stable fractures, unstable fractures, unipolar versus bipolar hemiarthroplasty (HA), HA versus THA, cemented versus non-cemented prostheses, dual-mobility and constrained prostheses, and surgical accesses.

### Anesthesia

There are three possibilities of anesthesia for patients who will undergo FNF surgery: general anesthesia, spinal anesthesia or neuroaxial block, and peripheral nerve block. The choice usually results from an understanding between the surgical and anesthesia teams, aiming to optimize the procedure and reduce the risks to the patient.

Current review articles have tried to determine the differences in indications of anesthesia types by comparing several studies that assessed patients undergoing anesthesia in the postoperative period of surgeries due to proximal femur fractures: mortality in the first month, thromboembolic events, and systemic alterations by microorganisms or overload. Regarding mortality in the first month, pneumonia up to the seventh day, myocardial infarction until the seventh day, stroke until the seventh day, state of acute confusion until the seventh day, acute venous thrombosis without adequate prophylaxis until the tenth day, and return of the patient home with one year of follow-up present very low evidence to estimate which type of anesthesia would result in fewer complications.

The lack of definitive studies and of the presentation of new research leads to the need for an in-depth study and an update of the surgical team (surgeons and anesthesiologists) to provide the best outcome for the treatment of patients.<sup>13</sup>

### Tranexamic acid

Tranexamic acid is a synthetic antifibrinolytic agent derived from the amino acid lysine that reversibly blocks lysine binding sites in the plasminogen, reducing its conversion into the active metabolite plasmin, and thus promoting the dissolution of fibrin.<sup>14</sup>

Studies have shown that the intravenous use of TXA in hip surgeries significantly reduced the rates of postoperative bleeding and the drop in serum hemoglobin. Consequently, there was a reduction in the need for blood transfusion. As for the different administration protocols, the use of the bolus and bolus/infusion pump methods has shown to have a very similar influence on serum hemoglobin and the amount

of blood loss through the suction drains, showing no statistically significant differences.<sup>15</sup>

A Cochrane review showed that, in an emergency surgical setting, TXA reduced the likelihood of receiving an erythrocyte transfusion by 30%.<sup>14</sup>

### Stable Femoral Neck Fractures

Cserhati et al.<sup>16</sup> compared the non-surgical and surgical treatment of stable FNFs (Garden grades 1 and 2). The benefits of avoiding anesthesia and surgery contrast with the high rate of fracture displacement, which occurred in 20% of the cases and required surgery, generating higher morbidity, mortality and longer hospital stay in patients treated without surgery.

Osteosynthesis can be performed by: canulated screws, with several combinations of position according to fracture type and line; dynamic hip screw (DHS); and DHS associated with canulated screws, medial support plates and/or locked plate for trochanteric support. In elderly patients, the option of performing HA or THA should consider the high rate of complications and reoperations in fixations. However, fracture fixation was associated with a significant decrease in surgical time (43 minutes versus 67 minutes) compared to HA, and resulted in lower levels of blood loss, a decrease in 1 year of the mortality rate, lower levels of pain in the first year, lower reduction in mobility, and a decrease in the need for orthosis for ambulation.<sup>17,18</sup> Thus, stable FNFs in healthy patients should preferably be treated by osteosynthesis.

### Unstable Femoral Neck Fractures

Unstable FNFs (Garden grades 3 and 4) are the most related to unsatisfactory outcomes after osteosynthesis of the proximal femur. Currently arthroplasties are considered mandatory in most cases of diverted FNF in the elderly. Numerous studies<sup>19-24</sup> have consistently reported better results with HA or THA than with fixation, more favorable pain scores, better functionality, lower complication rates, and, above all, lower rates of reoperation.

In order to choose the best implant, the individual characteristics of the patient should be considered, such as: bone quality, comorbidity profile, objectives, expectations, and preinjury functional status.<sup>25</sup> In general, unstable fractures are treated with hip arthroplasty, and the type of prosthesis chosen depends on the aforementioned factors.

### Unipolar versus Bipolar

There are several component options to perform hip HA in diverted FNFs, and each component has its respective indications.

According to a study by Filippo et al.,<sup>26</sup> there is evidence that HA with bipolar implants results in lower levels of acetabular erosion compared to unipolar implants. According to the authors,<sup>26</sup> mortality and complications such as dislocations, revision procedures and the Harris Hip Score showed no statistical differences after two years of follow-up.<sup>26</sup>

### Hemiarthroplasty versus Total Hip Arthroplasty

Hemiarthroplasty provides satisfactory results in patients with limited functional demands, but it may eventually require conversion into THA due to acetabular wear and erosion in physically-active patients. Total hip arthroplasty is associated with excellent functional results, but it presents higher rates of complications, mainly instability. In randomized clinical trials,<sup>27,28</sup> the mean surgical time and blood loss were significantly longer with THA than with HA. The mean surgical time was of 102 minutes (interval of 70 to 151 minutes) for THA, and of 78 minutes (range 43 to 131 minutes) for HA, and, in 26% of THA procedures and 7% of HA, the level of intraoperative blood loss was > 500 mL.<sup>27,28</sup>

The choice of the appropriate treatment requires a discussion about the risks and benefits for the patient and their family members. This can help determine which patients may benefit from superior pain relief and lower likelihood of revision surgery.<sup>28</sup>

### Cemented versus Non-Cemented Arthroplasty

The option for cementation in THA or hip HA is a controversial topic in systematic reviews.

Parker and Cawley<sup>29</sup> evaluated 400 patients undergoing cemented and non-cemented HA. In the first year, there mortality in the group of non-cemented HA was a slightly higher: 64 versus 51 patients. Patients treated with non-cemented HA had a higher number of femur fractures intraoperatively: five versus two cases. In the cemented group, there were four deaths in the perioperative period. The authors<sup>29</sup> concluded that, when the conditions allow, cemented HA should be used.

Li et al.<sup>30</sup> showed that non-cemented prostheses can reduce the operative time and the incidence of pulmonary embolism, but do not reduce mortality, blood loss, and hospitalization. More importantly, in their study,<sup>30</sup> the incidence of prosthesis-related complications was higher in non-cemented patients. However, Tan et al.<sup>31</sup> reported a high rate of perioperative mortality with cemented stems, and that they should be used with caution in elderly patients with hip fractures and multiple comorbidities. Among a total of 751 patients with femoral fracture operated with cemented stems, the mortality rates at 7 and 30 days were of 2.7% and 6.8% respectively.<sup>31</sup>

Currently, there is a trend in the literature for the use of non-cemented prostheses. Cemented arthroplasty still has numerous indications, especially in relation to the femoral component, for patients with very compromised bone quality.

### Constrained and Dual-Mobility Prostheses

The instability of hip prostheses has always been a complication feared by surgeons. Several factors contribute to this complication, and they can be divided into: intrinsic factors of each patient – muscle weakness, obesity, neuromuscular degenerative diseases (Parkinson, Alzheimer); intraoperative factors – poor positioning of the implant, chosen access route; and postoperative factors – two or more episodes of prosthesis dislocation. In these cases, con-

strained or dual-mobility (DM) prostheses can be indicated, and constrictors provide greater restriction in range of motion.

The DM prosthesis has always exhibited excellent results in reducing THA instability, but there was skepticism about the intraprosthetic dislocation unique to DM. This is induced by the loss of the polyethylene retaining edge, resulting in the separation of the femoral head from the polyethylene cover. Modifications in implants, including the use of better-quality polyethylene and of a cylindrical and smooth femoral neck, have almost eliminated intraprosthetic dislocations in current DM prostheses. In several short-term studies, the DM prosthesis resulted in a statistically significant reduction in displacement rates compared to standard THA. Results have been particularly promising among populations of at-risk patients and in cases of FNFs, in which the low rates of displacement and better functional outcomes are recurring topics. From an economic perspective, DM is equally attractive, with research<sup>32</sup> demonstrating lower cumulative costs compared to standard THA in patients with high risk of dislocation. Long-term clinical evidence and comparative prospective studies are needed to strengthen current research. The DM prosthesis may well represent in the future the gold standard for THA in populations of high-risk patients and in cases of FNFs, but, due caution regarding its long-term performance is necessary before recommending it. Currently, the main indications for the use of DM prostheses are in the so-called at-risk patients, who are: of advanced age ( $\geq 75$  years), women (aged  $\geq 70$  years), grade-3 patients in the classification of the American Society of Anesthesiologists (ASA), those submitted to arthroplasty review, those with dysplasia, cognitive impairment, neurological deficit, patients submitted to previous osteosynthesis surgery and previous spinal surgery (spinal balance), those with recurrent dislocation and abductor insufficiency, patients submitted to HA review, and those with hypermobility due to autoimmune diseases.<sup>33</sup>

### Surgical Access Routes

The most used access routes in patients with FNF are the posterior or lateral routes, and, recently, the anterior route has been gaining popularity among surgeons. The posterior access route for THA is the oldest and still the most used according to Chechik et al.<sup>33</sup> Numerous high-quality studies<sup>34-36</sup> compared the lateral and posterior pathways in HA and THA, and there are more cases of heterotopic ossification and delay in rehabilitation (within six months of the procedure) with the lateral route, and higher rates of dislocation with the posterior pathway, and the authors<sup>34-36</sup> did not find differences between the two routes regarding operative time, blood loss, length of hospital stay, and discrepancy in the length of the lower limbs.

In relation to the route prior to the other access routes, studies<sup>36-40</sup> report superior clinical results in the short term, but, at the end of the 12-month follow-up, no differences in postoperative function were observed. However, in other studies,<sup>40,41</sup> a higher number of femoral fractures was

observed in the insertion of the femoral nail and of cases of neuroparaxia of the lateral femoral cutaneous nerve.<sup>40,41</sup>

### Postoperative Aspects

Regarding the postoperative approaches, the following are addressed: DVT prophylaxis, transfusion threshold, occupational and physical therapies, intensive physical therapy, nutrition, interdisciplinary care program, multimodal analgesia, calcium, vitamin D, and prevention of new fractures.

### Prophylaxis of Deep Vein Thrombosis

Xia et al.<sup>42</sup> observed a high prevalence of preoperative venous thromboembolism in elderly patients with FNF, with risk factors identified. They found that the most commonly detected DVT was isolated calf muscle vein thrombosis. The authors<sup>42</sup> also suggested that direct surgery without the preoperative use of therapeutic anticoagulation for DVT would not reduce the risk of thrombus extension, and the therapeutic use of anticoagulation may worsen postoperative anemia. On the other hand, we know that cases should be individualized; Zhang and Zhang,<sup>43</sup> for example, showed, in a study on the benefit of DVT prophylaxis, that anticoagulant drugs of prolonged duration, up to four weeks after surgery, can significantly reduce the morbidity of venous thromboembolism in the postoperative period, and do not increase the risk of bleeding. Patients at risk of bleeding should be carefully evaluated regarding the risks and benefits of drug prevention in order to choose the best treatment. The authors<sup>43</sup> concluded that there is still no universal protocol regarding these drugs and their effects, and each case should be considered in isolation, and further research should be carried out to arrive at safe protocols for the prophylaxis of thromboembolisms.

### Transfusion Threshold

Blood loss in surgeries for FNF is of ~ 500 mL, and, with the expectation of surgical aggression in hip arthroplasties, we routinely use transfusion of blood elements in the perioperative management. The risks and benefits of this practice are a constant target of studies, and the real need for transfusion is often questionable. Gupta et al.,<sup>44</sup> in a retrospective study, showed that the patient's blood control was associated with reduced use of blood transfusion, with similar or superior clinical results in orthopedic surgery. A hemoglobin threshold of 7 g/dl seems to be safe for many orthopedic patients, not higher values, as suggested in the past. Gu et al.,<sup>45</sup> in a systematic review, concluded that, in patients undergoing orthopedic surgery, when comparing liberal transfusion (when a hemoglobin level of 10.0 g/dL is desired in the preoperative period) and restrictive transfusion (when a minimum hemoglobin level of 8.0 g/dL or symptomatic anemia is accepted), liberal transfusion increases the risk of cardiovascular events, regardless of preexisting cardiovascular diseases. It is important to highlight that the increased risk was observed in patients undergoing hip fracture surgery, but did not reach significance in those submitted to elective arthroplasty.<sup>45</sup>

### Rehabilitation Therapy

In its guidelines, the National Institute for Health and Care Excellence (NICE) of the United Kingdom recommends mobilization the day after surgery, unless there is any medical or surgical contraindications.<sup>46</sup> Lee et al.,<sup>47</sup> in a review, recommend early mobilization that includes: getting out of bed, sitting to stand, sitting on a chair with your arms and walking with an auxiliary device. Weight support is allowed according to surgeon guidance, except for those patients who did not walk before the fracture. Early assisted ambulation (initiated within 48 hours of surgery) accelerates functional recovery, and is associated with faster discharge and less need for high-level care. In the subacute period after surgery, physiotherapy focuses on increasing safe mobility and improving muscle function. Physiotherapy after discharge aims to improve gait and balance, and patients in the postoperative period of hip surgery recover in 6 to 9 months after the procedure.

Progressive resistance exercises typically include knee flexion/extension, leg press, hip abduction, and hip extension.

Recovery after a hip fracture tends to be particularly challenging for patients with cognitive impairment. Approximately 19% of all elderly patients with hip fracture have dementia, and up to 40% of them have some type of cognitive impairment. It should be emphasized that it is feasible to implement specific rehabilitation programs aimed at individuals with cognitive impairment.<sup>48</sup> There is consensus in the literature that rehabilitation should be initiated early in order to reduce pulmonary and other complications, starting walking with partial load and exercises for muscle strengthening as early as possible.

### Nutrition

To adapt the caloric intake and improve the muscle mass and nutritional markers of elderly patients, the possibility of oral, nasogastric and/or intravenous supplementation was suggested by several studies.

In a study on nutritional supplementation for hip fracture aftercare among the elderly, Avenell et al.<sup>49</sup> concluded that "There is low-quality evidence that oral multinutrient supplements started before or soon after surgery may prevent complications within the first 12 months after hip fracture, but that they have no clear effect on mortality."

According to Malafarina et al.,<sup>50</sup> "A diet enriched with HMB [ $\beta$ -hydroxy- $\beta$ -methylbutyrate] improves muscle mass, prevents the onset of sarcopenia, and is associated with functional improvement in elderly patients with hip fractures. Orally administered nutritional supplements can help to prevent the onset of sarcopenic obesity."

Despite the lack of conclusive studies, a balanced diet with protein consumption is indicated to ensure a restoration of the muscle and bone framework in patients undergoing surgery for proximal femoral fractures.

### Interdisciplinary Care Program

After a femoral fracture, the elderly patients bring with them chronic and often acute comorbidities, which may even have been the cause of the fall, and should be treated in a

multidisciplinary manner. Geriatrics in large centers is of paramount importance. Neuerburg et al.<sup>51</sup> concluded that interdisciplinary orthogeriatric management revealed an encouraging impact on the long-term outcome of elderly patients with hip fractures. According to these authors,<sup>51</sup> the observed reduction in mortality, care requirements, and readmission rates clearly demonstrate the economic and sanitary impact of interdisciplinary orthopedic care in specialized wards. Bano et al.,<sup>52</sup> in a prospective cohort, concluded that an interdisciplinary approach to elderly patients with hip fractures could reduce in-hospital mortality, improve functional recovery, and increase the likelihood of living alone at home 6 months after the surgical treatment.

### Postoperative Multimodal Analgesia

In the postoperative period of FNF, the combination of types of analgesics, and even nerve block, is an important subject to be taken into account, as a patient with controlled pain is a patient with a better management from the point of view of rehabilitation and overall recovery after surgery. Kang et al.<sup>53</sup> concluded that “multimodal pain management provides additional pain relief until the fourth postoperative day, improves patient satisfaction at discharge, and reduces total narcotic consumption for postoperative pain management after hip hemiarthroplasty for hip fractures”.

The reduction in pain and disability using opioid and non-opioid therapies, regional anesthesia, personalized anesthetic approach, to the patient and strategies to prevent delirium seems to ensure better results.

### Calcium and Vitamin D

Vitamin D, together with calcium, is generally considered necessary for bone health and fracture reduction. Sharma et al.,<sup>54</sup> after a study measuring serum vitamin D levels, found that the serum concentration of 25-hydroxy-vitamin D (25 (OH)D) is a positive predictor. Sprague et al.<sup>55</sup> concluded that a low proportion of elderly patients with hip fracture constantly consume vitamin D and calcium, which may contribute to poorer bone health. The authors<sup>55</sup> also stated that surgeons should be instructed to prescribe/recommend vitamin D and calcium, and institutions should develop comprehensive fragility fracture protocols and patient education strategies to ensure that osteoporosis patients receive bone health treatment in addition to the treatment for the fracture.

### Screening for the Prevention of New Fractures

Several studies and protocols were developed to reduce the incidence of hip fractures, based on the prevention of falls. The World Health Organization's (WHO) fracture-risk algorithm (FRAX) is an osteoporosis screening program to reduce hip fractures, which uses risk factors such as: bone mineral density of the femoral neck, previous fractures, parental history of hip fracture, age, gender, body mass index, ethnicity, smoking, alcohol intake, glucocorticoid use, rheumatoid arthritis, and secondary osteoporosis.

The International Osteoporosis Foundation (IOF) holds campaigns to prevent fractures secondary to osteoporosis and describes a program called Capture the Fracture, which

is based on osteoporosis treatment, risk assessment of falls, an exercise program, and continuing education. The IOF has developed a website, with internationally endorsed standards, which is updated as new studies are made available, achieving the recognition of best practices in the world.<sup>56,57</sup>

### Assessment and Treatment of Osteoporosis

There are several treatment options available for the control of bone disorders: calcium and vitamin D replacement, combined with the use of drug therapies with alendronate, risedronate, ibandronate, teriparatide, zoledronic acid, denosumab, strontium ranelate, selective estrogen receptor modulators (SERMs), raloxifene, and calcitonin. There are indications and contraindications to each of them, and several studies have related the use of teriparatide, zoledronic acid, and alendronate with an increase in bone mineral density (BMD) of the femur and a reduction in the occurrence of bone fractures.<sup>58</sup>

The proper management of proximal femur fractures in patients with osteoporosis has been increasingly promising regarding the outcome of intracapsular hip fractures. Wang et al.<sup>59</sup> concluded that “bisphosphonate and non-bisphosphonate medications for osteoporosis were significantly associated with decreased mortality after fragility hip fracture.”

It is up to the orthopedist, when treating FNF in the elderly, to diagnose osteoporosis and refer the patients to the proper specialist for treatment.

### Final Considerations

The treatment of FNF in the elderly presents several aspects that should be evaluated aiming at the success of the surgery and the reduction in the rate of morbidity and mortality. It is essential to perform thorough preoperative evaluation and planning. Good intraoperative care and adequate postoperative follow-up with a multidisciplinary team, if necessary, greatly reduce the risks of complications and the mortality rate, increasing the chances of success of the surgery, and providing better quality of life to the patient.

#### Approval Form for Medical Research Involving Human Subjects

The authors declare that the present study did not involve research with human subjects.

#### Financial Support

There was no financial support from public, commercial, or non-profit sources.

#### Conflict of Interests

The authors have no conflict of interests to declare.

### References

- 1 Kazley JM, Banerjee S, Abousayed MM, Rosenbaum AJ. Classifications in Brief: Garden Classification of Femoral Neck Fractures. *Clin Orthop Relat Res* 2018;476(02):441–445
- 2 Cummings SR, Black DM, Nevitt MC, et al; The Study of Osteoporotic Fractures Research Group. Bone density at various sites for prediction of hip fractures. *Lancet* 1993;341(8837):72–75

- 3 Li M, Cole PA. Anatomical considerations in adult femoral neck fractures: how anatomy influences the treatment issues? *Injury* 2015;46(03):453–458
- 4 Garden RS. Low angle fixation in fractures of the femoral neck. *J Bone Joint Surg Br* 1961;43(04):647–663
- 5 Foex BA, Russell A. BET 2: CT versus MRI for occult hip fractures. *Emerg Med J* 2018;35(10):645–647
- 6 Guay J, Parker MJ, Griffiths R, Kopp S. Peripheral nerve blocks for hip fractures. *Cochrane Database Syst Rev* 2017;5(05):CD001159
- 7 Neal JM, Barrington MJ, Brull R, et al. The Second ASRA Practice Advisory on Neurologic Complications Associated With Regional Anesthesia and Pain Medicine: Executive Summary 2015. *Reg Anesth Pain Med* 2015;40(05):401–430
- 8 Handoll HH, Queally JM, Parker MJ. Pre-operative traction for hip fractures in adults. *Cochrane Database Syst Rev* 2011;(12):CD000168
- 9 Moran CG, Wenn RT, Sikand M, Taylor AM. Early mortality after hip fracture: is delay before surgery important? *J Bone Joint Surg Am* 2005;87(03):483–489
- 10 Maheshwari K, Planchard J, You J, et al. Early Surgery Confers 1-Year Mortality Benefit in Hip-Fracture Patients. *J Orthop Trauma* 2018;32(03):105–110
- 11 Lott A, Haglin J, Belayneh R, Konda SR, Leucht P, Egol KA. Does Use of Oral Anticoagulants at the Time of Admission Affect Outcomes Following Hip Fracture. *Geriatr Orthop Surg Rehabil* 2018; 9:2151459318764151
- 12 Ginsel BL, Taher A, Whitehouse SL, Bell JJ, Pulle CR, Crawford RW. Effects of anticoagulants on outcome of femoral neck fracture surgery. *J Orthop Surg (Hong Kong)* 2015;23(01):29–32
- 13 Guay J, Parker MJ, Gajendragadkar PR, Kopp S. Anaesthesia for hip fracture surgery in adults. *Cochrane Database Syst Rev* 2016;2(02):CD000521
- 14 Haj-Younes B, Sivakumar BS, Wang M, An VV, Lorentzos P, Adie S. Tranexamic acid in hip fracture surgery: A systematic review and meta-analysis. *J Orthop Surg (Hong Kong)* 2020;28(01): 2309499019887995
- 15 Melo GLR, Lages DS, Madureira Junior JL, Pellucci GP, Pellucci JWJ. The use of tranexamic acid in patients submitted to primary total hip arthroplasty: an evaluation of its impact in different administration protocols. *Rev Bras Ortop* 2017;52(01, Suppl 1):34–39
- 16 Cserháti P, Kazár G, Manninger J, Fekete K, Frenyó S Non-operative or operative treatment for undisplaced femoral neck fractures: a comparative study of 122 non-operative and 125 operatively treated cases. *Injury* 1996;27(08):583–588
- 17 Xu DF, Bi FG, Ma CY, Wen ZF, Cai XZ. A systematic review of undisplaced femoral neck fracture treatments for patients over 65 years of age, with a focus on union rates and avascular necrosis. *J Orthop Surg Res* 2017;12(01):28
- 18 Oñativia IJ, Slullitel PA, Diaz Dileria F, et al. Outcomes of non-displaced intracapsular femoral neck fractures with internal screw fixation in elderly patients: a systematic review. [published correction appears in *Hip Int* 2020;30(2):NP1] *Hip Int* 2018;28(01):18–28
- 19 Davison JN, Calder SJ, Anderson GH, et al. Treatment for displaced intracapsular fracture of the proximal femur. A prospective, randomised trial in patients aged 65 to 79 years. *J Bone Joint Surg Br* 2001;83(02):206–212
- 20 Keating JF, Grant A, Masson M, Scott NW, Forbes JF. Displaced intracapsular hip fractures in fit, older people: a randomised comparison of reduction and fixation, bipolar hemiarthroplasty and total hip arthroplasty. *Health Technol Assess* 2005;9(41): iii–iv, ix–x, 1–65
- 21 Johansson T, Jacobsson SA, Ivarsson I, Knutsson A, Wahlström O. Internal fixation versus total hip arthroplasty in the treatment of displaced femoral neck fractures: a prospective randomized study of 100 hips. *Acta Orthop Scand* 2000;71(06):597–602
- 22 Bray TJ, Smith-Hoefer E, Hooper A, Timmerman L. The displaced femoral neck fracture. Internal fixation versus bipolar endoprosthesis. Results of a prospective, randomized comparison. *Clin Orthop Relat Res* 1988;(230):127–140
- 23 Frihagen F, Nordsletten L, Madsen JE. Hemiarthroplasty or internal fixation for intracapsular displaced femoral neck fractures: randomised controlled trial. *BMJ* 2007;335(7632):1251–1254
- 24 Sikorski JM, Barrington R. Internal fixation versus hemiarthroplasty for the displaced subcapital fracture of the femur. A prospective randomised study. *J Bone Joint Surg Br* 1981;63-B(03):357–361
- 25 Kazley J, Bagchi K. Femoral Neck Fractures. In: StatPearls Treasure Island (FL): StatPearls Publishing May 27, 2020
- 26 Filippo M, Driessen A, Colarossi G, Quack V, Tingart M, Eschweiler J. Bipolar versus monopolar hemiarthroplasty for displaced femur neck fractures: a meta-analysis study. *Eur J Orthop Surg Traumatol* 2020;30(03):401–410
- 27 Blomfeldt R, Törnkvist H, Ponzer S, Söderqvist A, Tidermark J. Internal fixation versus hemiarthroplasty for displaced fractures of the femoral neck in elderly patients with severe cognitive impairment. *J Bone Joint Surg Br* 2005;87(04):523–529
- 28 van den Bekerom MP, Hilverdink EF, Sierevelt IN, et al. A comparison of hemiarthroplasty with total hip replacement for displaced intracapsular fracture of the femoral neck: a randomised controlled multicentre trial in patients aged 70 years and over. *J Bone Joint Surg Br* 2010;92(10):1422–1428
- 29 Parker MJ, Cawley S. Cemented or uncemented hemiarthroplasty for displaced intracapsular fractures of the hip: a randomized trial of 400 patients. *Bone Joint J* 2020;102-B(01):11–16
- 30 Li N, Zhong L, Wang C, Xu M, Li W. Cemented versus uncemented hemi-arthroplasty for femoral neck fractures in elderly patients: A systematic review and meta-analysis of randomized controlled trials. *Medicine (Baltimore)* 2020;99(08):e19039
- 31 Tan KG, Whitehouse SL, Crawford RW. On-Table and Short-Term Mortality: A Single-Institution Experience With Cementing All Hip Arthroplasties for Neck of Femur Fractures. *J Arthroplasty* 2020;35(04):1095–1100
- 32 Cuthbert R, Wong J, Mitchell P, Kumar Jaiswal P. Dual mobility in primary total hip arthroplasty: current concepts. *EFORT Open Rev* 2019;4(11):640–646
- 33 Chechik O, Khashan M, Lador R, Salai M, Amar E. Surgical approach and prosthesis fixation in hip arthroplasty world wide. *Arch Orthop Trauma Surg* 2013;133(11):1595–1600
- 34 Schleicher I, Haas H, Adams TS, Szalay G, Klein H, Kordelle J. Minimal-invasive posterior approach for total hip arthroplasty versus standard lateral approach. *Acta Orthop Belg* 2011;77(04): 480–487
- 35 Mukka S, Mahmood S, Kadum B, Sköldenberg O, Sayed-Noor A. Direct lateral vs posterolateral approach to hemiarthroplasty for femoral neck fractures. *Orthop Traumatol Surg Res* 2016;102(08): 1049–1054
- 36 Zimmerma S, Hawkes WG, Hudson JI, et al. Outcomes of surgical management of total HIP replacement in patients aged 65 years and older: cemented versus cementless femoral components and lateral or anterolateral versus posterior anatomical approach. *J Orthop Res* 2002;20(02):182–191
- 37 Barrett WP, Turner SE, Leopold JP. Prospective randomized study of direct anterior vs postero-lateral approach for total hip arthroplasty. *J Arthroplasty* 2013;28(09):1634–1638
- 38 Zhao HY, Kang PD, Xia YY, Shi XJ, Nie Y, Pei FX. Comparison of Early Functional Recovery After Total Hip Arthroplasty Using a Direct Anterior or Posterolateral Approach: A Randomized Controlled Trial. *J Arthroplasty* 2017;32(11):3421–3428
- 39 Miller LE, Gondusky JS, Bhattacharyya S, Kamath AF, Boettner F, Wright J. Does Surgical Approach Affect Outcomes in Total Hip Arthroplasty Through 90 Days of Follow-Up? A Systematic Review With Meta-Analysis. *J Arthroplasty* 2018;33(04):1296–1302
- 40 Higgins BT, Barlow DR, Heagerty NE, Lin TJ. Anterior vs. posterior approach for total hip arthroplasty, a systematic review and meta-analysis. *J Arthroplasty* 2015;30(03):419–434



- 41 Cheng TE, Wallis JA, Taylor NF, et al. A Prospective Randomized Clinical Trial in Total Hip Arthroplasty-Comparing Early Results Between the Direct Anterior Approach and the Posterior Approach. *J Arthroplasty* 2017;32(03):883–890
- 42 Xia ZN, Xiao K, Zhu W, et al. Risk assessment and management of preoperative venous thromboembolism following femoral neck fracture. *J Orthop Surg Res* 2018;13(01):291
- 43 Zhang W, Zhang PX. [Analysis of prophylactic effect of extended-duration anticoagulant drugs in elderly patients undergoing hip fracture]. *Beijing Da Xue Xue Bao* 2019;51(03):501–504
- 44 Gupta PB, DeMario VM, Amin RM, et al. Patient Blood Management Program Improves Blood Use and Clinical Outcomes in Orthopedic Surgery. *Anesthesiology* 2018;129(06):1082–1091
- 45 Gu WJ, Gu XP, Wu XD, et al. Restrictive Versus Liberal Strategy for Red Blood-Cell Transfusion: A Systematic Review and Meta-Analysis in Orthopaedic Patients. *J Bone Joint Surg Am* 2018;100(08):686–695
- 46 Ftouh S, Morga A, Swift C Guideline Development Group. Management of hip fracture in adults: summary of NICE guidance. *BMJ* 2011;342:d3304
- 47 Lee KJ, Um SH, Kim YH. Postoperative Rehabilitation after Hip Fracture: A Literature Review. *Hip Pelvis* 2020;32(03):125–131
- 48 Resnick B, Beaupre L, McGilton KS, et al. Rehabilitation Interventions for Older Individuals With Cognitive Impairment Post-Hip Fracture: A Systematic Review. *J Am Med Dir Assoc* 2016;17(03):200–205
- 49 Avenell A, Smith TO, Curtain JP, Mak JC, Myint PK. Nutritional supplementation for hip fracture aftercare in older people. *Cochrane Database Syst Rev* 2016;11(11):CD001880
- 50 Malafarina V, Uriz-Otano F, Malafarina C, Martinez JA, Zulet MA. Effectiveness of nutritional supplementation on sarcopenia and recovery in hip fracture patients. A multi-centre randomized trial. *Maturitas* 2017;101:42–50
- 51 Neuerburg C, Förch S, Gleich J, et al. Improved outcome in hip fracture patients in the aging population following co-managed care compared to conventional surgical treatment: a retrospective, dual-center cohort study. *BMC Geriatr* 2019;19(01):330
- 52 Bano G, Dianin M, Biz C, et al. Efficacy of an interdisciplinary pathway in a first level trauma center orthopaedic unit: A prospective study of a cohort of elderly patients with hip fractures. *Arch Gerontol Geriatr* 2020;86:103957
- 53 Kang H, Ha YC, Kim JY, Woo YC, Lee JS, Jang EC. Effectiveness of multimodal pain management after bipolar hemiarthroplasty for hip fracture: a randomized, controlled study. *J Bone Joint Surg Am* 2013;95(04):291–296
- 54 Sharma DK, Sawyer RK, Robertson TS, et al. Elevated Serum 25-Hydroxyvitamin D Levels Are Associated with Improved Bone Formation and Micro-Structural Measures in Elderly Hip Fracture Patients. *J Clin Med* 2019;8(11):1988
- 55 Sprague S, Madden K, Slobogean G, et al. A Missed Opportunity in Bone Health: Vitamin D and Calcium Use in Elderly Femoral Neck Fracture Patients Following Arthroplasty. *Geriatr Orthop Surg Rehabil* 2017;8(04):215–224
- 56 Gómez-Vaquero C, Fábregas-Canales D, Seoane-Mato D, Sánchez-Piedra C, Díaz-González F, Bustabad-Reyes Sen nombre del Grupo de Trabajo del Proyecto EPISER2016 Grupo de Trabajo del Proyecto EPISER2016. Fracture risk assessment in the general population in Spain by FRAX® algorithm. EPISER2016 study. *Med Clin (Barc)* 2020;154(05):163–170
- 57 Akesson K, Marsh D, Mitchell PJ, et al; IOF Fracture Working Group. Capture the Fracture: a Best Practice Framework and global campaign to break the fragility fracture cycle. *Osteoporos Int* 2013;24(08):2135–2152
- 58 Degli Esposti L, Girardi A, Saragoni S, et al; on the behalf of the Study group. Use of antiosteoporotic drugs and calcium/vitamin D in patients with fragility fractures: impact on re-fracture and mortality risk. *Endocrine* 2019;64(02):367–377
- 59 Wang PW, Li YZ, Zhuang HF, et al. Anti-Osteoporosis Medications Associated with Decreased Mortality after Hip Fracture. *Orthop Surg* 2019;11(05):777–783