

Marco Kawamura Demange¹

ABSTRACT

Baker's cysts are located in the posteromedial region of the knee between the medial belly of the gastrocnemius muscle and semimembranosus tendon. In adults, these cysts are related to intra-articular lesions, which may consist of meniscal lesions or arthrosis. In children, these cysts are usually found on physical examination or imaging studies, and they generally do not have any clinical relevance. Ultrasound examination is appropriate for identifying and measuring the popliteal cyst. The main treatment approach

should focus on the joint lesions, and in most cases there is no need to address the cyst directly. Although almost all knee cysts are benign (Baker's cysts and parameniscal cysts), presence of some signs makes it necessary to suspect malignancy: symptoms disproportionate to the size of the cyst, absence of joint damage (e.g. meniscal tears) that might explain the existence of the cyst, unusual cyst topography, bone erosion, cyst size greater than 5 cm and tissue invasion (joint capsule).

Keywords – Knee; Popliteal Cyst; Adult; Child

INTRODUCTION

The Baker's cyst, or popliteal cyst, manifests itself as an increase of volume in the posterior region of the knee. These cysts were described for the first time by Adams in 1840, but were popularized by Baker's description in 1877. In his description, Baker postulated that the formation of this cyst results from a buildup of fluid in the bursa of the semimembranosus tendon, with communication between here and the joint, yet with a one-way flow of fluid in the direction of the cyst, limited by a valve⁽¹⁾. After Baker's description, several papers described popliteal cysts and noted that Baker's cyst corresponds to a cyst located between the medial head of the gastrocnemius muscle and semimembranosus tendon.

Baker's cyst presents bimodal epidemiologic distribution, with peaks in childhood and in adulthood⁽²⁾. Baker's cyst in childhood is rare and generally discovered by chance. There is usually no precedent trauma for the appearance of popliteal cysts in children. In the case of adults, in turn, there is generally an association between these cysts and intra-articular lesions. The most frequent associated pathologies are meniscal le-

sions (lesions of the medial meniscus in 82% of the cases and of lesions of the lateral meniscus in 38%) and osteoarthritis⁽³⁾. Studies with magnetic resonance describe that the prevalence of popliteal cysts is 5% of the adult population, and higher in older patients⁽⁴⁾. Patients with rheumatoid arthritis and patients with gout frequently present popliteal cysts⁽⁵⁾.

From the anatomopathological point of view, it is a ganglion cyst covered by mesothelial cells and fibroblasts. The fluid in its interior is viscous and with a high concentration of fibrin. The interior of the cyst may present lobulations with walls ranging from 2 to 8 mm. In the 1950s, Bickel *et al*⁽⁶⁾ actually classified Baker's cysts in three types, from the anatomopathological point of view, according to wall thickness and cyst content. The clinical relevance of this classification is limited.

The pathogenesis of Baker's cyst is explained by the presence of a connection between the knee joint and a bursa between the gastrocnemius muscle and the semitendinosus tendon, allowing the flow of fluid. There is a valve effect between the cyst and the joint, due to the action of the semitendinosus and gastrocnemius muscles. During flexion the "valve" opens and

1 - Master's degree and Doctor's degree from Universidade de São Paulo; Assistant Physician of the Knee Group of the Institute of Orthopedics and Traumatology of HC/FMUSP.

Mailing address: Rua Ovídio Pires de Campos, 333, 3º andar, Cerqueira Cesar - 05403-010 - São Paulo, SP. Email: demange@usp.br

Study received for publication: 03/03/2011, accepted for publication: 10/19/2011.

The authors declare that there was no conflict of interest in conducting this work

This article is available online in Portuguese and English at the websites: www.rbo.org.br and www.scielo.br/rbort

during extension the “valve” closes due to the tension of these muscles. Moreover, the intra-articular pressure of the knee interferes in the formation and in the filling of the popliteal cysts. The intra-articular pressure during partial knee flexion is negative (-6 mmHg), becoming positive with knee extension (16 mmHg). Hence, these three factors – presence of communication between joint and bursa, “valve” effect and variation of intra-articular pressure in the knee – correspond to the pathophysiologic explanation of the formation of Baker’s cysts⁽²⁾.

CLINICAL PICTURE

Patients with Baker’s cyst may refer to the presence of a mass or growth in the posterior region of the knee. In children, these cysts are asymptomatic, and are mostly found in physical examinations.

In adults, these cysts can cause pain and a feeling of pressure in the posterior region of the knee. The symptoms are more intense when extending the joint or during physical activities.

Most of the time, the clinical complaints are not related to the cyst, but refer to the problem associated with the condition. Therefore, complaints relating to osteoarthritis or to meniscal lesion are more frequent⁽²⁾.

When a Baker’s cyst ruptures, the clinical picture consists of abrupt and intense pain in the posterior region of the knee and of the calf. This picture is often confused with the diagnosis of deep vein thrombosis. In both clinical situations there can be an increase of volume and clubbing of the calf⁽⁷⁾.

In Baker’s cysts of significant volume there can be compression of associated structures and clinical symptoms arising from the latter. This profile is rare, yet should be suspected when there is correlation between compressive symptoms and the location of the cyst⁽⁸⁻¹¹⁾.

For the physical examination, we should assess the patient in prone position and perform knee palpation in extension and in flexion of 90 degrees. We palpate a rounded, mobile mass, with sensation of fluid content and of well-defined edges. The cyst tends to disappear or to decrease with 45 degrees of knee flexion (Foucher’s sign). This test is useful to distinguish Baker’s cysts from fixed, solid masses that do not change position.

IMAGING DIAGNOSIS

Ultrasonography allows us to define the size and location of the Baker’s cyst. Additional subsidiary examination is not usually necessary. Ultrasonography allows us to evaluate the tumor content, and to distinguish cysts with liquid contents from solid masses.

Complementarily, we can perform magnetic resonance imaging, which is especially useful in case of suspicion of lesions associated with the popliteal cyst. In the MR imaging exam, the popliteal cyst presents low-signal intensity in the T1-weighted images and high-signal intensity in the T2-weighted images, due to its fluid content (Figures 1, 2 and 3). Baker’s cyst consists of an ovular, well-defined image of fluid content. Magnetic resonance imaging allows us to differentiate popliteal cysts from parameniscal cysts, since the latter are generally located on the outer edges of the meniscuses (medial or lateral) and present communication with the meniscal lesion⁽¹²⁾.

The radiographic exam of the knee is useful in the diagnosis of osteoarthritis and not of the actual cyst. Arthrography was used as a diagnostic method in the past, demonstrating communication between the joint and the cyst in 30 to 40% of patients. Arthrography is not used as a routine diagnostic method nowadays.

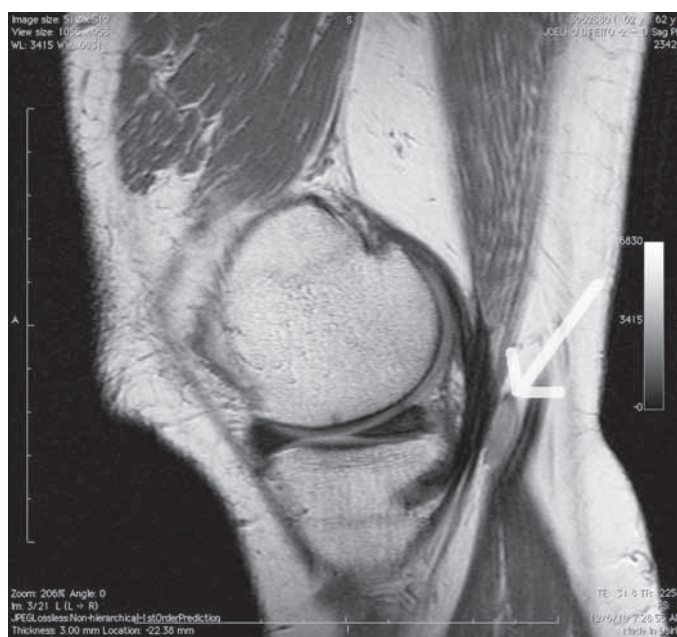


Figure 1 – Sagittal T1-weighted magnetic resonance image of the knee depicts the presence of Baker’s cyst.

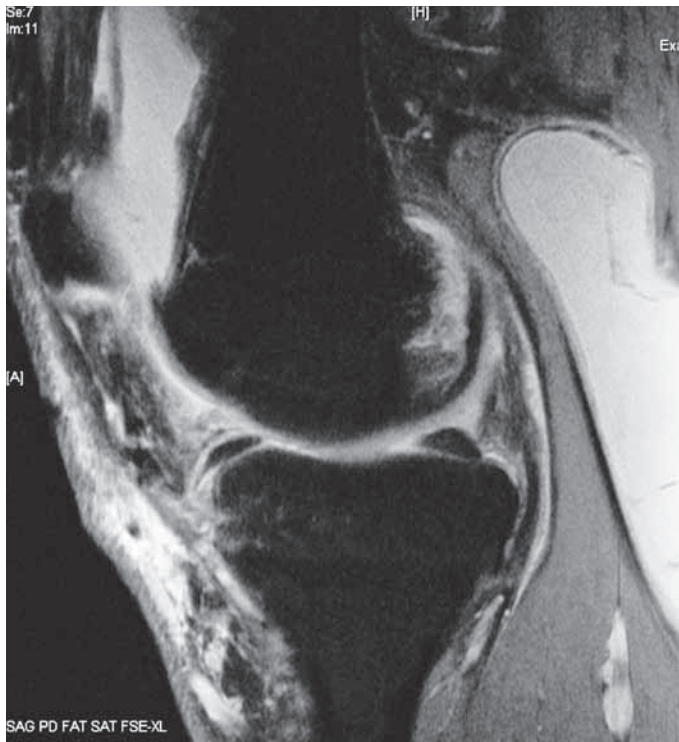


Figure 2 –Sagittal T2-weighted magnetic resonance image of the knee depicts the presence of Baker's cyst.

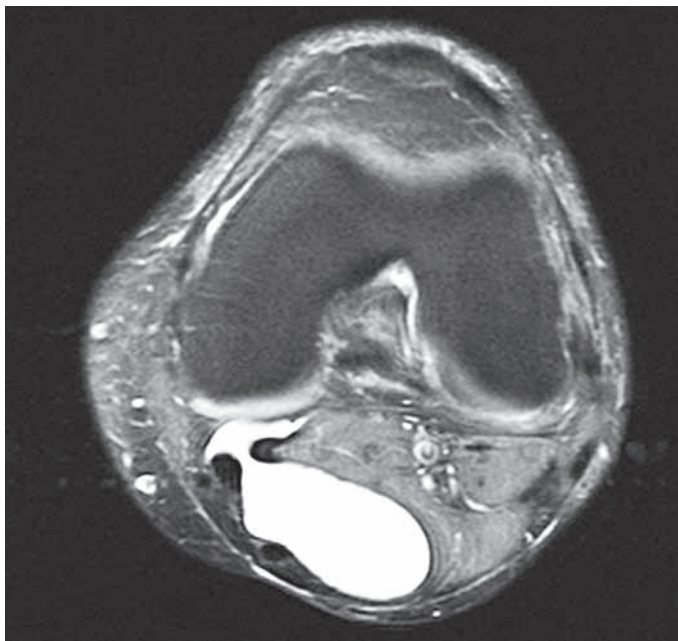


Figure 3 – Axial T2-weighted magnetic resonance image of the knee depicts the presence of Baker's cyst.

TREATMENT

In the vast majority of cases, the popliteal cyst does not require treatment⁽¹³⁾. In childhood it is necessary to explain the condition to the child's parents, in order to assuage their anxiety in relation to the presence of the cyst. It is known that, in spite of surgical treat-

ment, the recurrence of popliteal cysts in children is approximately 40%⁽¹⁴⁾. Moreover, in children treated conservatively, there is partial or total remission of the growth in approximately half of the patients⁽¹³⁾. In children with persistent painful symptoms we indicate surgical excision. In this case, the procedure is carried out with the patient in prone position, through a transverse access route in the popliteal fold, following the skin lines, dissecting around the cyst. After we identified the base of the cyst, we performed the excision and closed the residual orifice with circular stitches using non-absorbable thread⁽¹⁴⁾.

Surgical excision is not usually required in the treatment of Baker's cysts in adults. The surgical treatment of Baker's cysts calls for prioritization of the approach to the associated intra-articular lesion. The isolated resection of Baker's cysts generally leads to recurrence of the growth. On the same line, the aspiration and local injection of corticosteroids consists of a temporary measure, as it presents a high rate of recurrence of the cyst.

Thus, when we opt for the conservative treatment of the associated lesion, Baker's cyst is only observed. In these cases, it is also possible to perform aspiration and infiltration of corticosteroids as a relief measure. The treatment of the associated lesion is usually performed by arthroscopy, since many patients with popliteal cysts present meniscal lesions. In most cases, we perform only the treatment of the intra-articular lesion, as Baker's cyst frequently presents reduction of volume or remission after the arthroscopic procedure. In selected cases, when a Baker's cyst does not recede and continues to cause discomfort, we consider open resection. In this case, we create a local route of access, performing dissection of the cyst and removal from its base. We place a closing suture at the base to prevent its recurrence. Some authors have described the possibility of executing the approach to the Baker's cyst by arthroscopic route⁽¹⁵⁾.

In relation to parameniscal cysts, the treatment should also emphasize the meniscal lesion. In most cases, the isolated treatment of the meniscal lesion is sufficient. During the arthroscopy procedure, it is possible to use the probe, arthroscopic rasps or the shaver blade to break open the parameniscal cyst^(16,17). When the cyst cannot be decompressed arthroscopically, surgical excision can be considered when the presence of the cyst consists of an important complaint of the patient⁽¹⁷⁾.

DIFFERENTIAL DIAGNOSES

Parameniscal cysts generally appear on the outer edge of the menisci and communicate with meniscal lesions.

There are malignant tumors that can appear in cystic form, comprising differential diagnoses to Baker's cysts. The most common are the fibrosarcoma, synovial sarcoma and malignant fibrous histiocytoma. We suggest sending all resected synovial cysts for anatomopathological examination. The level of suspicion of malignant tumors should be stronger when the cyst is not in its typical location (between the medial gastrocnemius and the semimembranosus tendon), when there is recurrence of the cyst in spite of surgical treatment, in the case of fast growth of the tumor or disproportion between the lesion size and the symptoms⁽¹⁸⁾. Benign cysts do not present tissue invasion, having well-defined outlines, dissecting between the musculotendinous structures.

The differentiation between solid masses and cystic masses can be performed using transillumination. Nerve sheath tumors are rare and can present positive Tinel's sign upon local percussion. In imaging examinations, the presence of calcification or of areas of bone erosion arouses suspicion of malignant lesions. Moreover, the heterogeneous aspect of the cyst content and the absence of intra-articular lesions that justify the presence of the cysts in adults should

alert the orthopedist⁽¹⁹⁾. Anyhow, they are rare and infrequent lesions.

Aneurysms of the popliteal region can be differentiated by palpation and auscultation. Another pathology, cystic adventitial disease of the popliteal artery, can cause pain and claudication. It generally affects young adults, but can affect elderly patients with chronic vascular problems. It ideally requires early diagnosis as it can evolve to occlusion of popliteal artery. The diagnosis can be performed with the use of resonance imaging of the knee with contrast^(20,21).

In ruptured Baker's cysts, the differential diagnosis is performed with thrombophlebitis and with deep vein thrombosis⁽⁸⁾. In the case of thrombophlebitis, the differential diagnosis can be performed by palpation of a rope that corresponds to the thrombosed vein⁽²²⁾. In the case of deep vein thrombosis, we should appreciate the importance of the clinical history and, when necessary, use lower extremity venous Doppler⁽²³⁾.

FINAL CONSIDERATIONS

Baker's cyst consists of a frequent finding, and is highly prevalent in adult patients with meniscal lesions or arthrosis of the knee. The treatment should generally target intra-articular pathology. The cyst itself does not usually require treatment and can recede after treatment of the associated lesion.

REFERENCES

- Wigley RD. Popliteal cysts: variations on a theme of Baker. *Semin Arthritis Rheum.* 1982;12(1):1-10.
- Handy JR. Popliteal cysts in adults: a review. *Semin Arthritis Rheum.* 2001;31(2):108-18.
- Kornaat PR, Bloem JL, Ceulemans RY, Riyazi N, Rosendaal FR, Nelissen RG, *et al.* Osteoarthritis of the knee: association between clinical features and MR imaging findings. *Radiology.* 2006;239(3):811-7.
- Fielding JR, Franklin PD, Kustan J. Popliteal cysts: a reassessment using magnetic resonance imaging. *Skeletal Radiol.* 1991;20(6):433-5.
- Liao ST, Chiou CS, Chang CC. Pathology associated to the Baker's cysts: a musculoskeletal ultrasound study. *Clin Rheumatol.* 2010;29(9):1043-7.
- Bickel WH, Burlison RJ, Dahlin DC. Popliteal cyst; a clinicopathological survey. *J Bone Joint Surg Am.* 1956;38(6):1265-74.
- Arumilli BR, Lenin Babu V, Paul AS. Painful swollen leg—think beyond deep vein thrombosis or Baker's cyst. *World J Surg Oncol.* 2008;6:6.
- Kabeya Y, Tomita M, Katsuki T, Meguro S, Atsumi Y. Pseudothrombophlebitis. *Intern Med.* 2009;48(21):1927.
- Shiver SA, Blaivas M. Acute lower extremity pain in an adult patient secondary to bilateral popliteal cysts. *J Emerg Med.* 9. Shiver SA, Blaivas M. Acute lower extremity pain in an adult patient secondary to bilateral popliteal cysts. *J Emerg Med.* 9. Shiver SA, Blaivas M. Acute lower extremity pain in an adult patient secondary to bilateral popliteal cysts. *J Emerg Med.*
- Dressler F, Wermes C, Schirg E, Thon A. Popliteal venous thrombosis in juvenile arthritis with Baker cysts: report of 3 cases. *Pediatr Rheumatol Online J.* 2008;6:12.
- Ji JH, Shafi M, Kim WY, Park SH, Cheon JO. Compressive neuropathy of the tibial nerve and peroneal nerve by a Baker's cyst: case report. *Knee.* 2007;14(3):249-52.
- Papp DF, Khanna AJ, McCarthy EF, Carrino JA, Farber AJ, Frassica FJ. Magnetic resonance imaging of soft-tissue tumors: determinate and indeterminate lesions. *J Bone Joint Surg Am.* 2007;89(Suppl 3):103-15.
- Van Rhijn LW, Jansen EJ, Pruijs HE. Long-term follow-up of conservatively treated popliteal cysts in children. *J Pediatr Orthop B.* 2000;9(1):62-4.
- Chen JC, Lu CC, Lu YM, Chen CH, Fu YC, Hunag PJ, *et al.* A modified surgical method for treating Baker's cyst in children. *Knee.* 2008;15(1):9-14.
- Ahn JH, Lee SH, Yoo JC, Chang MJ, Park YS. Arthroscopic treatment of popliteal cysts: clinical and magnetic resonance imaging results. *Arthroscopy.* 2010;26(10):1340-7.
- Goldstein R, Andrade Júnior A. Lesão cística de menisco: abordagem por via artroscópica. *Rev Bras Ortop.* 1998;33(5):371-6.
- Greis PE, Holmstrom MC, Bardana DD, Burks RT. Meniscal injury: II. Management. *J Am Acad Orthop Surg.* 2002;10(3):177-87.
- Damron TA, Sim FH. Soft-Tissue Tumors About the Knee. *J Am Acad Orthop Surg.* 1997;5(3):141-52.
- Mountney J, Thomas NP. When is a meniscal cyst not a meniscal cyst? *Knee.* 2004;11(2):133-6.
- Chung CB, Isaza IL, Angulo M, Boucher R, Hughes T. MR arthrography of the knee: how, why, when. *Radiol Clin North Am.* 2005;43(4):733-46.
- Cassar K, Engeset J. Cystic adventitial disease: a trap for the unwary. *Eur J Vasc Endovasc Surg.* 2005;29(1):93-6.
- Gordon GV, Edell S, Brogadir SP, Schumacher HR, Schimmer BM, Dalinka M. Baker's cysts and true thrombophlebitis. Report of two cases and review of the literature. *Arch Intern Med.* 1979;139(1):40-2.
- Useche JN, de Castro AM, Galvis GE, Mantilla RA, Ariza A. Use of US in the evaluation of patients with symptoms of deep venous thrombosis of the lower extremities. *Radiographics.* 2008;28(6):1785-97.