



Original Article

Intra-focal reduction and percutaneous fixation of neck fractures of the fifth metacarpal: description of surgical technique^{☆,☆☆}

Gustavo Pacheco Martins Ferreira^{a,*}, Paulo Randal Pires^a, André Lopes Portugal^b,
Henriquo de Gouvêa Schneiter^c

^a Hospital Maria Amélia Lins, Belo Horizonte, MG, Brazil

^b Hospital Risoleta Tolentino Neves, Belo Horizonte, MG, Brazil

^c Hospital Eládio Lasserre, Cajazeiras, Salvador, BA, Brazil

ARTICLE INFO

Article history:

Received 11 December 2012

Accepted 7 May 2013

Available online 27 March 2014

Keywords:

Metacarpal
Bone fractures
Upper limb
Bone Wires

ABSTRACT

Objective: to demonstrate a surgical technique for treating neck fractures of the fifth metacarpal, by means of reduction through intra-focal manipulation and percutaneous fixation using Kirschner wires, with the aims of making it easier to achieve and maintain the reduction during the operation and enabling reduction of these fractures even if a fibrous callus has formed.

Methods: a series of ten patients with neck fractures of the fifth metacarpal presenting palmar angles greater than 30° underwent the surgical technique described, as examples, and their results were evaluated through postoperative radiographs and clinical examinations.

Results: all the patients achieved reductions that were close to anatomical and evolved to consolidation of the fracture in the position obtained.

Conclusion: the surgical technique described is effective, easy to carry out, minimally invasive and low-cost, thereby enabling adequate clinical and radiographic reduction, even in subacute fractures already presenting a fibrous callus.

© 2014 Sociedade Brasileira de Ortopedia e Traumatologia. Published by Elsevier Editora Ltda. All rights reserved.

Redução intrafocal e fixação percutânea das fraturas do colo do quinto metacarpo – descrição de técnica cirúrgica

RESUMO

Objetivo: demonstrar uma técnica cirúrgica para o tratamento das fraturas do colo do quinto metacarpo por meio de redução por manipulação intrafocal e fixação percutânea com fios de Kirschner, visando a facilitar a obtenção e manutenção da redução no intraoperatório e possibilitar a redução dessas fraturas, ainda que com calo fibroso formado.

Palavras-chave:

Metacarpo
Fraturas ósseas
Membro superior
Fios ortopédicos

[☆] Please cite this article as: Ferreira GPM, Pires PR, Portugal AL, Schneiter, HG. Redução intrafocal e fixação percutânea das fraturas do colo do quinto metacarpo – descrição de técnica cirúrgica. Rev Bras Ortop. 2014;49:116-120.

^{☆☆} Work performed at Hospital Maria Amélia Lins, Belo Horizonte, MG, Brazil.

* Corresponding author.

E-mail: gustavopmf@yahoo.com.br (G.P.M. Ferreira).

2255-4971/\$ – see front matter © 2014 Sociedade Brasileira de Ortopedia e Traumatologia. Published by Elsevier Editora Ltda. All rights reserved.
<http://dx.doi.org/10.1016/j.rboe.2014.03.013>

Métodos: dez pacientes portadores de fratura do colo do quinto metacarpo com angulação palmar superior a 30° foram submetidos, como exemplos, à técnica cirúrgica descrita. Os resultados foram avaliados por meio de radiografias e exame clínico pós-operatório.

Resultados: todos os pacientes obtiveram redução próxima da anatômica e evoluíram para consolidação da fratura na posição obtida.

Conclusão: a técnica cirúrgica descrita é eficaz, de simples execução, minimamente invasiva, de baixo custo e permite redução clínica e radiográfica adequadas, mesmo em fraturas subagudas com calo fibroso formado.

© 2014 Sociedade Brasileira de Ortopedia e Traumatologia. Publicado por Elsevier Editora Ltda. Todos os direitos reservados.

Introduction

Fractures of the neck of the fifth metacarpal generally result from an axial impact mechanism on the head of the metacarpal with the fist closed. For this reason, they are known as boxer's fractures, even though they only rarely occur among professional pugilists.¹⁻⁴ These fractures generally present palmar angulation because of the deforming force of the interosseous muscles and comminution of the volar cortex, with consequent instability.⁴ A sagittal angle greater than 30° or shortening of more than 5 mm is associated with alteration of the biomechanics of the flexor system and may lead to dysfunction. Presence of rotational deviation greater than 5° may lead to superimposition of the affected ray, with obstruction of the adjacent fingers.^{1,2,4,5}

In 1938, Jahss⁶ described a maneuver for reducing fractures of the metacarpals with palmar displacement that became established both for conservative treatment and for maintaining the reduction during surgical fixation. However, this maneuver requires an assistant to maintain the reduction during the operation, which also adds difficulty to percutaneous insertion of the Kirschner wires under radioscopy because the assistant's and the patient's hands overlap and also because the reduction often becomes lost if there is any movement of the hand. Furthermore, the maneuver is incapable of reducing subacute fractures with a fibrous callus already formed, which typically occurs after 7-10 days.

In 1987, Kapandji⁷ described a new technique for reduction and intrafocal fixation of fractures of the distal radius. Because of the success of this technique, it became established and was extrapolated for treating several types of fracture. This served as motivation for application to fractures of the neck of the fifth metacarpal.

In the present study, a technique for intrafocal reduction and percutaneous fixation with Kirschner wires for treating fractures of the neck of the fifth metacarpal is described, the radiographic results obtained are presented and the advantages of this technique are discussed.

Materials and methods

Between September and October 2012, ten patients with neck fractures of the fifth metacarpal were treated surgically using the technique described, and the radiographic results were

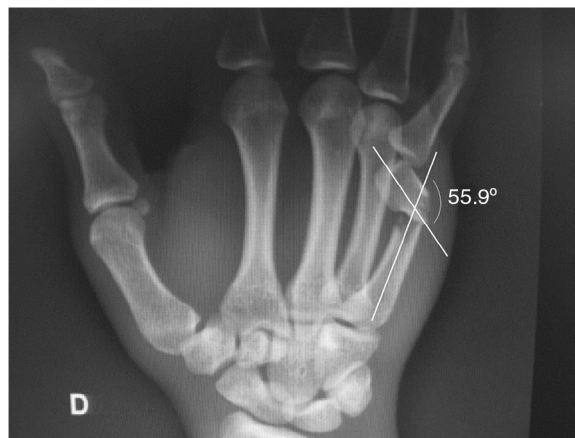

Fig. 1 – Measurement of fracture displacement angle.

recorded to demonstrate the efficacy of the technique. The other characteristics of the patients are described in [Table 1](#).

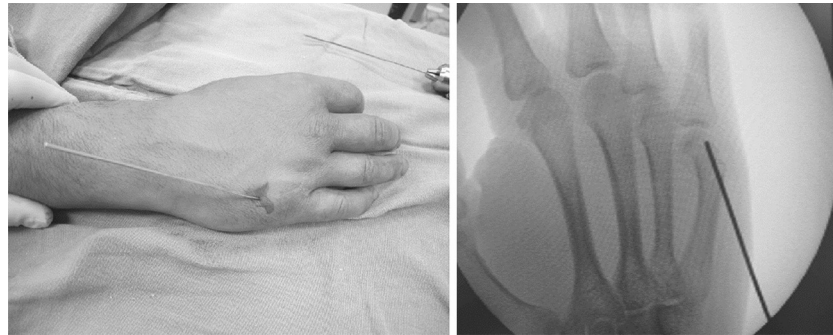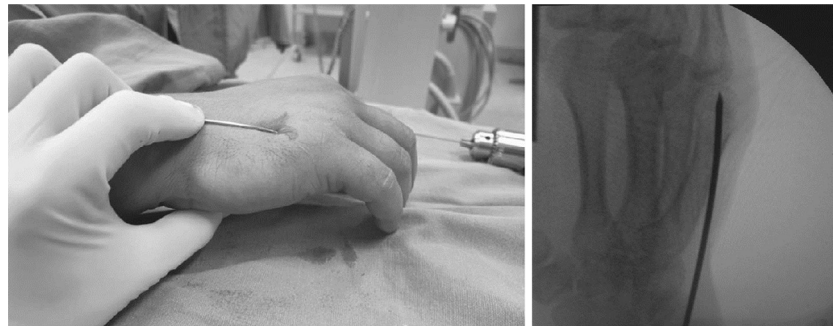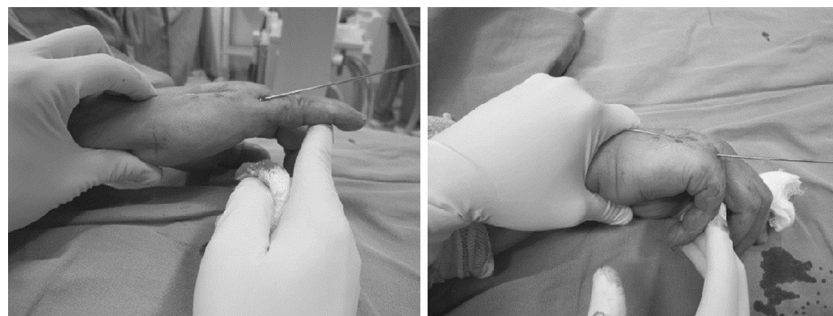All the patients were operated by a single professional hand surgeon. The inclusion criteria were as follows: fracture with volar displacement in the sagittal plane greater than 30° and/or rotational displacement greater than 5° on clinical examination; and length of evolution after the trauma of between 1 and 21 days. The exclusion criteria were skeletal immaturity, exposed fracture, previous fracturing of the fifth metacarpal and fracturing extending to the joint. The preoperative and postoperative displacements of the fracture were measured on radiographs in posteroanterior and oblique (semipronated at 30°) views of the affected hand, by means of a standard method for determination of the anatomical axis. The angles were measured using the Adobe Photoshop CS3 Extended 10.0 software ([Fig. 1](#)).

Description of the technique

The patient was positioned in dorsal decubitus with the fractured limb on a radiotransparent table, and under adequate anesthesia by means of brachial plexus block. Under fluoroscopy, the intrafocal wire was inserted manually in the dorsopalmar direction until reaching the subchondral region of the distal fragment of the fifth metatarsal. Its position was proven by means of radioscopy ([Fig. 2](#)). The wire was positioned in parallel to and juxtaposed with the diaphysis of the metatarsal, with consequent reduction of the fracture in the sagittal and coronal planes, given that the diaphyses of the

Table 1 – Patients' characteristics.

Patient	Sex	Age	Palmar angulation	Rotation	Length of evolution (days)
1	M	27	56.9	No	15
2	M	36	32.8	No	20
3	M	18	42.1	No	10
4	M	19	55.9	No	15
5	M	19	42.8	No	17
6	M	18	64.1	No	5
7	M	30	59.6	No	21
8	M	19	49.4	No	19
9	M	19	50.2	No	14
10	M	22	49.2	No	9
		Mean = 22.7	Mean = 50.3°		Mean = 14.5

**Fig. 2 – Introduction of the intrafocal wire. Position confirmed by means of radioscopy.****Fig. 3 – Reduction of the fracture.****Fig. 4 – Mobility of the metacarpophalangeal joint without loss of reduction.**

metacarpals present subcutaneous locations on the dorsum of the hand (Fig. 3). Maintaining the wire in this position enabled metacarpophalangeal joint mobility without loss of the reduction, which facilitated evaluation of the possible rotational

deformity and its correction. It also facilitated introduction of two 1.5 mm Kirschner wires in the retrograde direction, on each side of the metacarpal head, without locking the joint with the osteosynthesis material (Fig. 4). The wires were

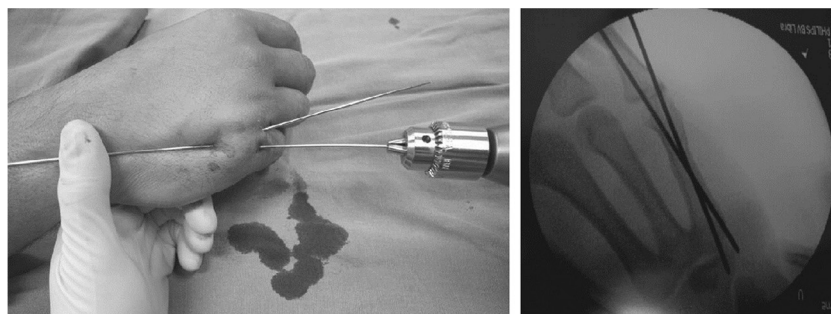


Fig. 5 – Fixation of the fracture.

anchored at the base of the metacarpal for better stabilization of the fixation (Fig. 5) and were left protruding through the skin with the points folded over.

After fixation, radiographs were produced in posteroanterior, lateral and oblique (semipronated at 30°) views in order to measure the angles obtained. The patients were then immobilized by means of a short ulnar plaster cast splint that covered the fourth and fifth fingers in intrinsic-plus position. They were discharged from hospital after recovery from anesthesia, with a prescription for analgesics to use at home. The Kirschner wires were removed as an outpatient procedure in the fourth week and the patients were then referred for hand therapy. In the sixth postoperative week, new radiographs were produced in order to measure the angles and assess the radiographic consolidation.

Results

All the patients achieved angulation of less than 30° on the oblique radiograph semipronated at 30° in the immediate postoperative period. None of the cases presented residual angulation in the coronal plane, malrotation or shortening in the clinical or radiographic examination. The mean length of follow-up was 184.9 days (minimum of 169) (Table 2). In none of the cases was conversion to open surgery necessary.

In all cases, the radiograph obtained in the sixth postoperative week showed radiographic consolidation without the loss of the reduction that was initially obtained. No complications such as hyper-reduction, translational displacement, increase

in the fracture line, extensor injury or infection on the paths of the Kirschner wires were observed.

Discussion

Fractures of the neck of the fifth metacarpal are among the ones most commonly treated by traumatologists and hand surgeons. Although there is no consensus regarding what the acceptable volar angulation of these fractures is, and even though some authors have accepted angulation of up to 70° in the sagittal plane in sedentary patients, there is evidence of variable degrees of dysfunction at angulations greater than 30°, albeit that in some cases the functional deficit is subjective and poorly assessed by the functional questionnaires currently in use.^{1,2,4,5} There is no doubt that many of these fractures can be treated conservatively. However, reduction as close as possible to the anatomical position should be sought, especially during surgical treatment, but minimizing the additional trauma to the adjacent soft tissues and their complications.

There is no consensus regarding the best way to measure the angles on radiographs. Some studies have shown low to moderate degrees of intra- and inter-observer concordance for methods of determining the anatomical axis (medullary canal) and the lines tangential to the dorsal cortical bone.^{1,3,8} Anatomical observations have shown that the metacarpals are not rectilinear, but present wide-radius curvature along their axis in the sagittal plane, with volar concavity, and a normal angle of around 15° between the neck and the diaphysis. Thus,

Table 2 – Radiographic results obtained.

Patient	Preoperative palmar angulation	Postoperative palmar angulation	Degree of correction obtained (%)	Length of follow-up (days)
1	56.9	8.7	84.7	201
2	32.8	16.3	50.3	199
3	42.1	12.7	69.8	170
4	55.9	0	100	178
5	42.8	0	100	188
6	64.1	4.9	92.4	169
7	59.6	0	100	189
8	49.4	6.9	86	171
9	50.2	3.3	93.4	194
10	49.2	17	65.4	190
	Mean = 50.3°	Mean = 6.9°	Mean = 84.2	Mean = 184.9

measurement by means of lines tangential to the dorsal cortical bone tends to overestimate the displacement angle and becomes particularly difficult in fractures that are more distal, because of the elliptical shape of the metacarpal head, and in lateral projection, because of the overlapping of images from the other metacarpals.⁸

Measurement of the angle from the anatomical axis in oblique projection, semipronated at 30°, was chosen because of the ease of identifying the medullary canal of the proximal fragment of the metacarpal and better evaluation of the fracture line, without overlapping of images from the other metacarpals, which enables measurements that are more reproducible. Oblique view tend to underestimate the real angle of the fracture, but it is known that the maximum difference is 4° in the oblique projection at 30° in relation to the absolute profile.⁹

The maneuver described by Jahss in 1938 was destined for conservative treatment of these fractures but, despite promoting satisfactory reduction in acute cases, these unstable fractures almost invariably consolidate with some degree of loss of the reduction that was initially obtained.^{1,4,6,8} During the surgical procedure, we also observed that the reduction obtained through the maneuver was difficult to maintain because it tended to become lost through movement of the patient's hand in the operating field. An assistant was needed in order to perform the maneuver and maintain the position throughout the fixation, with the inconvenience of overlapping of the images of the patient's hand and the assistant's hand in the radioscopy, as well as the exposure of the assistant's hands to radiation. Lastly, in cases that have evolved for more than 7–10 days, either in patients who have undergone an attempt to provide conservative treatment and may have evolved to loss of the reduction, or in cases of delayed surgical treatment, the maneuver is not capable of reducing the fracture. In such cases, open reduction and fixation with miniplates and screws or with Kirschner wires will be necessary, i.e. surgery of larger scale, higher cost and greater potential for complications, particularly adhesions of the extensor tendons and joint contractures that lead to loss of movement.

The technique described in the present study is easy to perform and can even be done without an assistant. It enables adequate fracture reduction, independent of the degree of displacement in the sagittal and coronal planes. In cases that have evolved for 7–21 days, reduction is still possible because of the leverage force that is applied directly to the distal fragment, and the principles and advantages of percutaneous surgery are maintained. The surgeon's hands can be kept out of the irradiation band while obtaining intraoperative radioscopic images, without loss of reduction, thereby minimizing the exposure to radiation.

We only used Kirschner wires as the implant: these are widely available and have a low cost. We chose to perform fixation using crossed wires in a retrograde manner, with an entry point in the extra-articular part of the metacarpal head, so as not to block movement. However, the same reduction technique can be used for fixation with longitudinal wires (intramedullary) or transverse wires (anchored in the fourth metacarpal), as described by Gallanakis et al.¹⁰ So far, there is no definitive evidence to show that one method is better than the others.¹⁻⁴

The aim of this study was to give examples and demonstrate the surgical technique, and for this reason, the sample was limited to ten patients. We believe that the long-term results would be equivalent to those from traditional surgical treatment in acute cases, since the additional trauma is negligible and the postoperative approach is the same. Subacute cases without the possibility of reduction through a closed maneuver may benefit from intrafocal reduction because of the lower aggressiveness and morbidity of the procedure, in relation to open reduction. New studies will be necessary to verify possible changes in the functional results.

Conclusion

The surgical technique of intrafocal manipulation and percutaneous fixation described here for treating neck fractures of the fifth metacarpal is easy to perform and enables clinical satisfactory clinical and radiographic reduction even for subacute fractures with a fibrous callus already formed. It is minimally invasive, has a low cost and becomes an option for treating these fractures.

Conflicts of interest

The authors declare no conflicts of interest.

REFERENCES

1. Beredjikian PK. Small finger metacarpal neck fractures. *J Hand Surg Am.* 2009;34(8):1524–6.
2. Hofmeister EP, Kim J, Shin AY. Comparison of 2 methods of immobilization of fifth metacarpal neck fractures: a prospective randomized study. *J Hand Surg Am.* 2008;33(8):1362–8.
3. Soong M, Got C, Katarincic J. Ring and little finger metacarpal fractures: mechanisms, locations, and radiographic parameters. *J Hand Surg Am.* 2010;35(8):1256–9.
4. Freeland AE, Geissler WB, Weiss AP. Surgical treatment of common displaced and unstable fractures of the hand. *Instr Course Lect.* 2002;51:185–201.
5. Meunier MJ, Hentzen E, Ryan M, Shin AY, Lieber RL. Predicted effects of metacarpal shortening on interosseous muscle function. *J Hand Surg Am.* 2004;29(4):689–93.
6. Jahss SA. Fractures of the metacarpals – a new method of reduction and immobilization. *J Bone Joint Surg Am.* 1938;20:178–86.
7. Kapanji A. Focal pinning of radial distal fractures. *Cahier Chirurg.* 1987;63:258.
8. Leung YL, Beredjikian PK, Monaghan BA, Bozontka DJ. Radiographic assessment of small finger metacarpal neck fractures. *J Hand Surg Am.* 2002;27(3):443–8.
9. Costa AC, Fonseca GM, Ribeiro AG, Gonzales DH, Fonseca Filho JM, Chakkour I. Qual o ângulo real do desvio da fratura do colo do metacarpiano nas incidências oblíquas? Estudo radiográfico. [Tema Livre apresentado no 31º Congresso Brasileiro de Cirurgia da Mão, 2011]. Santa Casa de São Paulo; 2011.
10. Galanakis I, Aligizakis A, Katonis P, Papadokostakis G, Stergiopoulos K, Hadjipavlou A. Treatment of closed unstable metacarpal fractures using percutaneous transverse fixation with Kirschner wires. *J Trauma.* 2003;55(3):509–13.