



Original Article

Analysis on the risk of contralateral proximal femoral epiphyseal slippage using the modified Oxford score[☆]



Jamil Faissal Soni*, Weverley Rubele Valenza*, Wellington Keity Ueda,
Gisele Cristine Schelle, Anna Carolina Pavelec Costa, Fernando Ferraz Faria

Hospital Universitário Cajuru, Pontifícia Universidade Católica do Paraná (PUC-PR), Curitiba, PR, Brazil

ARTICLE INFO

Article history:

Received 20 July 2014

Accepted 1 September 2014

Available online 9 September 2015

Keywords:

Dislocated epiphysis/pathology

Dislocated epiphysis/surgery

Dislocated epiphysis/radiography

ABSTRACT

Objective: To determine the application of the modified Oxford score among patients with proximal femoral epiphyseal slippage (PFES) as an aid to indicating prophylactic surgical treatment on the contralateral hip.

Methods: Retrospective analysis on the medical files of patients attended at the institution where the authors work. From these, patients attended between 2008 and 2011 who presented unilateral PFES and were followed up for a minimum of two years were selected. Patients were excluded if they presented endocrine disease, metabolic disease, Down syndrome or radiographs that were inadequate for determining the modified Oxford score. The initial radiographs received scores ranging from 16 to 26. Statistical analysis was used to determine whether the scoring was predictive of future development of contralateral slippage.

Results: Among the 15 patients with unilateral PFES that were selected, five (33.3%) evolved with contralateral slippage. The patients were divided into two groups. Four patients were considered to present risk and three of them developed contralateral slippage. In the group that was considered not to present risk, there were 11 patients and two of these evolved with contralateral slippage. Thus, there was a tendency for the patients in the group that developed the disease to differ from the group that did not develop it, in relation to the risk classification.

Conclusion: Although application of the modified Oxford score was not statistically significant in our sample, we noted a tendency toward contralateral slippage among hips with low scores.

© 2014 Sociedade Brasileira de Ortopedia e Traumatologia. Published by Elsevier Editora Ltda. All rights reserved.

[☆] Work performed in the Pediatric Orthopedics Group, Hospital Universitário Cajuru, Curitiba, PR, Brazil.

* Corresponding authors.

E-mails: jamilsoni@hotmail.com (J.F. Soni), weverleyvalenza@yahoo.com (W.R. Valenza).

<http://dx.doi.org/10.1016/j.rboe.2015.08.016>

2255-4971/© 2014 Sociedade Brasileira de Ortopedia e Traumatologia. Published by Elsevier Editora Ltda. All rights reserved.

Análise do risco do escorregamento epifisário femoral proximal contralateral pelo escore de Oxford modificado

R E S U M O

Palavras-chave:

Epifise deslocada/patologia
Epifise deslocada/cirurgia
Epifise deslocada/radiografia

Objetivo: Determinar a aplicação do escore de Oxford modificado em pacientes com escorregamento epifisário femoral proximal (EEFP) no auxílio da indicação do tratamento cirúrgico profilático dos quadris contralaterais.

Métodos: Análise retrospectiva dos prontuários dos pacientes atendidos na instituição na qual os autores trabalham. Foram selecionados aqueles com um tempo de seguimento mínimo de dois anos, atendidos de 2008 até 2011, que apresentaram EEFP unilateral. Os critérios de exclusão foram pacientes com doença endócrina ou metabólica, síndrome de Down e aqueles com radiografias inadequadas para determinar a pontuação no escore de Oxford modificado. As radiografias iniciais receberam uma pontuação que varia de 16 a 26. A análise estatística foi usada para determinar se a pontuação foi preditiva do desenvolvimento futuro de deslizamento contralateral.

Resultados: Dos 15 pacientes selecionados com EEFP unilateral, cinco (33,3%) evoluíram para o escorregamento contralateral. Os pacientes foram divididos em dois grupos, quatro pacientes foram considerados de risco e desses três desenvolveram o escorregamento contralateral. No grupo sem risco havia 11 pacientes, dois evoluíram para o escorregamento contralateral. Nota-se assim uma tendência de que pacientes do grupo que desenvolveu a doença difiram do grupo que não desenvolveu em relação à classificação de risco.

Conclusão: Apesar de na nossa amostra a aplicação do escore de Oxford modificado não ter sido estatisticamente significativa, notamos uma tendência para o escorregamento contralateral nos quadris com escore baixo.

© 2014 Sociedade Brasileira de Ortopedia e Traumatologia. Publicado por Elsevier Editora Ltda. Todos os direitos reservados.

Introduction

Proximal femoral epiphyseal slippage is a disease that mainly affects the hypertrophic zone of the growth plate cartilage. It affects the prepubescent and pubescent population at an incidence of 0.2–10 in every 100,000 adolescents. It occurs more frequently in boys and its commonest clinical manifestation is pain in the inguinal region and/or knee, associated with limitation of the flexion and internal rotation movements of the hip.^{1,2}

Involvement of the contralateral side (bilaterality) is observed in 20–40% of the patients, and in 90% of the cases, further slippage occurs within 12–18 months after the initial manifestation.^{3,4}

The true etiology of this illness remains unknown, although geographical, racial and seasonal epidemiological data suggest that environmental and genetic factors may influence its development.^{2,5} Important characteristics such as an accelerated growth spurt, obesity and hormonal disorders have been recognized as risk factors.^{6–9}

The relatively high risk of developing contralateral slippage has led many authors to recommend prophylactic fixation of the hip, even if there are no symptoms, in an attempt to preserve its anatomy.¹⁰

However, routine prophylactic fixation subjects a large number of patients to unnecessary surgery, given that 60–75% of the individuals who present unilateral slippage will never develop this pathological condition contralaterally.^{11,12} Moreover, prophylactic surgery may predispose toward certain

complications, such as: infection, implant breakage, avascular necrosis, chondrolysis or subtrochanteric fracturing of the femur.^{13,14}

The objective of the present study was to retrospectively evaluate the applicability of the modified Oxford score for predicting occurrences of contralateral slippage in patients with unilateral proximal femoral epiphyseal slippage.

Materials and methods

This was an observational cross-sectional retrospective study in which the medical records and radiographs of all patients with a diagnosis of unilateral proximal femoral epiphyseal slippage who were attended and treated by the pediatric orthopedics group of our institution between January 2008 and December 2011 were reviewed. From this review, 31 patients were selected and, among these, those who presented proven metabolic or endocrine disease, Down syndrome or bilateral proximal femoral epiphyseal slippage at the time when they were first seen, and those with follow-ups shorter than 24 months, were excluded. In this manner, 15 patients presenting the inclusion criteria of unilateral proximal femoral epiphyseal slippage and at least two years of follow-up were finally selected.

All the radiographs were evaluated using the modified Oxford score as described by Stasikelis et al.¹⁵ (Fig. 1 and Table 1). This method analyzes three consecutive stages of maturation for five of the characteristics described in the original Oxford method: the ilium, triradiate cartilage, femoral

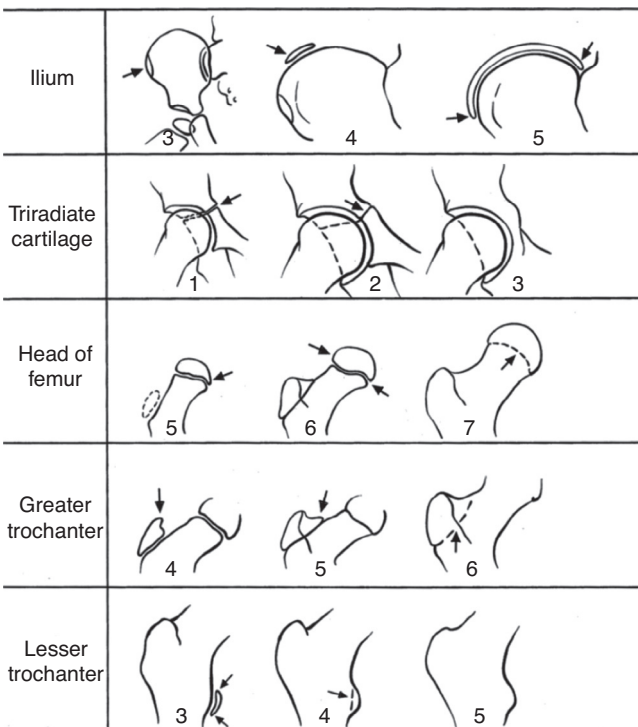
Table 1 – Modified Oxford score among the patients.

	Sex	Age	Initial side	Secondary side	I	TC	FE	GT	LT	Total
1	M	10	L	R	3	1	5	5	3	17
2	M	10	L	R	3	1	5	5	4	18
3	M	11	L	R	3	1	6	5	4	19
4	M	14	R	L	3	1	6	6	4	20
5	F	11	L	R	3	1	5	5	4	18
6	F	11	L	R	3	1	6	4	4	18
7	M	14	L	R	5	2	7	5	4	23
8	M	14	L	R	5	3	6	5	4	23
9	F	11	L	R	4	2	7	5	4	22
10	M	13	L	R	5	6	6	5	4	26
11	F	13	R	L	4	3	7	5	4	23
12	M	15	R	L	5	3	6	5	4	23
13	M	11	L	R	3	1	6	6	3	19
14	F	13	L	R	5	3	7	6	5	26
15	F	12	L	R	3	2	6	5	4	20

I, ilium; TC, triradiate cartilage; FE, femoral epiphysis; GT, greater trochanter; LT, lesser trochanter.

epiphysis, greater trochanter and lesser trochanter. The total score is determined from summing the scores of each item, and it can range from 16 to 26.

This study was approved by the research ethics committee under the number 13090913.9.0000.0020.



Source: Popejoy D, Emara K, Birch J. Prediction of contralateral slipped capital femoral epiphysis using the

Fig. 1 – Modified Oxford score.

Source: Popejoy D, Emara K, Birch J. Prediction of contralateral slipped capital femoral epiphysis using the modified Oxford bone age score. *J Pediatr Orthop.* 2012;32(3):290-4.

Results

Among the 15 patients with unilateral proximal femoral epiphyseal slippage who were initially selected, five (33.3%) evolved to contralateral slippage. Nine patients (60%) were male and six (40%) were female. Among the five who developed contralateral proximal femoral epiphyseal slippage, four (80%) were male and one (20%) was female, which was not statistically significant.

To analyze the results from the modified Oxford score as a predictive factor for contralateral proximal femoral epiphyseal slippage, we divided the patients into two groups (with and without risk). Patients at risk were considered to be those with total scores of 16, 17 or 18. This was because Popejoy et al.¹⁶ demonstrated that for these scores, the positive predictive value for developing contralateral proximal femoral epiphyseal slippage was 96% and the negative predictive value was 92% (Table 2).

Table 2 – Likelihood that proximal femoral epiphyseal slippage might develop, based on the modified Oxford score and using a linear regression model.

Modified Oxford score	Likelihood of contralateral proximal femoral epiphyseal slippage (%)
16	100
17	97
18	85
19	44
20	5
21	1
22	1
23	0
24	0
25	0
26	0

Source: Popejoy D, Emara K, Birch J. Prediction of contralateral slipped capital femoral epiphysis using the modified Oxford bone age score. *J Pediatr Orthop.* 2012;32(3):290-4.

Four patients were in the group at risk and three of them developed contralateral slippage. There were 11 patients in the group that was not at risk, and two of them evolved to contralateral slippage. From Fisher's exact test, a tendency for patients who developed the disease to differ from those who did not develop it was noted in relation to the risk score ($p=0.077$).

In the statistical analysis, the results obtained were described in terms of means, minimum values, maximum values and standard deviations (quantitative variables) or in terms of frequencies and percentages (qualitative variables). To evaluate the associations between the dichotomous categorical variables and the risk assessed using the Oxford score, Fisher's exact test was used. To make comparisons between the groups in relation to age, the non-parametric Mann-Whitney test was used. p values <0.05 indicated statistical significance. The data were analyzed using the SPSS v.20.0® computer software.

Discussion

Prophylactic surgical treatment for contralateral proximal femoral epiphyseal slippage at the time when slippage is first presented is a matter of controversy. Häggglund¹⁷ demonstrated that the risk of arthrosis in the contralateral hip could be reduced through prophylactic fixation. Thus, they suggested that all patients with unilateral proximal femoral epiphyseal slippage should receive prophylactic treatment for the contralateral hip, given the high incidence of future contralateral slippage and the low complication rate.

Although this procedure is relatively simple and has low morbidity, it has inherent complications, like any surgical procedure. Therefore, it is essential to evaluate the risks and benefits. A variety of factors seem to have an influence on the likelihood that contralateral proximal femoral epiphyseal slippage might develop. These include the following: sex, age, obesity, ethnicity and the contralateral growth plate angle. Although there is an association with etiology, these factors cannot be considered to be predictors of contralateral slippage.¹⁸ The classical indications for this procedure relate to age (for boys, less than 12.5 years; and for girls, less than 10.5 years) and/or proven concomitant endocrine disorders.¹⁹ In our study, a mean age of 10.5 years for prophylactic fixation was also observed.

In this light, it becomes important to seek an effective method for ensuring that indications for prophylactic fixation of a hip are safer and more reliable. Because of the simplicity and accessibility of the modified Oxford score for assessing bone maturity, this method is becoming ever more commonly used. The radiographs needed for applying it are the same ones used in the initial evaluation and in following up patients with proximal femoral epiphyseal slippage.

Stasikelis et al.,¹⁵ in a study on 50 patients, was the first to demonstrate that there is a linear distribution between the modified Oxford score and the risk that contralateral proximal femoral epiphyseal slippage might develop. However, because of their small number of patients, the clinical decision favoring prophylactic treatment did not have any impact.

Popejoy et al.¹⁶ evaluated 260 patients with proximal femoral epiphyseal slippage and found that 64 subsequently developed contralateral slippage. By following the same model of linear distribution, they demonstrated that the patients with modified Oxford scores of 16, 17 or 18 had a 96% probability of developing contralateral slippage. In our study, out of the five patients who presented contralateral proximal femoral epiphyseal slippage, two were not in the group at risk.

We had a total of five patients (33%) with contralateral proximal femoral epiphyseal slippage, which corroborates the current literature. Loder³ and Hurley et al.⁴ had previously demonstrated values close to this in their study (20-40%).

In our study, the left side was more affected (80%). In the literature too, the left side is more affected, in a ratio of 3:2, as demonstrated by Loder³ in a multicenter study published in 1996.

Conclusion

In our sample, application of the modified Oxford score did not show statistical significance. However, we could infer that there was a strong tendency for hips with low scores to evolve toward contralateral slippage. Thus, this score is a further tool that might aid in making the decision on whether to use prophylactic fixation.

Conflicts of interest

The authors declare no conflicts of interest.

REFERENCES

1. Bowen JR. Development disorders of the hip. In: Scoles PV, editor. Pediatric orthopedics in clinical practice. St. Louis: Mosby; 1988. p. 171-8.
2. Aronsson DD, Loder RT, Breur GJ, Weinstein SL. Slipped capital femoral epiphysis: current concepts. *J Am Acad Orthop Surg.* 2006;14(12):666-79.
3. Loder RT. The demographics of slipped capital femoral epiphysis: an international multicenter study. *Clin Orthop Relat Res.* 1996;322:8-27.
4. Hurley JM, Betz RR, Loder RT, Davidson RS, Alburger PD, Steel HH. Slipped capital femoral epiphysis. The prevalence of late contralateral slip. *J Bone Joint Surg Am.* 1996;78(2):226-30.
5. Lehmann CL, Arons RR, Loder RT, Vitale MG. The epidemiology of slipped capital femoral epiphysis: an update. *J Pediatr Orthop.* 2006;26(3):286-90.
6. Billing L, Eklöf O. Slip of the capital femoral epiphysis: revival of a method of assessment. *Pediatr Radiol.* 1984;14(6):413-8.
7. Burrows HJ. Slipped upper femoral epiphysis; characteristic of a hundred cases. *J Bone Joint Surg Br.* 1957;39(B(4)):641-58.
8. Fidler MW, Brook CG. Slipped upper femoral epiphysis following treatment with human growth hormone. *J Bone Joint Surg Am.* 1974;56(8):1719-22.
9. Weiner D. Pathogenesis of slipped capital femoral epiphysis: current concepts. *J Pediatr Orthop B.* 1996;5(2):67-73.
10. Kennedy JG, Hresko MT, Kasser JR, Shrock KB, Zurakowski D, Waters PM, et al. Osteonecrosis of the femoral head associated with slipped capital femoral epiphysis. *J Pediatr Orthop.* 2001;21(2):189-93.

11. Loder RT, Aronson DD, Greenfield ML. The epidemiology of bilateral slipped capital femoral epiphysis. A study of children in Michigan. *J Bone Joint Surg Am.* 1993;75(8):1141-7.
12. Hägglund G, Hansson LI, Ordeberg G, Sandström S. Bilaterality in slipped upper femoral epiphysis. *J Bone Joint Surg Br.* 1988;70(2):179-81.
13. Bertani A, Launay F, Glard Y, Chrestian P, Jouve JL, Bollini G. Severe hip infection after a prophylactic contralateral fixation in slipped upper femoral epiphysis: a case report. *J Pediatr Orthop B.* 2009;18(5):238-41.
14. Seller K, Raab P, Wild A, Krauspe R. Risk-benefit analysis of prophylactic pinning in slipped capital femoral epiphysis. *J Pediatr Orthop B.* 2001;10(3):192-6.
15. Stasikelis PJ, Sullivan CM, Phillips WA, Polard JA. Slipped capital femoral epiphysis. Prediction of contralateral involvement. *J Bone Joint Surg Am.* 1996;78(8):1149-55.
16. Popejoy D, Emara K, Birch J. Prediction of contralateral slipped capital femoral epiphysis using the modified Oxford bone age score. *J Pediatr Orthop.* 2012;32(3):290-4.
17. Hägglund G. The contralateral hip in slipped capital femoral epiphysis. *J Pediatr Orthop B.* 1996;5(3):158-61.
18. Zide JR, Popejoy D, Birch JG. Revised modified Oxford bone score: a simpler system for prediction of contralateral involvement in slipped capital femoral epiphysis. *J Pediatr Orthop.* 2011;31(2):159-64.
19. Segal LS, Davidson RS, Robertson WW Jr, Drummond DS. Growth disturbances of the proximal femur after pinning of juvenile slipped capital femoral epiphysis. *J Pediatr Orthop.* 1991;11(5):631-7.