







Facet Tropism/Inclination and Its Association with Intervertebral Disc Herniation in the Lumbar Spine – A Radiological Evaluation*

Tropismo/inclinação facetária e sua associação com hérnia de disco intervertebral na região lombar da coluna – Uma avaliação radiológica

Sanjay Yadav¹ Rajkumar Arya¹ Raghul Dakshinamoorthy¹ Abhinav Anand Jha¹ Shivi Jain²
Ishan Kumar²

¹Department of Orthopedics, Institute of Medical Sciences, Banaras Hindu University, Varanasi, Uttar Pradesh, India

²Department of Radiodiagnosis and Imaging, Institute of Medical Sciences, Banaras Hindu University, Varanasi, Uttar Pradesh, India

Address for correspondence Sanjay Yadav, MS, DNB, Department of Orthopedics, Institute of Medical Sciences, Banaras Hindu University, Varanasi 221005, Uttar Pradesh, India
(e-mail: drsanjay.pgi@gmail.com).

Rev Bras Ortop 2022;57(6):941–946.

Abstract

Objective To assess the role of facet tropism (FT) in intervertebral disc prolapse.

Methods A total 98 patients with lower back pain were included in the study. Magnetic resonance imaging scans were performed and analyzed. The angles of the right and left facets were measured on the axial section. Patients without disc prolapse at the L3-L4, L4-L5 and L5-S1 levels act as controls for those with disc prolapse at the same levels. A statistical analysis was also performed.

Results The incidence of FT at the L3-L4 level was of 85.2% in patients with disc herniation ($n = 27$), and of 56.3% in the control group, which was statistically significant ($p = 0.008$). Similarly, at the L4-L5 level, incidence of FT among cases and controls was of 71.4% ($n = 35$) and 52.4% respectively ($p = 0.066$). At the L5-S1 the incidence was of 66% and 51% among cases and controls respectively ($p = 0.13$).

Conclusion We found a positive association between FT and disc herniation at the L3-L4 level, but no association at the L4-L5 and L5-S1 levels.

Keywords

- ▶ intervertebral disc degeneration
- ▶ lumbar vertebrae
- ▶ spondylolisthesis
- ▶ magnetic resonance

* Study developed at the Department of Orthopedics, Institute of Medical Sciences, Banaras Hindu University, India.

received
July 31, 2021
accepted
October 14, 2021
published online
April 19, 2022

DOI <https://doi.org/10.1055/s-0042-1742338>.
ISSN 0102-3616.

© 2022. Sociedade Brasileira de Ortopedia e Traumatologia. All rights reserved.
This is an open access article published by Thieme under the terms of the Creative Commons Attribution-NonDerivative-NonCommercial-License, permitting copying and reproduction so long as the original work is given appropriate credit. Contents may not be used for commercial purposes, or adapted, remixed, transformed or built upon. (<https://creativecommons.org/licenses/by-nc-nd/4.0/>)
Thieme Revinter Publicações Ltda., Rua do Matoso 170, Rio de Janeiro, RJ, CEP 20270-135, Brazil

Resumo

Objetivo Avaliar o papel do tropismo facetário (TF) no prolapso discal intervertebral.

Métodos Um total de 98 pacientes com dor lombar foram incluídos no estudo. Exames de ressonância magnética foram realizados e analisados, e os ângulos das facetos direita e esquerda foram medidos na seção axial. Os pacientes sem prolapso discal nos níveis L3-L4, L4-L5 e L5-S1 atuam como controles para aqueles com prolapso nos mesmos níveis. Fez-se também uma análise estatística.

Resultados A incidência de TF no nível L3-L4 foi de 85,2% em pacientes com hérnia discal ($n = 27$), e de 56,3% no grupo controle, o que foi estatisticamente significativo ($p = 0,008$). Da mesma forma, a incidência de TF no nível L4-L5 entre casos e controles foi de 71,4% ($n = 35$) e 52,4%, respectivamente ($p = 0,066$). No nível L5-S1, a incidência foi de 66% e 51% nos casos e nos controles, respectivamente ($p = 0,13$).

Conclusão Encontramos associação positiva entre TF e hérnia de disco no nível L3-L4, mas nenhuma associação nos níveis L4-L5 e L5-S1.

Palavras-chave

- ▶ degeneração do disco intervertebral
- ▶ vértebras lombares
- ▶ espondilolistese
- ▶ ressonância magnética

Introduction

Facet joints connect adjacent vertebrae, and they are synovial joints that help in flexion, extension, and rotation of the spine. For each disc space, there are two facet joints and a disc, which together form a tripod that creates a motion segment. The facet joints bear $\sim 33\%$ of the dynamic compressive load and 35% of the static load.^{1,2} Facet tropism (FT) is defined as an asymmetry in the angles of the facet joints of left and right sides,^{3,4} and it has been proposed that FT is an important cause of lumbar degenerative disc pathologies and spondylolisthesis.^{5,6} When symptomatic, such condition often requires surgical intervention. In 1927, Putti⁷ proposed the significance of asymmetrical zygapophyseal joints in the pathogenesis of low back pain. Asymmetry in facet orientation was determined to be a normal feature in thoracic vertebrae, but not in lumbar vertebrae. It has been proposed that, in the lumbar segment, this may be due to a pathological condition.

There is conflicting evidence regarding the association between tropism and prolapsed disc. It has long been thought that disc degeneration in the spine can change the kinematics and load distribution, resulting in secondary structural and morphological effects on the facet joints and their orientation. Contrary to that view, asymmetry in the facet joints increases the motion at a particular segment and reduces tolerance to anterior shearing forces.^{8,9} This can exacerbate the degeneration process in both the disc and facet joints, resulting in prolapsed intervertebral disc.⁴ Van Schaik et al.¹⁰ showed a significant relationship between lower back pain and intervertebral disc prolapse at the L4-L5 level. Farhan and Sullivan¹¹ first suggested the correlation between FT and the development of lumbar disc prolapse. However, the role of FT in the pathogenesis of disc prolapse is still unclear. In the present study, we aim to analyze the correlation between tropism in the facet joints and degenerative disc prolapse, as well as the association between the severity of FT and disc prolapse. Identifying the role of facet inclination in intervertebral disc prolapse can enhance our understanding of the pathophysiology of

the facet joints and improve the treatment and management of disc prolapse.

Methods

The present is a cross-sectional study. The magnetic resonance imaging (MRI) scans of consecutive patients with back pain for more than 3 months with or without radiculopathy and aged between 19 and 64 years were analyzed over a period of 12 months. A total of 98 cases were studied, and cases with previous lumbar spine surgery, spinal deformity, or old trauma were excluded from the study.

Appropriate clearances were obtained from institutional ethics committee (IEC no. 2020/EC/2102). The study design was retrospective evaluation of MRI scans and case details available to us.

Facet tropism evaluation: The facet angles were evaluated using MRI scans of the spine. All MRIs were performed using the SIGNA 1.5T MRI scanner (GE Healthcare, Chicago, IL, US). The thickness of the image slice thickness was of at least 3 mm. T2-weighted axial film at the L3-L4, L4-L5 and L5-S1 levels with reference lines (facet line and a line along the posterior border of the vertebral body) drawn on it was selected to measure the right and left angles of the facet joints in relation to the coronal plane, which closely bisects the facet joints at each segmental level. The facet angle was calculated by intersecting the line drawn and the facet line (the line connecting the anteromedial and posterolateral tips of the superior articular facets; ▶ **Fig. 1**). The angles were measured manually using a goniometer. Facet tropism was calculated by subtracting the left and right facet angles, and FT was defined as an angulation difference $\geq 7^\circ$ in the coronal orientation of the left and right facet angles. We used the FT/facet inclination (FI) grading method developed by Ko et al.¹² as follows: grade 0 if $FI \leq 6^\circ$; grade 1 if the FI ranges from 7° to 15° ; and grade 2 if $FI \geq 16^\circ$ (▶ **Table 1**). Patients with grades 1 and 2 FI are considered to have FT, and grade 2 is considered severe.

Disc herniation was also evaluated at the levels from L3 to S1. Patients without disc prolapse between levels L3 and S1

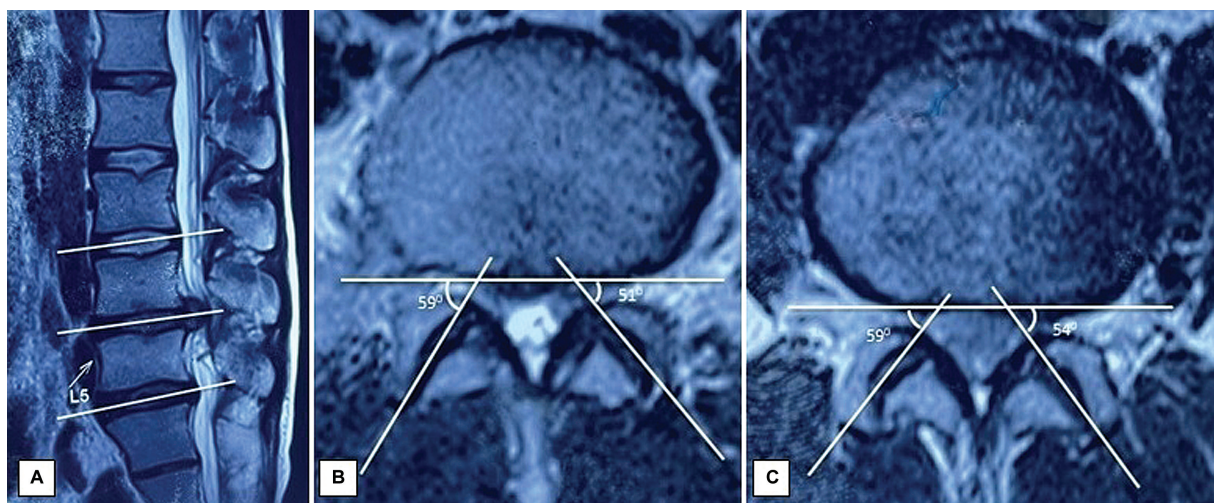


Fig. 1 (A) T2-weighted magnetic resonance imaging scan on sagittal view showing mid-disc cut at the levels from L3 to S1; (B,C) axial sections of T2-weighted images showing the angles of the left and right facets and disc prolapse with facet tropism at different levels. (Facet angle measurement: a reference line is drawn along the posterior border of the vertebra in the coronal plane. Facet lines joining the anteromedial and posterolateral ends of the facet joints are drawn on both sides intersecting the reference line. The angle between the facet lines and the coronal reference line are the facet angles.)

Table 1 Facet tropism according to the method of Ko et al.¹²

Explanation	Grade	Angle of the facet tropism
No facet tropism (no asymmetry)	Grade 0	≤ 6°
Moderate facet tropism (moderate asymmetry)	Grade 1	7°–15°
Severe facet tropism (severe asymmetry)	Grade 2	≥ 16°

acted as controls for those having disc prolapse at the same levels. Data was recorded on a Microsoft Excel (Microsoft Corp., Redmond, WA, US) spreadsheet. The statistical analysis was performed using the Statistical Package for the Social Sciences (IBM SPSS Statistics for Windows, IBM Corp., Armonk, NY, US) software, version 22.0. Data was reported as means and standard deviations. The relationship between

disc herniation and FI was evaluated using the Chi-squared test. Statistical significance was set as *p*-values ≤ 0.05.

Results

Magnetic resonance imaging (MRI) scans of 98 patients (54 male and 44 female patients) were evaluated. The average age of the sample was 42.1 years; that of the male patients was 42.3 years, and that of the female patients was 41.9 years. No significant gender difference was found regarding FT. A total of 294 lumbar levels (588 facet angles) were studied, including the levels from L3 to S1.

Overall facet joint angulation: The mean right and left FIs and cases with variable FI at the levels between L3 and S1 are detailed in ►Table 2. The prevalence of FI variability according to the tropism grading is shown in ►Table 3, which also shows the incidence rate of the total of cases of FT versus the severe cases. At the L3-L4 level, the rate of severe FT was of 8.2%; at the L4-L5 level, 6.1%; and, at the L5-S1 level, 3.1%.

Correlation between FT and disc herniation: The relationship between lumbar disc herniation and variable FI/FT is described in ►Table 4. The correlation at the L4-L5 level was

Table 2 Mean facet angle and facet tropism

Segment level	Facet angle (minimum; in degrees)	Facet angle (maximum; in degrees)	Mean facet angle (in degrees)	Presence of tropism (n)	Absence of tropism (n)
L3-L4 (right)	23	70	43.2 ± 9.01	36	62
L3-L4 (left)	19	69	46.4 ± 9.23		
L4-L5 (right)	15	68	42.7 ± 9.53	31	67
L4-L5 (left)	19	74	44 ± 10.01		
L5-S1 (right)	17	56	39.02 ± 8.06	31	67
L5-S1 (left)	16	65	41.9 ± 9.31		

Table 3 Incidence of facet tropism

Segment level	Facet tropism grade*	Number of patients	Incidence rate (total of cases/severe cases**; %)
L3-L4	0	62	36.7/8.2
	1	28	
	2	8	
L4-L5	0	66	32.6/6.1
	1	26	
	2	6	
L5-S1	0	67	31.6/3.1
	1	28	
	2	3	

Notes: *Grading method as proposed by Ko et al.¹²

**Severe tropism defined as grade 2 (according to the method of Ko et al.¹²).

Table 4 Relationship between facet tropism and disc prolapse

Spinal level	Disc herniation - n (%)		Facet tropism - n (%)		p-value
			Yes	No	
L3-L4	Present	27 (27.6)	14 (51.8)	13 (48.2%)	0.038
	Absent	71 (72.4)	22 (30.9)	49 (69.1%)	
L4-L5	Present	35 (35.7)	17 (48.5)	18 (51.5%)	0.007
	Absent	63 (64.3)	13 (23.1)	50 (76.9%)	
L5-S1	Present	47 (47.9)	19 (40.4)	28 (59.6%)	0.073
	Absent	51 (52)	12 (23.5)	39 (76.5%)	

the most statistically significant ($p = 0.007$) followed by the L3-L4 level ($p = 0.03$).

Discussion

The orientation of the facet joints bears a considerable role in understanding the biomechanics of the lumbar spine. For their coordinated movements, a symmetrical alignment of both sides of the facet joint is necessary. Asymmetrical facet joints result in abnormal loading of the spinal motion segments. There are few studies which report the association between FI variability and lumbar disc herniation, and their results are not consistent. Facet joint orientation and bilateral variability can be assessed using MRI without exposure to harmful radiation.³ The usual course of facet joint pathologies is not very clear, and a few studies^{4,13-15} suggest that FT may be due to a biological remodeling process secondary to disc changes and instability of the spine in the rotational axis. A few studies¹⁶⁻¹⁸ also suggest a developmental origin.

The current study establishes that tropism/bilateral variability exists in lumbar levels irrespective of the degenerative changes. This challenges the notion that facet orientation

is related to remodeling changes caused by spine degeneration. The L3-L4 joint is more rounded and resists both anterior and lateral translations, whereas the L5-S1 joint is flat and oriented more in the coronal plane. This provides higher resistance to anterior shear stresses. Facet joint orientation in the axial plane in patients with spondylolisthesis in this region presented a variation up to 15° in one study.¹⁹

Kalichman et al.^{17,18} and Farfan and Sullivan¹¹ reported that the angle of the lumbar facet joint and lumbar disc herniation were significantly linked to the asymmetry of the lumbar facet joint and its severity. Similar results were found in the present study.

In another study, Noren et al.²⁰ found that FT is a risk factor in the development of disc disease. Asymmetrical and sagittally-inclined facet joints were present in patients with lumbar disc prolapse, especially taller subjects, in the study by Karacan et al.⁴ Cyron and Hutton¹⁴ hypothesized that variable facet orientation can lead to segmental instability. This can increase the rotational strain on the annulus fibrosus and lead to disc prolapse. In another study, Chadha et al.²¹ reported a considerable association between FT and disc prolapse at the L5-S1 level, but no association at the L4-L5 level.

On the other hand, some researchers^{10,20,22,23} have suggested that FT has no clinical significance. They consider it to be a congenital structural problem rather than one due to age or degeneration, and propose that there is no association between the facet angle and disc herniation.

Various other works^{24,25} have also demonstrated that the axial torque-rotation response in the lumbar spine is unaffected by the orientation of a facet joint with a similar degree of asymmetry at all levels. Lee et al.²⁶ found no significant difference in FT between herniated and normal discs in both adolescent and adult groups, except at the L4-L5 level in adults.

On flexion-extension, the more coronally-oriented facet joint restricts movement in the sagittal plane, causing involuntary rotation along the more sagittally-oriented facet joint. Masharawi et al.⁸ have explained how FT may convert movements in one plane into a complex multiplanar movement. The nucleus shifts posterolaterally in an unbalanced manner when flexion and torsion are coupled. The combination of flexion and torsion has been shown in many biomechanical studies^{27,28} to cause injury to the posterolateral annulus.

In the present study, intervertebral disc prolapse was especially associated with FT at L3-L4 and L4-L5 levels, with a statistically insignificant association at the L5-S1 level. This can be explained by different loading patterns at different levels. The biomechanics at L4-L5 level and those above it is different from that of the L5-S1 level, as the L4-L5 level lies between 2 mobile segments, and the L5-S1 level lies between mobile and fixed segments. Further, the L5-S1 disc is subjected to higher anteroposterior shear forces because of the increased inclination at S1 and the absence of a protective role of the extensor muscles.^{21,29} The high correlation between FT and disc prolapse reported at L4-L5

but not at L5-S1 might thus be explained by a variation in loading pattern.

The present study has several limitations. First, it is a single-center study with a small sample size. Second, errors may have been made in locating the margins and reference plane of the facet joint. Osteophytes in the facet joint can lead to errors in the measurement of the facet angle. Third, it is not feasible to analyze FT as an isolated factor; other degenerative changes such as asymmetric disc degeneration may also affect FT; hence, further studies on the pathological mechanisms of FT are needed. One of the strengths of the study is the inclusion of patients without disc prolapse at the same level as controls for comparison, instead of considering the adjacent segment, as in many previous studies. Nevertheless it would have been better had the controls been obtained by performing MRI scans in asymptomatic subjects.

Conclusion

Clinical significance: The present study showed a positive association between facet inclination variability and disc herniation at the L4-L5 level, followed by the L3-L4 level. Facet orientation may guide which side to approach for surgical decompression when needed. Long-term follow up may help in deducing the natural history of facet orientation variability.

Authors' Contribution Statement

Sanjay Yadav: conceptualization (lead), writing of the original draft (equal), writing, review, and editing (equal), and supervision (lead);

Rajkumar Arya: data curation (lead), formal analysis (equal), writing, review, and editing (equal);

Raghul Dakshinamoorthy: data curation (equal), writing, review, and editing (equal), and formal analysis (equal);

Abhinav Anand Jha: investigation (equal), writing, review, and editing (equal), and project administration (equal); and

Ishan Kumar: data curation, reviewing and editing.

Financial Support

These authors declare they have received no financial support from public, commercial, or non-profit sources.

Conflict of Interests

The authors have no conflict of interests to declare.

References

- Lorenz M, Patwardhan A, Vanderby R Jr. Load-bearing characteristics of lumbar facets in normal and surgically altered spinal segments. *Spine (Phila Pa 1976)* 1983;8(02):122-130
- Yang KH, King AIKH. Mechanism of facet load transmission as a hypothesis for low-back pain. *Spine (Phila Pa 1976)* 1984;9(06):557-565
- Boden SD, Riew KD, Yamaguchi K, Branch TP, Schellinger D, Wiesel SW. Orientation of the lumbar facet joints: association with degenerative disc disease. *J Bone Joint Surg Am* 1996;78(03):403-411
- Karacan I, Aydin T, Sahin Z, et al. Facet angles in lumbar disc herniation: their relation to anthropometric features. *Spine (Phila Pa 1976)* 2004;29(10):1132-1136
- Chotiyarnwong P, Pichaisak W. Facet joint orientation and tropism in lumbar degenerative disc disease and spondylolisthesis. *Global Spine J* 2014;4(1 Suppl):s-0034-1376586-s-0034-13765866
- Gao T, Lai Q, Zhou S, et al. Correlation between facet tropism and lumbar degenerative disease: a retrospective analysis. *BMC Musculoskelet Disord* 2017;18(01):483
- Putti V. New conceptions in the pathogenesis of sciatic pain. *Lancet* 1927;2:53-60
- Masharawi Y, Rothschild B, Salame K, Dar G, Peleg S, Hershkovitz I. Facet tropism and interfacet shape in the thoracolumbar vertebrae: characterization and biomechanical interpretation. *Spine (Phila Pa 1976)* 2005;30(11):E281-E292
- Park JB, Chang H, Kim KW, Park SJ. Facet tropism: a comparison between far lateral and posterolateral lumbar disc herniations. *Spine (Phila Pa 1976)* 2001;26(06):677-679
- Van Schaik JP, Verbiest H, Van Schaik FD. The orientation of laminae and facet joints in the lower lumbar spine. *Spine (Phila Pa 1976)* 1985;10(01):59-63
- Farfan HF, Sullivan JD. The relation of facet orientation to intervertebral disc failure. *Can J Surg* 1967;10(02):179-185
- Ko S, Chae S, Choi W, Kim JY, Kwon J, Doh J. The Prevalence of Facet Tropism and Its Correlation with Low Back Pain in Selected Community-Based Populations. *Clin Orthop Surg* 2019;11(02):176-182
- Farfan HF, Huberdeau RM, Dubow HI. Lumbar intervertebral disc degeneration: the influence of geometrical features on the pattern of disc degeneration—a post mortem study. *J Bone Joint Surg Am* 1972;54(03):492-510
- Cyron BM, Hutton WC. Articular tropism and stability of the lumbar spine. *Spine (Phila Pa 1976)* 1980;5(02):168-172
- Dai L, Jia L. Role of facet asymmetry in lumbar spine disorders. *Acta Orthop Belg* 1996;62(02):90-93
- Grogan J, Nowicki BH, Schmidt TA, Haughton VM. Lumbar facet joint tropism does not accelerate degeneration of the facet joints. *AJNR Am J Neuroradiol* 1997;18(07):1325-1329
- Kalichman L, Guermazi A, Li L, Hunter DJ, Suri P. Facet orientation and tropism: associations with spondylolysis. *J Spinal Disord Tech* 2010;23(02):101-105
- Kalichman L, Suri P, Guermazi A, Li L, Hunter DJ. Facet orientation and tropism: associations with facet joint osteoarthritis and degeneratives. *Spine (Phila Pa 1976)* 2009;34(16):E579-E585
- Williams R, Cheung JP, Goss B, et al. An International Multicenter Study Assessing the Role of Ethnicity on Variation of Lumbar Facet Joint Orientation and the Occurrence of Degenerative Spondylolisthesis in Asia Pacific: A Study from the AOSpine Asia Pacific Research Collaboration Consortium. *Global Spine J* 2016;6(01):35-45
- Noren R, Trafimow J, Andersson GB, Huckman MS. The role of facet joint tropism and facet angle in disc degeneration. *Spine (Phila Pa 1976)* 1991;16(05):530-532
- Chadha M, Sharma G, Arora SS, Kochar V. Association of facet tropism with lumbar disc herniation. *Eur Spine J* 2013;22(05):1045-1052
- Badgley C. The articular facets in relation to low back pain and sciatic radiation. *J Bone Joint Surg Am* 1941;23(02):481-496
- Vanharanta H, Floyd T, Ohnmeiss DD, Hochschuler SH, Guyer RD. The relationship of facet tropism to degenerative disc disease. *Spine (Phila Pa 1976)* 1993;18(08):1000-1005
- Duncan NA, Ahmed AM. The role of axial rotation in the etiology of unilateral disc prolapse. An experimental and finite-element analysis. *Spine (Phila Pa 1976)* 1991;16(09):1089-1098
- Cassidy JD, Loback D, Yong-Hing K, Tchang S. Lumbar facet joint asymmetry. Intervertebral disc herniation. *Spine (Phila Pa 1976)* 1992;17(05):570-574

- 26 Lee DY, Ahn Y, Lee SH. The influence of facet tropism on herniation of the lumbar disc in adolescents and adults. *J Bone Joint Surg Br* 2006;88(04):520–523
- 27 Veres SP, Robertson PA, Broom ND. The influence of torsion on disc herniation when combined with flexion. *Eur Spine J* 2010;19(09):1468–1478
- 28 Drake JD, Aultman CD, McGill SM, Callaghan JP. The influence of static axial torque in combined loading on intervertebral joint failure mechanics using a porcine model. *Clin Biomech (Bristol, Avon)* 2005;20(10):1038–1045
- 29 Arjmand N, Shirazi-Adl A. Biomechanics of changes in lumbar posture in static lifting. *Spine (Phila Pa 1976)* 2005;30(23):2637–2648