



Original Article

Clinical and radiographic medium-term evaluation on patients with developmental dysplasia of the hip, who were submitted to open reduction, capsuloplasty and Salter osteotomy^{☆,☆☆}

Válney Luiz da Rocha, Guilherme Lima Marques, Leonardo Jorge da Silva, Tiago Augusto di Macedo Bernardes, Frederico Barra de Moraes*

Departamento de Ortopedia e Traumatologia, Hospital das Clínicas, Universidade Federal de Goiás, Goiânia, GO, Brazil

ARTICLE INFO

Article history:

Received 12 October 2012

Accepted 22 March 2013

Keywords:

Congenital hip dislocation/surgery

Surgical procedures

Operative/methods

Bone diseases

Developmental

Hip/growth and development

ABSTRACT

Objective: to evaluate the clinical and radiographic medium-term results from surgical treatment of developmental dysplasia through open reduction, Salter et al.'s osteotomy and capsuloplasty.

Methods: 13 patients were evaluated, 13 hips treated surgically by the proposed technique between 2004 and 2011. A clinical and radiographic evaluation was conducted by Dutoit et al. and Severin et al. criteria, respectively.

Results: the acetabular preoperative index for the 13 surgically treated hips ranged from 27° to 50° (average of 36), and after surgical correction to 18.5° (10–28°), so that the evaluations of preoperative and postoperative acetabular indexes showed up significant statistic reduction ($p < 0.05$). Regarding the postoperative clinical evaluation, it was found: nine excellent hips (69.2%), three good ones (23.1%), no fair hips (0%) and a poor one (7.7%). In radiographic evaluation, it was found: six excellent hips (46.1%), three good ones (23.1%), no fair hips (0%) and four poor ones (30.8%). Therefore, favorable results were obtained (92.3%), with grouped hips with excellent and good ratings as satisfactory and with fair and bad ratings as unsatisfactory. It is also important to notice that there was no significance among occurrence of complications, the patient's age, the time of surgery and the preoperative acetabular index ($p > 0.05$). As complications occurred, it was found that three subluxations and a subluxation associated with avascular necrosis of the femoral head.

Conclusion: open reduction, Salter et al.'s osteotomy and capsuloplasty are seen to be a viable option for the treatment of developmental dysplasia of the hip, according to clinical and radiological medium-term evaluations.

© 2014 Sociedade Brasileira de Ortopedia e Traumatologia. Published by Elsevier Editora Ltda. All rights reserved.

* Please cite this article as: da Rocha VL, Marques GL, da Silva LJ, di Macedo Bernardes TA, de Moraes FB. Avaliação clínica e radiológica em médio prazo dos pacientes portadores de displasia do desenvolvimento do quadril submetidos a redução aberta, capsuloplastia e osteotomia de Salter. Rev Bras Ortop. 2014;49:51-55.

☆☆ Study conducted at Pediatric Orthopedia Service, Department of Orthopedia and Traumatology, Hospital das Clínicas, Universidade Federal de Goiás, Goiânia, GO, Brazil.

* Corresponding author.

E-mail: frederico_barra@yahoo.com.br (F.B. de Moraes).

2255-4971/\$ – see front matter © 2014 Sociedade Brasileira de Ortopedia e Traumatologia. Published by Elsevier Editora Ltda. All rights reserved. <http://dx.doi.org/10.1016/j.rboe.2014.01.006>

Avaliação clínica e radiológica em médio prazo dos pacientes portadores de displasia do desenvolvimento do quadril submetidos a redução aberta, capsuloplastia e osteotomia de Salter

R E S U M O

Palavras-chave:

Luxação congênita do quadril/cirurgia
Procedimentos cirúrgicos operatórios/métodos
Doenças do desenvolvimento ósseo
Quadril/crescimento e desenvolvimento

Objetivo: avaliar o resultado clínico e radiológico do tratamento cirúrgico da displasia do desenvolvimento do quadril em médio prazo, por meio da redução aberta, da capsuloplastia e da osteotomia de Salter et al.

Métodos: foram avaliados 13 pacientes, 13 quadris, entre 2004 e 2011, tratados cirurgicamente pela técnica proposta. Uma avaliação clínica e radiológica foi feita pelos critérios de Dutoit et al. e Severin et al., respectivamente.

Resultados: nos 13 quadris acometidos o índice acetabular pré-operatório variou de 27° a 50° (média de 36) e, após correção cirúrgica, para 18,5° em média, com variação de 10° a 28°, de modo que as avaliações dos índices acetabulares pré e pós-operatórios apresentaram redução com significância estatística ($p < 0,05$). Quanto à avaliação clínica pós-operatória, foram encontrados: nove quadris ótimos (69,2%), três bons (23,1%), nenhum regular (0%) e um ruim (7,7%). Na avaliação radiológica, foram encontrados seis quadris ótimos (46,1%), três bons (23,1%), nenhum regular (0%) e quatro ruins (30,8%). Portanto, obtiveram-se resultados favoráveis em 92,3%, pois agrupam-se quadris com avaliação ótima e boa como satisfatórios e os com avaliação regular e ruim como insatisfatórios. Atente-se que não houve significância entre a ocorrência de complicações, a idade do paciente, o momento da cirurgia e o índice acetabular pré-operatório ($p > 0,05$). Como complicações ocorridas, têm-se três subluxações isoladas e uma subluxação associada à necrose avascular da cabeça femoral.

Conclusão: a redução aberta, a capsuloplastia e a osteotomia de Salter et al. são consideradas uma opção viável do ponto de vista clínico e radiológico em médio prazo para o tratamento da displasia do desenvolvimento do quadril.

© 2014 Sociedade Brasileira de Ortopedia e Traumatologia. Publicado por Elsevier Editora Ltda. Todos os direitos reservados.

Introduction

Developmental dysplasia of the hip (DDH) involves a spectrum of developmental disorders of the hip, which present in different forms and ages, from a ligament laxity to complete dislocation of the femoral head. In such cases, the acetabulum is situated in an anterosuperior position as a result of excessive anteversion, which makes it increasingly shallow, thick and oblique. DDH is classified into two types: typical (subdivided into dislocable, subluxated and dislocated hip) and teratologic.

The etiology of DDH remains unknown, but ethnic and genetic factors are important. Genetic factors may determine the acetabular dysplasia, ligament laxity or both, as reported by Wynne-Davies.¹ In addition to the preexisting factors, mechanical factors such as intrauterine position and postnatal habits can also interfere with the process.

In several papers, the incidence of DDH ranged from 2 to 17 per 1000. In Brazil, Volpon and Carvalho Filho² demonstrated an incidence of 2.31 per 1000.

The treatment depends on the patient's age, degree of acetabular and proximal femur dysplasia. It is considered that, after the start of the walking, a surgical option for the treatment of DDH consists of open reduction, Salter's osteotomy, and capsuloplasty.³ This technique promotes acetabular repositioning, aiming to increase the coverage of the femoral head, which will be surgically reduced into the acetabulum.

The aim of this study was to evaluate the clinical and radiological outcome in the medium term surgical treatment of DDH by open reduction, Salter's osteotomy, and capsuloplasty.

Materials and methods

Thirteen patients who remained with DDH after they start walking, whether by failure of medical treatment in the first year of life or by referral of the child with a delayed diagnosis, were evaluated. All were treated surgically between 2004 and 2011, by the techniques of open reduction, capsuloplasty, and Salter's osteotomy. The study was approved by the Ethics and Research Committee of the hospital, where the work was done.

The age of patients ranged between one year and 11 months to six years. The group was composed of three males and 10 females, with six hips with involvement on the right side and seven on the left side. The average immobilization time with postoperative pelvi-pedal plaster was two months. The patients underwent surgical treatment with open reduction, capsuloplasty and Salter et al.'s osteotomy, as per surgical description,⁴ and were operated by the same orthopedic surgeon (Fig. 1). However, in only one case it was necessary to make previous traction to surgery. On average, the osteosynthesis material was removed after one year of postoperative follow-up, whose clinical and radiological evaluation occurred

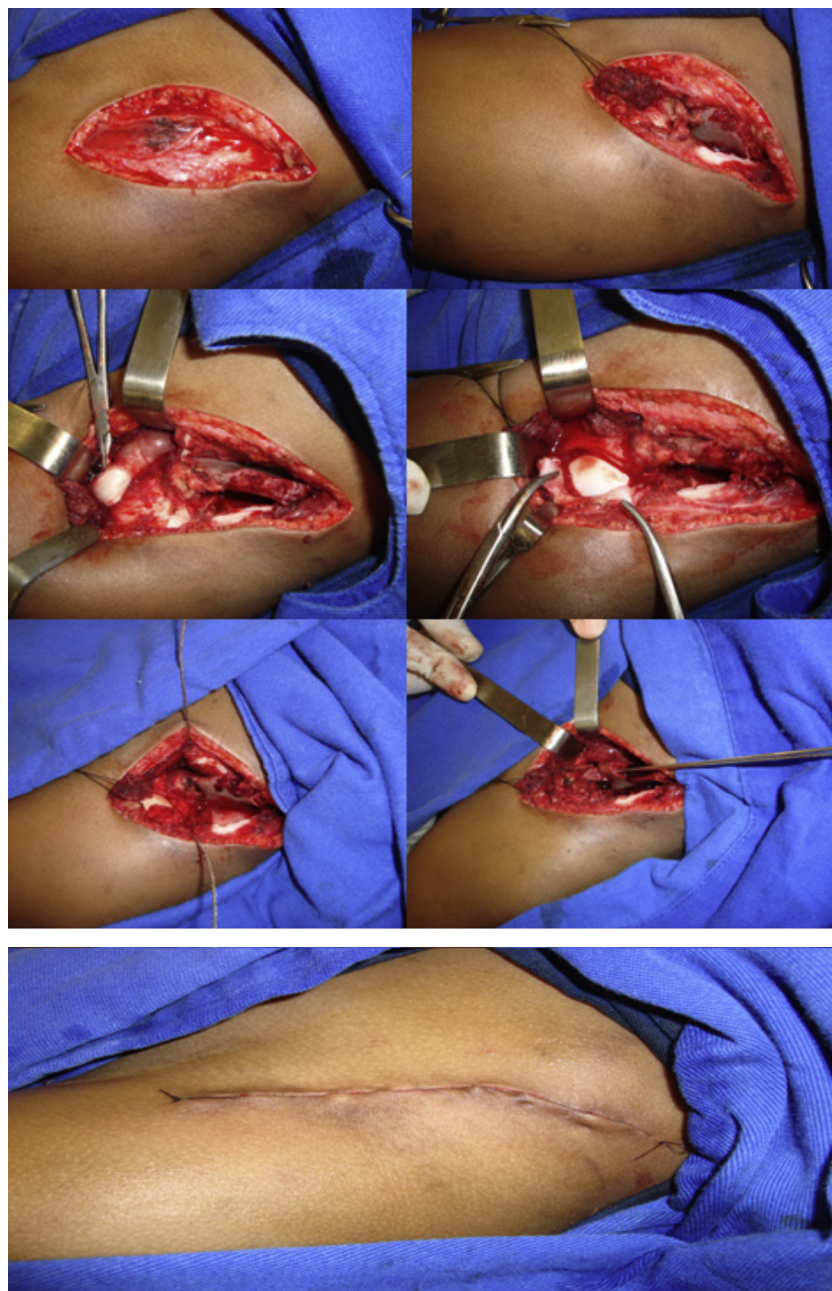


Fig. 1 – Surgical technique: open reduction, capsuloplasty and Salter's innominate osteotomy.

under an average outpatient follow-up of 5.3 years (1.4–14.1 years).

To evaluate the results, radiographic and clinical criteria were employed. The radiographs were evaluated by the criteria of Severin,⁵ which take into account the Wiberg acetabular (AC) and CE angles, the sphericity of the femoral head, the dislocation and subluxation of the hip, and occurrence (or not) of arthrosis. With respect to the clinical situation, the analysis was performed in conformity to Dutoit et al. criteria,⁶ based on hip stability and mobility, pain, lameness and on the Trendelenburg test.

The statistical analysis was performed descriptively and analytically, with the methods of McNemar, Friedman, Wilcoxon and Univariate Logistic Regression Analysis, in

order to establish statistical significance between the clinical and radiological parameters, with a significance level of 5% ($p < 0.05$).

Results

The hips were pooled for analysis regardless of the involved side. In the 13 affected hips, the preoperative acetabular index ranged from 27° to 50° (average, 36°) and after the surgical correction, the average was 18.5° (10–28°). For this estimate, the Friedman test was used, and for pairwise comparison of the acetabular index, we used the Wilcoxon test, obtaining a statistically significant result ($p < 0.05$).

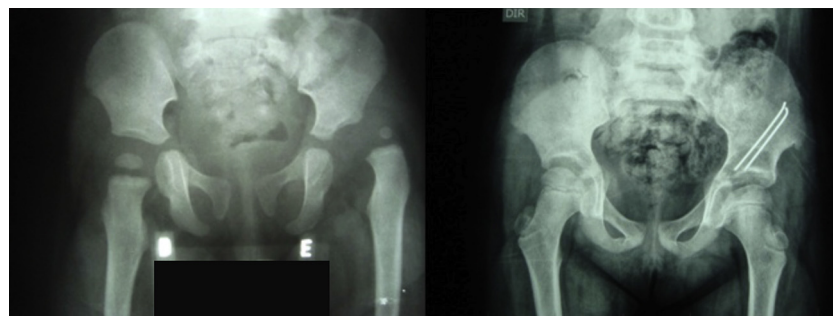


Fig. 2 – Radiological evolution of a female patient with DDH treated with Salter et al.'s osteotomy. Excellent radiologic result with 53 months' follow-up.

According to Dutoit et al.,⁶ in the clinical evaluation we could observe nine very good (69.2%), three good (23.1%), 0 fair (0%), and 1 poor (7.7%) hip. Therefore, we grouped hips with good and very good evaluation as satisfactory, and those with poor and fair evaluation as unsatisfactory. Hence, we obtained 92.3% satisfactory results (Table 1).

In the radiological study, six very good (46.1%) (Fig. 2), three good (23.1%), 0 fair (0%), and four poor (30.8%) hips were found. Therefore, we grouped hips with good and very good evaluation as satisfactory, and those with poor and fair evaluation as unsatisfactory. Hence, we obtained 69.2% of favorable results (Table 2).

To evaluate the influence of Dutoit et al.⁶ and of Severin⁵ in relation to pre- and post-surgical treatment, considering the techniques of open reduction and capsuloplasty and Salter's osteotomy, McNemar test and Fisher et al.'s exact test were applied, and no other correlations were observed, i.e., only the surgery interfered with the clinical and radiological outcome.

With regard to complications, two isolated subluxations and one osteonecrosis of the femoral head with subluxation

and dislocation occurred. This was one of the cases of isolated subluxation treated with another surgical procedure. There were no cases of infection, fracture, significant lower limb dysmetria, or neurovascular injury.

Discussion

The surgical treatment of developmental dysplasia of the hip is becoming an increasingly less frequent challenge, thanks to current methods for early diagnosis and prevention, for example, the physical examination of the newborn and routine use of ultrasonography for suspected cases. Physical examination to identify cases of DDH should be done routinely on all newborns.

The Ortolani maneuver, described in 1948 by Marino Ortolani *apud* Tachdjian,⁴ when positive, allows the diagnosis of DDH; however, the negativity does not exclude the diagnosis, because some hips are unstable, but not dislocated. The Barlow provocative maneuver allows the diagnosis of hip instability. Moreover, in children older than three months, the Ortolani maneuver may be negative, because even if the hip remains dislocated, it will be no longer possible to replace the femoral head into the acetabulum. With respect to the Barlow maneuver, it must be emphasized that many newborns tested positive in the first test become negative after two or three weeks.

In the dislocated hip the treatment consists concentric and atraumatic reduction of femoral head within the acetabulum. Before the start of walking, this treatment may be conservative, however, after the child begins to walk there is a tendency of interposition of soft tissues, such as the round ligament, labrum and capsule of this joint. Hence, it is necessary an open reduction. Once achieved, this reduction can be maintained by means of procedures on the acetabulum, soft tissue, or both. Lindstrom et al.⁷ showed that if the concentric reduction is achieved and maintained, there will be remodeling of the acetabulum that will be more pronounced up to four years, and may occur up to eight years.

Based on the joint mobility and stability in the presence of pain and/or lameness, Dutoit et al.⁶ developed a system of post-surgical clinical classification.

Severin⁵ developed a system of radiological classification of the results of surgical procedures for treatment of developmental dysplasia of the hip and evaluated deformities

Table 1 – Results of clinical evaluation according Dutoit.⁶

Treatment	Pre			Post		
	n	%	%	Nutrition	%	%
Dutoit						
1 – excellent	0	0.0		9	69.2	92.3
2 – good	0	0.0		3	23.1	
3 – regular	0	0.0	100.0	0	0.0	7.7
4 – poor	13	100.0		1	7.7	

Table 2 – Results of radiological evaluation according Severin⁵

Treatment	Pre			Post		
	n	%	%	n	%	%
Severin						
1 – excellent	0	0.0		6	46.1	69.2
2 – good	0	0.0		3	23.1	
3 – regular	2	15.4	100.0	0	0.0	30.8
4 – poor	9	69.2		4	30.8	
5 – poor	1	7.7		0	0.0	
6 – poor	1	7.7		0	0.0	

of the head/neck and acetabulum, with reference to the CE angle of Wiberg and presence of post-surgical subluxation/dislocation.

Salter et al.³ described an innominate osteotomy for the treatment of congenital hip dislocation and subluxation and promoted acetabular repositioning with the formation of a roof to support the femoral head after reduction. In their first report, Salter et al. evaluated 25 hips after follow-up of one to three years, and reported that all their patients achieved a good or excellent result.

Bohm et al.⁸ studied 63 hips treated with innominate osteotomy, with a median follow-up of 30.9 years; in 88.8% of cases, they achieved satisfactory radiological results, according to Severin index.

Tukenmez et al.⁹ evaluated 61 hips treated with Salter osteotomy and obtained satisfactory clinical and radiological results in 82% (Dutoit) and 94.5% (Severin) procedures, respectively, with an incidence of 21.5% of post-operative complications.

Carvalho Filho et al.¹⁰ evaluated 18 patients with DDH treated with Salter et al.'s osteotomy and obtained 72% satisfactory clinical results (Dutoit) and 81% favorable radiological outcomes (Severin); 16.6% of patients had post-operative redislocation inside the cast.

Of the 13 hips included in this study, we obtained satisfactory clinical and radiological results in 92.3% (Dutoit) and 69.2% (Severin), respectively. Thus, our findings agree with the results of other series.

Saleh et al.¹¹ have demonstrated absence of pelvic remodeling after innominate osteotomy in patients with skeletal maturity. In this study, the osteotomy was performed in patients between 1.9 and 6 years (age post-march), yet there was no influence on the clinical and radiographic results in the medium term, according to that described by Carvalho and Volpon Filho.²

Frequency, degree of disability, duration of symptoms and morbidity were taken into account. However, osteonecrosis is the most feared complication of treatment of DDH, and occurs only in patients who received some form of bloody or bloodless treatment, being regarded as a common cause of hip positioning in abduction >70° or in forced medial rotation. This can occur even in the normal hip opposite to that which is being treated. Therefore, hip immobilizations in an adequate position and a careful bloodless or bloody reduction in accordance with the basic principles, may decrease the risk of this serious complication. It should be borne in mind that, in this study, there were complications, such as two cases of isolated

subluxation, a case of osteonecrosis associated with subluxation, and one dislocation.

Conclusion

The association of Salter's osteotomy with open reduction and capsuloplasty becomes a viable option for the treatment of DDH after the child begins to walk, with satisfactory clinical and radiological results.

Conflicts of interest

The authors declare no conflicts of interest.

REFERENCES

1. Wynne-Davies R. Acetabular dysplasia and familial joint laxity: two etiological factors in congenital dislocation of the hip. A review of 589 patients and their families. *J Bone Joint Surg Br.* 1970;52(4):704-16.
2. Volpon JB, Carvalho Filho G. Luxação congênita do quadril no recém-nascido. *Rev Bras Ortop.* 1985;20(7):317-20.
3. Salter RB. Innominate osteotomy in treatment of congenital dislocation of the hip. *J Bone Joint Surg.* 1961;43:72-80.
4. Tachdjian MO. Dysplasia congenital of the hip. In: *Pediatric orthopaedics*. 2nd ed. Philadelphia: Saunders; 1990.
5. Severin E. Contribution to knowledge of congenital dislocation of hip joint: late results of closed reduction and arthrographic studies of recent cases. *Acta Chir Scand.* 1941;84:1-142.
6. Dutoit M, Moulin P, Morscher E. Salter's innominate osteotomy. 20 years later. *Chir Pediatr.* 1989;30(6):277-83.
7. Lindstrom JR, Ponseti IV, Wenger DR. Acetabular development after reduction in congenital dislocation of the hip. *J Bone Joint Surg Am.* 1979;61(1):112-8.
8. Böhm P, Brzuske A. Salter innominate osteotomy for the treatment of developmental dysplasia of the hip in children: results of seventy-three consecutive osteotomies after twenty-six to thirty-five years of follow-up. *J Bone Joint Surg Am.* 2002;84(2):178-86.
9. Tukenmez M, Tezeren G. Salter innominate osteotomy for treatment of developmental dysplasia of the hip. *J Orthop Surg (Hong Kong).* 2007;15(3):286-90.
10. Carvalho Filho G, Chueire AG, Helencar I, Carneiro MO, Francese Neto J, Carnesin AC. Tratamento cirúrgico da luxação congênita do quadril pós-marcha: redução aberta e osteotomia de Salter. *Acta Ortop Bras.* 2003;11(1):42-7.
11. Saleh JM, O'Sullivan ME, O'Brien TM. Pelvic remodeling after Salter osteotomy. *J Pediatr Orthop.* 1995;15(3):342-5.