

## **Gastric neoplasia misdiagnosed as an eating disorder**

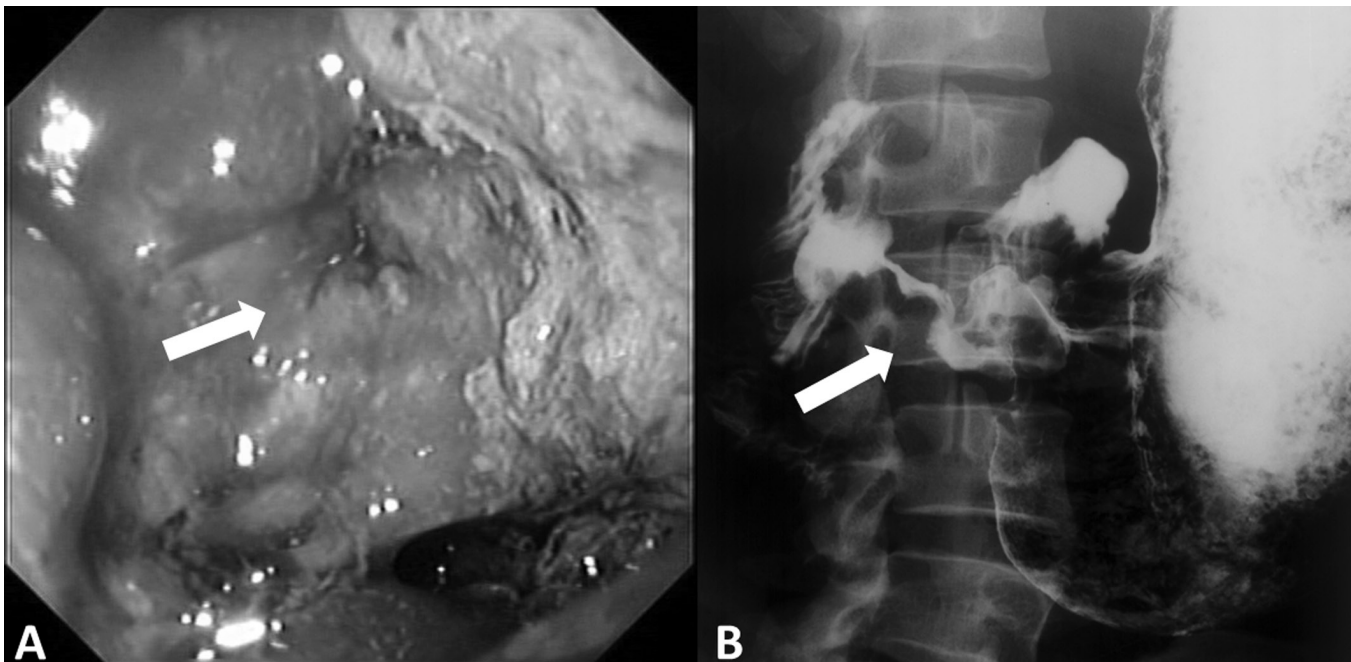
### ***Neoplasia gástrica diagnosticada por engano como transtorno do comportamento alimentar***

Dear Editor,

Except for typical anorexia and bulimia nervosa, the diagnosis of eating disorders is delayed, especially when symptoms such as abdominal pain, weakness or fatigue are prominent. On the other hand, a number of organic conditions may mimic the symptoms of an eating disorder including brain tumor<sup>1</sup>, inflammatory bowel disease, acid peptic diseases<sup>2</sup>, and gastrointestinal motility disorders such as achalasia<sup>3</sup>. Also, gastric cancer mimicking anorexia nervosa has rarely been reported<sup>4</sup>.

Case report

We describe the case of a 28-year-old female patient, a ballet teacher and professional dancer, who was hospitalized in March 2008 with a diagnosis of anorexia nervosa. Two years



**Figure 1:** A: Upper digestive endoscopy identifying an ulcerative lesion (arrow) in the stomach, edema, hyperemia and thick fibrine; B: Barium swallow exam displaying distended stomach, concentric stenosis of gastric antrum, pylorus and first portion of duodenum (arrow).

prior to hospitalization, she had been presenting episodes of spontaneous emesis after meals followed by an 18 kg weight loss. She underwent psychiatric evaluation and treatment, in which the diagnoses of anorexia nervosa and bipolar disorder were made (according to the patient's own statement). The weight had returned to the usual values (56 kg), even though emesis was still occasional and the patient interrupted the treatment nine months after being diagnosed. Five months prior to hospitalization, she presented a 20 kg weight loss (26% of her usual weight) and approximately 10 spontaneous emesis episodes per day, including during the night. She sought psychiatric treatment again, without improvement. She had also presented alopecia, intestinal constipation, excessive thirst and amenorrhea four months prior to hospitalization. Her work activities were interrupted one month prior to hospitalization due to feelings of sadness and weakness. On the day before hospitalization, she sought the emergency room with dehydration, when she was directed to our facilities.

The patient never met her father and had thus been raised by her grandparents after being abandoned by her mother. She tried to commit suicide at ages 14, 16, and 21. She denied using alcohol, tobacco, illegal drugs, laxatives, diuretics or amphetamines. At the time we made our evaluation, she had no self-image distortion issues and denied self-induced vomiting or feelings of guilt after feeding. She presented drastic body mass index reduction (BMI = 16.6 kg/m<sup>2</sup>) and no signs of respiratory, cardiological, abdominal or neurological disorders in the physical examination. The biochemical data were normal, except for discrete iron-deficiency anemia and

hypoproteinemia. Her upper digestive endoscopy identified an obstructive and ulcerative lesion in the pylorus and the barium swallow exam revealed an infiltrating lesion in the antrum-pylorus (Figure 1). Histological examination of the pylorus biopsy specimen revealed a mixed pattern of Lauren's intestinal and gastric adenocarcinoma. During 10 days, the patient received enteral nutrition by nasogastric tube, with its distal portion positioned below the obstructive lesion. A subtotal gastrectomy and a Roux-Y gastric reconstruction was performed, with emesis remission, weight gain and anemia correction. She returned to work three months after the surgical procedure.

#### Discussion

This case report describes a patient whose clinical history might mislead to an eating disorder diagnosis. Eating disorders are diagnoses often taken into consideration in young women who present with unexplained weight loss and vomiting. The patient presented some eating disorder risk factors, such as being a female, presenting amenorrhea, familiar instability and previous history of psychiatric disorders. Furthermore, she is a ballet teacher and performer, and thus lives in a situation in which there is social pressure to keep body weight under control. Eating disorders are more prevalent in high-performance athletes, and may affect 31% of dancers<sup>5</sup>. These epidemiological data, the initial clinical improvement and the interruption of the treatment may have induced physicians not to perform a gastrointestinal investigation, which resulted in an anorexia nervosa misdiagnosis.

This late diagnosis could have been avoided by excluding organic diseases as the cause of vomiting and weight loss and by applying the diagnostic criteria for eating disorders. Differentiating eating disorders from primary gastrointestinal diseases may be difficult. After review of the charts of 987 patients who had been referred to a tertiary care eating disorders program over a 20-year period, 33 (3.3%) were identified as having no eating disorders, 8 of which had a medical diagnosis<sup>6</sup>. In this report, the patient did not present some of the essential criteria for an eating disorder diagnosis, such as morbid or intense fear of gaining weight, self-body image distortion, feeding compulsion or self-induced emesis<sup>7</sup>. However, we cannot dismiss the possibility that the patient presented true bulimia at the beginning of the disease, considering the long-term evolution (two years) in the vomiting episodes. This case displays a rare occurrence of gastric neoplasia<sup>4</sup> misdiagnosed as

an eating disorder.

**Guilherme Araújo Teixeira**

Department of Internal Medicine, Faculty of Medicine of Ribeirão Preto, University of São Paulo, Ribeirão Preto, São Paulo, Brazil.

**Júlio Sérgio Marchini**

Division of Nutrology, Department of Internal Medicine, Faculty of Medicine of Ribeirão Preto, University of São Paulo, Ribeirão Preto, São Paulo, Brazil.

**Selma Freire de Carvalho da Cunha**

Division of Nutrology and Nutrition and Metabolism Course, Department of Internal Medicine, Faculty of Medicine of Ribeirão Preto, University of São Paulo, Ribeirão Preto, São Paulo, Brazil.

**Disclosures**

Writing group member	Employment	Research grant <sup>1</sup>	Other research grant or medical continuous education <sup>2</sup>	Speaker's honoraria	Ownership interest	Consultant/ Advisory board	Other <sup>3</sup>
Guilherme Araújo Teixeira	HCFMRP-USP	-	-	-	-	-	-
Júlio Sérgio Marchini	HCFMRP-USP	-	-	-	-	-	-
Selma Freire C. da Cunha	HCFMRP-USP	-	-	-	-	-	-

\* Modest

\*\* Significant

\*\*\* Significant: Amounts given to the author's institution or to a colleague for research in which the author has participation, not directly to the author.

HCFMRP-USP: Hospital das Clínicas da Faculdade de Medicina de Ribeirão Preto – Universidade de São Paulo

**References**

1. Winston AP, Barnard D, D'Souza G, Shad A, Sherlala K, Sidhu J, Singh SP. Pineal germinoma presenting as anorexia nervosa: Case report and review of the literature. *Int J Eat Disord.* 2006;39(7):606-8.
2. McClain CJ, Humphries LL, Hill KK, Nickl NJ. Gastrointestinal and nutritional aspects of eating disorders. *J Am Coll Nutr.* 1993;12(4):466-74.
3. Garcia Júnior C, Araújo OFG, Murro ALB, Traballi ALM, Andreollo NA. Idiopathic achalasia mistakenly diagnosed as anorexia nervosa. *Rev Bras Psiquiatr.* 2008;30(2):168.
4. Siew LC, Huang C, Fleming J. Gastric adenocarcinoma mistakenly diagnosed as an eating disorder: case report. *Int J Eat Disord.* 2010;43(3):286-8.
5. Ringham R, Klump K, Kaye W, Stone D, Libman S, Stowe S, Marcus M. Eating disorder symptomatology among ballet dancers. *Int J Eat Disord.* 2006;39(6):503-8.
6. Su JC, Birmingham CL. Differential diagnoses to consider at an eating disorders clinic. *Eat Weight Disord.* 2003;8(4):311-4.
7. Hay PJ. Epidemiologia dos transtornos alimentares: estado atual e desenvolvimentos futuros. *Rev Bras Psiquiatr.* 2002;24 (Supl.3):13-7.