

Hepatic coccidiosis in *Serrasalmus rhombeus* Linnaeus, 1766 from the Amazon basin: morphological and histopathological aspects

Coccidiose hepática em *Serrasalmus rhombeus* Linnaeus, 1766 da Amazônia paraense: aspectos morfológicos e histopatológicos

Jhonata Eduard Farias de Oliveira¹; Rayline Thaimenne Alves Figueredo²; José Ledamir Sindeaux-Neto³; Maria do Perpétuo Socorro Progene Vilhena⁴; José Francisco Berrêdo⁵; Edilson Matos^{1,3}; Michele Velasco^{6*} 

¹ Programa de Pós-graduação em Aquicultura e Recursos Aquáticos Tropicais, Universidade Federal Rural da Amazônia – UFRA, Belém, PA, Brasil

² Programa de Pós-graduação em Biologia Animal, Universidade Estadual de Campinas – UNICAMP, Campinas, SP, Brasil

³ Laboratório de Pesquisa Carlos Azevedo, Universidade Federal Rural da Amazônia – UFRA, Belém, PA, Brasil

⁴ Universidade Federal Rural da Amazônia – UFRA, Tomé-Açu, PA, Brasil

⁵ Museu Paraense Emílio Goeldi, Belém, PA, Brasil

⁶ Universidade Federal Rural da Amazônia – UFRA Campus Paragominas, Paragominas, PA, Brasil

How to cite: Oliveira JEF, Figueredo RTA, Sindeaux-Neto JL, Vilhena MPSP, Berrêdo JF, Matos E, et al. Hepatic coccidiosis in *Serrasalmus rhombeus* Linnaeus, 1766 from the Amazon basin: morphological and histopathological aspects. *Braz J Vet Parasitol* 2021; 30(1): e026120. <https://doi.org/10.1590/S1984-29612021007>.

Abstract

Calyptospora species are coccids that commonly cause liver infections in fish all around the world. This paper describes the morphology and histopathological characteristics of liver infection caused by *Calyptospora* sp. in black piranha *Serrasalmus rhombeus*, from the Capim River, in the municipality of Ipixuna do Pará, state of Pará (Brazil). Specimens were collected, analyzed and necropsied and tissue fragments containing parasites were prepared for histology and scanning electron microscopy. Parasitism was detected in 33.0% of the analyzed specimens, which had spherical oocysts in the liver, with four pyriform sporocysts presenting sporozoites internally. A histological examination revealed oocysts positioned close to blood vessels, causing necrosis and degeneration of hepatic parenchyma, while the presence of mononuclear cell infiltrate and melanomacrophages indicated the onset of an inflammatory process. This is the first record of the genus *Calyptospora* in fish from the Capim River.

Keywords: Amazon basin, *Calyptospora*, histopathology, piranha.

Resumo

Calyptosporídeos são coccídeos constantemente encontrados causando infecções hepáticas em peixes de todo o planeta. Este estudo descreve a morfologia e características histopatológicas da infecção hepática causada por *Calyptospora* sp. encontrados em *Serrasalmus rhombeus*, a piranha negra, oriunda do rio Capim, em Ipixuna do Pará, Brasil. Os animais foram coletados, analisados e necropsiados; fragmentos teciduais com a presença dos parasitos foram processados para histologia e microscopia eletrônica de varredura. O parasitismo ocorreu em 33,0% dos espécimes analisados, onde foram encontrados oocistos esféricos no fígado, com esporocistos piriformes, apresentando internamente esporozoítos. No exame histológico, os oocistos estavam dispostos próximos aos vasos sanguíneos, causando necrose e degeneração do parênquima hepático; a presença de infiltrado de células mononucleares e melanomacrófagos indicaram o início de um processo inflamatório. Este é o primeiro registro do gênero *Calyptospora* em peixes do rio Capim.

Palavras-chave: Amazônia, *Calyptospora*, histopatologia, piranha.

Received November 10, 2020. Accepted January 21, 2021.

Financial support: Scholarship PQ 1 D CNPq Process 310068 / 2019-3 and PVNS UNIFAP / CAPES Process 8887.314368/2019-00.

*Corresponding author: Michele Velasco Oliveira da Silva. E-mail: michele.velasco.mv@gmail.com



This is an Open Access article distributed under the terms of the Creative Commons Attribution License, which permits unrestricted use, distribution, and reproduction in any medium, provided the original work is properly cited.

Introduction

Coccids, a subclass of the phylum Apicomplexa, are intracellular parasites that have a wide variety of host fish, from Chondrichthyes (elasmobranches) to Osteichthyes, which are represented by freshwater and saltwater teleosts that occur worldwide (Dyková & Lom, 1981; Davies & Ball, 1993; Molnár, 2006). In fact, there is phylogenetic evidence that coccids of terrestrial vertebrate emerged from fish coccidian strains (Rosenthal et al., 2016).

The family Calyptosporidae is represented by species with a heteroxenous life cycle, where by the oocysts are transmitted from the intermediate host, an invertebrate, to the definitive host, the fish (Overstreet et al., 1984; Whipps et al., 2012). The genus *Calyptospora* Overstreet, Hawkins and Fournie, 1984 is known to cause mainly liver pathologies, but it can also be found in the pancreas, gallbladder, mesentery, gonads and other tissues (Overstreet & Hawkins, 2017; Ramos et al., 2018; Negrão et al., 2019).

Five species are currently described in Brazil: *Calyptospora tucunarensis* (Békési & Molnár, 1991), *Calyptospora spinosa* (Azevedo et al., 1993), *Calyptospora serrasalmi* (Cheung et al., 1986), *Calyptospora gonzaguensis* (Silva et al., 2020) and *Calyptospora paranaidji* (Da Silva et al., 2019), and four of them are reported in fish from the Amazon basin. According to Da Silva et al. (2019), this region has great potential for the discovery of new calyptosporid species.

Serrasalmus rhombeus Linnaeus, 1766 stands out among the ichthyofauna of the Amazon basin. Commonly known as black or red-eyed piranha, its carnivorous habits render it notoriously aggressive. This species is part of the family Serrasalmidae, endemic to South America, usually found in northeastern Brazil and in rivers of the Amazon basin, which local communities sell as ornamental fish (Nakayama et al., 2001; Acácio et al., 2012; Sá-Oliveira et al., 2017; Anjos et al., 2018).

This paper describes the morphology of *Calyptospora* sp. and histopathological aspects of hepatic coccidiosis in *S. rhombeus*, captured in the Capim River, in the northeast of the state of Pará, eastern Amazonia.

Material and Methods

Collection and analysis of specimens

Serrasalmus rhombeus specimens were collected (under SISBIO/ICMBio Permit No. 62276-1) in the Capim River close to the “Ribeira” community (2°66'67”S, 48°32'34”W), located in the municipality of Ipixuna do Pará, in the northeastern part of the state of Pará (PA). Collection efforts extended from April 2018 to March 2019. Captured live specimens were placed in aerated plastic bags and taken to the Carlos Azevedo Research Laboratory at the Federal Rural University of Amazonia (UFRA), Belém, PA.

The fish were anesthetized using the MS-222 protocol (50 mg/L tricaine methanesulfonate) and then necropsied, as authorized by the institution's Ethics Committee on Animal Use, under Protocol No. 011/2014). A parasitology examination was performed using a stereomicroscope to search for lesions/cysts on the body surface and in the coelomic cavity, and the findings were confirmed under an ordinary light microscope (LM), using fresh slides.

Histology

Were small fragments of parasitized liver tissue were fixed in Davidson's fluid for a period of 24 hours, processed using paraffin techniques, 5 µm thick cut and stained with Hematoxylin-Eosin (HE) and Zielh-Neelsen (ZN) (Luna, 1968).

Oocyst morphometry

Mature oocysts (n=30) were measured from images captured by a Zeiss Axiocam ICc 1 camera installed in a Zeiss Axioskop 40 microscope. Means and standard deviations were measured in micrometers (µm). A morphometric comparison was made with other species described in the literature, using principal component analysis (PCA), and analyzing the following parameters: oocyst diameter (OD), sporocyst length and width (SL) and the length-to-width ratio of oocyst to sporocyst (L:W), as described by Da Silva et al. (2019) for *Calyptospora*. The hierarchical clustering method UPGMA was also adopted. Both analyses were performed using PAST 3.0 software (Hammer et al., 2001).

Scanning Electron Microscopy (SEM)

Fragments of parasitized liver tissue were fixed in 5% glutaraldehyde buffered with sodium cacodylate at pH 7.2 for 12h at 4°C. They were then washed in buffer solution, fixed in 2% OsO₄ and buffered for three hours without

varying the temperature. After this, the fragments were dehydrated in increasing ethanol and propylene oxide series, coated with a thin layer of gold and photographed in a TESCAN MIRA3 FEG-SEM field emission scanning electron microscope at the Emílio Goeldi Museum in Belém, state of Pará (Brazil).

Results

Spherical oocysts, showing characteristics inherent to the genus *Calyptospora*, were found in the liver of 05 of the 15 analyzed *S. rhombeus* specimens, representing 33.0% of the specimens.

The oocysts had a diameter of 17.4 ± 1.0 (15.7-19) (Figure 1A, 2B and 3A), with four pyriform sporocysts in the shape of “bowling pins” (Figure 1B, 2A and B), 8.33 ± 1.1 (6- 10) in length and 4.29 ± 0.83 (3-4.68) in width. The oocysts, which were arranged perpendicularly and covered by a thin membranous veil-like layer, and in the internal region of the sporocysts, two sporozoites were present (Figure 1C and 3A). A suture was visible in the apical region of the external surface (Figure 2B and D, 3B), while the posterior part contained several lateral projections, the sporopods (Figure 2C, 3B). These morphological traits are characteristic of the genus *Calyptospora* (Overstreet et al., 1984).

The first two axes in the PCA, which explained 92.1% of the variance, were influenced mainly by the length-to-width ratio of oocyst to sporocyst. The *Calyptospora* sp. identified in this study was similar to *Calyptospora* sp. 4 and *C. gonzaguensis*, although this relationship was negative to the other species on both axes (Figure 4). This aspect was confirmed in the similarity dendrogram, indicating that the Euclidean distance between *Calyptospora* sp. 4 and *C. gonzaguensis* was smaller, compared to *Calyptospora* sp. (Figure 5).

The histological results revealed oocyst clusters close to blood vessels in the hepatic parenchyma (Figure 6 A – F), showing tissue degeneration, localized liver fibrosis and compression necrosis, with hepatic cells exhibiting pyknotic nuclei and lacey cytoplasm (Figure 6A and 6D). Note the presence of mononuclear cell infiltrates surrounded the oocysts, indicating a mild inflammatory process (Figure 6A and 6C), as well as melanomacrophages in both types of stains (Figure 6B and 6F).

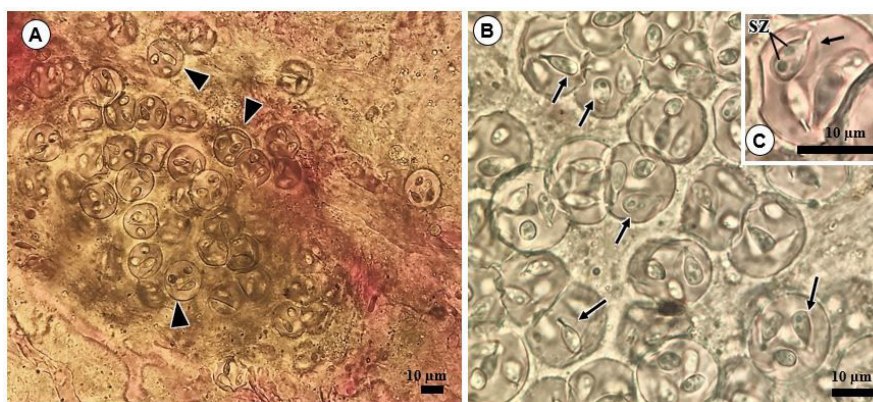


Figure 1. Light microscope images of infection by *Calyptospora* sp. in *Serrasalmus rhombeus*. A: Clusters of *Calyptospora* sp. oocysts in the liver; B: The arrowhead indicates sporocysts inside oocysts; C: Highlight of the sporocyst structure, with sporozoites (SZ) and membranous veil (arrowhead).

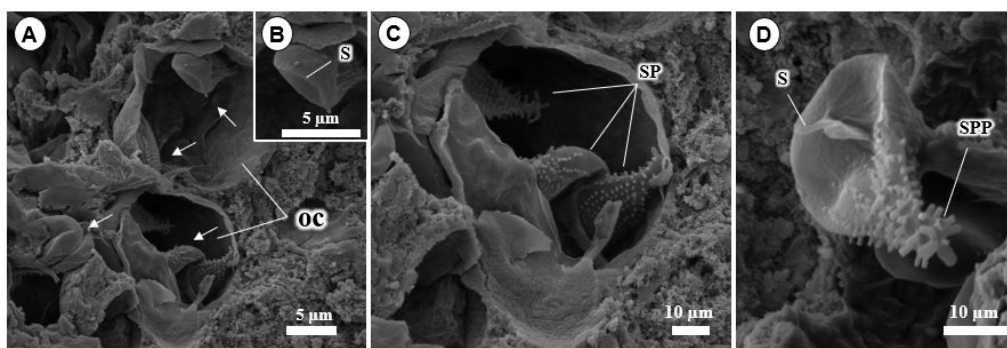


Figure 2. Scanning electron microscopy micrographs of *Calyptospora* sp. in the liver of *Serrasalmus rhombeus*. A: Oocysts (oc) composed of 4 sporocysts (arrow). B-D: Sporocyst (sp), with emphasis on the suture (s) and sporopods (spp).

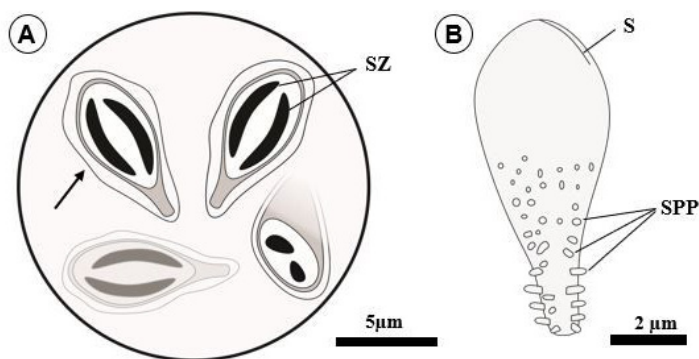


Figure 3. Schematic drawings of the oocyst and sporocyst, respectively. A: Oocyst containing 4 sporocysts, each surrounded by a membranous veil (arrow) and containing two sporozoites (sz); B: Details of the external structure of the sporocysts, with the presence of a suture (s) and sporopods (spp).

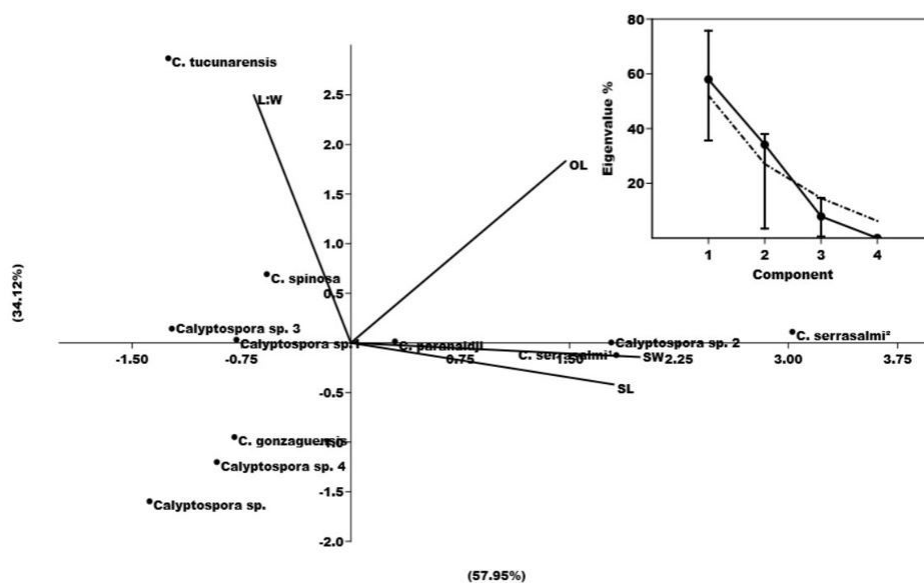


Figure 4. Principal component analysis (PCA). Oocyst length (OL); Sporocyst length (SL); length-to-width ratio of oocyst to sporocyst (L:W).

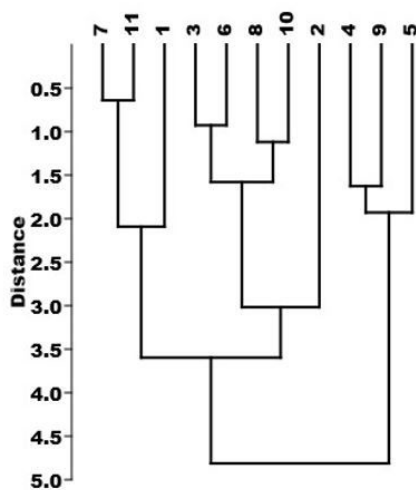


Figure 5. Dendrogram of similarity. 1- *Calyptospora* sp.; 2- *C. tucunarensis*; 3- *C. spinosa*; 4- *C. serrasalmi* ¹; 5- *C. serrasalmi* ²; 6- *C. paranaidji*; 7- *C. gonzaguensis*; 8- *Calyptospora* sp.¹; 9- *Calyptospora* sp.²; 10- *Calyptospora* sp.³; 11- *Calyptospora* sp.⁴

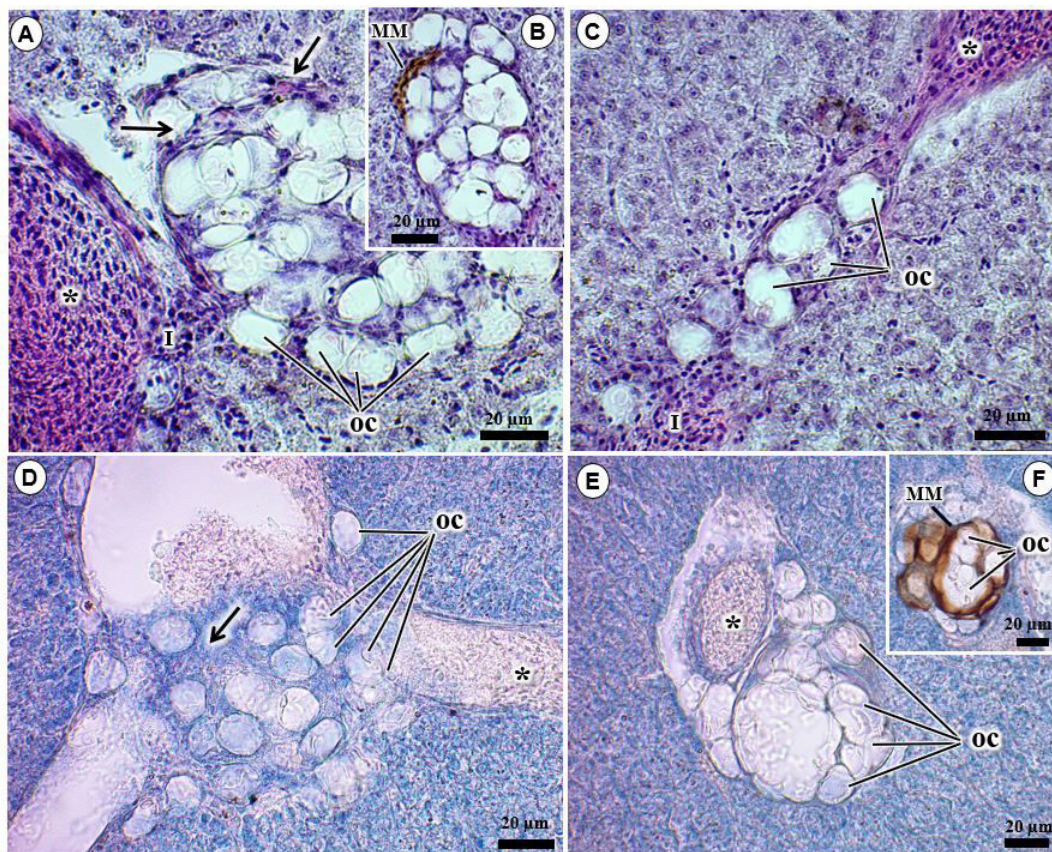


Figure 6. Histological sections of *Serrasalmus rhombeus* liver infected by *Calyptospora* sp. Oocysts (OC) disseminated in the liver tissue close to blood vessels (*), with the presence of fibroblasts (arrowhead) and mononuclear cell infiltrate (I) (6A, C and E). 6B and 6F indicate melanomacrophages (MM) around oocysts. 6D reveals widespread necrosis, liver degeneration (arrowhead), and the presence of red blood cells (*) in microphotographs of ZN stained tissue.

Discussion

The parasite prevalence rate found in this study is lower than other infections by *Calyptospora*, which were reported in *Cichla temensis* Heckel, 1840 (56.0%) (Santiago et al., 2012), *Brachyplatystoma vaillantii* Valenciennes, 1940 (60.0%) (Silva et al., 2012), *Crenicichla lepidota* Heckel, 1840 (63.0%) (Azevedo et al., 1993), *Cichla ocellaris* Bloch & Schneider, 1801 (100%) (Békési & Molnár, 1991) and 100% in carnivorous species collected by Negrão et al. (2019).

Calyptosporids have already been described causing liver infections in *Serrasalmus niger*, *Serrasalmus striolatus* and *S. rhombeus*, the host species in this study, presenting specificity for *Calyptospora serrasalmi* (Cheung et al., 1986; Casal et al., 2007; Whipps et al., 2012; Negrão et al., 2019). The spherical shape of oocysts, pyriform shape of sporocysts, and lateral extension of the sporopods were similar to this species. However, the morphometric comparisons showed greater proximity to *Calyptospora* sp. 4 found in *Arapaima gigas* (Bonar et al., 2006) and *C. gonzaguensis* described in *Triporthus angulatus* (Silva et al., 2020), which were particularly congruent with the diameter of the oocysts, of 19 μm and 19.6 μm, respectively (Table 1).

The histopathological examination revealed oocyst clusters in the liver parenchyma adjacent to blood vessels. This is a typical histopathological finding of *Calyptospora* and has been described in several studies (Békési & Molnár, 1991; Ramos et al., 2018; Velasco et al., 2012; Santiago et al., 2012). However, minor variations occur, with some species showing tropism only in blood vessels, as observed in *C. gonzaguensis*, or only in the liver parenchyma, such as *C. paranaidji* (Silva et al., 2020; Da Silva et al., 2019).

In more intense infections, the liver changes to a visibly lighter color (Videira et al., 2013; Velasco et al., 2012), resulting from the degeneration of liver tissue. As the oocysts proliferate, they cause inflammation and formation of granulomas coated with fibrous tissue (Ramos et al., 2018; Fournie & Overstreet, 1993; Solangi & Overstreet, 1980). According to Azevedo et al. (1993), the damage caused by *Calyptospora* becomes more evident at the cellular level, with cells adjacent to the oocysts presenting morphological changes such as hypertrophy and destruction of cytoplasmic structures. Similar results were found in this study.

Table 1. Morphometric comparison of *Calyptospora* spp. oocysts and sporocysts described in fish species from Brazil.

Species	OD	L:W	Shape	Sporocyst (µm)		CS/IS	References
				Length	Width		
<i>Calyptospora</i> sp.	17.4 (1.0)	2.1	Pyriform	8.3 (1.1)	4.3 (0.8)	Pará/Liver	This study
<i>Calyptospora tucunarensis</i>	24.3 (2.1)	2.9	Ellipsoidal	8.3 (1.3)	3.7 (1.1)	Ceará/Liver	(Békési & Molnár, 1991)
<i>Calyptospora spinosa</i>	22.3 (1.6)	2.4	Ellipsoidal	9.3 (0.4)	3.8 (0.4)	Pará/Liver, Gonads and ovary.	(Azevedo et al., 1993)
<i>Calyptospora serrasalmi</i> ¹	23.5 (2.1)	2.2	Pyriform	10.7 (1.1)	5.5 (0.5)	Amazonas and Pernambuco/Liver	(Cheung et al., 1986)
<i>Calyptospora serrasalmi</i> ²	25.4 (0.6)	2.2	Pyriform	11.7 (1)	5.9 (0.4)	Pará/Liver	(Casal et al., 2007)
<i>Calyptospora paranaidji</i>	22.1 (1.5)	2.3	Pyriform	9.7 (0.5)	4.6 (0.6)	Maranhão/Liver	(Da Silva et al., 2019)
<i>Calyptospora gonzaguensis</i>	19.6 (1.4)	2.1	Pyriform	9.2 (0.6)	3.9 (0.2)	Maranhão/Liver, gall bladder and fatty tissue	(Silva et al., 2020)
<i>Calyptospora</i> sp. 1	20.8	2.3	Pyriform	8.9	4.1	Pará/Liver	(Silva et al., 2012)
<i>Calyptospora</i> sp. 2	24.5	2.1	Ellipsoidal	11.5	4.5	Minas Gerais /Liver and Intestines	(Albuquerque & Brasil-Sato, 2010)
<i>Calyptospora</i> sp. 3	21.2	2.3	Pyriform	9.2	3.1	Manaus/ Hepatopancreas	(Santiago et al., 2012)
<i>Calyptospora</i> sp. 4	19.0	2.1	Pyriform	9	4	Brazil/ Liver	(Bonar et al., 2006)

Note: Oocyst Diameter (OD); length-to-width ratio of oocyst to sporocyst (L:W); Collection Site (CS); Infection Site (IS).

Inflammatory infiltrate and the presence of mononuclear cells surrounding the oocysts were also described by Velasco et al. (2012), Ramos et al. (2018) and Santiago et al. (2012). Melanomacrophages were also found close to oocysts. These phagocytic cells belong to the host's innate immune system and are a common cell type usually found in fish liver infections. In such infections, these cells are part of the reticuloendothelial system and their function is to eliminate pathogens that use the bloodstream to reach the target organ/tissue where their life cycle is completed (Agius, 1985; Steinel & Bolnick, 2017).

Susceptibility to parasitism, as well as the degree of pathogenicity, may depend on ecological factors, as was observed in an experiment with induced *C. funduli* infections in Atheriniformes fish, where environmental conditions and geographical isolation acted as barriers to the prevalence of parasites in each species (Fournie et al., 2000).

The histopathological data indicated that although the prevalence of parasitism by *Calyptospora* sp. was not high, significant pathological changes occurred in the host's liver tissue. These changes may give rise to functional abnormalities in the liver, threatening the host's survival in nature.

Acknowledgements

The authors gratefully acknowledge the financial support of CAPES, Brazil's Federal Agency for the Support and Improvement of Higher Education and the Federal Rural University of Amazonia – UFRA for enabling this study.

References

- Acácio M, Varella ÂMB, Malta JCO. The parasitic crustaceans of *Serrasalmus rhombeus* (Linnaeus, 1776) (Characiformes: Serrasalminidae) from floodplain lakes of the Solimões River, Central Amazon, Brazil. *Neotrop Helminthol* 2012; 6(2): 179-184.
- Agius C. The melano-macrophage centres of fish: a review. In: Manning MJ, Tatner MF. *Fish Immunology*. 1st ed. Cambridge: Academic Press; 1985. p. 85-105. <http://dx.doi.org/10.1016/B978-0-12-469230-5.50011-8>.

- Anjos HDB, Amorim RMS, Siqueira JA, Anjos CR. Ornamental fish export of the State of Amazonas, Amazon Basin, Brazil. *Bol Inst Pesca* 2018; 35(2): 259-274.
- Azevedo C, Matos P, Matos E. Morphological data of *Calyptospora spinosa* n. sp. (Apicomplexa, Calyptosporidae) parasite of *Crenicichla lepidota* Heckel, 1840 (Teleostei) from Amazon River. *Eur J Protistol* 1993; 29(2): 171-175. [http://dx.doi.org/10.1016/S0932-4739\(11\)80270-1](http://dx.doi.org/10.1016/S0932-4739(11)80270-1). PMID:23195539.
- Albuquerque MC, Brasil-Sato MC. First report of *Calyptospora* sp. (Apicomplexa, Calyptosporidae) in forage characid fish from the Três Marias Reservoir, São Francisco Basin, Brazil. *Eur J Protistol* 2010; 46(2): 150-152. <http://dx.doi.org/10.1016/j.ejop.2009.12.005>. PMID:20163938.
- Békési L, Molnár K. *Calyptospora tucunarensis* n. sp. (Apicomplexa: Sporozoa) from the liver of tucunare *Cichla ocellaris* in Brazil. *Syst Parasitol* 1991; 18(2): 127-132. <http://dx.doi.org/10.1007/BF00017665>.
- Bonar CJ, Poynton SH, Schulman FY, Rietschek RL, Garner MM. Hepatic *Calyptospora* sp. (Apicomplexa) infection in a wild-born, aquarium-held clutch of juvenile arapaima *Arapaima gigas* (Osteoglossidae). *Dis Aquat Organ* 2006; 70(1-2): 81-92. <http://dx.doi.org/10.3354/dao070081>. PMID:16875394.
- Casal G, Padovan I, Matos E, Padovan P, Matos P, Guimarães A, et al. Morphological and ultrastructural redescription of *Calyptospora serrasalmi* Cheung, Nigrelli & Ruggieri, 1986 (Apicomplexa: Calyptosporidae), a parasite found in two new host species of the genus *Serrasalmus*. *Braz J Morphol Sci* 2007; 101(1): 11-16.
- Cheung PJ, Nigrelli RF, Ruggieri GD. *Calyptospora serrasalmi* sp. nov. (Coccidia: Calyptosporidae) from liver of the black piranha, *Serrasalmus niger* Schomburgk. *J Aquaricult Aquat Sci* 1986; 4(3): 54-57.
- Da Silva MF, Da Silva DT, Giese EG, Hamoy IG, Matos E. Morphology and Phylogeny of *Calyptospora paranaidji* n. sp. (Eimeriorina: Calyptosporidae), an Apicomplexan Parasite of the Hepatic Tissue of *Cichla piquiti* Kullander & Ferreira, 2006, From a Reservoir in the Brazilian Amazon Region. *J Eukaryot Microbiol* 2019; 66(4): 608-616. <http://dx.doi.org/10.1111/jeu.12707>. PMID:30548108.
- Davies AJ, Ball SJ. The biology of fish coccidia. In: Baker JR, Muller R. *Advances in parasitology*. 1st ed. Cambridge: Academic Press; 1993. p. 293-366.
- Dyková I, Lom J. Fish coccidia: critical notes on life cycles, classification and pathogenicity. *J Fish Dis* 1981; 4(6): 487-505. <http://dx.doi.org/10.1111/j.1365-2761.1981.tb01161.x>.
- Fournie JW, Overstreet RM. Host Specificity of *Calyptospora funduli* (Apicomplexa: Calyptosporidae) in Atheriniform Fishes. *J Parasitol* 1993; 79(5): 720-727. <http://dx.doi.org/10.2307/3283611>. PMID:8410544.
- Fournie JW, Vogelbein WK, Overstreet RM, Hawkins WE. Life cycle of *Calyptospora funduli* (Apicomplexa: calyptosporidae). *J Parasitol* 2000; 86(3): 501-505. [http://dx.doi.org/10.1645/0022-3395\(2000\)086\[0501:LCOFA\]2.0.CO;2](http://dx.doi.org/10.1645/0022-3395(2000)086[0501:LCOFA]2.0.CO;2). PMID:10864246.
- Hammer Ø, Harper DAT, Ryan PD. PAST: Paleontological statistics software package for education and data analysis. *Paleontol Electronic* 2001; 4(1):1-9.
- Luna LG. *Manual of histologic staining methods of the Armed Forces Institute of Pathology*. New York: McGraw-Hill; 1968.
- Molnár K. Phylum apicomplexa. In: Woo PTK, Leatherland JF. *Fish diseases and disorders*. 2nd ed. Cambridge: Cabi; 2006. <http://dx.doi.org/10.1079/9780851990156.0183>.
- Nakayama C, Jégu M, Porto JIR, Feldberg E. Karyological Evidence for a Cryptic Species of Piranha within *Serrasalmus rhombeus* (Characidae, Serrasalminae) in the Amazon. *Copeia* 2001; 2001(3): 866-869. [http://dx.doi.org/10.1643/0045-8511\(2001\)001\[0866:KEFACS\]2.0.CO;2](http://dx.doi.org/10.1643/0045-8511(2001)001[0866:KEFACS]2.0.CO;2).
- Negrão MCS, Silva MRL, Videira MN, Viana LA. Prevalence and molecular characterisation of *Calyptospora* parasites Overstreet, Hawkins and Fournié, 1984 (Apicomplexa: Calyptosporidae) in fishes from the eastern Amazon, Brazil. *Parasitol Int* 2019; 73: 101975. <http://dx.doi.org/10.1016/j.parint.2019.101975>. PMID:31421267.
- Overstreet RM, Hawkins WE, Fournie JW. The Coccidian Genus *Calyptospora* n. g. and Family Calyptosporidae n. fam. (Apicomplexa), with Members Infecting Primarily Fishes. *J Protozool* 1984; 31(2): 332-339. <http://dx.doi.org/10.1111/j.1550-7408.1984.tb02972.x>.
- Overstreet RM, Hawkins WE. Diseases and mortalities of fishes and other animals in the Gulf of Mexico. In: Ward C. *Habitats and biota of the Gulf of Mexico: Before the Deepwater Horizon oil spill*. 1st ed. New York: Springer; 2017. p. 1589-1738. http://dx.doi.org/10.1007/978-1-4939-3456-0_6.
- Ramos ABMA, Santos PFS, Hemeterio LCA, Santos WJP, Araújo RS, Matos EM. Coccidiose hepática em *Aspistor quadriscutis*, Valenciennes, 1840 (Teleostei: Ariidae) capturados no estuário do nordeste paraense, Amazônia, Brasil. *Arch Vet Sci* 2018; 23(3): 63-67. <http://dx.doi.org/10.5380/avs.v23i3.52244>.
- Rosenthal BM, Dunams-Morel D, Ostoros G, Molnár K. Coccidian parasites of fish encompass profound phylogenetic diversity and gave rise to each of the major parasitic groups in terrestrial vertebrates. *Infect Genet Evol* 2016; 40: 219-227. <http://dx.doi.org/10.1016/j.meegid.2016.02.018>. PMID:26911642.

- Santiago H, Corrêa JL, Tortelly R, Menezes RC, Matos P, Matos E. Morphology and histopathology of *Calyptospora* sp. (Apicomplexa: Calyptosporidae) in speckled peacock bass, *Cichla temensis* Humboldt, 1821 (Perciformes: Cichlidae), from the Marajó-Açu River, Marajó Island, Brazil. *Parasitol Res* 2012; 110(6): 2569-2572. <http://dx.doi.org/10.1007/s00436-011-2770-0>. PMID:22200958.
- Sá-Oliveira JC, Ferrari SF, Vasconcelos HCG, Araujo AS, Campos CEC, Mattos-Dias CAG, et al. Resource Partitioning between Two Piranhas (*Serrasalmus gibbus* and *Serrasalmus rhombeus*) in an Amazonian Reservoir. *Sci World J* 2017; 2017: 9. <http://dx.doi.org/10.1155/2017/8064126>. PMID:29359177.
- Silva MC, Clemente SCS, Júnior JAP, Silva MVO, Matos ER. *Calyptospora* sp. in *Brachyplatystoma vaillantii* trapped at the Vigia, State of Pará, Brazil. *Rev Bras Parasitol Vet* 2012; 21(2): 176-178. <http://dx.doi.org/10.1590/S1984-29612012000200020>. PMID:22832762.
- Silva MF, Orlanda JFF, Araújo-Costa MJ, Hamoy I, Matos E. Hepatic coccidiosis in *Triporthes angulatus* Spix & Agassiz, 1829 (Characiformes: Triporthidae), a tropical fish from the eastern Brazilian Amazon, with the description of a new species of *Calyptospora* (Apicomplexa: Calyptosporidae). *J Eukaryot Microbiol* 2020; 67(3): 352-358. <http://dx.doi.org/10.1111/jeu.12785>. PMID:31943507.
- Solangi MA, Overstreet RM. Biology and Pathogenesis of the Coccidium *Eimeria funduli* Infecting Killifishes. *J Parasitol* 1980; 66(3): 513-526. <http://dx.doi.org/10.2307/3280757>. PMID:7391893.
- Steinel NC, Bolnick DI. Melanomacrophage centers as a histological indicator of immune function in fish and other poikilotherms. *Front Immunol* 2017; 8: 827. <http://dx.doi.org/10.3389/fimmu.2017.00827>. PMID:28769932.
- Velasco M, Videira M, Matos P, São Clemente SC, Sanches O, Matos E. Morfologia e nova ocorrência de um coccídio hepatopancreático parasita de peixe amazônico. *Amazon J Agric Envir Sci* 2012; 55(3): 231-235. <http://dx.doi.org/10.4322/rca.2012.063>.
- Videira M, Velasco M, Tortelly R, Menezes RC, São Clemente SC, Matos E. An anatomopathological study of hepatic coccidiosis (*Calyptospora* sp.) in the Acará-pixuna, *Aequidens plagiozonatus* Kullander, 1984 from the Brazilian state of Pará. *Arq Bras Med Vet Zootec* 2013; 65(1): 91-94. <http://dx.doi.org/10.1590/S0102-09352013000100014>.
- Whipps CM, Fournie JW, Morrison DA, Azevedo C, Matos E, Thebo P, et al. Phylogeny of fish-infecting *Calyptospora* species (Apicomplexa: eimeriorina). *Parasitol Res* 2012; 111(3): 1331-1342. <http://dx.doi.org/10.1007/s00436-012-2969-8>. PMID:22645034.