

# Parasitological survey on birds at some selected brazilian zoos

Levantamento parasitológico em aves de alguns zoológicos brasileiros

Paulo Gonzalez Hofstatter<sup>1\*</sup>; Ana Maria Aparecida Guaraldo<sup>1</sup>

<sup>1</sup>Department of Animal Biology, Institute of Biology, Universidade Estadual de Campinas – UNICAMP, Campinas, SP, Brazil

Received November 4, 2014

Accepted December 8, 2014

## Abstract

A parasitological survey was conducted at some zoos in the states of São Paulo and Paraná, Brazil, from 2009 to 2011. Several groups of birds were surveyed for fecal samples, but the most important was Psittacidae. Among the parasites, *Eimeria* (coccidian) and *Capillaria*, *Ascaridia* and *Heterakis* (nematodes) were observed in almost one third of the samples. Presence of a rich parasite fauna associated with captive birds seems to be an effect of captivity, since data on free-ranging birds indicate few or virtually no parasites at all. The discovery of new coccidian species during this survey reveals the need of more research on the subject as even well-known bird species have unknown parasites, but caution must be exercised in order to avoid descriptions of pseudoparasites.

**Keywords:** *Ascaridia*, *Capillaria*, Cracidae, *Eimeria*, Psittacidae.

## Resumo

Um levantamento parasitológico foi conduzido em alguns zoológicos dos Estados de São Paulo e Paraná, Brasil, de 2009 a 2011. Vários grupos de aves foram examinados por meio de amostras fecais, sendo o mais importante o Psittacidae. Entre os parasitas, *Eimeria* (coccidio) e *Capillaria*, *Ascaridia* e *Heterakis* (nematoides) foram observados em quase um terço das amostras. A presença de uma rica fauna parasitária associada a aves cativas parece ser um efeito do cativeiro, já que dados oriundos de animais de vida livre mostraram poucos ou virtualmente nenhum parasita. A descoberta de novas espécies de coccídeos durante esse levantamento revela a necessidade de mais pesquisas sobre o assunto, pois até espécies de aves bem conhecidas têm parasitas desconhecidos, por isso toda cautela é necessária para se evitar a descrição de pseudoparasitas.

**Palavras-chave:** *Ascaridia*, *Capillaria*, Cracidae, *Eimeria*, Psittacidae.

## Introduction

Most of the birds kept at zoos in Brazil belong to native species. Among these, psittacine species are the most common and diverse, but Cracidae, Ramphastidae, Passeriformes and ratites are also present. Little is known about their parasites and deaths are fairly common in captivity, some probably due to high parasite loads. For instance, the infection with *Sarcocystis falcatula* may lead psittacids to acute fatal disease (CLUBB & FRENKEL, 1992).

The most common gut parasites of birds are nematodes (mainly ascarids and capillariids) and protozoa (usually coccidians). In a survey conducted by Cordon et al. (2009) on birds (mostly psittacids) at the Almuñecar ornithological garden in Spain, roughly half of the samples were positive for some type of parasite. *Capillaria* sp. was the most prevalent nematode, but *Ascaridia* sp. and *Heterakis* sp. were found as well. Among protozoa, the most prevalent were *Blastocystis* sp. and coccidians (mostly *Eimeria* sp. and unidentified oocysts). Hemoparasites were

also found, namely *Plasmodium* and *Haemoproteus*. Patel et al. (2000) also found parasite prevalence of 50% among birds at the Gujarat zoo, India, and the most common parasitic genera were *Capillaria*, *Ascaridia* and *Eimeria*.

In Brazil, Freitas et al. (2002) found overall prevalence of 46.7% among Psittacidae, Cracidae, Phasianidae, Columbidae and other avian groups in captivity. The most common parasitic genera were again *Capillaria* and *Ascaridia*, along with *Strongyloides*, 'coccidians' and others.

The aim of this study was to obtain data on prevalence and diversity of intestinal parasites from fecal samples of captive birds, mostly psittacids, kept in some selected Brazilian zoos.

## Materials and Methods

Fecal samples (n = 170) from individuals or pairs of the same species were collected by fresh deposit on cage floor or dry paper, when possible, from 2009 to 2010 from several species of birds kept at some Brazilian zoos. These species were mostly Psittacidae

\*Corresponding author: Paulo Gonzalez Hofstatter, Department of Animal Biology, Institute of Biology, Universidade Estadual de Campinas – UNICAMP, Rua Monteiro Lobato, 255, CP 6109, CEP 13083-862, Campinas, SP, Brazil, e-mail: paullogh@hotmail.com

(85.3% of the samples) along with Cracidae (4.1%), Cacatuidae (1.8%) and others (8.8%): Cathartidae, Ramphastidae, Psophidae, Strutioniformes, Icteridae and Musophagidae. The samples were stored in 2.5% potassium dichromate solution ( $K_2Cr_2O_7$ ). These samples were obtained from zoos in Americana, Bosque dos Jequitibás (Campinas), Itatiba and Guarulhos, which are all in the state of São Paulo; and from the Bird Park of Foz do Iguaçu, Paraná.

In the laboratory, the fecal material was filtered through a 154  $\mu\text{m}$  sieve using clean water and was concentrated by means of centrifugation at 1,200 g for 5 min. Nematode eggs and coccidian oocysts were obtained by flotation in sucrose solution ( $d = 1.2 \text{ g/mL}$ ) using the Sheather method (SHEATHER, 1923). Unsporulated oocysts obtained in this way were allowed to sporulate on a dish containing 2.5% potassium dichromate solution at room temperature for a few days.

The oocysts and nematode eggs were photographed under a Zeiss® light photomicroscope and then measured using the Image Manager IM50© software (Leica IM50 4.0 Imagic Bildverarbeitung AG; Leica Microsystems Imaging Solutions Ltd., Cambridge, U.K.).

## Ethics

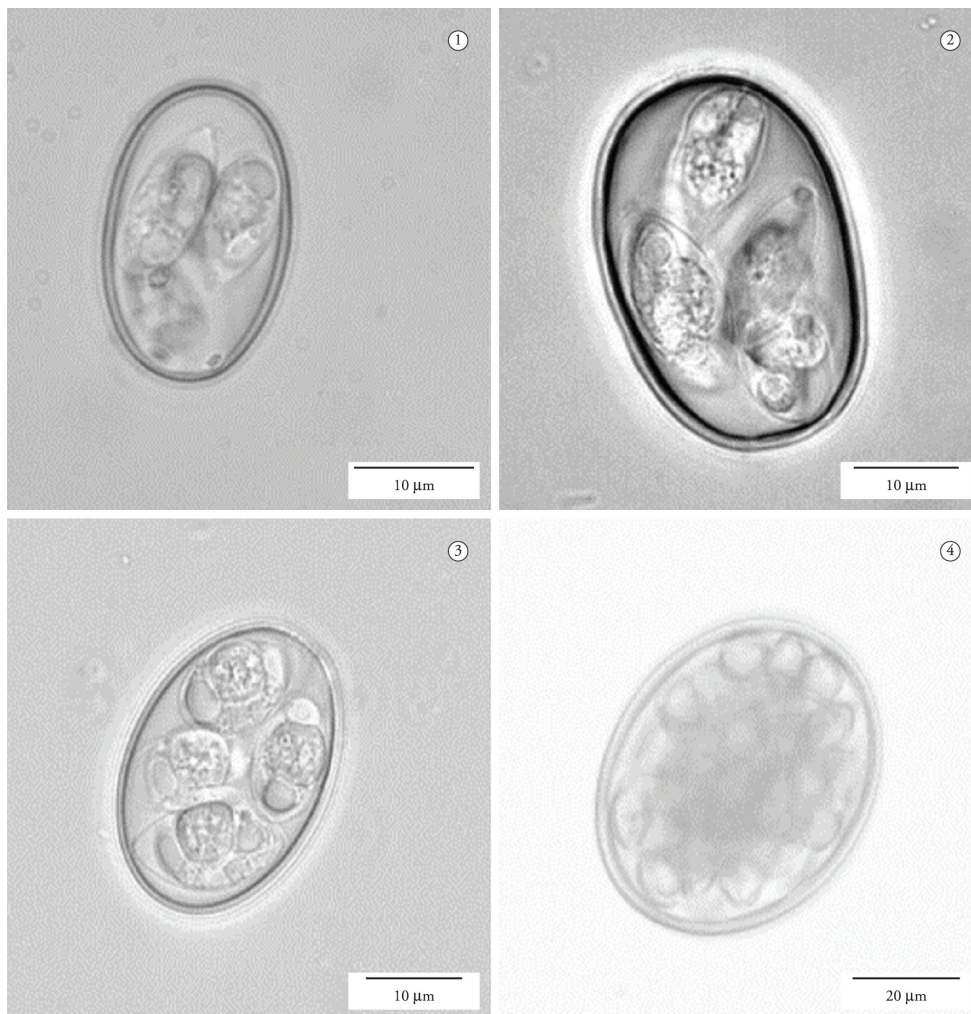
Although not involving animal experimentation, all procedures performed through this project were subject to and approved by our Institution's Ethics Committee for Animal Use (CEUA, UNICAMP) under number 1923-1.

## Results

Despite low prevalence of coccidians (3.5%), nematodes were present in every zoo surveyed, with prevalence of 26.5%. The overall prevalence of samples testing positive for nematode eggs or coccidian oocysts was 29.4% (50 out of 170).

## Coccidia

Coccidians, mostly *Eimeria*, were infrequently observed (6 out of 170 samples), although present in samples from Psittacidae, Cracidae and Ramphastidae. Some new eimerian species were described as part of this project: *E. abmitu* (Figure 1), host: *Mitu tuberosum* (HOFSTATTER & GUARALDO, 2011a) and



**Figures 1-4.** 1. *Eimeria abmitu* from *Mitu tuberosum*; 2. *Eimeria aestivae* from *Amazona aestiva*; 3. *Eimeria forresteri* from *Ramphastos toco*; 4. Unidentified polysporocystic oocyst from *Cacatua alba*, probably an adeleid pseudoparasite from insects.

*E. amazonae* (Figure 2), host: *Amazona aestiva* (HOFSTATTER & GUARALDO, 2011b).

*Eimeria forresteri* (UPTON et al., 1984) (Figure 3) was identified in samples from *Ramphastos toco*. An unidentified poly-sporocystic coccidian was observed in *Cacatua alba* (Figure 4), probably a pseudoparasite from insects.

## Nematodes

Nematodes were much more frequent than protozoa (45 out of 170 samples). Among these, *Capillaria* sp. (or *Ornithocapillaria* sp.) was the most abundant in psittacid samples. Its presence was confirmed in every zoo. *Capillaria plagiaticia* (FREITAS et al., 1959) was obtained from the gut of a dead Hyacinth Macaw individual. Furthermore, *Ascaridia* sp., *Heterakis* sp. and an unidentified nematode were also present in samples from psittacids. Unidentified nematode eggs were also observed in samples from ostriches (*Struthio camelus*) (Table 1).

## Discussion

In our study, almost one-third of the samples were positive for at least one parasite. This result was similar to the findings from other surveys in zoos, and this prevalence was higher than among free-ranging birds. The results of Freitas et al. (2002) regarding captive psittacids in northeastern Brazil were very similar to ours, thus indicating that the same parasitic agents are associated with Brazilian psittacids all over the country and elsewhere too, since data from studies in other countries also bear similarities to ours (CORDÓN et al., 2009; PATEL et al., 2000). Thus, the most

important parasites of parrots in captivity are nematodes of the genera *Capillaria* and *Ascaridia*.

Authors working with free-ranging birds have failed to detect any intestinal parasites associated with psittacine birds (GILARDI et al., 1995; STONE et al., 2005; MASELLO et al., 2006; ALLGAYER et al., 2009). In contrast, the data obtained from birds in zoos show high prevalence of parasites (PATEL et al., 2000; CORDÓN et al., 2009), thus indicating that captivity may facilitate transmission between individuals and also raise the parasitic load in the hosts. There seems to be a trend for captive birds to have bigger loads of associated parasitic fauna than those of free-ranging birds.

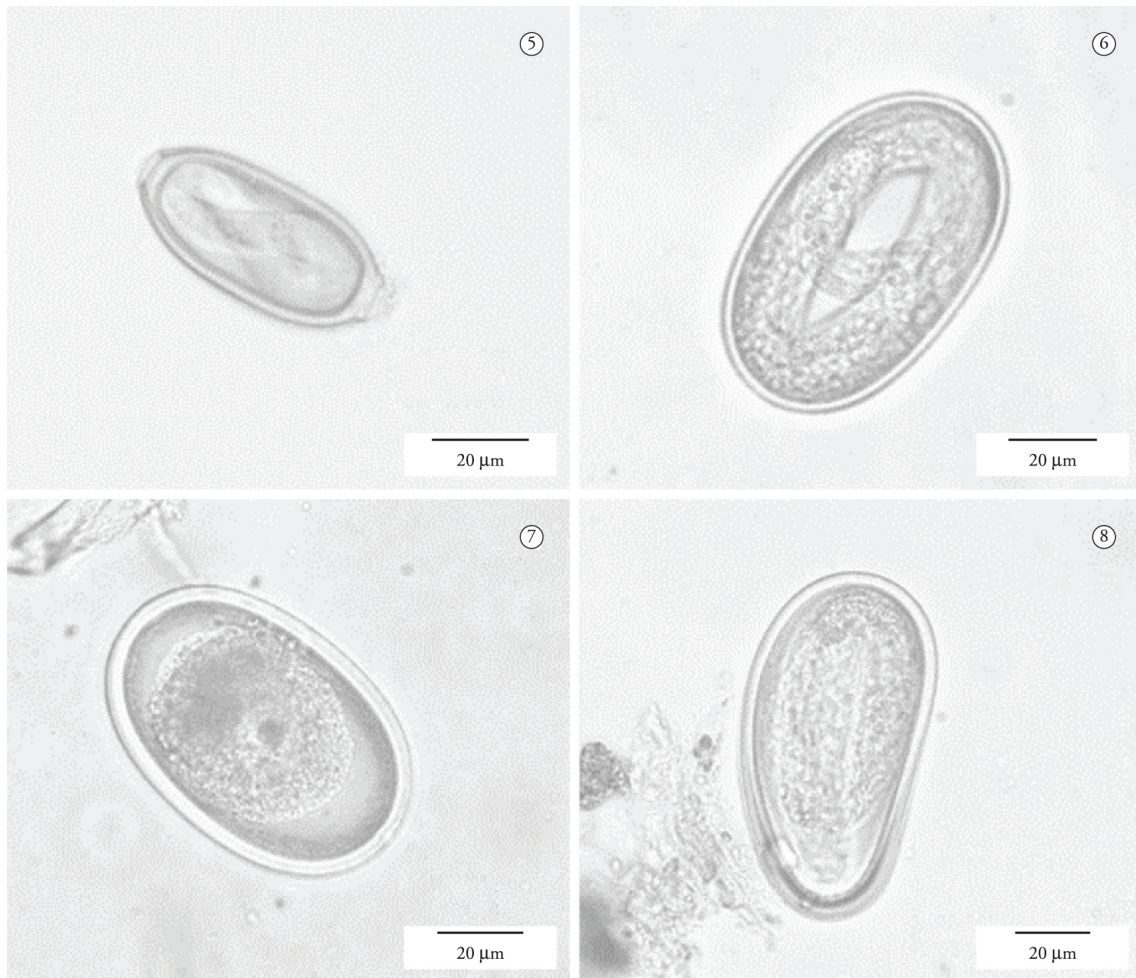
It seems that high prevalence and heavy parasitic load are not natural among those birds, which may threaten the health of birds held in captivity and even cause deaths, either due to the parasites themselves or due to secondary infections derived from their presence. Several suspicious deaths of individuals occurred in these zoos before and during this study, which may be attributed to complications caused by heavy parasite loads. Reasonable knowledge of the associated parasite fauna would enable more efficient disease control, in order to prevent the loss of specimens through easily avoidable causes. Clubb & Frenkel (1992) have controlled outbreaks of fatal *Sarcocystis* infection in psittacine birds by cockroach control in and around the facility where the birds were held.

The description of new coccidian species during this survey reveals the need of more research on the subject as even well-known bird species have unknown parasites. Most surveys are superficial in identification of parasites and it seems to be the case, several new species are frequently overlooked as in Freitas et al. (2002), Patel et al. (2000) and Cordón et al. (2009). But we need to exercise caution in order to avoid erroneous descriptions

**Table 1.** Nematodes, their hosts and zoos surveyed from 2009 to 2010 in the State São Paulo and Paraná, Brazil.

Nematodes	Hosts	Zoos
	<i>Ara ararauna</i> , <i>A. macao</i>	Bosque dos Jequitibás
	<i>Amazona aestiva</i> , <i>A. amazonica</i>	
	<i>Amazona aestiva</i>	Zoológico de Americana
	<i>Anodorhynchus hyacinthinus</i>	
	<i>Ara ararauna</i> , <i>A. rubrogenis</i> , <i>Ara macao</i>	
<i>Capillaria</i> sp. (Figure 5)	<i>Ara chloropterus</i> , <i>Ara macao</i> , <i>Ara ararauna</i>	Zooparque de Itatiba
	<i>Amazona aestiva</i> , <i>A. brasiliensis</i> , <i>A. farinosa</i> , <i>A. ochrocephala</i>	
	<i>Pionus menstruus</i>	
	<i>Amazona vinacea</i>	Parque das Aves (Bird Park) Foz do Iguaçu
	<i>Pionus maximiliani</i>	
	<i>Ara macao</i>	Zoológico de Guarulhos
<i>Ascaridia</i> sp. (Figure 6)	<i>Amazona amazonica</i>	Bosque Jequitibás
	<i>Amazona aestiva</i> , <i>A. ochrocephala</i>	Zooparque Itatiba
<i>Heterakis</i> sp. (Figure 7)	<i>Amazona aestiva</i> , <i>A. farinosa</i> , <i>A. ochrocephala</i>	Zooparque de Itatiba
Unidentified psittacid nematode (Figure 8)	<i>Amazona aestiva</i>	Zooparque de Itatiba
Unidentified ostrich nematode	<i>Struthio camelus</i>	Zooparque de Itatiba





**Figures 5-8.** 5. *Capillaria/Ornithocapillaria* sp. (probably *C. plagiaticia*) egg; 6. *Ascaridia* sp. egg; 7. *Heterakis* sp. egg; 8. Unidentified psittacid nematode egg.

of new species, as pseudoparasites may be present in the samples (BERTO et al., 2010). The polysporocystic oocysts found in our analysis probably represents an adeleid pseudoparasite from insects.

## Acknowledgements

We would like to thank the staffs from the surveyed zoos for the help with the fecal samples as well as the referees for their contributions to this manuscript. We would like to thank also Coordenação de Aperfeiçoamento de Pessoal de Nível Superior (CAPES) for research funding.

## References

- Allgayer MC, Guedes NMR, Chiminazzo C, Cziulik M, Weimer TA. Clinical pathology and parasitologic evaluation of free-living nestlings of the Hyacinth Macaw (*Anodorhynchus hyacinthinus*). *J Wildl Dis* 2009; 45(4): 972-981. <http://dx.doi.org/10.7589/0090-3558-45.4.972>. PMID:19901373
- Berto BP, Lopes BB, Teixeira Filho WL, Flausino W, Lopes CWG. Coccídios de invertebrados associados ao hábito alimentar de vertebrados: uma revisão breve dos gêneros *Adelea*, *Adelina* e *Barroussia*. *Rev Bras Med Vet* 2010; 32(1): 33-41.
- Clubb SL, Frenkel JK. *Sarcocystis falcatula* of opossums: transmission by cockroaches with fatal pulmonary disease in psittacine birds. *J Parasitol* 1992; 78(1): 116-124. <http://dx.doi.org/10.2307/3283697>. PMID:1738053
- Cordón GP, Prados AH, Romero D, Moreno MS, Pontes A, Osuna A, et al. Intestinal and haematic parasitism in the birds of the Almuñecar (Granada, Spain) ornithological garden. *Vet Parasitol* 2009; 165(3-4): 361-366. <http://dx.doi.org/10.1016/j.vetpar.2009.07.027>. PMID:19682800
- Freitas JFT, Mendonça JM, Guimarães JP. Sobre algumas espécies do gênero *Capillaria* Zeder, 1800 parasitas de aves (Nematoda, Trichuroidea). *Mem Inst Oswaldo Cruz* 1959; 57(1): 17-32. <http://dx.doi.org/10.1590/S0074-02761959000100002>. PMID:13814750
- Freitas MFL, Oliveira JB, Cavalcanti MDB, Leite AS, Magalhães VS, Oliveira RA, et al. Parasitos gastrointestinais de aves silvestres em cautiverio en el estado de Pernambuco, Brasil. *Parasitol Latinoam* 2002; 57(1-2): 50-54. <https://dx.doi.org/10.4067/S0717-77122002000100012>.

- Gilardi KVK, Lowenstine LJ, Gilardi JD, Munn CA. A survey for selected viral, chlamydial, and parasitic diseases in wild dusky-headed parakeets (*Aratinga weddellii*) and tui parakeets (*Brotogeris sanctithomae*) in Peru. *J Wildl Dis* 1995; 31(4): 523-528. <http://dx.doi.org/10.7589/0090-3558-31.4.523>. PMID:8592384
- Hofstatter PG, Guaraldo AMA. *Eimeria abmitu* n. sp. (Apicomplexa: Eimeriidae) from the razor-billed curassow *Mitu tuberosum* Spix (Galliformes: Cracidae). *Syst Parasitol* 2011a; 78(1): 69-71. <http://dx.doi.org/10.1007/s11230-010-9277-4>. PMID:21161492
- Hofstatter PG, Guaraldo AMA. A new eimerian species (Apicomplexa: Eimeriidae) from the blue-fronted Amazon parrot *Amazona aestiva* L. (Aves: Psittacidae) in Brazil. *J Parasitol* 2011b; 97(6): 1140-1141. <http://dx.doi.org/10.1645/GE-2797.1>. PMID:21612420
- Masello JF, Choconi RG, Sehgal RNM, Tell L, Quillfeldt P. Blood and intestinal parasites in wild Psittaciformes: a case study of burrowing parrots (*Cyanoliseus patagonus*). *Ornitol Neotrop* 2006; 17(4): 515-529.
- Patel PV, Patel AI, Sahu RK, Vyas R. Prevalence of gastro-intestinal parasites in captive birds of Gujarat Zoo's. *Zoos Print J* 2000; 15(7): 295-296. <http://dx.doi.org/10.11609/JoTT.ZPJ.15.7.295-6>.
- Sheather AT. The detection of intestinal protozoa and mange parasites by a flotation technique. *J Comp Pathol* 1923; 36(4): 266-275. [http://dx.doi.org/10.1016/S0368-1742\(23\)80052-2](http://dx.doi.org/10.1016/S0368-1742(23)80052-2).
- Stone EG, Montiel-Parra G, Pérez TM. A survey of selected parasitic and viral pathogens in four species of Mexican parrots, *Amazona autumnalis*, *Amazona oratrix*, *Amazona viridigenalis*, and *Rhynchopsitta pachyrhyncha*. *J Zoo Wildl Med* 2005; 36(2): 245-249. <http://dx.doi.org/10.1638/04-026.1>. PMID:17323565
- Upton SJ, Ernst JV, Clubb SL, Current WL. *Eimeria forresteri* n. sp. (Apicomplexa: Eimeriidae) from *Ramphastos toco* and a redescription of *Isospora graculai* from *Gracula religiosa*. *Syst Parasitol* 1984; 6(3): 237-240. <http://dx.doi.org/10.1007/BF00009233>.