

# Evaluation of abortions spontaneously induced by *Neospora caninum* and risk factors in dairy cattle from Lima, Peru

Avaliação de abortos induzidos espontaneamente por *Neospora caninum* e fatores de risco em bovinos leiteiros de Lima, Peru

Marcos Enrique Serrano-Martínez<sup>1\*</sup> ; Cesar Abel Burga Cisterna<sup>1</sup>; Roberto Carlos Evaristo Romero<sup>2</sup>; Marco Antonio Quispe Huacho<sup>1</sup>; Alessandra Matienzo Bermabé<sup>1</sup>; Luis Antonio Llanco Albornoz<sup>1</sup>

<sup>1</sup> Grupo SANIVET: Sanidad Veterinaria, Facultad de Medicina Veterinaria y Zootecnia, Universidad Peruana Cayetano Heredia – UPCH, Lima, Peru

<sup>2</sup> Facultad de Medicina Veterinaria y Zootecnia, Universidad Peruana Cayetano Heredia – UPCH, Lima, Peru

Received November 7, 2018

Accepted March 13, 2019

## Abstract

Our objective was to identify the direct and indirect presence of *Neospora caninum* in dairy cattle and their aborted fetuses from Lima, Peru. A total 219 blood samples obtained from dairy cattle with records of spontaneous abortion were collected to detect antibodies against *N. caninum* in serum with indirect ELISA and search for risk-factor associations. 68 fetal aborted tissue samples of these cows were analyzed by PCR, indirect ELISA and histopathology assay to detect *N. caninum* presence. The prevalence ratio (PR) and 95% confidence intervals (CI) were estimated. Univariate analysis was performed using the chi-squared test. Among the 68 aborted fetuses collected, 10 (15%) were positive in at least two diagnostic tests. Among 219 serum samples, 46.6% (95% CI: 40.0%-53.3%) were positive. Cows with 4 years or older (PR: 7.10; 95% CI: 4.89-10.67) and multiparous (PR: 1.76; 95% CI: 1.11-2.80) were found to be more likely to possess *N. caninum* antibodies. This study detects presence of *N. caninum* in dairy cattle and their aborted fetus from Lima valley, suggesting biosecurity management improve to neosporosis control.

**Keywords:** Abortos, neosporosis, bovine, diagnostic, Peru.

## Resumo

O objetivo do trabalho foi diagnosticar a presença direta e indireta de *Neospora caninum* em fetos abortados e de soros de bovinos leiteiros de Lima, Peru. Um total de 219 amostras de sangue obtido de vacas leiteiras, com registros de abortos espontâneos, foi coletado para detectar anticorpos contra *N. caninum* no soro (pelo ELISA indireto), e para estudar associações com fatores de risco. Foram examinadas 68 amostras de tecido fetal abortado das vacas soropositivas pela PCR, ELISA indireto e histopatologia para detectar a presença de *N. caninum*. Entre os 68 fetos abortados, 10 (15%) foram positivos em pelo menos dois testes diagnósticos. A taxa de prevalência (PR) e o intervalo de confiança (CI) de 95% foram estimados. Análise univariada foi realizada usando o teste de Qui-quadrado. Entre as 219 amostras de soro, 46,6% (95% IC: 40,0%-53,3%) foram positivas. Vacas com 4 anos ou mais de idade (RP: 7,10; 95% IC: 4,89-10,67) e multíparas (RP: 1,76; 95% IC: 1,11-2,80) apresentaram maior frequência de anticorpos contra *N. caninum*. Este estudo demonstrou a presença de *N. caninum* em bovinos leiteiros e em fetos abortados oriundos do vale de Lima, sugerindo a implementação de medidas de biossegurança, para o controle da neosporose.

**Palavras-chave:** Aborto, neosporosis, bovino, diagnóstico, Peru.

## Introduction

*Neospora caninum* is an Apicomplexa identified as a causal agent of reproductive problems in cattle worldwide (DUBEY, 2003). In their life cycle, dogs (MCALLISTER et al., 1998), coyotes (GONDIM et al., 2004b), and grey wolves (DUBEY et al., 2011)

are definitive hosts. *N. caninum* easily survives in many mammals, identifying multiple intermediate hosts such as cows, sheep, goats, deer (CABRAL et al., 2009; PANADERO et al., 2010; SALABERRY et al. 2010; VARASCHIN et al., 2012), and alpacas (CHÁVEZ-VELÁSQUEZ et al., 2004).

*N. caninum* is a major cause of spontaneous abortion in bovines and is influenced by several factors. Some reports showed that seropositive cows are three to seven times more likely to abort

\*Corresponding author: Marcos Enrique Serrano-Martínez. Universidad Peruana Cayetano Heredia, Honorio Delgado Avenue, 430, Lima 31, Lima, Perú. e-mail: [enrique.serrano@upch.pe](mailto:enrique.serrano@upch.pe)



than seronegative cows (HALL et al., 2005; MOEN et al., 1998). In low-seroprevalence herds (<5%), spontaneous abortions due to *N. caninum* infection might occur at a rate of 1 per 100 cows/year. In high-seroprevalence herds (>20%), abortions are frequent all year round (THURMOND & HIETALA, 1997). Therefore, seropositivity in herds might increase with age or gestation number, and horizontal transmission can influence this event (JENSEN et al., 1999; RINALDI et al., 2005). Based on *N. caninum* seropositive herd risk, control of neosporosis in cattle is necessary to prevent reproductive problems outbreaks.

The valley of Lima is one of livestock regions with the highest milk production from Peru; nevertheless, cattle suffer from constant reproductive diseases, principally aborts (GAMARRA, 2001; RIVERA, 2001). Several studies have found *N. caninum* high prevalence in dairy cattle from Lima Valley (GAMARRA et al., 2009; SILVA et al., 2002). Considering *N. caninum* presence such a risk in reproductive cattle health (DUBEY et al., 2007), the identification of *N. caninum* in aborted fetus in areas with previous high reports of neosporosis is essential.

Several diagnostic assays have been employed with varying degrees of success to identify *N. caninum*. Serology diagnostic assays are the most frequently used given their simplicity and speed; nevertheless, their diagnostic capacity depends on the cutoff value for the assay, as well as on their cross-reactivity with other parasites (ORTEGA-MORA et al., 2006) or their ability to be influenced by pregnancy (NOGAREDA et al., 2007). Polymerase chain reaction (PCR) is the most suitable diagnostic assay, but is expensive and different target genes might influence its sensibility (AL QASSAB et al., 2010; ELLIS, 1998). Histopathology has a low sensitivity for detection when compared to other diagnostic tests; however, it still holds important diagnostic value (DUBEY & SCHARES, 2006; SÁNCHEZ-CASTILLEJA & RODRÍGUEZ-DIEGO, 2018). Overall, the diagnosis of neosporosis is difficult, and more than one diagnostic test should be used to make a correct diagnosis.

In this context, the present study aimed to identify *N. caninum* seroprevalence and risk factors in dairy cattle. In addition, fetuses aborted of these cows were applied multiple diagnostic assays to demonstrate and understand the impact of neosporosis in reproductive losses in Peru.

## Materials and Methods

### Samples

The present study was developed according to the Animal Use Ethics Committee from Universidad Peruana Cayetano Heredia, Lima- Peru (protocol number 64237).

A total of 219 serum samples from dairy cattle with records of spontaneous abortion were collected to detect antibodies against *N. caninum*. All bovines were of Holstein breed and had a semi-intensive-to-intensive breeding system. Additionally, 68 aborted bovine fetuses at different stages of gestation from 7 milk farms were collected to detect the presence of *N. caninum* (Table 1). The samples collected from the fetuses were intrathoracic liquid, as well as the brain, lung, liver, adrenal gland, heart, kidney, thymus, spleen, bone marrow, and intestine. The intrathoracic liquid was obtained by direct puncture; fetal organs were obtained by necropsy and stored in 10% formaldehyde. Blood samples were obtained by direct puncture of the jugular vein in collection tubes without anticoagulant; waited for coagulation and centrifuged for 1.600g for 10 minutes at room temperature. Foetus age was calculated based on reproductive registers.

Samples were collected from June 2015 to May 2016 in different milk farms from Lima Valley, excluding farms that had cattle for fattening purposes. Necropsy of the fetus and all related samples were processed in the Laboratory of Parasitology, Faculty of Veterinary Medicine and Animal Science of the Universidad Peruana Cayetano Heredia, Lima, Peru.

**Table 1.** PCR, ELISA and Histologic assay from fetuses aborted recollected of dairy cattle in Lima Valley, with at least one positive test.

Nº Farm	Nº. Fetuses	ELISA	PCR	Histopathologic lesions according tissues recollected											
				BRA	LUN	LIV	KID	HEA	TIM	SPL	BM	AG	INT	Autolysis (%)	
1	1	-	+	-	-	AU	-	-	-	-	-	AU	-	AU	20
1	2	+	+	+	+	+	-	+	-	-	-	NR	-	NR	-
1	3	+	+	+	-	-	-	-	-	-	-	AU	-	-	10
2	4	+	+	-	-	-	-	-	-	-	-	AU	-	NR	10
4	5	+	+	-	-	AU	-	-	-	-	-	AU	-	-	20
4	6	+	+	+	-	-	-	+	-	-	-	NR	+	NR	-
4	7	-	+	-	-	-	-	AU	-	-	-	AU	-	-	20
5	8	+	+	+	-	+	-	+	-	-	-	AU	-	NR	10
5	9	+	+	+	-	-	-	+	+	-	-	-	-	NR	-
6	10	+	+	-	-	AU	-	-	-	-	-	AU	-	-	20
6	11	+	+	-	-	-	-	-	-	-	-	NR	-	AU	10
	<b>Total</b>			<b>5/11</b>	<b>1/11</b>	<b>2/11</b>	<b>1/11</b>	<b>4/11</b>	<b>1/11</b>	<b>0/11</b>	<b>0/11</b>	<b>0/11</b>	<b>1/11</b>	<b>0/11</b>	<b>8/11</b>
	<b>%</b>			<b>45.4</b>	<b>9.1</b>	<b>18.2</b>	<b>9.1</b>	<b>36.4</b>	<b>9.1</b>	<b>0</b>	<b>0</b>	<b>9.1</b>	<b>0</b>	<b>72.7</b>	

+: Histologic lesion compatible with *N. caninum*; -: No histological lesion compatible with *N. caninum*; BRA: brain; LUN: Lung; LIV: Liver; KID: Kidney; HEA: Heart; TIM: Thymus; SPL: Spleen; BM: Bone marrow; AG: Adrenal gland; INT: Intestine; AU: Autolysis; NR: No recollected. PCR: Polymerase chain reaction.

## PCR

DNA from the fetal brain sample was analyzed using nested PCR on the internal transcribed spacer (ITS1) region of *N. caninum*. DNA was obtained and quantified by the DNeasy Blood and Tissue Kit (Qiagen, Hilden, Germany) and a NanoDrop Lite spectrophotometer (Thermo Fisher Scientific, Waltham, MA, USA), respectively. Nested PCR was carried out using four oligonucleotides, as previously described by Buxton et al. (BUXTON et al., 1998). The Taq PCR Master mix (Qiagen) commercial kit was used. All Qiagen and Thermo Fisher Scientific products were utilized according to the manufacturers' protocols.

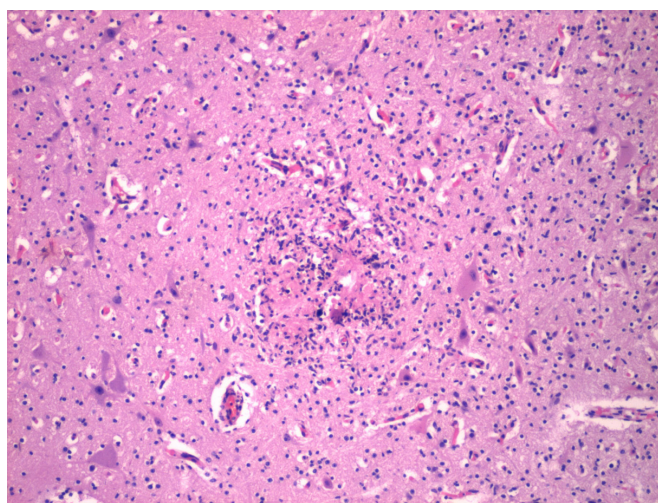
## ELISA

Antibody detection against *N. caninum* was performed for the intrathoracic fluid and serum samples obtained from the aborted fetuses and dairy cattle, respectively. The intrathoracic fluids were centrifuged for 600g for 10 minutes and store in 1.5 ml eppendorf tubes in -80°C. The HerdCheck IDEXX commercial kit was used according to manufacturer's protocol.

## Histology

Fetal tissues (brain, lung, liver, adrenal gland, heart, kidney, thymus, spleen, bone marrow, and intestine) were fixed in 10% neutral buffered formalin, and they were paraffin embedded and stained with hematoxylin and eosin for routine histologic examination. Fetus samples were classified as being positive for *N. caninum* if they had histopathologic changes compatible (Figure 1) and no compatible with *N. caninum* infection according Pescador (PESCADOR et al., 2007).

## Variables



**Figure 1.** Fetal brain of an aborted bovine fetus with mild diffuse encephalitis. Diffuse gliosis and focal necrosis surrounded by mononuclear inflammatory cells (H&E-stained sections, magnification is 100x).

## Outcome variables

We assessed the presence of *N. caninum* antibodies in dairy cattle. This outcome variable was assessed using the indirect enzyme-linked immunosorbent assay (ELISA) test in 219 bovines. The presence of *N. caninum* in aborted fetuses were evaluated by PCR, indirect ELISA, and histological analysis. A fetus with at least two positive diagnostic tests (PCR, ELISA, or histology) was considered a positive case.

## Independent variables

To evaluate the association between the outcome variable and neosporosis risk factors in dairy cows, we obtained data from the routine health register for cattle. The risk factors evaluated were age and number of births (first birth or multiparous).

## Statistical analysis

Statistical analyses were performed in Stata 14.0<sup>®</sup> (StataCorp, College Station, TX, USA); statistical significance was set at a level of  $P < 0.05$ . All variables were categorized and presented in absolute and relative frequencies. Aborted fetuses diagnostic were presented with descriptive statistics. The prevalence ratio (PR) and 95% confidence intervals (CI) were estimated to evaluate the association between seroprevalence and risk factors in dairy cattle. Univariate analysis was performed using the chi-squared test.

## Results

From the 68 fetuses that were aborted and recollected, 10 (15%) were positive in almost two diagnostic tests and 1 fetus aborted were positive only at least one diagnostic test. PCR and ELISA showed better diagnostic capabilities than histopathologic analysis (Table 1). The brain (5/11) and heart (4/11) showed a high frequency of injuries in histopathologic assay. Also, samples from the fourth and fifth month of gestation showed more cases of neosporosis (Table 2).

Among 219 dairy bovines included in the study, 46.6% (95% CI: 40.0%-53.3%) were positive for *N. caninum* antibodies. A significantly higher proportion of *N. caninum* antibodies were found in older ( $p < 0.001$ ) and multiparous bovines ( $p = 0.017$ ), confirming that age and the number of births were risk factors for this infection (Table 3).

## Discussion

The present study aimed to identify the presence of *N. caninum* in aborted fetuses from dairy cattle. Our findings demonstrate that 15% (10/68) of aborted fetuses were positive in almost two diagnostic assays, at least (Table 1). In Peru, *N. caninum* cyst records in aborted bovine fetuses showed a moderate proportion of positive cases (55.2%; 16/29), this is higher when compared with the findings from our study (15%). Spontaneous abortions in cattle are strongly associated with *N. caninum* high seroprevalence



**Table 2.** Number of *N. caninum* fetuses positive according gestational age and diagnostic technique in dairy cattle from Lima Valley.

		Fetuses (months)							Total Positives	
		2	3	4	5	6	7	8		9
Diagnostic test	ELISA	-	-	4	2	1	1	1	1	10
	Histology	-	1	2	1	1	-	-	-	5
	PCR	1	1	4	2	1	1	-	1	11
Type of histologic lesion	Compatibles	-	1	2	1	1	-	-	-	5
	Non-specific	1	-	1	-	-	-	-	-	2
	NLO	-	-	1	1	-	1	-	1	4

NLO: No lesion observed; PCR: Polymerase chain reaction.

**Table 3.** Prevalence and factors associated with the presence of antibodies against *Neospora caninum* in dairy cattle from Lima-Peru.

Variable	Category	Positive		PR <sup>†</sup>	CI 95%	P***
		n**	%			
Age	15-24 months	2	10	Reference		
	2-4 years	24	26.1	2.67	0.67-5.18	0.168
	>4 years	76	71.0	7.10*	4.89-10.67	<0.001
N° Births	First birth	14	29.2	Reference		
	Multiparous	88	51.5	1.76*	1.11-2.80	0.017
Antibodies <i>N. caninum</i>	Negative	117	53.4	-	46.7-59.9	-
	Positive	102	46.6	-	40.0-53.3	

†Prevalence ratio; \*p < 0.05, statistical differences with reference group; \*\* Sample elements; \*\*\*Chi square p value.

herd; and it is associated to dog presence, overcrowding, waste management, high replacement rate (>50%) and low biosecurity in insemination process (HADDAD et al., 2005; HALL et al., 2005; MOEN et al., 1998).

No other infectious abortigenic agents were investigated in this work. Multiple pathogens may produce spontaneous abortions in bovines, such as *Leptospira* spp., *Brucella abortus*, bovine viral diarrhea virus, and *Aspergillus* spp. (RIVERA, 2001). However, this work confirms that neosporosis is present in Peru and is associated with abortions in dairy cows in the Lima Valley.

Seroprevalence of *N. caninum* in dairy cattle has been reported in different regions of Peru and described their association with aborts. In the highlands, a seroprevalence of 46.7% was reported (GRANADOS et al., 2014), while in the Amazon rainforest it was 18.8% (PORTOCARRERO et al., 2015), in Lima Valley (Peru central coast) it was 29.6%-69.6% (GAMARRA et al., 2009; SILVA et al., 2002), and in our study it was 46.6%. Rivera reported 55% of aborted fetus with *N. caninum* presence in different farms from Lima valley with different diagnostic test (RIVERA, 2001) and our study found 15% of aborted fetus. This prevalence difference would be related to technology level and her size in different region from Peru (BARLING et al., 2000; SENASA, 2011). However, the high prevalence and constant report of aborted fetus in cattle from Peru related to *N. caninum* presence confirm that seropositive herds present more probability to report aborts than seronegative herds (THURMOND & HIETALA, 1997).

Our study found that cows older than 4 years and multiparous are more likely to possess *N. caninum* antibodies (Table 3). Other studies also found that age and the numbers of births influence neosporosis (JENSEN et al., 1999; RINALDI et al., 2005). These would be

explained by the replacement with no-free *N. caninum* identification cattle or the use of contaminated reproductive tools (FERRE et al., 2008; SERRANO-MARTÍNEZ et al., 2007). Also in Peru, the lack of diagnosis to *N. caninum* due to deficient report in semen imported from others cities or countries increment the risk to convert a cow in seropositive by the time or numbers of births (ESCALONA et al., 2010). So, *N. caninum* identification of multiparous and older cows would be an important control option to neosporosis in stable.

There are different diagnostic techniques for detect *N. caninum* infection, showing advantages and disadvantages. Nested PCR assay based on the Nc5 and ITS regions demonstrated good performance in different works (GONDIM et al., 2004a; PENA et al., 2007). These genetic regions are the most frequently used to detect *N. caninum* and are useful for detecting the presence of this protozoo in aborted fetuses autolysis when tissues are frozen. Serology aids in diagnosing fetal neosporosis, since there is no transplacental transfer of antibodies from dam to fetus in cattle. Despite the fact that other reports showed the low sensitivity of fetal serology (GOTTSTEIN et al., 1998; SÖNDGEN et al., 2001), our study found that ELISA performed well when compared with PCR (Table 2). The primary method used to diagnose *N. caninum* infection in aborted fetuses is histopathology. Fetal lesions such as multifocal, non-suppurative encephalitis and myocarditis are not pathognomonic, but they do allow for a presumptive diagnosis. Moreover, histologic lesions are not exclusive for *N. caninum*, as they share histologic characteristics with other apicomplexans (DONAHOE et al., 2015; JENKINS et al., 2002; SÁNCHEZ-CASTILLEJA & RODRÍGUEZ-DIEGO, 2018). In conclusion, assays using two or more diagnostic tests may contribute to the successful identification of spontaneous abortion in bovines caused by *N. caninum*.

In our study, different diagnostic test was applied to detect *N. caninum* infection, showing PCR and ELISA only differ one sample in diagnostic; meanwhile, histopathology differs in more than 1 (Table 1). Limiting of histopathology is the subjective criterion because need an expert evaluator, in contrast to PCR and ELISA that are objectives diagnostic test (ORTEGA-MORA et al., 2006). ELISA need a high level of antibodies to detect a positive sample; considering immunology system of fetus recollected is in developing, titers of antibodies may not reach cut-off ELISA, need more time to produce more immunoglobuline or the parasite burden was low (ALMERÍA et al., 2016; PEREIRA-BUENO et al., 2003) PCR diagnostic performance is very high, detecting presence of small amounts of *N. caninum* DNA in large quantity of sample; moreover, PCR detect DNA in tissues of autolysed fetuses (VAN MAANEN et al., 2004). In conclusion, PCR in our study demonstrated be more sensitivity than ELISA in aborted fetus samples.

## Conclusion

*Neospora caninum* was detected in aborted fetus from Lima Valley and seropositivity of cattle with abort records is significantly associated with age and number of births, suggesting this variables be a risk factors to infection with this parasite.

## Acknowledgements

This study was supported by Grant: Fondo Innovación, Ciencia y Tecnología (FINCYT-Innovate Peru), Project “Obtención y caracterización del primer aislado de *Neospora caninum* causante de abortos y mortalidad neonatal en la producción bovina lechera del Peru, con fines inmunodiagnóstico y vacunal” (contrato 167-PNICP-PIAP-2015 FINCYT); Programa Iberoamericano de Ciencia y Tecnología para el Desarrollo (CYTED), support for Red Temática 113RT0469 PROTOZOOVAC: “DIAGNÓSTICO Y CONTROL DE LAS PROTOZOOSIS REPRODUCTIVAS DEL GANADO BOVINO” that facilitated technical capacitation of our researchers. We thank the breeders and thesis students, who collaborated during the collection of samples.

## References

- Almería S, Serrano-Perez B, Darwich L, Domingo M, Mur-Novales R, Regidor-Cerrillo J, et al. Foetal death in naive heifers inoculated with *Neospora caninum* isolate Nc-Spain7 at 110 days of pregnancy. *Exp Parasitol* 2016; 168: 62-69. <http://dx.doi.org/10.1016/j.exppara.2016.06.009>. PMID:27388371.
- Al-Qassab SE, Reichel MP, Ellis JT. On the biological and genetic diversity in *Neospora caninum*. *Diversity (Basel)* 2010; 2(3): 411-438. <http://dx.doi.org/10.3390/d2030411>.
- Barling KS, Sherman M, Peterson MJ, Thompson JA, McNeill JW, Craig TM, et al. Spatial associations among density of cattle, abundance of wild canids, and seroprevalence to *Neospora caninum* in a population of beef calves. *J Am Vet Med Assoc* 2000; 217(9): 1361-1365. <http://dx.doi.org/10.2460/javma.2000.217.1361>. PMID:11061391.
- Buxton D, Maley SW, Wright S, Thomson KM, Rae AG, Innes EA. The pathogenesis of experimental neosporosis in pregnant sheep. *J Comp Pathol* 1998; 118(4): 267-279. [http://dx.doi.org/10.1016/S0021-9975\(07\)80003-X](http://dx.doi.org/10.1016/S0021-9975(07)80003-X). PMID:9651804.
- Cabral AD, Camargo CN, Galletti NTC, Okuda LH, Pituco EM, Del Fava C. Diagnosis of *Neospora caninum* in bovine fetuses by histology, immunohistochemistry, and nested-PCR. *Rev Bras Parasitol Vet* 2009; 18(4): 14-19. <http://dx.doi.org/10.4322/rbpv.01804003>. PMID:20040203.
- Chávez-Velásquez A, Álvarez-García G, Collantes-Fernández E, Casas-Astos E, Rosadio-Alcántara R, Serrano-Martínez E, et al. First Report of *Neospora caninum* Infection in Adult Alpacas (*Vicugna pacos*) and Llamas (*Lama glama*). *J Parasitol* 2004; 90(4): 864-866. <http://dx.doi.org/10.1645/GE-260R>. PMID:15357084.
- Donahoe SL, Lindsay SA, Krockenberger M, Phalen D, Šlapeta J. A review of neosporosis and pathologic findings of *Neospora caninum* infection in wildlife. *Int J Parasitol Parasites Wildl* 2015; 4(2): 216-238. <http://dx.doi.org/10.1016/j.ijppaw.2015.04.002>. PMID:25973393.
- Dubey J, Schares G, Ortega-Mora L. Epidemiology and control of neosporosis and *Neospora caninum*. *Clin Microbiol Rev* 2007; 20(2): 323-367. <http://dx.doi.org/10.1128/CMR.00031-06>. PMID:17428888.
- Dubey J, Schares G. Diagnosis of bovine neosporosis. *Vet Parasitol* 2006; 140(1-2): 1-34. <http://dx.doi.org/10.1016/j.vetpar.2006.03.035>. PMID:16730126.
- Dubey JP, Jenkins MC, Rajendran C, Miska K, Ferreira LR, Martins J, et al. Gray wolf (*Canis lupus*) is a natural definitive host for *Neospora caninum*. *Vet Parasitol* 2011; 181(2-4): 382-387. <http://dx.doi.org/10.1016/j.vetpar.2011.05.018>. PMID:21640485.
- Dubey JP. Review of *Neospora caninum* and neosporosis in animals. *Korean J Parasitol* 2003; 41(1): 1-16. <http://dx.doi.org/10.3347/kjp.2003.41.1.1>. PMID:12666725.
- Ellis JT. Polymerase chain reaction approaches for the detection of *Neospora caninum* and *Toxoplasma gondii*. *Int J Parasitol* 1998; 28(7): 1053-1060. [http://dx.doi.org/10.1016/S0020-7519\(98\)00096-4](http://dx.doi.org/10.1016/S0020-7519(98)00096-4). PMID:9724876.
- Escalona J, García F, Mosquera O, Vargas F, Corro A. Factores de riesgo asociados a la prevalencia de Neosporosis Bovina en el municipio Bolívar del estado Yaracuy, Venezuela. *Zootec Trop* 2010; 28(2): 201-211.
- Ferre I, Serrano-Martínez E, Martínez A, Osoro K, Mateos-Sanz A, del-Pozo I, et al. Effects of re-infection with *Neospora caninum* in bulls on parasite detection in semen and blood and immunological responses. *Theriogenology* 2008; 69(7): 905-911. <http://dx.doi.org/10.1016/j.theriogenology.2007.11.006>. PMID:18336895.
- Gamarra G. Situación actual y perspectivas de la ganadería lechera en la cuenca de Lima. *Rev Investig Vet Peru* 2001; 12(2): 1-13.
- Gamarra S, Salazar I, Zarate D, Vargas J. Seroprevalencia de *Neospora caninum* en una población ganadera lechera de la Cuenca de Lima. *Anales Científ UNALM* 2009; 70(1): 81-85. <http://dx.doi.org/10.21704/ac.v70i1.76>.
- Gondim LFP, Laski P, Gao L, McAllister MM. Variation of the internal transcribed spacer 1 sequence within individual strains and among different strains of *Neospora caninum*. *J Parasitol* 2004a; 90(1): 119-122. <http://dx.doi.org/10.1645/GE-134R>. PMID:15040677.
- Gondim LFP, McAllister MM, Pitt WC, Zemlicka DE. Coyotes (*Canis latrans*) are definitive hosts of *Neospora caninum*. *Int J Parasitol* 2004b; 34(2): 159-161. <http://dx.doi.org/10.1016/j.ijpara.2004.01.001>. PMID:15037103.

- Gottstein B, Hentrich B, Wyss R, Thür B, Busato A, Stärk KDC, et al. Molecular and immunodiagnostic investigations on bovine neosporosis in Switzerland. *Int J Parasitol* 1998; 28(4): 679-691. [http://dx.doi.org/10.1016/S0020-7519\(98\)00006-X](http://dx.doi.org/10.1016/S0020-7519(98)00006-X). PMID:9602392.
- Granados SZ, Rivera HG, Casas EA, Suárez FA, Arana CD, Chávez AV. Seroprevalencia de *Neospora caninum* en bovinos lecheros de cuatro distritos del Valle del Mantaro, Junín. *Rev Investig Vet Peru* 2014; 25(1): 58-64. <http://dx.doi.org/10.15381/rivep.v25i1.8468>.
- Haddad JP, Dohoo IR, VanLeewen J. A review of *Neospora caninum* in dairy and beef cattle—a Canadian perspective. *Can Vet J* 2005; 46(3): 230-243. PMID: 15884645.
- Hall CA, Reichel MP, Ellis JT. Neospora abortions in dairy cattle: diagnosis, mode of transmission and control. *Vet Parasitol* 2005; 128(3-4): 231-241. <http://dx.doi.org/10.1016/j.vetpar.2004.12.012>. PMID:15740860.
- Jenkins M, Baszler T, Björkman C, Schares G, Williams D. Diagnosis and seroepidemiology of *Neospora caninum*-associated bovine abortion. *Int J Parasitol* 2002; 32(5): 631-636. [http://dx.doi.org/10.1016/S0020-7519\(01\)00363-0](http://dx.doi.org/10.1016/S0020-7519(01)00363-0). PMID:11943234.
- Jensen AM, Björkman C, Kjeldsen AM, Wedderkopp A, Willadsen C, Uggla A, et al. Associations of *Neospora caninum* seropositivity with gestation number and pregnancy outcome in Danish dairy herds. *Prev Vet Med* 1999; 40(3-4): 151-163. [http://dx.doi.org/10.1016/S0167-5877\(99\)00048-3](http://dx.doi.org/10.1016/S0167-5877(99)00048-3). PMID:10423771.
- McAllister MM, Dubey J, Lindsay DS, Jolley WR, Wills RA, McGuire AM. Dogs are definitive hosts of *Neospora caninum*. *Int J Parasitol* 1998; 28(9): 1473-1478. [http://dx.doi.org/10.1016/S0020-7519\(98\)00138-6](http://dx.doi.org/10.1016/S0020-7519(98)00138-6). PMID:9770635.
- Moen AR, Wouda W, Mul MF, Graat EAM, Van Werven T. Increased risk of abortion following *Neospora caninum* abortion outbreaks: a retrospective and prospective cohort study in four dairy herds. *Theriogenology* 1998; 49(7): 1301-1309. [http://dx.doi.org/10.1016/S0093-691X\(98\)00077-6](http://dx.doi.org/10.1016/S0093-691X(98)00077-6). PMID:10732067.
- Nogareda C, López-Gatius F, Santolaria P, García-Ispuerto I, Bech-Sabat G, Pabón M, et al. Dynamics of anti-*Neospora caninum* antibodies during gestation in chronically infected dairy cows. *Vet Parasitol* 2007; 148(3-4): 193-199. <http://dx.doi.org/10.1016/j.vetpar.2007.06.032>. PMID:17643822.
- Ortega-Mora L, Fernández-García A, Gómez-Bautista M. Diagnosis of bovine neosporosis: recent advances and perspectives. *Acta Parasitol* 2006; 51(1): 1-14. <http://dx.doi.org/10.2478/s11686-006-0001-0>.
- Panadero R, Paineira A, López C, Vázquez L, Paz A, Díaz P, et al. Seroprevalence of *Toxoplasma gondii* and *Neospora caninum* in wild and domestic ruminants sharing pastures in Galicia (Northwest Spain). *Res Vet Sci* 2010; 88(1): 111-115. <http://dx.doi.org/10.1016/j.rvsc.2009.05.010>. PMID:19482324.
- Pena HFJ, Soares RM, Ragozo AMA, Monteiro RM, Yai LEO, Nishi SM, et al. Isolation and molecular detection of *Neospora caninum* from naturally infected sheep from Brazil. *Vet Parasitol* 2007; 147(1-2): 61-66. <http://dx.doi.org/10.1016/j.vetpar.2007.03.002>. PMID:17451882.
- Pereira-Bueno J, Quintanilla-Gozalo A, Pérez-Pérez V, Espi-Felgueroso A, Alvarez-García G, Collantes-Fernández E, et al. Evaluation by different diagnostic techniques of bovine abortion associated with *Neospora caninum* in Spain. *Vet Parasitol* 2003; 111(2-3): 143-152. [http://dx.doi.org/10.1016/S0304-4017\(02\)00361-8](http://dx.doi.org/10.1016/S0304-4017(02)00361-8). PMID:12531290.
- Pescador CA, Corbellini LG, Oliveira EC, Raymundo DL, Driemeier D. Histopathological and immunohistochemical aspects of *Neospora caninum* diagnosis in bovine aborted fetuses. *Vet Parasitol* 2007; 150(1-2): 159-163. <http://dx.doi.org/10.1016/j.vetpar.2007.08.028>. PMID:17904290.
- Portocarrero CM, Pinedo RV, Falcón NP, Chávez AV. Factores de riesgo asociados a la seroprevalencia de *Neospora caninum* en bovinos naturalmente infectados en la ceja de selva de Oxapampa, Perú. *Rev Investig Vet Peru* 2015; 26(1): 119-126. <http://dx.doi.org/10.15381/rivep.v26i1.10916>.
- Rinaldi L, Fusco G, Musella V, Veneziano V, Guarino A, Taddei R, et al. *Neospora caninum* in pastured cattle: determination of climatic, environmental, farm management and individual animal risk factors using remote sensing and geographical information systems. *Vet Parasitol* 2005; 128(3-4): 219-230. <http://dx.doi.org/10.1016/j.vetpar.2004.12.011>. PMID:15740859.
- Rivera H. Causas frecuentes de aborto bovino. *Rev Investig Vet Peru* 2001; 12(2): 117-122.
- Salaberry SR, Okuda LH, Nassar AF, Castro JR, Lima-Ribeiro AMC. Prevalence of *Neospora caninum* antibodies in sheep flocks of Uberlandia county, MG. *Rev Bras Parasitol Vet* 2010; 19(3): 148-151. <http://dx.doi.org/10.1590/S1984-29612010000300004>. PMID:20943017.
- Sánchez-Castilleja YM, Rodríguez-Diego JG. Identificación de lesiones histológicas coincidentes con *Neospora caninum* en tejido cerebral de fetos bovinos. *Rev Salud Anim* 2018; 40(1): 1-4.
- Serrano-Martínez E, Ferre I, Martínez A, Osoro K, Mateos-Sanz A, del-Pozo I, et al. Experimental neosporosis in bulls: Parasite detection in semen and blood and specific antibody and interferon-gamma responses. *Theriogenology* 2007; 67(6): 1175-1184. <http://dx.doi.org/10.1016/j.theriogenology.2007.01.010>. PMID:17316779.
- Servicio Nacional de Sanidad y Calidad Agroalimentaria – SENASA. *Caracterización de la diarrea viral bovina, neosporosis bovina y rinotraqueitis infecciosa bovina en el Peru* [online] 2011. [cited 2019 Mar 13]. Buenos Aires: Servicio Nacional de Salud Agraria del Peru. Available from: [http://repositorio.senasa.gob.pe/bitstream/SENASA/135/1/2011\\_SENASA\\_DVB-neosporosis-IBR.pdf](http://repositorio.senasa.gob.pe/bitstream/SENASA/135/1/2011_SENASA_DVB-neosporosis-IBR.pdf)
- Silva P, Chávez A, Rivera H, Casas E. Seroprevalencia de *Neospora caninum* en Bovinos lecheros del valle de Lima. *Rev Investig Vet Peru* 2002; 13(2): 51-55. <http://dx.doi.org/10.15381/rivep.v13i2.7330>.
- Söndgen P, Peters M, Bärwald A, Wurm R, Holling F, Conraths FJ, et al. Bovine neosporosis: immunoblot improves foetal serology. *Vet Parasitol* 2001; 102(4): 279-290. [http://dx.doi.org/10.1016/S0304-4017\(01\)00543-X](http://dx.doi.org/10.1016/S0304-4017(01)00543-X). PMID:11731071.
- Thurmond MC, Hietala SK. Effect of congenitally acquired *Neospora caninum* infection on risk of abortion and subsequent abortions in dairy cattle. *Am J Vet Res* 1997; 58(12): 1381-1385. PMID:9401685.
- van Maanen C, Wouda W, Schares G, von Blumröder D, Conraths FJ, Norton R, et al. An interlaboratory comparison of immunohistochemistry and PCR methods for detection of *Neospora caninum* in bovine foetal tissues. *Vet Parasitol* 2004; 126(4): 351-364. <http://dx.doi.org/10.1016/j.vetpar.2004.08.016>. PMID:15567040.
- Varaschin MS, Hirsch C, Wouters F, Nakagaki KY, Guimarães AM, Santos DS, et al. Congenital neosporosis in goats from the State of Minas Gerais, Brazil. *Korean J Parasitol* 2012; 50(1): 63-67. <http://dx.doi.org/10.3347/kjp.2012.50.1.63>. PMID:22451736.