

Tissue alterations in the pirarucu, *Arapaima gigas*, infected by *Goezia spinulosa* (Nematoda)

Alterações teciduais em pirarucu, *Arapaima gigas*, infectado por *Goezia spinulosa* (Nematoda)

Rodrigo Caldas Menezes¹; Sonia Maria Cursino dos Santos²; Paulo Sérgio Ceccarelli³;
 Luiz Eduardo Roland Tavares⁴; Rogério Tortelly⁵; José Luis Luque^{2*}

¹Clinical Research Laboratory for Domestic Animal Dermatozoonosis, Evandro Chagas Clinical Research Institute, Oswaldo Cruz Foundation – Fiocruz

²Postgraduate Program on Veterinary Sciences and Department of Animal Parasitology, Veterinary Institute, Federal Rural University of Rio de Janeiro – UFRRJ

³National Research and Conservation Center for Continental Fish – CEPTA, Chico Mendes Biodiversity Conservation Institute – ICMBio

⁴Department of Pathology, Biological and Health Sciences Center, Federal University of Mato Grosso do Sul – UFMS

⁵Department of Pathology and Veterinary Clinical Medicine, Veterinary School, Fluminense Federal University – UFF

Received December 13, 2010

Accepted February 7, 2011

Abstract

Five specimens of *Arapaima gigas* caught in the Araguaia River (State of Mato Grosso, Brazil) were investigated for helminths in 2004. Numerous adult specimens of the rhabdiascarid nematode *Goezia spinulosa* were found in stomach ulcers in all the specimens of *A. gigas* and were surrounded by thickening of the mucosa. The gastric glands of all the fish were necrotic and there was a severe and diffuse inflammatory reaction composed of eosinophils (which were predominant), lymphocytes and rare macrophages in the mucosa, submucosa and muscle layer. This is the first report of tissue lesion occurrences in this host, in the presence of *G. spinulosa*, and it confirms the high pathogenicity of this parasite species.

Keywords: Pathology, neotropical fish, Araguaia River, Brazil.

Resumo

Cinco espécimens de *Arapaima gigas* capturados no Rio Araguaia (Estado do Mato Grosso, Brasil) foram investigados para diagnóstico de infecção por helmintos em 2004. Numerosos espécimes adultos do nematóide rhabdiascarídeo *Goezia spinulosa* foram encontrados em úlceras do estômago circundadas por um espessamento da mucosa em todos os exemplares de *A. gigas*. As glândulas gástricas de todos encontravam-se necróticas e havia um acentuado e difuso infiltrado inflamatório composto por eosinófilos, que eram predominantes, linfócitos e raros macrófagos na mucosa, submucosa e camada muscular. As lesões teciduais na presença de nematóide *G. spinulosa* são relatadas pela primeira vez nesse hospedeiro e confirmam a alta patogenicidade dessa espécie de parasito.

Palavras-chave: Patologia, peixe neotropical, Rio Araguaia, Brasil.

Introduction

The pirarucu, *Arapaima gigas* (Schinz, 1822), is distributed predominantly in the Amazon basin and has high commercial value as a food resource and ornamental fish (HRBEK et al., 2007). However, over recent decades, the population has been in steady decline, and this fish came under protection through

the Convention on International Trade in Endangered Species of Wild Fauna and Flora (CITES) in 1975.

Farming of the pirarucu is limited by parasite infections. The ascarid nematode *Goezia spinulosa* (Diesing, 1839) was found to be one of the most pathogenic parasites of tank-reared *A. gigas* on Mexiana Island, Amazon River, Brazil, causing high mortality among cultured fingerlings (SANTOS; MORAVEC, 2009). Santos and Moravec (2009) described gross lesions, characterized by nematodes penetrating deeply into the stomach mucosa and causing ulcers, sometimes with more than 50 parasites involved, but without perforations into the mesentery of large fish. However,

*Corresponding author: José Luis Luque
 Curso de Pós-Graduação em Ciências Veterinárias,
 Departamento de Parasitologia Animal, Instituto de Veterinária,
 Universidade Federal do Rio de Janeiro – UFRRJ, BR-465, Km 7,
 CEP 23851-970, Seropédica - RJ, Brazil;
 e-mail: jlluque@ufrj.br

nematode larvae and juveniles caused perforations in the stomach wall in fingerlings, thus penetrating the mesentery.

There are no data on microscopic lesions associated with this parasite in this host. Recently, Santos et al. (2008) recorded *G. spinulosa* in wild pirarucu from the Araguaia River (State of Mato Grosso, Brazil) and provided a quantitative account of this species. Here, we present a full description of the pathological alterations caused by this nematode in the stomach of pirarucu from this locality.

Materials and Methods

In August 2004, five adult specimens of pirarucu (average length of 2.3 m) were caught in the Araguaia River using nylon fishing nets, in the municipality of Cocalinho, State of Mato Grosso, Brazil (13° 23' 07.3" S, 50 ° 39' 58.1" W). These fish were captured and necropsied under permission granted through SISBIO, the Brazilian Biodiversity Information System (License n° 15507-1). Fragments of parasitized stomach were removed and immediately fixed in 10% formalin, and nematode specimens were stored in 70% alcohol. The tissue samples were routinely processed for paraffin embedding (BEHMER et al., 1976). Sections of five micrometers in thickness were stained with hematoxylin and eosin. The parasites were identified based on descriptions by Moravec (1998) and Santos and Moravec (2009). Photomicrographs were taken using a Media Cybernetics Cool Sharp Pro camera connected to a Nikon Eclipse E-800 microscope. The parasitized stomach samples, preserved in 10% formalin, and slides containing histopathological sections through these organs, were deposited in the Helminthological Collection of the Oswaldo Cruz Institute (CHIOC n° 37707-37708, 37315-37317), Rio de Janeiro, RJ, Brazil.

Results

The gross lesions due to *G. spinulosa* in the stomachs of the five specimens of *A. gigas* studied here consisted of ulcers at the insertion sites of the nematodes, which were surrounded by thickening of the mucosa (Figure 1). Microscopically, all the fish contained nematodes with cuticular spines in the gastric lumen, and the anterior regions of the nematodes were embedded either superficially or deeply in extensively ulcerated and thickened mucosa, but without reaching the muscularis mucosa and submucosa (Figure 2). At times, nests of bacteria were observed on the ulcer surface (Figure 3). Moreover, there was necrosis in the gastric glands (which were scarce), and a severe and diffuse inflammatory reaction composed of eosinophils (which were predominant), lymphocytes and rare macrophages in the mucosa (Figure 4), submucosa and muscle layers of the five fish studied.

Discussion

The pathological alterations associated with *G. spinulosa* were severe and were characterized by ulcerative eosinophilic gastritis. According to Martins et al. (2004), fish parasitized with *Goezia leporini* may present hematological alterations such as anemia, leukocytopenia, neutrophilia and eosinophilia, which can be caused by tissue lesions like those observed in the present study. Moreover,

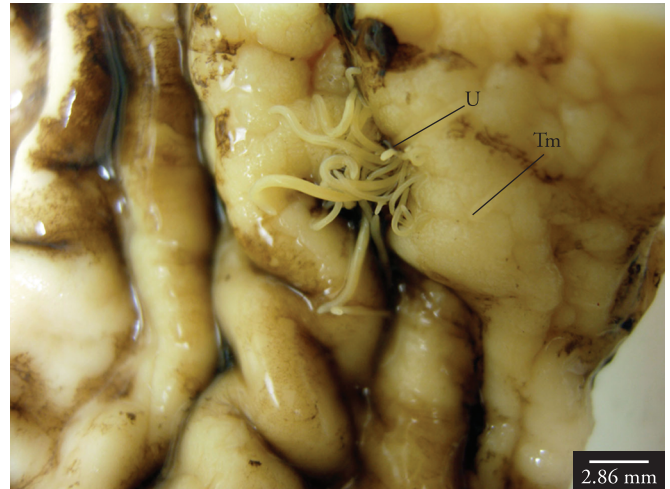


Figure 1. Stomach (fixed in 10% formalin) of a specimen of *Arapaima gigas* parasitized with *Goezia spinulosa*. Clusters of nematodes with the anterior region burrowed into the mucosa. An ulcer (U) can be seen at the nematode insertion site, which is surrounded by thickening of the mucosa (Tm). Bar = 2.86 mm.

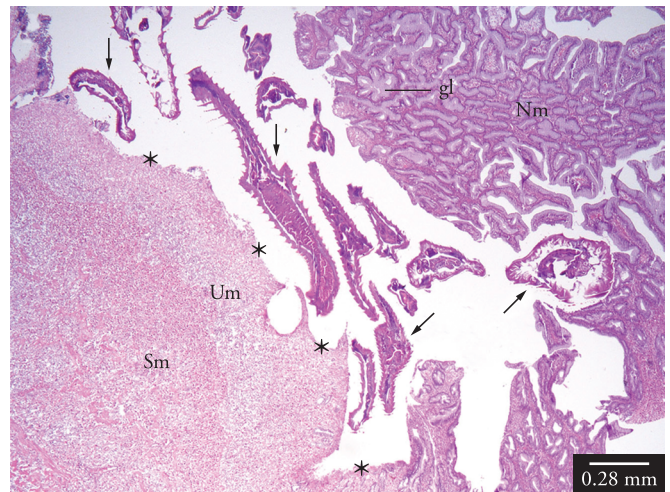


Figure 2. Histological section through the stomach of a specimen of *Arapaima gigas* parasitized with *Goezia spinulosa*. Multiple sections of nematodes (arrows) with cuticular spines can be seen in the lumen: their anterior regions are embedded in damaged mucosa (Um), which is extensively ulcerated (asterisks) and thickened, showing scarce gastric glands and a severe and diffuse inflammatory reaction composed of eosinophils, lymphocytes and macrophages. The ulcers do not reach the muscularis mucosa and submucosa (Sm). An area of non-ulcerated mucosa (Nm) containing multiple gastric glands (gl) can be seen. H&E; bar = 0.28 mm.

the ulcerative eosinophilic gastritis associated with *G. spinulosa* may cause digestion disorders and secondary infections, thus worsening the health status of the fish and leading to economic losses in farming this species. Mortality among pirarucu due to parasitism by *G. spinulosa* has only been reported in fingerlings, which have thin stomach tissue and are highly susceptible to attachment of larvae and juveniles of this nematode, which frequently cause perforations and penetrate into the mesentery (SANTOS; MORAVEC, 2009). The absence of migration of the

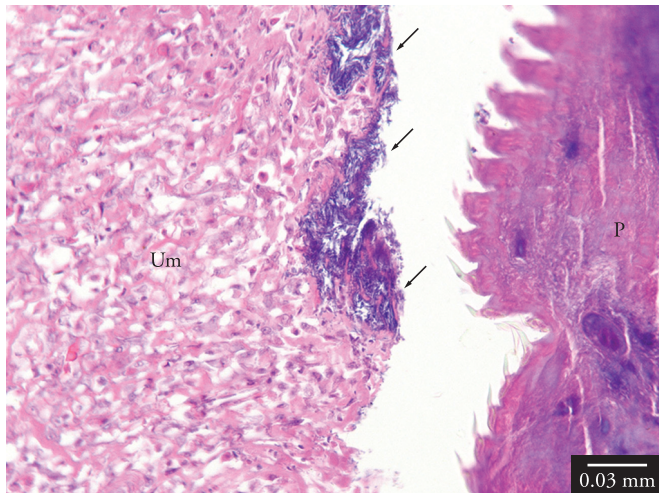


Figure 3. Histological section through the stomach of a specimen of *Arapaima gigas* parasitized with *Goezia spinulosa*. Ulcerated mucosa (Um) containing bacteria (arrows) on its surface can be seen associated with a nematode (P) with cuticular spines. H&E; bar = 0.03 mm.

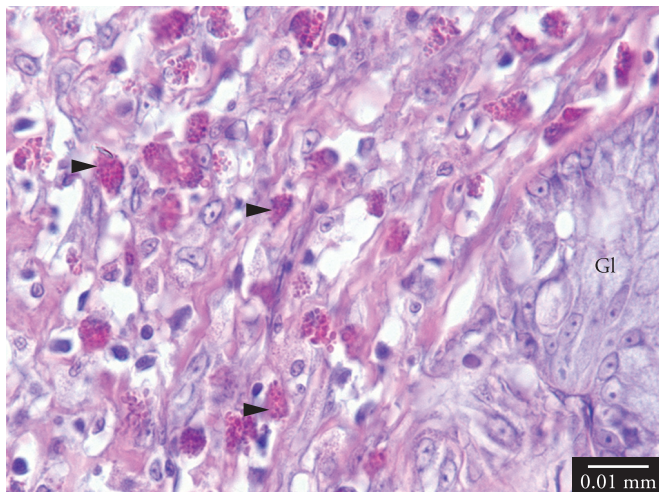


Figure 4. Histological section through the stomach of a specimen of *Arapaima gigas* parasitized with *Goezia spinulosa*. Detail of the severe inflammatory reaction in the mucosa, showing a gastric gland (Gl), numerous eosinophils (arrow heads), lymphocytes and macrophages. H&E; bar = 0.01 mm.

larvae through the digestive tract wall in the present study may be explained by the fact that the parasitized fish were large and had a thicker stomach wall, which is in agreement with the findings described by Santos and Moravec (2009).

The gross lesions were similar to those described by Santos and Moravec (2009) in the stomach of large specimens of *A. gigas* parasitized by the same species and similar to those described by Deardorff and Overstreet (1980) in the stomach of *Tilapia aurea* parasitized by *G. sinamora* and *Rachycentrum canadum* parasitized by *G. pelagia*. Microscopically, however, the fibrotic nodules, collagenous capsules around the parasites, epithelioid tubercles encasing embryonated eggs, penetration of helminths into the body cavity and inflammation only near to the worms with few eosinophils that Deardorff and Overstreet (1980) reported

were not seen in the present study. The reason for the different microscopic lesions observed in the present study is likely to be related to the different species of *Goezia*, as well as the age and species of the host. According to Deardorff and Overstreet (1980), the host response to *Goezia* species varies between both identical and different hosts. The ulcerative gastritis with numerous eosinophils observed in the present study has also been associated with other anisakid nematodes, such as *Anisakis*, *Contracaecum* and *Pseudoterranova* species, in the stomachs of marine mammals and humans (YOUNG; LOWE, 1969; ORIHHEL; ASH, 1995). In contrast with the microscopic lesions associated with these anisakids in mammals, the specimens of *G. spinulosa* in the present study were only embedded in the mucosa and did not reach the submucosa or muscle layers. Moreover, no abscesses, granulomas or areas of mineralization were observed.

Acknowledgements

We thank the research group of the Instituto Chico Mendes de Conservação de Biodiversidade (ICMBio), Brazil, for collecting the fish studied. José L. Luque was supported by a research fellowship from Conselho Nacional de Desenvolvimento Científico e Tecnológico do Brasil (CNPq).

References

- BEHMER, O. A.; TOLOSA, E. M. C.; FREITAS-NETO, A. G. **Manual de técnicas para histologia normal e patológica**. São Paulo: EDART, 1976. 256 p.
- DEARDORFF, T. L.; OVERSTREET, R. M. Taxonomy and biology of North American species of *Goezia* (Nematoda: Anisakidae) from fishes, including three new species. **Proceedings of Helminthological Society of Washington**, v. 47, n. 2, p. 192-217, 1980.
- HRBEK, T.; CROSSA, M.; FARIAS, I. P. Conservation strategies for *Arapaima gigas* (Schinz, 1822) and the Amazonian várzea ecosystem. **Brazilian Journal of Biology**, v. 67, p. 909-917, 2007. Suplemento 4.
- MARTINS, M. L. et al. Haematological alterations of *Leporinus macrocephalus* (Osteichthyes: Anostomidae) naturally infected by *Goezia leporini* (Nematoda: Anisakidae) in fish pond. **Arquivos Brasileiros de Medicina Veterinária e Zootecnia**, v. 56, n. 5, p. 640-646, 2004.
- MORAVEC, F. **Nematodes of freshwater fishes of the Neotropical region**. Praga: Academia, 1998. 464 p.
- ORIHHEL, T. C.; ASH, L. R. **Parasites in human tissues**. Chicago: ASPC Press, 1995. 386 p.
- SANTOS, C. P.; MORAVEC, F. *Goezia spinulosa* (Nematoda: Raphidascarididae), a pathogenic parasite of the arapaima *Arapaima gigas* (Osteichthyes). **Folia Parasitologica**, v. 56, n. 1, p. 55-63, 2009.
- SANTOS, M. C.; CECCARELLI, P. S.; LUQUE, J. L. Helminths parasitos do pirarucu, *Arapaima gigas* (Schinz, 1822) (Osteoglossiformes: Arapaimidae), no rio Araguaia, Estado de Mato Grosso, Brasil. **Revista Brasileira de Parasitologia Veterinária**, v. 17, n. 3, p. 171-173, 2008.
- YOUNG, P. C.; LOWE, D. Larval nematodes from fish of the subfamily Anisakinae and gastro-intestinal lesions in mammals. **Journal of Comparative Pathology**, v. 79, n. 3, p. 301-313, 1969. [http://dx.doi.org/10.1016/0021-9975\(69\)90043-7](http://dx.doi.org/10.1016/0021-9975(69)90043-7)