



REVISTA BRASILEIRA DE REUMATOLOGIA

www.reumatologia.com.br



Case report

Disseminated histoplasmosis in adolescent mimicking granulomatosis with polyangiitis



Histoplasmose disseminada em um adolescente mimetizando uma granulomatose com poliangiíte

Marlon van Weelden^{a,b}, Gabriela R. Viola^c, Katia T. Kozu^d, Nadia E. Aikawa^{d,e},
Claudia M. Ivo^f, Clovis A. Silva^{d,e,*}

^a Vrije University, Medical Faculty, Amsterdam, The Netherlands

^b Universidade de São Paulo, Faculdade de Medicina, Departamento de Pediatria, São Paulo, Brazil

^c Universidade de São Paulo, Faculdade de Medicina, Unidade de Reumatologia, São Paulo, Brazil

^d Universidade de São Paulo, Faculdade de Medicina, Unidade de Reumatologia Pediátrica, São Paulo, Brazil

^e Universidade de São Paulo, Faculdade de Medicina, Divisão de Reumatologia, São Paulo, Brazil

^f Universidade de São Paulo, Faculdade de Medicina, Unidade de Infectologia Pediátrica, São Paulo, Brazil

ARTICLE INFO

Article history:

Received 5 June 2014

Accepted 20 January 2015

Available online 14 July 2015

Introduction

Systemic infections are important differential diagnoses to autoimmune pediatric rheumatic diseases. Disseminated fungal infections have been rarely reported in these patients, especially in childhood-onset systemic lupus erythematosus patients under disease activity, lymphopenia or immunosuppressor therapy.¹⁻³

In addition, systemic histoplasmosis generally is associated with immunocompromised patients.⁴ This invasive fungal infection may mimic primary vasculitis with similar clinical manifestations, in particular granulomatosis with polyangiitis (GPA) or Wegener granulomatosis, which was rarely described in adult patients, but to our

knowledge such a thing has not been reported in pediatric population.⁵

Therefore, we reported herein an immunocompetent patient with disseminated histoplasmosis mimicking GPA that fulfilled the new European League Against Rheumatism (EULAR), Pediatric Rheumatology International Trials Organization (PRINTO), Pediatric Rheumatology European Society (PRES) propose validated classification criteria for pediatric population.⁶

Case report

A 6 year-old boy had recurrent acute migratory polyarthritides in shoulders, elbows, hips and knees associated with

* Corresponding author.

E-mail: clovisaasilva@gmail.com (C.A. Silva).

<http://dx.doi.org/10.1016/j.rbre.2015.01.003>

2255-5021/© 2015 Elsevier Editora Ltda. This is an open access article under the CC BY-NC-ND license (<http://creativecommons.org/licenses/by-nc-nd/4.0/>).

recurrent sinus inflammation, fever, malaise, headaches and daily abdominal pain. After two months at admission in our University Hospital, he presented arthritis in the left knee and morning stiffness of 2 h with spontaneous remission. Laboratory tests showed erythrocyte sedimentation rate (ESR) 81 mm/1st hour, C-reactive protein (CRP) 63 mg/L, hemoglobin 11.2 g/dL, hematocrit 32%, white blood cell count (WBC) 11,400/mm³ (neutrophils 60%, lymphocytes 35%, eosinophils 1% and monocytes 4%) and platelets counts 523,000/mm³. Serologic tests for hepatitis A, B and C, cytomegalovirus, human immunodeficiency virus, Epstein-Barr virus, toxoplasmosis, dengue virus and antistreptolysin O were all negative. Ophthalmological examination, bone scintigraphy, echocardiogram, colonoscopy, skull computer tomography (CT) and bone marrow aspirate were normal. Abdomen magnetic resonance imaging (MRI) revealed moderate ascites in pelvis and sinuses MRI showed pansinusitis. Antinuclear antibodies (ANA) were 1/80. Antineutrophil cytoplasmic antibodies (c-ANCA) were positive on two different occasions (1/80 and 1/20) at 6 years old, and were systematically negative on an annual basis. The anti-proteinase 3 antibody was not evaluated. The rheumatoid factor and anti-DNA antibodies were negative. Serum levels of IgG were 1988 mg/dL (normal range 970–1710), IgA 301 mg/dL (normal 69–382) and IgM 340.5 mg/dL (normal 53–145). Lymphocyte immunophenotyping showed: CD3⁺ 1614 cells/mm³ (normal 1000–2200), CD4⁺ 1136 cells/mm³ (normal 530–1300), CD8⁺ 412 cells/mm³ (normal 330–920), CD16⁺/56⁺ 135 cells/mm³ (normal 70–480) and CD19⁺ 246 cells/mm³ (normal 110–570). C4 was 38 mg/dL (normal 10–40) and C3 164 mg/dL (normal 90–180). At that moment, childhood GPA was suspected, however he had spontaneous regression of symptoms, normalization of acute phase reactants and absence of fever for 5 years. At 11 years and 10 months, he presented acute sinusitis and pneumonia with pleural effusion, which improved after benzylpenicillin for 10 days. At 11 years and 11 months, he had epididymitis confirmed by testicular ultrasound. At 12 years, he was hospitalized due to persistent headache, ocular hyperemia and left palpebral edema. MRI showed left eye proptosis degree 1. The cerebrospinal fluid analysis was normal, including negative fungus and tuberculosis cultures. Indirect tests (detection of antigen or cell-wall constituents) for aspergillosis, histoplasmosis and paracoccidioidomycosis were negative. No epidemiology for histoplasmosis was reported. c-ANCA was negative. Urinalysis was normal and proteinuria was 0.007 g/24 h. At the age of 12 years and 2 months, he was hospitalized due to lumbar pain. Thorax CT showed the presence of pulmonary nodule in right lung and abdominal CT presented heterogeneous mass with 2.5 cm of diameter in parenchyma of the right kidney. At that moment, even though the patient fulfilled the EULAR/PRINTO/PRES childhood GPA criteria,⁶ the renal biopsy showed a focal granulomatous interstitial nephritis with yeast fungal cells compatible with *Histoplasma* sp. (Figs. 1 and 2). He was treated only with liposomal amphotericin B (4.0 mg/kg/day) for 12 days, with improvement of ocular proptosis, epididymitis and renal mass. After that, he received itraconazole (300 mg/day for 3 days) and continued with 200 mg/day in two doses of this antifungal therapy for the last 6 months without any signs or symptoms.

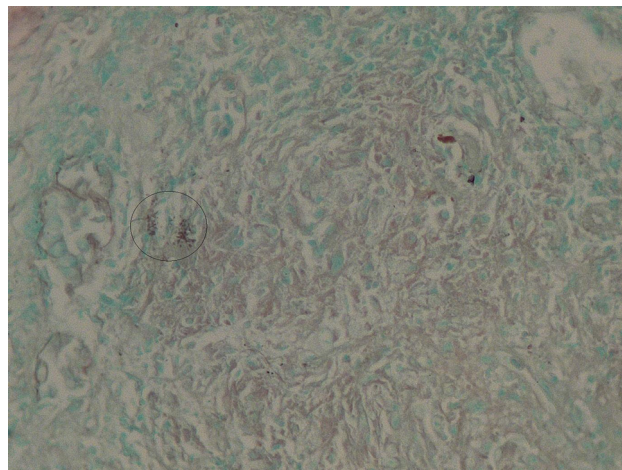


Fig. 1 – Yeast fungal cells compatible with *Histoplasma* sp. according to Grocott coloring.

Discussion

To our knowledge, this was the first case of disseminated histoplasmosis in pediatric population, mimicking GPA.^{5,7}

Histoplasmosis is caused by *Histoplasma* sp. which is a dimorphic fungal pathogen⁸ and usually affects the respiratory tract.⁹ This mycosis has been reported in Brazil, especially in the Midwestern and Southeastern regions.¹⁰ The disease can be classified in three subtypes: disseminated histoplasmosis (generally in immunosuppressed patients), acute pulmonary histoplasmosis (mainly in immunocompetent host) and chronic pulmonary histoplasmosis (associated with anatomic defect).¹¹

This fungal infection is mostly asymptomatic and self-restrictive in normal children. However it can cause disseminated and acute form in immunocompromised hosts, such as those who receive corticosteroids and immunosuppressive agents, after transplantation and in acquired immune-deficiency syndrome (AIDS) patients.⁹ Our patient

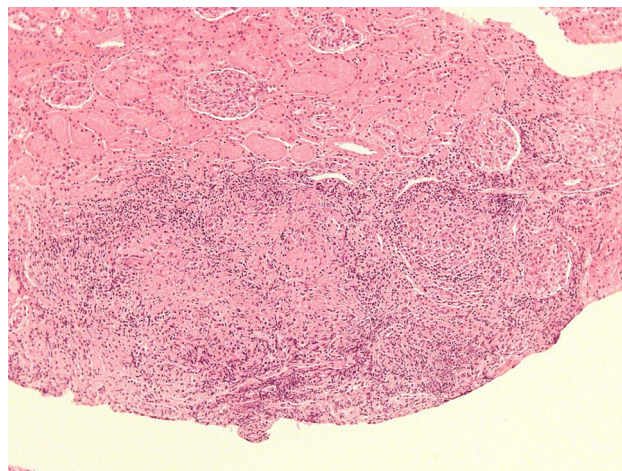


Fig. 2 – Focal granulomatous interstitial nephritis according to Hematoxylin-Eosin coloring.

had a long disease duration, probably due to adequate immune response. He also had a possible spontaneous remission and not requiring immunosuppressive therapy during this period. Indeed, disseminated form of histoplasmosis was only confirmed 6 years after the initial manifestations.

Histoplasmosis can lead to spectrum of clinical manifestations, generally includes fever, malaise and respiratory, as well as gastrointestinal symptoms, as observed herein.⁴ Additionally, epididymitis was rarely reported in adult patients infected by *Histoplasma* sp.¹² Of note, acute migratory polyarthritis is also seldom described in adult histoplasmosis population, generally self-limited and disappears without sequelae, as observed in our patient.¹³ Nevertheless, only one case of pediatric histoplasmosis with polyarthritis was reported.¹⁴

There are rare cases of histoplasmosis mimicking vasculitis. Generalized lymphadenopathy and renal involvement, mainly glomerulonephritis and chronic recurrent abscess of urogenital tract, were the main clinical manifestations of disseminated histoplasmosis in the two cases reported.^{5,11} In addition, association of disseminated histoplasmosis with GPA was diagnosed at necropsy in the other patient.⁷

Importantly, the confirmed diagnosis was obtained after fungus isolation in renal tissue, fulfilling "proven invasive fungal disease" for disseminated histoplasmosis according to National Institute of Allergy and Infectious Diseases Mycoses Study Group.¹⁵ Indirect tests of fungi showed low sensitivity to histoplasmosis diagnosis and *Histoplasma* serology positivity varied from 20% to 80%.⁴ Our patient had positive c-ANCA, a well known biomarker of GPA, in low titers and this autoantibody was rarely reported in histoplasmosis patients.¹⁶

Interestingly, our patient had three out of the six EULAR/PRINTO/PRES criteria for GPA, including upper airway involvement, pulmonary involvement and positive c-ANCA. The sensitivity and specificity for these criteria were 93.3% and 99.2%, respectively.⁶ In spite of the high specificity, these validated criteria were established for children and adolescents by comparing GPA with other primary vasculitis, thus reinforcing the relevance of the differential diagnosis with granulomatous infectious chronic diseases in pediatric population, as shown in the present case.

GPA is frequently a more severe systemic primary vasculitis that may lead to sinusitis, pulmonary nodules, cavitations or alveolar hemorrhage and serious pauci-immune glomerulonephritis, in contrast to the satisfactory outcome of our patient.¹⁷

The treatment of pediatric and adult histoplasmosis is performed according to Infectious Diseases Society of America guidelines. Amphotericin B and after itraconazol are recommended, as administered in our patient.¹⁸

In conclusion, we reported a patient with progressive disseminated histoplasmosis mimicking GPA. Histoplasmosis infection should also be considered in immunocompetent children and adolescents with uncommon clinical manifestations, such as joint, kidney and genital involvements.

Funding

This study was supported by Fundação de Amparo à Pesquisa do Estado de São Paulo (FAPESP – grants 2008/58238-4 to CAS),

by Conselho Nacional do Desenvolvimento Científico e Tecnológico (CNPQ – grant 302724/2011-7 to CAS), by Federico Foundation to CAS and by Núcleo de Apoio à Pesquisa "Saúde da Criança e do Adolescente" da USP (NAP-CriAd). We thank Dr. Varni for providing the Pediatric Quality of Life Inventory 4.0 (PedsQL 4.0) instrument.

Conflicts of interest

The authors declare no conflicts of interest.

REFERENCES

1. França CM, Cavalcante EG, Ribeiro AS, Oliveira GT, Litvinov N, Silva CA. Disseminated histoplasmosis in a juvenile lupus erythematosus patient. *Acta Reumatol Port.* 2012;37:276–9.
2. Silva MF, Ribeiro AS, Fiorot FJ, Aikawa NE, Lotito AP, Campos LM, et al. Invasive aspergillosis: a severe infection in juvenile systemic lupus erythematosus patients. *Lupus.* 2012;21:1011–6.
3. Sizemore TC. Rheumatologic manifestations of histoplasmosis: a review. *Rheumatol Int.* 2013;33:2963–5.
4. Assi MA, Sandid MS, Baddour LM, Roberts GD, Walker RC. Systemic histoplasmosis: a 15-year retrospective institutional review of 111 patients. *Medicine (Baltimore).* 2007;86:162–9.
5. Papo T, Boisnic S, Piette JC, Frances C, Beaufile H, Le TH, et al. Disseminated histoplasmosis with glomerulonephritis mimicking Wegener's granulomatosis. *Am J Kidney Dis.* 1993;21:542–4.
6. Ozen S, Pistorio A, Iusan SM, Bakkaloglu A, Herlin T, Brik R, et al. EULAR/PRINTO/PRES criteria for Henoch-Schönlein purpura, childhood polyarteritis nodosa, childhood Wegener granulomatosis, and childhood Takayasu arteritis: Ankara 2008. Part II: final classification criteria. *Ann Rheum Dis.* 2010;69:798–806.
7. Manepalli AN, Rush L. Disseminated histoplasmosis and Wegener's granulomatosis. *South Med J.* 1998;91:1156–8.
8. Darling ST. A protozoan general infection producing pseudotubercles in the lungs and focal necrosis in the liver, spleen, and lymph nodes. *JAMA.* 1906;46:1283.
9. Fischer GB, Mocelin H, Severo CB, de Mattos Oliveira F, Xavier MO, Severo LC. Histoplasmosis in children. *Paediatr Respir Rev.* 2009;10:172–7.
10. Guimarães AJ, Nosanchuk JD, Zancopé-Oliveira RMN. Diagnosis of histoplasmosis. *Braz J Microbiol.* 2006;37:1–13.
11. Ubesie AC, Okafo OC, Ibeziako NS, Onukwuli VO, Mbanefo NR, Uzoigwe JC, et al. Disseminated Histoplasmosis in a 13-year-old girl: a case report. *Afr Health Sci.* 2013;13:518–21.
12. Tichindelean C, East JW, Sarria JC. Disseminated histoplasmosis presenting as granulomatous epididymo-orchitis. *Am J Med Sci.* 2009;338:238–40.
13. Cuéllar ML, Silveira LH, Espinoza LR. Fungal arthritis. *Ann Rheum Dis.* 1992;51:690–7.
14. Verhaert K, Rodriguez M, Mendoza G, Delgadillo JL, Casaer P. Polyarthritis and humeral epiphysal separation in an infant with acute disseminated histoplasmosis. *Pediatr Infect Dis J.* 2002;21:352–3.
15. De Pauw B, Walsh TJ, Donnelly JP, Stevens DA, Edwards JE, Calandra T, et al. Revised definitions of invasive fungal disease from the European Organization for Research and Treatment of Cancer/Invasive Fungal Infections Cooperative Group and the National Institute of Allergy and Infectious Diseases Mycoses Study Group (EORTC/MSG) Consensus Group. *Clin Infect Dis.* 2008;46:1813–21.

16. Mead GE, Wilks D, McLaren K, Fergusson RJ. Oral histoplasmosis: a case report. *J Infect.* 1998;37:73-5.
17. Twilt M, Benseler S, Cabral D. Granulomatosis with polyangiitis in childhood. *Curr Rheumatol Rep.* 2012;14:107-15.
18. Wheat LJ, Freifeld AG, Kleiman MB, Baddley JW, McKinsey DS, Loyd JE, et al. Clinical practice guidelines for the management of patients with histoplasmosis: 2007 update by the Infectious Diseases Society of America. *Clin Infect Dis.* 2007;45: 807-25.