



REVISTA BRASILEIRA DE REUMATOLOGIA

www.reumatologia.com.br



SOCIEDADE BRASILEIRA
DE REUMATOLOGIA

Case report

Relapsing polychondritis with severe hearing loss



Francisco Vileimar Andrade de Azevedo*, Juliana de Deus e Albuquerque,
Deborah Pereira Gonçalves

Hospital Geral Dr. Waldemar Alcântara, Fortaleza, CE, Brazil

ARTICLE INFO

Article history:

Received 3 October 2013

Accepted 20 March 2014

Available online 5 January 2015

Keywords:

Policondritis

Auditive loss

Vasculitis

ABSTRACT

Relapsing polychondritis is an uncommon, immune-mediated condition characterized by episodes of inflammation of cartilaginous structures, especially the ears, nose, joints and respiratory tract. RP also affects proteoglycan-rich structures such as the eyes, heart, blood vessels and inner ear. Around one third of cases are associated with other diseases such as vasculitides, connective tissue diseases or myelodysplastic syndrome. Disorders of the inner ear occur in 40–50% of patients. Profound hearing loss is rare. The aim of this study was to describe the case of a patient with relapsing polychondritis associated with severe bilateral hearing loss and clinical manifestations of systemic vasculitis. This study reinforces the importance of an early diagnosis and immediate treatment in case of severe manifestations of the disease.

© 2014 Elsevier Editora Ltda. All rights reserved.

Policondrite recidivante com perda auditiva severa

RESUMO

Policondrite recidivante é uma condição rara, imunomediada, caracterizada por episódios de inflamação de estruturas cartilaginosas, principalmente orelhas, nariz, articulações e sistema respiratório. Acomete também estruturas ricas em proteoglicanos como olhos, coração, vasos sanguíneos e ouvido interno. Em torno de 1/3 dos casos apresentam associação com outras doenças como vasculites sistêmicas, doenças do tecido conectivo ou síndrome mielodisplásica. Desordens do ouvido interno ocorrem em 40%-50% dos pacientes. Perda auditiva profunda é rara. O objetivo do estudo foi descrever o caso de uma paciente com diagnóstico de policondrite recidivante associado à perda auditiva severa bilateral e manifestações clínicas de vasculite sistêmica. Este trabalho reforça a importância do diagnóstico precoce e do tratamento imediato em caso de manifestações severas da doença.

© 2014 Elsevier Editora Ltda. Todos os direitos reservados.

Palavras-chave:

Policondrite

Perda auditiva

Vasculite

* Corresponding author.

E-mail: vileimar@yahoo.com.br (F.V.A. de Azevedo).

<http://dx.doi.org/10.1016/j.rbre.2014.03.029>

2255-5021/© 2014 Elsevier Editora Ltda. All rights reserved.

Introduction

Relapsing polychondritis (RP) is a rare, immune-mediated condition characterized by episodes of inflammation of cartilaginous structures, especially the ears, nose, joints and respiratory system. It also affects proteoglycan-rich structures such as the eyes, heart, blood vessels and inner ear. The disease was first described in 1923 by Jaksch-Wartenhorst, who named the disease policondropaty. Pearson et al. introduced the term polychondritis in 1960.¹ The condition affects men and women equally and can be seen in all races. Its peak incidence is between 40 and 60 years.²

The etiology of RP is unknown. The genetic predisposition is suggested by the association with leukocyte antigen HLA-DR4.³ There is evidence for the emergence of autoimmunity, both humoral and cellular, against cartilage matrix components such as collagen types II, IX, XI and matrilin-1.²

We report the case of RP associated with severe hearing loss and vasculitic skin lesions.

Case report

DMD, 31 years old, female, with an everyday fever for two months, associated with chills, asthenia, polyarthritis, progressive bilateral hearing loss, tinnitus and episodes of dizziness. A month ago, her case evolved with the appearance of skin lesions on the hands and lower limbs, bilateral edema in the eyelids and ears, and a continuous pain in the distal region of 2nd right finger.

A physical examination revealed arthritis in wrists, elbows, ankles and proximal interphalangeal joints bilaterally. Her skin lesions were characterized by papules, pustules and purplish plaques on the hands, feet and anterior legs. In her oropharynx, aphthous ulcers were observed. It was also noticed a lobe-sparing swelling and pain on palpation in her pinnae, and bilateral conjunctival edema and erythema. The distal region of 2nd right finger exhibited a fixed painful cyanosis, associated with lower temperatures (Fig. 1).

Complementary tests showed normocytic and normochromic anemia (hemoglobin 7.9 g/dL), leukocytosis of 16,000/mm³ without shift, and elevation of inflammatory markers: C-reactive protein (CRP 196 mg/L), erythrocyte

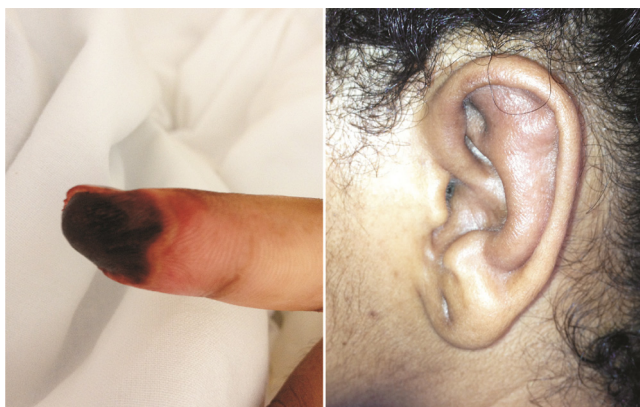

Fig. 1 – Left, vasculitic injury in 2nd right chirodactyl. Right, edema in the pinna, sparing the ear lobe.

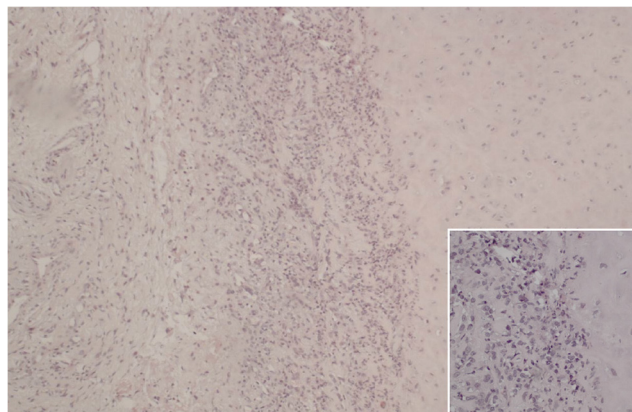


Fig. 2 – Hyaline cartilage (pinna) containing numerous inflammatory cells with matrix degeneration. (Hematoxylin-eosin – 100×). Inset: evidence of infiltrate with numerous neutrophils, in association with lymphocytes and histiocytes (400×).

sedimentation rate (ESR, 45 mm within 1 h). Serology for hepatitis B and C and HIV were negative, and the presence of autoantibodies (antinuclear antibody, antineutrophil cytoplasmic antibody, rheumatoid factor) and cryoglobulins were negative, as well as for AFB in lymph. Direct Coombs, dosage of complements, urinalysis and liver and renal functions were within normal standards. High digestive endoscopy, chest radiography, abdominal ultrasound, and Doppler for limbs were normal. The echocardiogram showed no changes. Blood and urine cultures showed no growth of microorganisms. Biopsies of skin lesions were performed in the 2nd right finger and pinna.

The diagnosis of relapsing polychondritis was proposed based on the clinical manifestations found and on results of complementary tests. In the light of these findings, a treatment with prednisone 1 mg/kg/day was initiated. The condition progressed to resolution of fever, conjunctival lesions and joint conditions, but with no improvement of the deafness and of ischemia in the 2nd chirodactyl after a week of treatment. At that moment, it was decided to start pulse therapy with methylprednisolone 1 g/day for three days.

The histopathology of the pinna showed the cartilage with lymphocytic and neutrophilic infiltrate associated with degeneration of hyaline matrix (Fig. 2). The histopathology of cutaneous lesions of the right hand revealed necrosis with extensive infiltration of neutrophils and lymphocytes.

After pulse therapy, the patient improved her skin condition and with the disappearance of ischemic pain in her 2nd chirodactyl; however, a significant loss of tissue by distal necrosis had already taken place. Normalization of inflammatory markers (ESR 10 mm within 1 h; PCR, 5 mg/L) and hemoglobin level (12 g/dL) was observed. Despite the complete resolution of edema and pain in her pinnae, the patient still remained with severe hearing loss. An otorhinolaryngological evaluation showed severe to profound sensorineural bilateral hearing loss; thus, pulse therapy with cyclophosphamide was initiated. After six months of monthly therapy with cyclophosphamide, the patient still remained with severe bilateral hearing loss.

Discussion

Patients with relapsing polychondritis exhibit a broad spectrum of clinical signs and symptoms that often increase the diagnostic challenge. The diagnostic criteria have been proposed by MacAdam, and require three or more of the following clinical features: bilateral auricular chondritis, seronegative non-erosive polyarthritis, nasal chondritis, ocular inflammation, respiratory tract chondritis and vestibulocochlear dysfunction.⁴ A recent modification of these criteria suggests that the diagnosis can be made by the presence of at least one of the MacAdam criteria, in association with histological confirmation of cartilage damage or chondritis in two distinct anatomical regions, with response to corticosteroids or dapsone.⁵

The patient described had bilateral chondritis of the pinna, bilateral conjunctivitis, seronegative non-erosive polyarthritis, sensorineural hearing loss and compatible histopathological findings, in compliance with criteria for the diagnosis of RP. A pinna biopsy was performed, but the histopathology is not always necessary to confirm the diagnosis.

Early diagnosis is a difficult task. Trentham and Le reported that the average time to its establishment is of 2.9 years.⁶ The most frequent clinical manifestation is an unilateral or bilateral inflammation of the ear cartilage, with an incidence ranging from 43 to 83%. Arthritis is the second most common manifestation. Around one third of cases occur in association with other diseases such as systemic vasculitides, connective tissue diseases or myelodysplastic syndrome.² In the case reported, besides auricular chondritis and polyarthritis the patient had severe sensorineural hearing loss and vasculitis-compatible cutaneous manifestations.

Disorders of the inner ear occur in 40–50% of patients. Profound hearing loss is rare.^{3,7} It was reported an association of cutaneous vasculitis and severe hearing loss, but the pathogenesis of this sensorineural injury is still uncertain. There is a possibility of an obliterative vasculitis in the inner auditory artery, causing otological injury.^{8,9} Another hypothesis, raised by Issing et al., would be the presence of antilabyrinth antibodies in the serum of patients with audiovestibular dysfunction.¹⁰

Mucocutaneous manifestations occur in more than 50% of cases; aphthous ulcers are the most common change.² A histological evaluation of skin lesions has shown leukocytoclastic vasculitis, neutrophilic infiltrates and thrombosis of skin vessels more often.¹¹

Vasculitis is histologically observed in 14–25% of cases and can be indolent or fulminant; additionally, it can occur simultaneously or independently of other manifestations.¹²

Drug treatment in patients with chondritis or arthritis should be started with nonsteroidal anti-inflammatory drugs, dapsone or corticosteroids. In those patients with severe manifestations, systemic vasculitis or sensorineural hearing loss, prednisone 1 mg/kg/day or pulse therapy with methylprednisolone is the treatment of choice. In cases of resistance to steroids, other immunosuppressive agents, including azathioprine, methotrexate and cyclophosphamide, are reported as being useful. Isolated case reports were published showing potentially beneficial results with antagonists of tumor

necrosis factor.² In the case reported, prednisone 1 mg/kg/day was started in a patient with a clinical picture compatible with cutaneous vasculitis and severe injury in her inner ear. As the condition has not evolved with the expected improvement of its most severe manifestations, we decided in favor of pulse therapy with methylprednisolone and cyclophosphamide.

It is estimated that the five-year survival is 74%. Patients younger than 51 years old and with systemic vasculitis have a worse prognosis.¹³

Relapsing polychondritis is a multisystem disease with variable presentation, which, in its spectrum of manifestations, can lead to serious and irreversible damage to target organs. It is likely, that in the case reported, the permanence of a severe hearing sequel, even with the institution of an aggressive therapy, is explained by the long time elapsed from the onset of clinical manifestations to the diagnosis and institution of therapy. An early diagnosis, combined with an aggressive therapy in cases of severe manifestations, can produce beneficial effects in the prevention of serious sequelae.

Conflicts of interest

The authors declare no conflicts of interest.

REFERENCES

- Pearson MC, Kline MH, Newcomer DV. Relapsing polychondritis. *N Engl J Med.* 1960;263:51–8.
- Gergely P Jr, Poor G. Relapsing polychondritis. *Best Pract Res Clin Rheumatol.* 2004;18:723–38.
- Zeuner M, Straub RH, Rauh G, Albert ED, Schölmerich J, Lang B. Relapsing polychondritis: clinical and immunogenetic analysis of 62 patients. *J Rheumatol.* 1997;24:96–101.
- MacAdam LP, O'Hanlan AM, Bluestone R, Reardon CM. Relapsing polychondritis: prospective study of 23 patients and a review of the literature. *Medicine (Baltimore).* 1976;55:193–215.
- Damiani JM, Levine HL. Relapsing polychondritis – report of ten cases. *Laryngoscope.* 1979;89:929–46.
- Trentham DE, Le CH. Relapsing polychondritis. *Ann Intern Med.* 1998;129:114–22.
- Cody DTR, Sones DA. Relapsing polychondritis: audiovestibular manifestations. *Laryngoscope.* 1971;81:208–22.
- Schuknecht H. Ear pathology in autoimmune disease. *Adv Oto Rhino Laryngol.* 1991;46:50–70.
- Michet C. Vasculitis and relapsing polychondritis. *Rheum Dis Clin N Am.* 1990;16:441–4.
- Issing WJ, Selover D, Schulz P. Anti-labyrinthine antibodies in a patient with relapsing polychondritis. *Eur Arch Otorhinolaryngol.* 1990;256:163–6.
- Frances C, el Rassi R, Laporte JL, Rybojad M, Papo T, Piette JC. Dermatologic manifestations of relapsing polychondritis. A study of 200 cases at a single center. *Medicine (Baltimore).* 2001;80:173–9.
- Barzegar C, Vrtovnik F, Devars JF, Mignon F, Pradalier A. Vasculitis with mesangial IgA deposits complicating relapsing polychondritis. *Clin Exp Rheumatol.* 2002;20:89–91.
- Michet CJ Jr, McKenna CH, Luthra HS, O'Fallon WM. Relapsing polychondritis: survival and predictive role of early disease manifestations. *Ann Intern Med.* 1986;104:74–8.