



REVISTA BRASILEIRA DE REUMATOLOGIA

www.reumatologia.com.br



Case report

Antisynthetase Syndrome: two case reports and literature review[☆]



Lívia Regina Theilacker^a, Fabíola Sampaio Brandão^a, Fernanda Velloso Goulart^a,
João Luiz Pereira Vaz^b, Luiz Octávio Dias D'Almeida^a,
Maria Cecília da Fonseca Salgado^{a,b,*}

^a Gaffré and Guinle University Hospital, Universidade Federal do Estado do Rio de Janeiro, Rio de Janeiro, RJ, Brazil

^b Department of Rheumatology, Escola de Medicina e Cirurgia, Universidade Federal do Estado do Rio de Janeiro, Rio de Janeiro, RJ, Brazil

ARTICLE INFO

Article history:

Received 4 October 2012

Accepted 3 May 2013

Available online 26 November 2014

Keywords:

Antisynthetase Syndrome

Polydermatomyositis

Anti Jo1

Interstitial lung disease

ABSTRACT

Antisynthetase Syndrome (ASS) is characterized by myositis, Raynaud's phenomenon, fever, interstitial lung disease, mechanic's hands and arthropathy associated with the presence of antibodies against tRNA synthetase, especially anti-Jo-1. This article aims to review the literature on ASS and report two cases where the first is a patient with polymyositis who developed subluxation on the proximal interphalangeal joint of bilateral first right finger after a few years of the disease, associated with pulmonary manifestations and positive anti-JO-1. In the second case, we present a patient with dermatomyositis, who developed a subluxation of the two first fingers, anti-Jo1 positive and chest CT changes, but without clinical evidence of pulmonary involvement. These cases reveal the importance of performing early diagnosis. The authors describe two cases of this rare syndrome, emphasizing the severity of interstitial lung disease and arthritis.

© 2014 Elsevier Editora Ltda. All rights reserved.

Síndrome Antissintetase: relato de dois casos e revisão da literatura

RESUMO

A Síndrome Antissintetase (SAS) é caracterizada por miosite, fenômeno de Raynaud, febre, doença pulmonar intersticial, artropatia e *mãos de mecânico* associados à presença de anticorpos contra a sintetase do RNAt especialmente anti-Jo-1. Este artigo tem como objetivo revisar a literatura sobre SAS e relatar dois casos, sendo o caso 1 de uma paciente com Polimiosite que desenvolveu, após alguns anos de doença, subluxação da articulação interfalangeana proximal do primeiro quirododático direito, associada a manifestações pulmonares e anti-Jo-1 positivo. O caso 2 é de uma paciente com Dermatmiosite que evoluiu com subluxação dos dois primeiros quirodóctilos, anti-Jo-1 positivo e alterações pulmonares intersticiais na

Palavras-chave:

Síndrome antissintetase

Polidermatomiosite

Anti-Jo 1

Doença intersticial pulmonar

[☆] Study conducted at Department of General Medicine, Gaffré and Guinle University Hospital, School of Medicine and Surgery, Universidade Federal do Estado do Rio de Janeiro, Rio de Janeiro, RJ, Brazil.

* Corresponding author.

E-mail: cecilsalgado@yahoo.com.br (M.C. da Fonseca Salgado).

<http://dx.doi.org/10.1016/j.rbre.2013.05.006>

2255-5021/© 2014 Elsevier Editora Ltda. All rights reserved.

TC de tórax, porém assintomática. Esses casos demonstram a importância do diagnóstico precoce. Os autores descrevem dois casos dessa síndrome rara, enfatizando a sua gravidade do ponto de vista pulmonar e articular.

© 2014 Elsevier Editora Ltda. Todos os direitos reservados.

Introduction

Idiopathic inflammatory myopathies are a heterogeneous group of acquired muscular diseases characterized by various types and degrees of skeletal muscle inflammation.¹ Polymyositis (PM) and dermatomyositis (DM) are the two major conditions making up this group of diseases. They are associated with serum antibodies related to particular clinical manifestations, therefore marking important clinical subgroups. The largest subgroup in muscular inflammatory diseases comprises the Antisynthetase Syndrome (ASS), firstly described by Marguerie et al. in 1990 as the triad polymyositis, diffuse interstitial lung disease, and self-antibodies to aminoacyl-tRNA synthetase (anti-ARS). It is currently characterized by the production of antibodies to tRNA synthetase, with anti-Jo-1 being the best known of these antibodies associated with myositis, interstitial lung disease, joint disease, fever, Raynaud's phenomenon and "mechanic's hands".^{2,3} This is a rare disease with an incidence in general population that is still unknown and a twofold higher prevalence in females. The interstitial lung disease (ILD) is the main morbidity and mortality determinant in the syndrome.

Case 1

A white craftswoman aged 61 with Hashimoto's thyroiditis was seen in the rheumatology clinic in January 2001 reporting some manifestations that were consistent with Raynaud's phenomenon, but she did not have muscle weakness or joint pain. A number of laboratory tests were obtained and the results are as follows: LDH: 628 (RV: 115-225); CK: 1041 (RV: 96-140); aldolase: 20.6 (RV: 3-7); ALT: 20 (RV: 7-56); AST: 36 (RV: 5-40); rheumatoid factor (RF): 12 (RV=up to 20), antinuclear antibody (ANA): negative; anti-Jo-1: positive; chest X-ray: no abnormalities were seen. Corticosteroids were initiated and muscle enzymes were normalized 4 months later. In January 2002, the patient complained of dyspnea and the chest X-ray showed a bilateral lung base infiltrate, in addition to elevated muscle enzymes. In May 2002, a chest computed tomography (CT) was obtained and diffuse "ground glass" imaging was seen, in addition to a pulmonary function test exhibiting a restrictive pattern. At that time, the patient complained of fever. In 2004, she had an interstitial thickening of the right upper lobe and both bases on chest X-ray, with dense bands showing a residual fibrous appearance in the right lower lobe.

In 2007, due to a respiratory and laboratory worsening, a monthly pulse therapy with cyclophosphamide was initiated. In that very year, she had a synovitis at the first finger of the right hand, progressing to a bilateral proximal interphalangeal

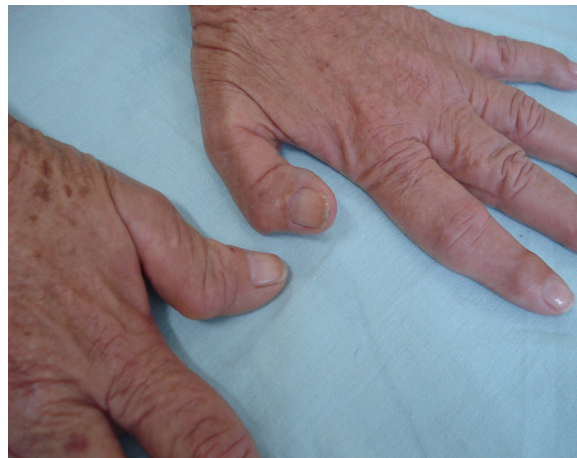

Fig. 1 – Bilateral subluxation of distal interphalangeal joints (case 2).

subluxation of the first finger. Hand X-ray: slightly reduced carpometacarpal joint space.

Case 2

A white female patient aged 78, born in Portugal and who retired as an embroiderer, presented with a classic dermatomyositis since 1980. She had used corticosteroids for 11 years, with symptom remission (proximal muscle weakness, heliotrope rash, Gottron's papules, Raynaud's phenomenon, joint pain, and skin rash). Remission was maintained. Five years earlier, she had presented a deformity with distal interphalangeal joint subluxation of the first fingers (Fig. 1). A hand X-ray in 2009 showed bilateral interphalangeal (IP) arthrosis signs from the 2nd to the 5th finger and at the thumb IP, unilateral rizarthrosis and right pyramidal osteophytes. Chest CT: slight reticular pattern, subpleural lines, and ground glass opacities in the lung periphery. Positive anti-Jo-1.

Discussion

The Antisynthetase Syndrome is characterized by myositis, interstitial lung disease, joint pain, arthritis, "mechanic's hands", fever, and Raynaud's phenomenon. It is associated with self-antibodies to tRNA synthetase, mainly anti-Jo-1. In general, the myositis either precedes or is concomitant with the lung involvement, as in the first reported case, in which the patient only had Raynaud's phenomenon, elevated enzymes (LDH, CK, and aldolase) and positive anti-Jo-1, manifesting dyspnea and chest CT changes with diffuse ground glass imaging and restrictive pattern on the PFT. The patient in case 2,

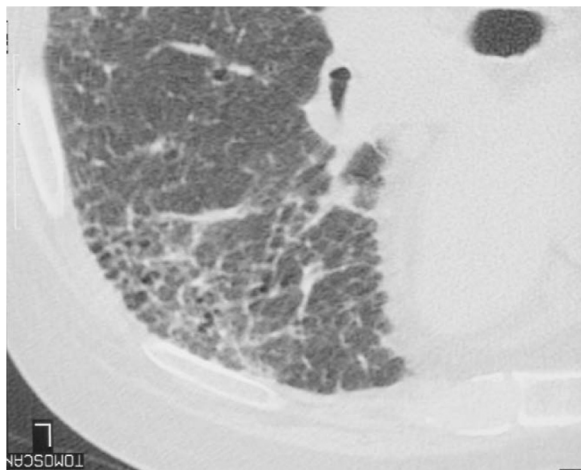


Fig. 2 – Ground glass imaging (case 2).

in turn, reported no respiratory complaints, but her chest CT has also demonstrated similar changes (Fig. 2).

Lung impairment is found in over 60% of the cases and is the major morbidity cause.⁴ Therefore, in some cases, the interstitial lung disease is predominant in the Antisynthetase Syndrome. The interstitial disease can have a slow onset and lead to acute respiratory failure, sometimes highly refractory to treatment.⁵

Adult respiratory distress syndrome, bronchiolitis obliterans organizing pneumonia (BOOP), and fibrosing alveolitis are associated with ILD.⁶ Lung manifestations include dyspnea, cough, thoracic pain, physical exercise intolerance and respiratory failure.

Radiological imaging of lungs can reveal an interstitial pattern, and ground glass lesions, linear opacities, pulmonary parenchyma consolidations, and micronodules can also be seen on the computed tomography. The pulmonary function test shows a restrictive pattern. The patients with BOOP usually have a more favorable prognosis compared with those with either diffuse alveolar lesions or interstitial pneumonia. Anti-Ro antibodies presence has been associated with pulmonary fibrosis in the Antisynthetase Syndrome.⁷⁻⁹

Joint involvement affects 50% of the cases with joint pain or arthritis with or without bone erosions. All the patients had joint symptoms early in the disease.⁵ Typically, the arthritis in idiopathic inflammatory myopathies is light, nondeforming, and nonerosive,¹⁰ although a subgroup of patients might develop an erosive and/or subluxing joint disease. The following joints are commonly affected: distal and proximal interphalangeal joints, metacarpophalangeal joints, wrists, elbows, and knees.

Meyer et al.¹¹ described 40 patients with ASS and joint manifestations and they were classified into three categories: subluxing joint disease of thumb distal interphalangeal joints ($n=6$); symmetrical polyarthritis with or without erosion ($n=24$) and isolated arthralgia ($n=10$). Oddis et al.¹² described nonerosive joint disease of proximal and distal interphalangeal joints (floppy thumb).

Both our cases had a subluxing joint disease of interphalangeal joints (case 1: PIPJ of the first finger; case 2: DIPJ of the first finger).

Raynaud's phenomenon is early in 2/3 of patients and can precede the myositis in years. It is more frequently found in anti-Jo-1-positive patients.³

"Mechanic's hands" are a hyperkeratosis, scaling, and fissure in fingertips and lateral aspects of the fingers, being more frequently found in the Antisynthetase Syndrome and interstitial lung disease.

A skin vasculitis has also been described. The heart involvement does not have a different prevalence from that in polymyositis/dermatomyositis. A mesangial proliferative glomerulonephritis has been observed, but it is rare and has a good prognosis.¹³ Regarding idiopathic inflammatory myopathies associated with a interstitial lung lesion, recent reports show a favorable response to prednisone: 30-40% of the patients had an improvement and 20-40% became stable for symptoms and pulmonary function. A small group of patients is resistant to corticosteroids. There are remission reports with azathioprine, methotrexate, cyclophosphamide, cyclosporine, tacrolimus or mycophenolate mofetil.^{1,14} A late relapse following an initial remission is more common in the Antisynthetase Syndrome.

Bruhler et al. described a patient aged 57 with an Antisynthetase Syndrome treated by prednisone (high doses) and methotrexate 15 mg/week who had a good response. A severe clinical and laboratory relapse was seen three months later. Rituximab (2×1 -g infusions) was introduced, with myositis and ILD improvement.⁹ Studies suggest that CD20 depletion therapy might be valuable in refractory Antisynthetase Syndrome.¹⁴

Anti-Jo-1-positive myopathies have a worse prognosis than other inflammatory myopathies.¹⁵

Tests for anti-Jo-1 should be obtained in patients with inflammatory muscle disease, as well as a screening for interstitial lung disease.³

Conflicts of interest

The authors declare no conflicts of interest.

REFERENCES

- Solomon J, Swigris JJ, Brown KK. Doença pulmonar intersticial relacionada a miosite e a síndrome antissintetase. *J Bras Pneumol.* 2011;37:100-9.
- Masseau AI, Hamidou M, Agard C, Grolleau J-Y, Chérin P. Review antisynthetase syndrome. *Joint Bone Spine.* 2003;70:161-8.
- Katzap E, Barilla-LaBarca ML, Marder G. Review antisynthetase syndrome. *Curr Rheumatol Rep.* 2011;13:175-81.
- Shinjo SK, Neto ML. Síndrome antissintetase anti-Jo-1. *Rev Bras Reumatol.* 2010;50:492-500.
- Gugliemi S, Merz M, Gugger M, Suter C, Nicod LP. Acute respiratory distress syndrome secondary to antisynthetase syndrome is reversible with tacrolimus. *Eur Respir J.* 2008;31:213-7.
- Sauty A, Rochat Th, Schoch OD, Hamacher J, Kurt A-M, Dayer J-M, et al. Pulmonary fibrosis with predominant CD8 lymphocytic alveolitis and anti-Jo-1 antibodies. *Eur Respir J.* 1997;10:2907-12.

7. Corte R, Naco A, Locaputo A, Dolzani F, Trotta F. In patients with antisynthetase syndrome the occurrence of anti-Ro/SSA antibodies causes a more severe interstitial lung disease. *Autoimmunity*. 2006;39:249-53.
8. Vánca A, Csípo I, Németh J, Dévényi K, Gergely L, Dankó K. Characteristics of interstitial lung disease in SS-A positive/Jo-1 positive inflammatory myopathy patients. *Rheumatol Int*. 2009;29:989-94.
9. Brulhart L, Waldburger JM, Gabay C. Rituximab in the treatment of antisynthetase syndrome. *Ann Rheum Dis*. 2006;65:974-5.
10. Wasco MC, Carlson GW, Tomaino MM, Oddi CV. Dermatomyositis with arthropathy association with the anti Pl-7 antibody. *J Rheumatol*. 1999;26:2693-4.
11. Meyer O, Charlanne H, Cherin P, Allanore Y, Coquerelle P, Grardel B, et al. Subluxing arthropathy: an unusual manifestation of the antisynthetase syndrome. *Ann Rheum Dis*. 2009;68:152-3.
12. Oddis CV, Medsger TALA Jr. A subluxing arthropathy associated with the anti-Jo1 antibody in polymyositis/dermatomyositis. *Arthritis Rheum*. 1990;33:1640-5.
13. Hervier B, Masseur A, Mussini JM, Audrain M, Hamidou MA. Long-term efficacy of mycophenolate mofetil in a case of refractory antisynthetase syndrome. *Joint Bone Spine*. 2009;76:575-6.
14. Sem M, Molberg O, Lund MB, Gran JT. Rituximab treatment of the anti-synthetase syndrome - a retrospective case series. *Rheumatology*. 2009;48:968-71.
15. Patel HC, Lauder NN. The antisynthetase syndrome. *Am J Med*. 2011;124:3-4.