



REVISTA BRASILEIRA DE REUMATOLOGIA

www.reumatologia.com.br



Case report

Paraneoplastic necrotizing myopathy – a case report



Miopatia necrosante paraneoplásica – relato de caso

Alberto Pereira Ferraz*, Fabio Freire José

Universidade Federal de São Paulo (UNIFESP), Divisão de Medicina Interna, São Paulo, SP, Brazil

ARTICLE INFO

Article history:

Received 30 July 2013

Accepted 16 October 2013

Available online 26 November 2014

Introduction

Immune-mediated necrotizing myopathy is a rare and recently described form of idiopathic inflammatory myopathy, characterized as a necrotizing myopathy with minimal or no inflammatory infiltrate on muscle biopsy. The clinical features of symmetrical proximal muscle weakness and acute or subacute onset may be misunderstood with polymyositis or dermatomyositis. This condition has a wide range of reported outcomes, from fast progression with no remission to complete recovery. To the best of our knowledge up to date there is no case reported in Brazil of immune-mediated necrotizing myopathy, and no one in Latin America related to cancer. Here we described a case of paraneoplastic necrotizing myopathy secondary a tubo-ovarian adenocarcinoma.

Case report

A 61-year-old woman, married, white, was admitted with the chief complaint of pain and progressive weakness of the lower limbs, with ascension to upper members, of 4 weeks of

development, associated with dysphagia and dysphonia. She also reported weight loss of 10kg in that period. She previously had hypertension and hypothyroidism. She underwent a total hysterectomy 21 years ago due to uterine leiomyomatosis. She also underwent bariatric surgery, abdominoplasty and mammoplasty for about 9 years. There was no history of alcoholism, smoking or use of recreational drugs. The family history was positive for acute myocardial infarction and stroke.

On physical examination the patient was afebrile and appeared well. The pulse was 68bpm, the blood pressure 130 × 85 mmHg, breathing frequency of 20 incursions per minute. The lungs and heart were normal. There was a presence of a median scar on abdomen. Edema of lower limbs and plastering of calves were absent. Neurological examination showed a weakness of proximal muscles graduated in 2 and weakness of distal muscles graduated in 4 on a scale of 0–5. The deep tendon reflexes were graduated in 1 on a scale of 0–4. The plantar cutaneous reflex was in flexion bilaterally. There were no other abnormalities on neurological examination.

Additional laboratory evaluation showed a creatine kinase of 7874 U/l (normal range: 26–192), lactic acid dehydrogenase 1350 U/l (reference: <50), aspartate aminotransferase 452 U/l

* Corresponding author.

E-mail: albertopferraz@gmail.com (A.P. Ferraz).

<http://dx.doi.org/10.1016/j.rbre.2013.10.007>

2255-5021/© 2014 Elsevier Editora Ltda. This is an open access article under the CC BY-NC-ND license (<http://creativecommons.org/licenses/by-nc-nd/4.0/>).

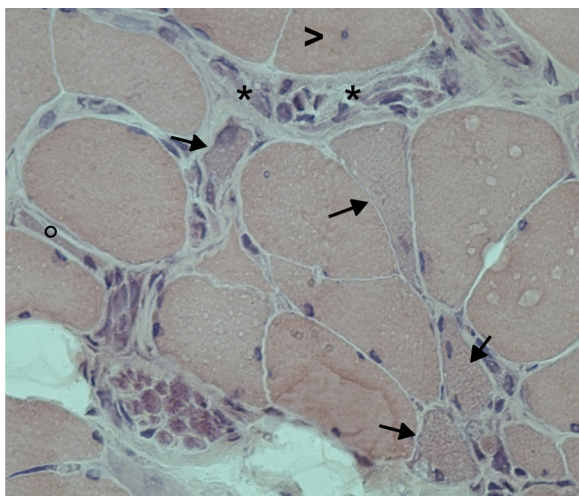


Fig. 1 – Necrosis with macrophagy (asterisk), nuclear centralization (arrowhead), regenerating fibers (arrows) and atrophic fiber (circle), in the absence of inflammatory infiltrate. HE X250. Given by Dr. Beny Schmidt, associate professor of pathological anatomy, chief of the Neuromuscular Laboratory – UNIFESP.

(<32), alanine aminotransferase 679 U/l (<33). Serological tests for hepatitis B and C and for HIV were negative. In immunological parameters, the antinuclear factor was positive with a speckled pattern, titer of 1/160, but anti-JO and anti-native DNA antibody, anti-ribonucleoprotein, anti-Ro, anti-La, anti-SCL70 were negative. Cerebrospinal fluid analysis was positive for neoplastic cells. The level of CA125 was increased: 6013 U/mL (reference: <35).

Electromyography showed a pattern of predominantly proximal myopathy, polyphasic motor unit potentials reduced in amplitude and duration. Biopsy of the deltoid muscle revealed atrophy of muscle fibers, with homogeneous necrosis and the presence of macrophagy, with absence of inflammatory infiltrate (Fig. 1). The search for malignancies of gastrointestinal tract by upper gastrointestinal endoscopy and colonoscopy resulted negative. Screening for breast cancer with mammography and research of tumor marker CA 15.3 was negative. Computed tomography (CT) of the chest showed bilateral pulmonary thromboembolism, reinforcing the idea of underlying malignancy neoplasia (Fig. 2). A CT of the abdomen and pelvis showed retroperitoneal lymphadenopathy involving the chain interaortocaval, pelvic lymphadenopathy and lymphonodes around the bladder. MRI of the abdomen and pelvis showed the presence of retroperitoneal node 6 centimeters of larger diameter and the presence of vascularized solid nodule in the right ovary. Magnetic resonance imaging of the skull and spine showed no neoplastic focus. White matter of the brain hemispheres had foci of ischemia, while column showed degenerative changes, as well as atrophy of the posterior paraspinal muscle groups, with replacement of muscle fibers by fat, especially in the lumbar spine.

The biopsy of the retroperitoneal mass showed adenocarcinoma infiltration. The patient then underwent exploratory laparotomy with bilateral oophorectomy, resection of

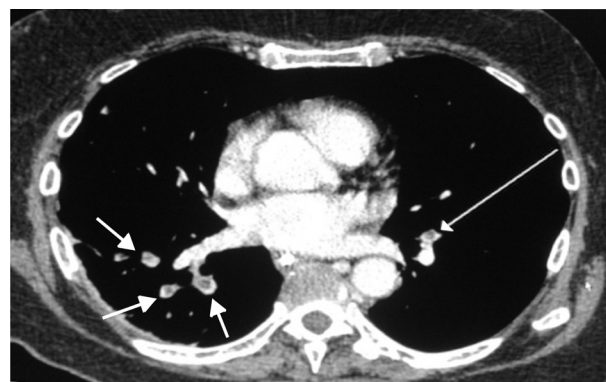


Fig. 2 – Filling defects of segmental branches of the right lower lobe and left lower lobe due to pulmonary thromboembolism.

paraortic mass, omentectomy and pelvic lymphadenectomy. The study by immunohistochemistry concluded that it was a right tubo-ovarian high-grade serous carcinoma with metastasis to the left ovary, periaortic lymphonodes and omentum. The patient died 2 weeks after surgery due to sepsis after severe pancytopenia, possibly due to neoplastic marrow infiltration, although bone marrow biopsy for confirmation was not performed.

Discussion

Immune-mediated necrotizing myopathy is now recognized as part of the group of Idiopathic Inflammatory Myopathies that include polymyositis, dermatomyositis, sporadic inclusion body myositis, juvenile dermatomyositis and amyopathic and hypomyopathic dermatomyositis. This uncommon condition is frequently confused with polymyositis because of their symptoms of weakness of proximal muscles and high levels of creatine kinase.¹ It may occur in several settings, including viruses, connective tissue diseases, in association with the use of certain drugs, including statins and as a paraneoplastic disorder.

The immune-mediated necrotizing myopathy that occurs in association with use of statins persists despite drug discontinuation, unlike the more typical statin-related myopathy that resolves after drug discontinuation. In comparison to the toxic myopathy, the course of a necrotizing myopathy may be self-limited, and recovery may occur after the offending agent is discontinued, occasionally over weeks to months. Like polymyositis and dermatomyositis, it may precede the identification of a tumor. The most common cancers are gastrointestinal tumors, small cell lung cancer, and breast cancer.²

These patients may have high elevations of creatine kinase levels, greater than 10 times the upper limits of normal, with acute or subacute onset of symptoms, although a chronic disease course may also occur. In the physical examination proximal muscle weakness is found.¹ As with other idiopathic inflammatory myopathies, electromyography should be performed to confirm a myopathic process characterized by polyphasic motor unit action potentials of short duration and

low amplitude with increased insertional and spontaneous activity with fibrillation potentials, sharp waves, or repetitive discharges and to target a muscle for biopsy. It is recommended that the same muscle on the opposite side should be chosen for biopsy.¹

The pathophysiology of this disease is still incompletely understood. Statin-induced necrotizing myopathy has been associated with an antibody against the 3-hydroxy-3-methylglutaryl-coenzyme A reductase (HMGCR) protein that is upregulated in regenerating muscle fibers.¹ T cell-mediated immune responses as well as humoral factors may be involved. The small number of inflammatory cells in muscle specimens of patients with necrotizing myopathy raises the possibility of a toxic molecule mediating the syndrome, but the response to steroids or immunoglobulins is more compatible with an immune-mediated process.³

Histopathologically, in paraneoplastic necrotizing myopathies a heterogeneous pattern of necrosis are found, ranging from sparse, segmental necrotic lesions to massive necrosis.^{2,4,5} Macrophages surround necrotic muscle fibers, and atrophic and regenerating fibers are present. Immunostaining reveals T lymphocytes (CD3) and macrophages (CD68) around necrotic and regenerating muscle fibers.¹

Despite the new evidences, it has recently been shown how rheumatologists and neurologists often differ in classification of myopathies. While neurologists are specialized in diagnosis utilizing electromyography and muscle biopsy interpretation, rheumatologists, on the contrary, are typically trained in making a clinical diagnosis, understanding the role of autoantibody association.⁶ Nevertheless, effective communication and synergy between subspecialists, using both strategies to make diagnosis and to classify, is nowadays required to improve communication and achieve consistent conclusion in clinical trials.

Conclusion

Immune-mediated necrotizing myopathy secondary to statin has already been reported in Latin America by Opazo et al,⁷ but until our present knowledge this is the first case of immune-mediated necrotizing myopathy reported in Brazil and the first related to neoplasia in Latin America.

This case report emphasizes the need for clinical suspicion of cancer in patients with idiopathic inflammatory myopathies and highlights the immune-mediated necrotizing myopathy, one of its more recently described clinical forms. The case showed good correlation with what is found in the literature regarding the clinical manifestations. Ovarian cancer is not the neoplasm most commonly found in paraneoplastic necrotizing myopathies. Therefore, this case demonstrates the need to investigate other sites beyond gastrointestinal, lung and breast. The recovery of the symptoms of muscle weakness after treatment of the underlying cancer could not be assessed due to the advanced cancer stage of the patient.

Conflicts of interest

The authors declare no conflicts of interest.

REFERENCES

1. Ernst FC, Reed AM. Idiopathic inflammatory myopathies: current trends in pathogenesis, clinical features, and up-to-date treatment recommendations. *Mayo Clin Proc.* 2013;88:83-105.
2. Wegener S, Bremer J, Komminoth P, Jung HH, Weller M. Paraneoplastic necrotizing myopathy with a mild inflammatory component: a case report and review of the literature. *Oncology.* 2010;3:88-92.
3. Bronner IM, Hoogendijk JE, Wintzen AR, Van der Meulen MF, Linszen WH, Wokke JH, et al. Necrotising myopathy, an unusual presentation of a steroid-responsive myopathy. *J Neurol.* 2003;250:480-5.
4. Smith B. Skeletal muscle necrosis associated with carcinoma. *J Pathol.* 1969;97:207-10.
5. Urich H, Wilkinson M. Necrosis of muscle with carcinoma: myositis or myopathy? *J Neurol Neurosurg Psychiatry.* 1970;33:398-407.
6. Christopher-Stine L. Neurologists are from Mars Rheumatologists are from Venus: differences in approach to classifying the idiopathic inflammatory myopathies. *Curr Opin Rheumatol.* 2010;22:623-6.
7. Opazo DE, Quiroga ON. Miopatía necrotizante autoinmune (NAM): a propósito de un caso clínico. *Ver Chil Reumato.* 2012;28:160-3.