



REVISTA BRASILEIRA DE REUMATOLOGIA

www.reumatologia.com.br



Case report

Skeletal abnormalities of tricho-rhino-phalangeal syndrome type I



Guilherme Monteiro de Barros, Adriana Maria Kakehasi*

Universidade Federal de Minas Gerais, Belo Horizonte, Belo Horizonte, MG, Brazil

ARTICLE INFO

Article history:

Received 24 April 2014

Accepted 26 August 2014

Available online 9 March 2015

Keywords:

Tricho-rhino-phalangeal syndrome type I

Joint malformations

Genetic syndrome

ABSTRACT

The tricho-rhino-phalangeal syndrome (TRPS) type I is a rare genetic disorder related to the TRPS1 gene mutation in chromosome 8, characterized by craniofacial abnormalities and disturbances in formation and maturation of bone matrix. The hallmarks are sparse and brittle hair, tendency to premature baldness, bulbous nose called pear-shaped, long and flat filter and low ear implantation. The most noticeable skeletal changes are clinodactyly, phalangeal epiphyses of the hands appearing as cone-shaped, short stature and hip joint malformations. We report a case of a teenager boy diagnosed with TRPS and referred for rheumatologic evaluation due to joint complaints.

© 2014 Elsevier Editora Ltda. All rights reserved.

Anormalidades esqueléticas da síndrome tricorinofalangiana tipo I

RESUMO

A síndrome tricorinofalangiana (STRF) tipo I é uma doença genética rara, relacionada com a mutação no gene TRPS1 do cromossomo 8. É caracterizada por anomalias craniofaciais e distúrbios na formação e maturação da matriz óssea. As características são cabelos ralos e quebradiços, tendência à calvície prematura, nariz bulboso em formato de pera, filtro nasal longo e plano e baixa implantação das orelhas. As alterações esqueléticas mais notáveis são a clinodactilia, as epífises das falanges das mãos em forma de cone, a baixa estatura e as malformações na articulação do quadril. Relata-se o caso de um adolescente diagnosticado com STRF e encaminhado para avaliação reumatológica em decorrência de queixas articulares.

© 2014 Elsevier Editora Ltda. Todos os direitos reservados.

Palavras-chave:

Síndrome tricorinofalangiana tipo I

Malformações articulares

Síndrome genética

* Corresponding author.

E-mail: amkakehasi@gmail.com (A.M. Kakehasi).

Introduction

First described by Giedion, the tricho-rhino-phalangeal syndrome (TRPS) type I is a rare disease caused by TRPS1 gene haploinsufficiency, which is located in chromosome 8.¹ This gene is related to decoding of transcription factors involved in regulation of bone perichondrium mineralization and proliferation and apoptosis of chondrocytes. The TRPS is classified into three subtypes: types I and III have distinct clinical presentations according to TRPS1 mutation, differing clinically by degree of malformations,² while type II has associated mental retardation and bone exostoses as a landmark.³ In most cases the syndrome is autosomal dominant and marked by short stature, fine hair and alopecia, pear-shaped nose, craniofacial and skeletal malformations, and phalangeal joint deformity. Although rare, individuals may present to the rheumatologist at different ages, bringing differential diagnoses including juvenile idiopathic arthritis and Legg-Calvé-Perthes disease. Besides changes of the hands and feet, degeneration of the hip joint may be a serious consequence due to the potential for early functional impairment. This genetic disease presents broad clinical spectrum and important impact on patient and family, requiring multidisciplinary approach.

Case report

A 17-year-old boy was evaluated with complaints of chronic pain in the hips and interphalangeal joints of the hands. In the last 7 months, hip joint pain was also observed during sports activities, which led the patient for musculoskeletal system evaluation. No morning stiffness and no significant inflammatory signs were noted. There was no report of fever or weight loss. Five years ago, his mother observed symmetric deformity in proximal interphalangeal joints of hands characterized by local swelling and insidious mechanical pain. In 2009, during the investigation of short stature, the patient was diagnosed with tricho-rhino-phalangeal syndrome type I through genetic study. Cognitive development was normal.

Physical examination showed triangular face with the nose elongated (pear-shaped), the presence of median nasolabial groove and tapering of the lips, thin hair and prominent jaw, prominence of the interphalangeal joints of the hands, no redness or local heat (Fig. 1). There was no pain on manipulation and no movement limitation in upper limbs. Discreet genu varus, and pain with limitation of movement were observed in both hip joints. Laboratory tests were essentially normal: erythrocyte sedimentation rate was 2 mm/h, C-reactive protein <6 mg/L (reference value <8 mg/L), antinuclear antibodies and rheumatoid factor negative, creatinine and blood count cells were also normal. Radiography of the hands showed bone dimorphism in the distal phalanx of the thumb and the middle phalanx of the other fingers, characterized by shortening and widening of the proximal metaphysis and proximal epiphysis triangular shape (Fig. 2). Radiography of the hip joints showed *coxa plana* and mild subchondral sclerosis in the right femoral acetabulum with preserved joint space. Magnetic resonance imaging (MRI) ruled out aseptic necrosis of the hip showing flattening of the femoral necks and labral hypertrophy. Assessment of bone mineral density (BMD) and body composition by dual-energy X-ray absorptiometry (equipment Hologic Discovery W) showed low BMD in lumbar spine (Z-score -2.3) and limitrophe bone mineral content value (Z-score of -2.0). Patient and his family received support about the diagnosis and recommendations for articular structures preservation.

Discussion

TRPS1 encodes a transcription factor for a zinc-finger protein at the 8q24 locus. The completely penetrant autosomal dominant pattern expressed, in most cases, indicates haploinsufficiency as the cause for the condition. Tricho-rhino-phalangeal syndrome type I is characterized by features of a bulbous-tipped nose, sparse, slow-growing scalp hair, and cone-shaped epiphyses in the long bones of the hand.^{4,5} Type II is distinguished by concomitant mental deficiencies and skeletal exostoses, and type III by simultaneous severe short stature and shortening of the metacarpals and phalanges.⁴⁻⁶

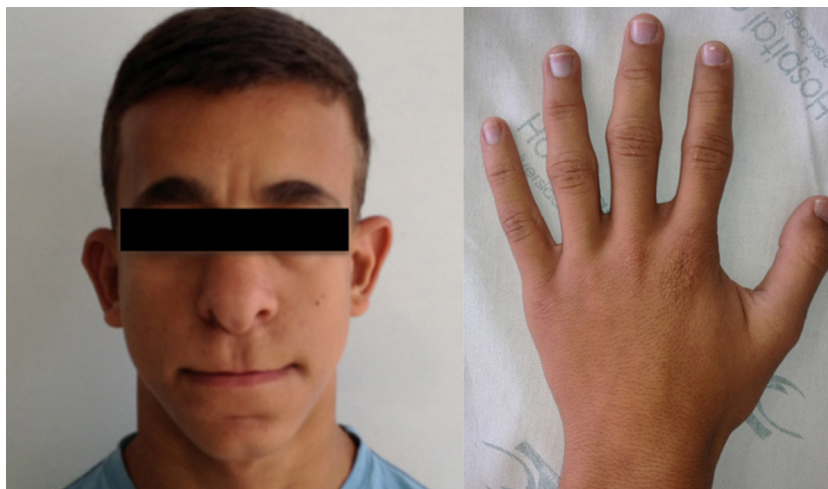

Fig. 1 – Seventeen-year-old boy with tricho-rhino-phalangeal syndrome showing fine hair, long philtrum and bulbous tip of the nose (a) and hand showing increased proximal interphalangeal joints (b).

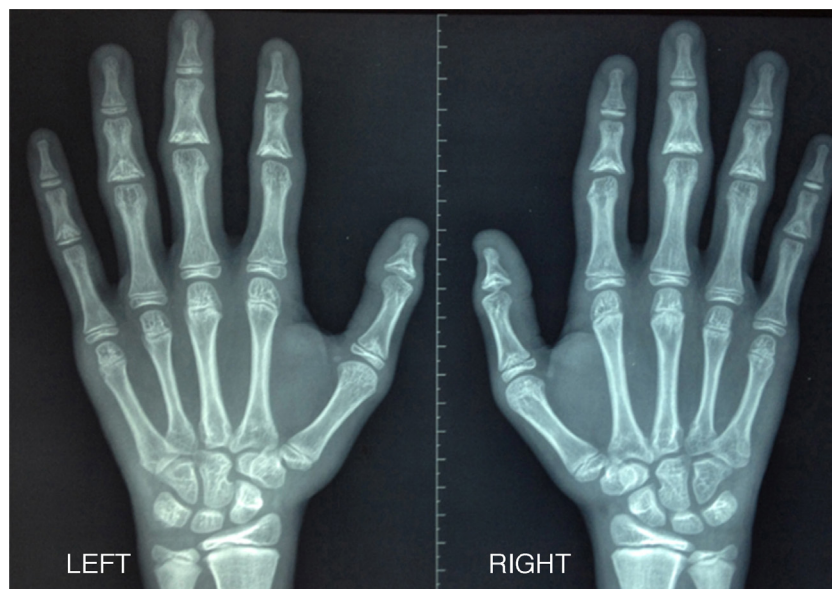


Fig. 2 – Hand radiography showing shortening and widening of the proximal metaphysis and proximal epiphysis triangular shape.

Types I and III are thought to exist on a common spectrum resulting from mutations of the TRPS1 gene, and are differentiated by the degree of phenotypic skeletal deformity. Deletions spanning TRPS1 and the distal adjacent gene EXT are found in TRPS type II, and alterations in EXT are thought to be responsible for the mental deficiencies and exostoses seen in this form. Clinodactyly describes a bend or curvature of the fifth finger toward the adjacent fourth finger and can be an isolated anomaly or it can occur in association with genetic syndromes like TRPS. Deformities like irregularly short and stubby hands are frequent. Similar feet involvement can occur, but in a lesser extent. As in this case, deformities of the hips and pelvis such as *coxa plana*, *coxa magna*, or findings resembling Legg–Calvè–Perthes disease, can be found.

History and physical examination can suggest the diagnosis especially because of craniofacial and hands appearance in typical cases. Imaging roentgenograms of hands, pelvis, and hip can be useful and, although coned epiphysis at the base of phalanges is typical, it can be found in other skeletal dysplasias and in almost 5% of normal children and teenagers. Analysis of the TRPS and EXT genes at the 8q24 locus can be undertaken to identify the responsible mutation.⁶ In this index patient, there are no reports of relatives with similar condition, and probably a sporadic mutation was responsible, as reported by Booth in 1981.⁷ There are reports of cardiac and neurologic abnormalities⁸ but none of them were found in our patient. No association with autoimmune disease is described and immunological laboratory tests are essentially normal.

Delayed skeletal maturation and early degeneration of the hips are also described. This case report confirms the main features of the syndrome and adds information about MR imaging and body composition by DXA. Both diagnostic methods are helpful tools in evaluation of phenotype characteristics, bringing more information about articular consequences and growth disturbances. The contribution of

MRI resides in the possibility of early evaluation of the joints cartilage status, allowing the exclusion of other diseases or complications, such as hip aseptic necrosis.

Low bone mineral density can be another pitfall in young individuals with tricho-rhino-phalangeal syndrome. An appropriate evaluation of bone status in the youth comprises the composite of lumbar spine mineral density and bone mineral content by DXA and, given the results in this case, strategies to minimize unfavorable evolution can be implemented. Delayed skeletal maturation can also be followed by DXA and it is important to remember that total body and lumbar spine are the sites to be evaluated in individuals less than 20 years.

One of the hallmarks of the syndrome is its wide variety of clinical presentation, which includes a simple change in the phalanges to low bone mineral density with high risk of fragility fractures. Besides musculoskeletal care, patients with tricho-rhino-phalangeal syndrome must be followed up for the development of endocrine abnormalities such as hypothyroidism, growth hormone deficiency, and idiopathic hypoglycemia.⁵

Experimental studies have permitted evaluation of TRPS1 specific role in kidney development. Newborn mice TRPS1^{-/-} have shortened long bones and incompletely formed phalangeal joints. It could reveal that TRPS1 acts in the Bmp7/p38 MAPK/TRPS1 signaling pathway, responsible for mediating the induction of mesenchymal to epithelial transition, which leads to formation of tubules and glomeruli and is essential for normal renal development.⁹

For our knowledge this is the second Brazilian case being described and adds information about the possible use of imaging methods of bone and cartilage architecture study and body composition analysis.¹⁰ Additionally, for rheumatologists, it is very important to recognize the syndrome, first because the long term management of joint complaints

and, second, this syndrome can resemble idiopathic juvenile arthritis, Legg-Calvè-Perthes, or skeletal dysplasia. The value of early evaluation also lies in providing the patient and family with appropriate support and counseling for family planning.

Conflicts of interest

The authors declare no conflicts of interest.

REFERENCES

1. Giedion A. Das tricho-rhino-phalangeal syndrom. *Helv Paediatr Acta*. 1966;21:475-82.
2. Ludecke HJ, Schaper J, Meinecke P, Momeni P, Groß S, Von Hultum D, et al. Genotypic and phenotypic spectrum in tricho-rhino-phalangeal syndrome types I and III. *Am J Hum Genet*. 2001;68:81-91.
3. Langer LO Jr, Krassikoff N, Laxova R, Scheer-Williams M, Lutter LD, Gorlin RJ, et al. The tricho-rhinophalangeal syndrome with exostoses (or Langer-Giedion syndrome): four additional patients without mental retardation and review of the literature. *Am J Med Genet*. 1984;19:81-111.
4. Burgess RC. Trichorhinophalangeal syndrome. *South Med J*. 1991;84:1268-70.
5. Vaccaro M, Guarneri C, Blandino A. Trichorhinophalangeal syndrome. *J Am Acad Dermatol*. 2005;53:858-60.
6. Sayed CJ, Matheis P, Morrell DS. Hypotrichosis, bulbous nose, and cone-shaped epiphyses in an 8-year-old girl. *Pediatr Dermatol*. 2008;25:557-8.
7. Booth CW, Maurer WF, Kaye C. De novo 9:11 translocation in a sporadic case of trichorhinophalangeal (I) syndrome. *Pediatr Res*. 1981;15:559.
8. Rué M, Ludecke HJ, Sibon I, Richez C, Taine L, Fouber-Samier A, et al. Rheumatologic and neurological events in an elderly patient with tricho-rhino-phalangeal syndrome type I. *Eur J Med Genet*. 2011;54:e405-8.
9. Sun Y, Gui T, Shimokado A, Muragaki Y. The role of tricho-rhino-phalangeal syndrome (TRPS) 1 in apoptosis during embryonic development and tumor progression. *Cells*. 2013;2:496-505.
10. Carvalho JF. Tricho-rhino-phalangeal syndrome: first Brazilian case. *Acta Reumatol Port*. 2009;34:125-7.