



# REVISTA BRASILEIRA DE REUMATOLOGIA

[www.reumatologia.com.br](http://www.reumatologia.com.br)



## Brief communication

# Ultrasound color histogram assessment allows better view of echotexture damage



## O histograma de imagens coloridas permite melhor visualização de danos ecotexturais pelo ultrassom

*José Alexandre Mendonça*

*Pontifícia Universidade Católica de Campinas (PUC-Campinas), Departamento de Reumatologia, Campinas, SP, Brazil*

### ARTICLE INFO

#### Article history:

Received 20 January 2014

Accepted 7 December 2014

Available online 23 November 2015

The technological advances have resulted in significant improvements in the quality and definition of ultrasonography (US) as an evaluation tool of joint structures, and it has been frequently used in the propedeutic aid for a variety of rheumatologic diseases.<sup>1-4</sup> Recent findings on joint US warrant a broad spectrum of indications from assessment of joint synovitis (SYN), tendinitis, bursitis, inflammatory activity follow-up, aspiration monitoring, guided injections for therapeutic and diagnostic punctures.<sup>5,6</sup> US results quality depends on the characteristics of the equipment and on its operator, requiring knowledge of anatomy, pathology and techniques allowed by the equipment.<sup>7</sup>

Joint ultrasound (US), like other imaging methods can aid in diagnosis, progress of the disease and identification of actual decline in signs and symptoms of many diseases.<sup>8,9</sup>

The radiographic evaluation detects bone structural damage belatedly, while the US shows early joint changes and thus facilitates the initial diagnosis of rheumatoid arthritis (RA).<sup>10</sup> The musculoskeletal US is an imaging method that can be considered a sensitive tool compared to radiography and offers

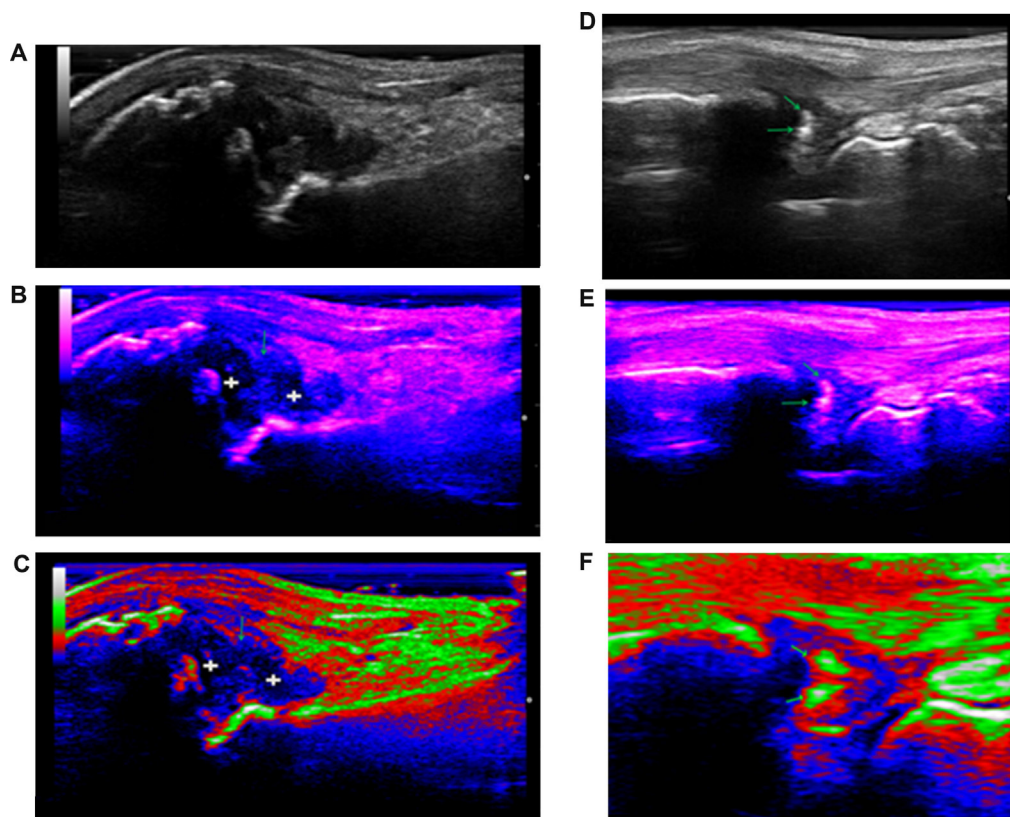
similar accuracy compared to the magnetic resonance, being useful both for detecting and following inflammatory activity, and for the assessment of structural damage in various types of arthropathies.<sup>11-15</sup>

The use of gray scale (GS) has proved to be a reliable instrument to check structural changes, setting different degrees of lesion in RA and psoriatic arthritis patients, thereby evaluating the activity of these diseases through the characterization of the synovitis. The US has proved to be important in the monitoring of treatment with high-complexity drugs, such as the biological ones.<sup>16</sup> Additionally, GS proves to be able to evaluate the extent of effusion, and synovial proliferation, even signaling the disease stage, namely an initial synovitis or an already established one. Thus, US can complement traditional clinical evaluation resources in patients with musculoskeletal conditions, reducing the subjectivity of the clinical examination. The US has also proved to be more sensitive than clinical evaluations for detecting enthesitis in patients with ankylosing spondylitis<sup>17</sup> and can be a sensitive, and almost specific technique to detect soft tissue or joint calcifications.<sup>18</sup> It is

E-mail: [mendocaja@ig.com.br](mailto:mendocaja@ig.com.br)

<http://dx.doi.org/10.1016/j.rbre.2015.05.001>

2255-5021/© 2015 Elsevier Editora Ltda. This is an open access article under the CC BY-NC-ND license (<http://creativecommons.org/licenses/by-nc-nd/4.0/>).



**Fig. 1 – (A–C) Synovitis in 1st metacarpophalangeal joint in a patient with psoriatic arthritis; A: synovitis assessment by gray scale (GS). B and C: Assessment of the same images, exudative (+ sign) and proliferative (arrow) synovitis, by Indigo and RGB patterns, through color map – Mode-B Histogram, respectively. (D–F, Calcifications in the triangular fibrocartilage complex of the wrist (TFC) in a patient with chondrocalcinosis); D–F: Evaluation of calcifications (arrows), in wrist TFC, by GS, Indigo and RGB, through color map – Mode-B Histogram, respectively.**

important to use a high frequency linear probe that ranges from 18 MHz to GS in the evaluation of small joints and surface structures.

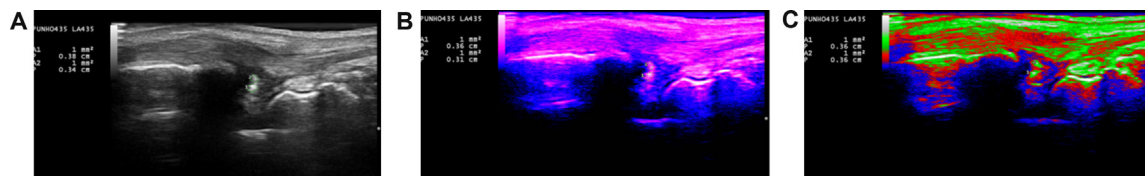
Ultrasonography with high frequency linear array probe, besides allowing a better resolution in the GS, is able to identify color images standards, better highlighting musculoskeletal echotexture damage already present. This is the case of color images with RGB pattern, which are formed by information of additive primary colors, such as red (R – Red), green (G – Green) and blue (B – Blue), “orange”, “indigo”, “magenta”, “blue” and “yellow”, generating a histogram, considered unique for a given image, a simple method, offered by US machine, a resource that belongs to the B-mode software.

The histogram modification techniques are known as dot-to-dot techniques, since the gray level value of a certain pixel after processing depends on its original value only. In contrast, in the processing techniques for completion of color images, the resulting value depends, in some way, on the pixels surrounding the element of the original pixel.

Several techniques of pixels distribution modification in the GS can be implemented from the concept of intensity transformations, meaning that an original image in a new shade of gray, in the target image, increasing its contrast and resolution of the lesion under study.

The linear intensity transformation concept can be used to implement a function that automatically expands the scale of an image grayscale so that it fills all the possible gaps. This feature is called auto-scaling. For a system which operates with images at 256 levels of gray, an auto-scale function can be implemented for each pixel with a gray tone and each tone of different color. The equalization of a histogram is a technique where one seeks to redistribute the grayscale values of pixels in an image; therefore, an ancillary function is used, which is called transformation function, for this same image in color.

The objective of color models is to allow color specification in a universally accepted standard format.<sup>19</sup> The detection of synovitis (SYN) and calcifications (calcif) through a histogram, that is, patterns of color images, in contrast with GS, may facilitate the identification of echographic structural damages, giving better accuracy in measurements and more accurate diagnosis of the lesion studied, especially in situations that generate doubt in image analysis. RGB pattern can best show an exudative SYN of a proliferative SYN, when we have, in a single structure, a mixed type of synovial tissue damage, but also can better detect calcif because this echotexture damage, in this pattern, shows echotexture that is identical to the cortical bone, differentiating these findings when they are in soft tissues, such as synovial tissue (Fig. 1).



**Fig. 2 – (A–C) Area measurements, in cm<sup>2</sup> of calcifications in the triangular fibrocartilage complex of the wrist in a patient with Chondrocalcinosis – calcifications assessment by gray scale patterns, Indigo and RGB, respectively, confirmed the presence of “white” echotexture, identical to the cortical ulnar bone.**

Thus, we evaluated 10 patients, mean age 40.7 years old, 2 males and 8 females. A total of 104 SYN and calcif measurements in cm<sup>2</sup> were performed in the dorsal radiocarpal joint (DRR); triangular fibrocartilage complex (TFC); dorsal metacarpophalangeal joints (MCP) and lateral and medial knee suprapatellar recesses. Four patients exhibited chondrocalcinosis, 5 patients osteoarthritis and 1 patient psoriatic arthritis. For each measurement in GS there was one measurement performed for each color image pattern, held at different times and blind, in order that the previous measures are not seen or remembered. For the Spearman correlation analysis, the software IBM SPSS Statistics 19 was used.

Mean  $\pm$  SD of image patterns: RGB (Red, Green and Blue) SYN  $16.96 \pm 0.25$  cm<sup>2</sup>; Indigo SYN  $6.43 \pm 0.07$  cm<sup>2</sup>, RGB Calcif  $0.03 \pm 0.00$  cm<sup>2</sup>; Indigo Calcif  $0.06 \pm 0.03$  cm<sup>2</sup>; GS SYN  $16.13 \pm 0.35$  cm<sup>2</sup> and GS Calcif  $0.56 \pm 0.01$  cm<sup>2</sup>.

Correlations of color images patterns: RGB DRR SYN and Indigo DRR SYN:  $r = 1.0$ ,  $p < 0.001$ ; Indigo DRR SYN and RGB suprapatellar SYN:  $r = 1.0$ ,  $p < 0.001$ ; RGB MCP SYN and Indigo MCP SYN:  $r = 1.0$ ,  $p < 0.001$ ; Indigo DRR calcif and RGB TFC calcif:  $r = 1.0$ ,  $p < 0.001$  (Fig. 2).

The RGB and Indigo measurement standards when correlated with GS for SYN and calcifs were not statistically significant ( $p = 0.333$ – $0.667$ ). Color images patterns of GS, represented by the histogram, evaluates SYN and calcif through RGB, “orange”, “indigo”, “magenta”, “blue” and “yellow”, and RGB and Indigo patterns seem to better delimit these echotexture damage, through better visualization, detected by area measurements in cm<sup>2</sup>.

This identification of structural damage by the US, using a color histogram, has never been previously done this way for rheumatic diseases. Further studies are needed to strengthen these US findings.

## Conflicts of interest

The author declares no conflicts of interest.

## REFERENCES

- Filippucci E, Iagnocco A, Meenagh G, Riente L, Delle Sedie A, Bombardieri S, et al. Ultrasound imaging for the rheumatologist. *Clin Exp Rheumatol*. 2006;24:1–5.
- Grassi W, Salaffi F, Filippucci E. Ultrasound in rheumatology. *Best Pract Res Clin Rheumatol*. 2005;19:467–85.
- Kane D, Grassi W, Sturrock R, Balint PV. Musculoskeletal ultrasound – a state of the art review in rheumatology. Part 2: Clinical indications for musculoskeletal ultrasound in rheumatology. *Rheumatology*. 2004;43:829–38.
- Kane D, Bruyn G, Arnold E, Grassi W. A rheumatologist's perspective on musculoskeletal ultrasound in rheumatology: comment on the editorial by Roemer et al. *Arthritis Rheum*. 2006;55:341–2.
- D'Agostino MA, Ayrat X, Baron G, Ravaut P, Breban M, Dougados M. Impact of ultrasound imaging on local corticosteroid injections of symptomatic ankle, hind-, and mid-foot in chronic inflammatory diseases. *Arthritis Rheum*. 2005;53:284–92.
- Koski JM, Helle M. Ultrasound guided synovial biopsy using portal and forceps. *Ann Rheum Dis*. 2005;64:926–9.
- Ferri M, Finlay K, Popowich T, Stamp G, Schuringa P, Friedman L. Sonography of full-thickness supraspinatus tears: comparison of patient positioning technique with surgical correlation. *AJR Am J Roentgenol*. 2005;184:180–4.
- Luukkainen RK, Saltyshev M, Koski JM, Huhtala HS. Relationship between clinically detected joints swelling and effusion diagnosed by ultrasonography in metatarsophalangeal and talocrural joints in patients with rheumatoid arthritis. *Clin Exp Rheumatol*. 2003;21:632–4.
- Naredo E, Bonilla G, Gamero F, Uson J, Carmona L, Laffon A. Assessment of inflammatory activity in rheumatoid arthritis: a comparative study of clinical evaluation with grey scale and power Doppler ultrasonography. *Ann Rheum Dis*. 2005;64:375–81.
- Grassi W, Filippucci E, Farina A, Salaffi F, Cervini C. Ultrasonography in the evaluation of bone erosions. *Ann Rheum Dis*. 2001;60:98–103.
- Karim Z, Wakefield RJ, Conaghan PG, Lawson CA, Goh E, Quinn MA, et al. The impact of ultrasonography on diagnosis and management of patients with musculoskeletal conditions. *Arthritis Rheum*. 2001;44:2932.
- Scheel AK, Backhaus M. Prospective 7 year follow up imaging study comparing radiography, ultrasonography, and magnetic resonance imaging in rheumatoid arthritis finger joints. *Ann Rheum Dis*. 2006;65:595–600.
- Backhaus M, Kamradt T, Sandrock D, Loreck D, Fritz J, Wolf KJ, et al. Arthritis of the finger joints: a comprehensive approach comparing conventional radiography, scintigraphy, ultrasound, and contrast-enhanced magnetic resonance imaging. *Arthritis Rheum*. 1999;42:1232–45.
- Szkudlarek M, Narvestad E, Klarlund M, Court-Payen M, Thomsem HS, Østergaard M. Ultrasonography of the metatarsophalangeal joints in rheumatoid arthritis: comparison with magnetic resonance imaging, conventional radiography, and clinical examination. *Arthritis Rheum*. 2004;50:2103–12.
- Brown AK, Conaghan PG, Karim MA. An explanation for the apparent dissociation between clinical remission and continued structural deterioration in rheumatoid arthritis. *Arthritis Rheum*. 2008;58:2958–67.
- Fiocco U, Ferro F, Vezzù M, Cozzi L, Checchetto C, Sfriso P, et al. Rheumatoid and psoriatic knee synovitis: clinical, grey

- 
- scale, and power Doppler ultrasound assessment of the response to etanercept. *Ann Rheum Dis.* 2005;64:899-905.
17. Balint PV, Kane D, Wilson H, McInnes I, Sturrock R. Ultrasonography of enthesal insertions in the lower limb in spondyloarthropathy. *Ann Rheum Dis.* 2002;61:905-10.
  18. Frediani B, Filippou G, Falsetti P, Lorenzini S, Baldi F, Acciai C, et al. Diagnosis of calcium pyrophosphate dihydrate crystal deposition disease: ultrasonographic criteria proposed. *Ann Rheum Dis.* 2005;64:638-40.
  19. Marques Filho O, Vieira Neto H. *Processamento Digital de Imagens.* Rio de Janeiro: Brasport; 1999.