



Urethral leiomyoma: combined vaginal and abdominal approach – a case report


Francilberto Dyego de Souza ¹

 <https://orcid.org/0000-0001-9622-5551>


Carolina Mayumi Haruta ⁴

 <https://orcid.org/0000-0003-1098-6822>


Fernanda dos Passos e Silva Leite ²

 <https://orcid.org/0000-0002-8887-0494>

Artur Eduardo de Oliveira Rangel ⁵

 <https://orcid.org/0000-0002-3623-2722>

Ana Ricarlanda Cajaseiras Liberato ³

 <https://orcid.org/0000-0002-7447-6103>

¹⁻⁵Instituto de Medicina Integral Prof. Fernando Figueira. Rua dos Coelhos, 300. Boa Vista. Recife, PE, Brazil. CEP: 50.070-902. E-mail: francilbertosouza@gmail.com

Abstract

Introduction: leiomyomas are benign mesenchymal tumors of smooth muscle origin that can develop in various locations. Urethral leiomyomas are rare, with approximately only 120 cases reported in the literature. These tumors often occur in the third and fourth decades of life but are rare in menopausal patients. In general, treatment involves surgery, only three recurrence reports in the literature.

Description: a case report on a 56-year-old woman; the patient had type II diabetes mellitus and chronic high blood pressure, was overweight (body mass index, 27.1 kg/m²), and a smoker. Besides this, the patient presented symptoms of urinary obstruction and had a large urethral leiomyoma. The tumor was completely removed with no associated urethral lesions using a complex, combined abdominal-vaginal surgical approach.

Discussion: the management and treatment on urethral leiomyomas is challenging and have not been established yet due to the rarity of these tumors.

Key words *Leiomyoma, Urethra, Urinary bladderneck obstruction*



Introduction

Leiomyomas are benign mesenchymal tumors of smooth muscle origin¹ and can develop in any tissue containing smooth muscle. The most common extrauterine locations are in the genitourinary system (vulva, ovaries, urethra, and urinary bladder) and the least common location is the gastrointestinal tract.²

The first case of a urethral leiomyoma was described by Buttner in 1894. This is a condition that is so rare that merely less than 120 cases have been reported in the literature.¹ Categorized as deep-tissue leiomyomas, leiomyomas of the urethra are much larger than their superficial counterparts and generally exhibit a broader spectrum of histological alterations; hence, it is important to clearly distinguish them from leiomyosarcomas, which more frequently develop in deep soft tissues.³ However, the definitive diagnosis can only be confirmed by a histopathological examination.

Due to the rarity of this condition, open or transurethral surgical management are the standard treatment.⁴ Herein, we present a case report of a large urethral leiomyoma that was completely removed through a combined surgical approach (abdominal and vaginal), without urethral lesions associated with surgical procedure.

Description

A 56-year-old, mixed color skin woman, with a history of three previous vaginal deliveries, who had her menarche at the age of 17 and reached menopause at

53, she was attended at the health service complaining of voiding for the past three years. She denied other urinary complaints. Her history included type II diabetes, chronic hypertension, overweight (body mass index (BMI) 27.1kg/m²), and smoking. In addition, she reported past bilateral tubal ligation.

During the gynecological examination, a tumor of fibroelastic consistency was palpated along the entire urethral length, measuring approximately 5.0 x 3.0cm. Pelvic nuclear magnetic resonance imaging (MRI) showed a tumor in the anterior vaginal wall, hyperintense on T2 imaging, with mass effect on the urethra extending to the bladder neck (Figure 1).

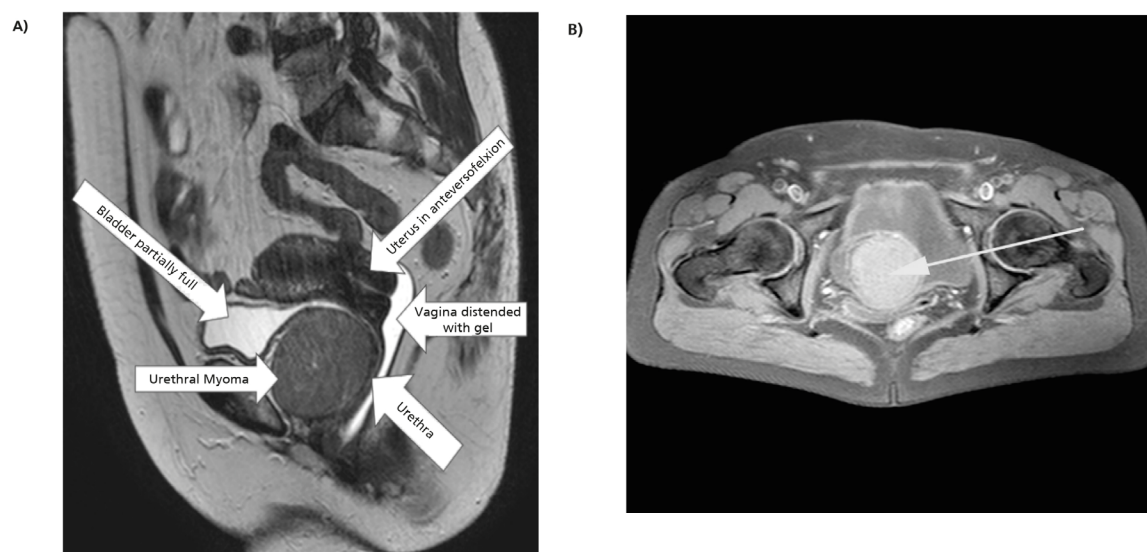
Video-urethrocystoscopy showed only extrinsic compression caused by the tumor; therefore, an incisional biopsy was performed involving the excision of a fragment of the urethral tumor (Figure 2). Histopathological analysis revealed the following immunohistochemical panel: Ki-67/cloneMIB-1/m7240 positive with low risk for neoplasia; this was suggestive for leiomyoma (Figure 2).

The patient underwent urethral leiomyoma excision vaginally, under spinal anesthesia, using a 14FR Foley catheter.

During the vaginal access in the anterior wall, there were extreme technical difficulties due to the cranial extension of the lesion toward the bladder neck. Thus, a combined abdominal access was chosen, with releasing a part of the tumor by the vaginal route and another part by the abdominal route. During the vaginal dissection, the bladder was incidentally opened, requiring a partial cystectomy to correct the bladder lesion. Transoperative

Figure 1

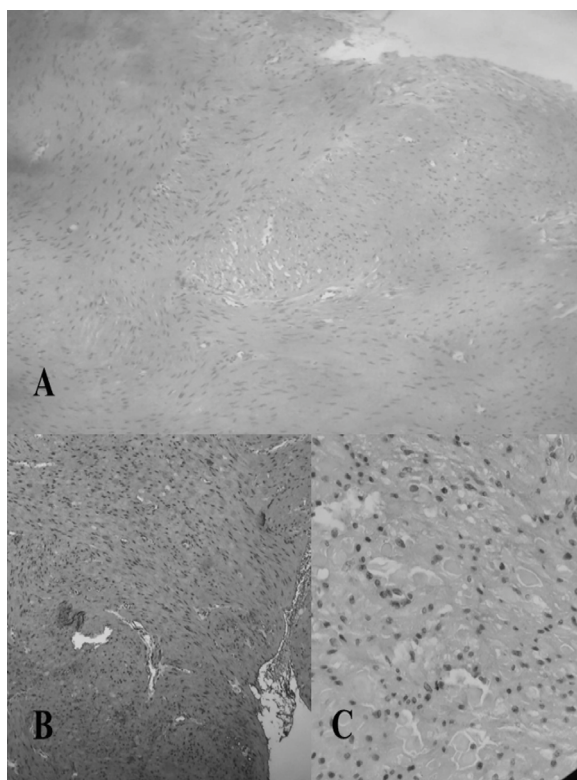
Pelvic nuclear magnetic resonance.



A) Sagittal T2-weighted MRI image showing the relationship between the tumor and the pelvic structures (arrows); B) Axial STIR image showing a voluminous solid nodule that bulges the bladder floor, located in the urethral path (final arrow).

Figure 2

Histopathological analysis.



A) Histological slide stained with hematoxylin-eosin of the specimen collected by incisional biopsy of the urethral tumor; B) Unidirectional cell bundles, without cell atypia and positive staining for smooth muscle actin; C) Marking with Ki67, showing low cell proliferation, compatible with benign neoplasms.

urethroscopy was performed with no evidence of other alterations, and the patient was maintained with suprapubic cystostomy because of the bladder lesion. The surgical specimen consisted of a nodular tumor with fibroelastic consistency, measuring approximately 5.0 x 5.0 x 3.0cm.

Venous antibiotic therapy with ciprofloxacin was administered for seven days due to extensive bladder manipulation, combined vaginal and abdominal approach, and visualization of purulent secretion through the right ureteral ostium.

The patient had an uneventful postoperative course and was discharged on the seventh day after the removal of the cystostomy, and was referred to our outpatient department for follow-ups.

The final anatomopathological report was compatible with a benign mesenchymal fusocellular neoplasm, exhibiting morphological characteristics consistent with a leiomyoma.

The patient remained asymptomatic, without lower urinary tract symptoms, infections, surgical complications, or signs of tumor recurrence after one year of follow-up.

This work consists of a case report and a narrative review of the literature and was approved by the Research Ethics Committee at IMIP (consubstantiated opinion

number 3,945,385). We obtained the informed consent form from the research participant prior to publishing this report.

Discussion

An extrauterine leiomyoma is a rare benign tumor, especially when located in deep soft tissues, such as in the female urethra.⁴ Although they may affect women at any age, they occur more commonly during the third and fourth decades of life, with an average age of 41 years, especially around menopause.⁵ The presence of urethral leiomyomas in menopausal women is infrequent due to their dependence on estrogenic stimulus.⁵

There are certain factors associated with the risk of developing leiomyomas, these include: black race, BMI, early menarche, late menopause, and other factors, such as diabetes and multiparity, are associated with a reduced risk. Data on the effect of smoking are conflicting in the literature.⁶ It is believed that the development of leiomyomas, at least partially, is due to the action of sex steroids, estrogen and progesterone, as they usually occur during menarche and regress in the postmenopausal period.

On the other hand, overweight and obesity are related to the development of leiomyomas because of the reduction in the levels of sex hormone-binding protein, with consequent increase in the bioavailability of sex steroids in peripheral tissues. Diabetes is related to reduced leiomyoma vascularization due to local vascular dysfunction and is considered to be a protective factor against their development.⁶ In the present case, the patient had her menarche at the age of 17 and reached menopause at 53, has a history of three vaginal deliveries, a BMI of 27.1 kg/m²; she was a long-term smoker and has diabetes mellitus.

Therefore, she did not present significant risk factors for the development of leiomyomas; on the contrary, she had some protective factors. On the other hand, besides the age, race could be considered as a risk factor, since black patients have a two to three times higher incidence and a higher risk of hospitalization.⁶

The mean diameter of leiomyomas of the urethra is 3.7cm and may reach up to 40cm, and they are more common in the proximal segment of the urethra (80%). In the present case, the tumor measured approximately 5.0cm and affected the entire length of the urethra, which is uncommon.^{1,5,7}

Although they may be asymptomatic at the initial clinical presentation, the most frequent symptoms are dyspareunia, urinary tract infection (UTI), mass effect (as an intravesical obstructive factor, causing urinary retention), and irritative symptoms in the lower urinary tract.⁸ However, complaints related to urinary obstruction

are rare symptoms and not an isolated presentation of the entire clinical picture,⁵ as in the case presented here. It is likely that the large extension of the tumor, compromising the entire urethral extension and bladder neck, justifies the obstructive clinical picture presented (Figure 1).

The differential diagnosis of paraurethral masses includes urethral prolapse, urethral diverticula, Skene's and/or Gartner's gland cysts, Müllerian remnants, inclusion of epithelial cysts, congenital paraurethral cysts, vaginal or urethral neoplasms, fibrous polyps, and mesenchymal tumors (such as leiomyomas).

Imaging modalities can be very useful in the differential diagnosis of leiomyomas and in the determination of the exact tumor location and depth of tissue infiltration. They also provide evidence to determine the presence of features suggestive of a malignancy and additional information to appropriately plan the process of surgical excision.⁴ Regarding imaging modalities, pelvic endovaginal ultrasound and magnetic resonance imaging (MRI) are extremely useful. MRI is considered as the gold standard of imaging tests by most authors, while ultrasound is useful to differentiate between solid or cystic lesions.^{9,10}

Leiomyomas of deep tissues (urethral) generally present a wide spectrum of histological alterations, which makes it important to distinguish them from leiomyosarcomas, which are more common in deep soft tissues. Therefore, the final diagnosis can only be confirmed by histopathological examination to rule out neoplastic involvement. There are no reports of malignant transformation in this type of tumor.³

In the present case, the MRI findings indicated a solid tumor; however, the exclusion of malignancy and confirmation of the histological origin of the lesion was only possible with the anatomopathological and immunohistochemical analyses. These analyses showed a tumor composed of smooth muscle cells arranged in bundles, a pattern compatible with smooth muscle tumors, and with a low cell proliferation index (Ki67), compatible with a lesion devoid of malignancy.¹¹

Because it is an extremely rare condition, its ideal management has not been established yet, and local excision is generally recommended. Hormonal treatment with a gonadotropin-releasing hormone analog has also been described.⁴ However, in the present case, this option was less feasible due to the difficulties in finding this medication through the public health system in Brazil for this particular condition. The laparoscopic treatment of urethral leiomyomas, which develop in the vesicouterine and vesicovaginal spaces, is also considered to be viable when the lesions are very extensive.¹²

In relation to the case presented, a combined approach was chosen due to the extension of the lesion, which was along the entire urethral length, making the complete

removal of the lesion difficult and increasing the risk of severe lesions if a single access route was chosen. Another preponderant factor while choosing the route was the surgical expertise of the assistant team and the availability of the laparoscopic approach for this type of lesion in the local medical setup.

Therefore, the most feasible approach was chosen to resolve the obstructive condition, which if left untreated, could lead to chronic renal dysfunction. To the best of our knowledge, this is the first case in the literature for which such an approach has been used.

With this approach, it was possible to excise the entire extensive tumor lesion, without injuring the adjacent organs, without the need for blood transfusion, and without any other complications arising in the early postoperative period. A longer surgical time, a longer recovery period after laparotomy, as compared to laparoscopy, and a more gradual and slower return to daily activities could be considered as limitations.

So far, world widely, only three patients with urethral leiomyoma have developed recurrence and were treated with repeated excisions. Therefore, when complete surgical excision is performed, there is usually a very low risk of recurrence, which may probably be caused due to an incomplete first excision to avoid damage to the urethra.⁹

In summary, we present the case of a menopausal woman with multiple comorbidities diagnosed with a rare urethral tumor, who presented complaints of urinary obstructive symptoms. A large tumor was removed by implementing a combined approach (abdominal and vaginal) due to the complexity of the case and required partial cystectomy, but showed no association with urethral lesions and no recurrence in the postoperative follow-up.

Based on the considerations presented in this study, we conclude that urethral leiomyomas are tumors whose surgical excision can be challenging and may require surgeons with technical expertise and skills to perform multiple surgical access routes and appropriate consideration for the management of associated urological complications.

Authors' contribution

Souza FD participated in patient care and in the idealization and reporting of the case, literature review, capturing and editing of the included images, and writing and reviewing the manuscript. Silva Leite FP participated in patient care and in the idealization and reporting of the case, literature review, capturing and editing of the included images, and writing of the manuscript. Liberato ARC participated in patient care and in the idealization and reporting of the case, and in the literature and manuscript review. Haruta CM participated in patient care and in the idealization and reporting of the case and manuscript review. Rangel AEO participated in patient

care and in the idealization and reporting of the case and manuscript review, besides supervising the work.

All authors have approved the final version of the article and declare that there are no conflicts of interest.

References

1. Fedelini P, Chiancone F, Fedelini M, Fabiano M, Persico F, Di Lorenzo D, *et al.* A very large leiomyoma of the urethra: a case report. *Urol J.* 2018 May; 85 (2): 79-82.
2. Verma R, Mehra S, Garga UC, Jain N, Bhardwaj K. Imaging diagnosis of urethral leiomyoma, usual tumour at an unusual location. *J Clin Diagn Res.* 2014 Nov; 8 (11): RD4-RD6.
3. Lima Junior MM, Sampaio CB, Ticianeli JG, Lima MM, Granja F. Leiomyoma – a rare benign tumor of the female urethra: a case report. *J Med Case Rep.* 2014; 13 (8): 366.
4. Kwang BN, Naidu A, Yahaya A, Shan LP. Urethral leiomyoma: a rare clinical entity. *Case Rep Surg.* 2016; 2016: 6037104.
5. Chodiseti S, Namburi RR, Boddepalli Y. Female urethral leiomyoma presenting with acute urinary retention-a rare case with unusual presentation. *Indian J Surg.* 2015 Apr; 77 (Suppl 1): 128-9.
6. Wise LA, Laughlin-Tommaso SK. Epidemiology of uterine fibroids: from menarche to menopause. *Clin Obstet Gynecol.* 2016 Mar; 59 (1): 2-24.
7. Lopes SP, Severo L, Gameiro CD, Vilas-Boas V, Forte P, Oliveira M, *et al.* Leiomioma da uretra feminina - revisão da literatura a propósito de caso clínico. *Acta Urol.* 2009; 26 (3): 63-6.
8. Slaoui A, Lasri A, Karmouni T, Elkhader K, Koutani A, Attaya AI. Leiomyoma: a case report of a rare benign tumor of the female urethra. *Pan Afr Med J.* 2015; 8 (22): 111.
9. Navarro MJ, Martínez BB, Talavera JR, Robayna AA. Recurrence of urethral leiomyoma: a case report. *Urol Case Rep.* 2019 Sep; 26: 100968.
10. Cicilet S, Joseph T, Furuq F, Biswas A. Urethral leiomyoma: a rare case of voiding difficulty. *BMJ Case Rep.* 2016; 2016: bcr2016216728.
11. D'Angelo E, Prat J. Uterine sarcomas: a review. *Gynecol Oncol.* 2010 Jan; 116 (1): 131-9.
12. Ciravolo G, Ferrari F, Zizioli V, Donarini P, Forte S, Sartori E, *et al.* Laparoscopic management of a large urethral leiomyoma. *Int Urogynecol J.* 2019 Jul; 30 (7): 1211-3.

Received on August 16, 2021

Final version presented on February 16, 2022

Approved on March 1, 2022