

# Single transverse extended incision for radical neck dissection

## *Esvaziamento cervical radical por incisão transversa única estendida*

JOSÉ FRANCISCO SALES CHAGAS<sup>2</sup>; MARIA BEATRIZ NOGUEIRA PASCOAL<sup>2</sup>; JOSÉ LUÍS BRAGA AQUINO, TCBC-SP<sup>2</sup>; LUÍS ANTÔNIO BRANDI FILHO<sup>2</sup>; EVANDRO VON ZUBEN PREVITALE<sup>2</sup>; ANA SOFIA PONTES TRILLO<sup>2</sup>; OTÁVIO ALBERTO CURIONI, TCBC-SP<sup>1</sup>; ABRÃO RAPOPORT, TCBC-SP<sup>1</sup>; ROGÉRIO APARECIDO DEDIVITIS, TCBC-SP<sup>1</sup>.

### ABSTRACT

**Objective:** to assess the efficacy of the single transverse extended cervical incision in radical neck dissection. **Method:** we conducted a prospective study, from January 2008 to January 2009, with 18 patients undergoing surgical treatment of malignant tumors of the upper aero-digestive tract. The primary lesion was located in the oral cavity in eight cases, in the oropharynx in three, in the hypopharynx in three, in the larynx in two, in the maxillary sinus, and in one case, the primary injury was hidden. There were 29 neck dissections, eight bilateral and 10 unilateral (26 radical and three selective). Staging revealed nine patients with T4 tumor, one T3, six T2, one T1 and one Tx. Five patients were N0, nine N2b, one N2c and three N3. The average number of dissected lymph nodes was 34.25. We performed the neck dissection through a single incision located in the middle neck, coincident with the skinfold, with a length of about 2 to 3 cm behind the anterior edge of the trapezius muscle and 3 to 4 cm from the midline for the unilateral neck dissections. **Results:** as complications, there were myocutaneous flap necrosis in one patient with prior radiation therapy, one lymphatic fistula, one dehiscence of the tracheostomy, one cervical abscess, one salivary fistula and one suture dehiscence. **Conclusions:** the single extended incision provides adequate exposure of the neck structures, without compromising surgical time, even in bilateral dissections. It does not compromise the resection of all cervical lymph nodes; it has excellent aesthetic and functional results and is easily associated with other approaches to resection of the primary tumor.

**Keywords:** Neck Dissection. Postoperative Complications. Carcinoma, Squamous Cell. Prospective Studies

### INTRODUCTION

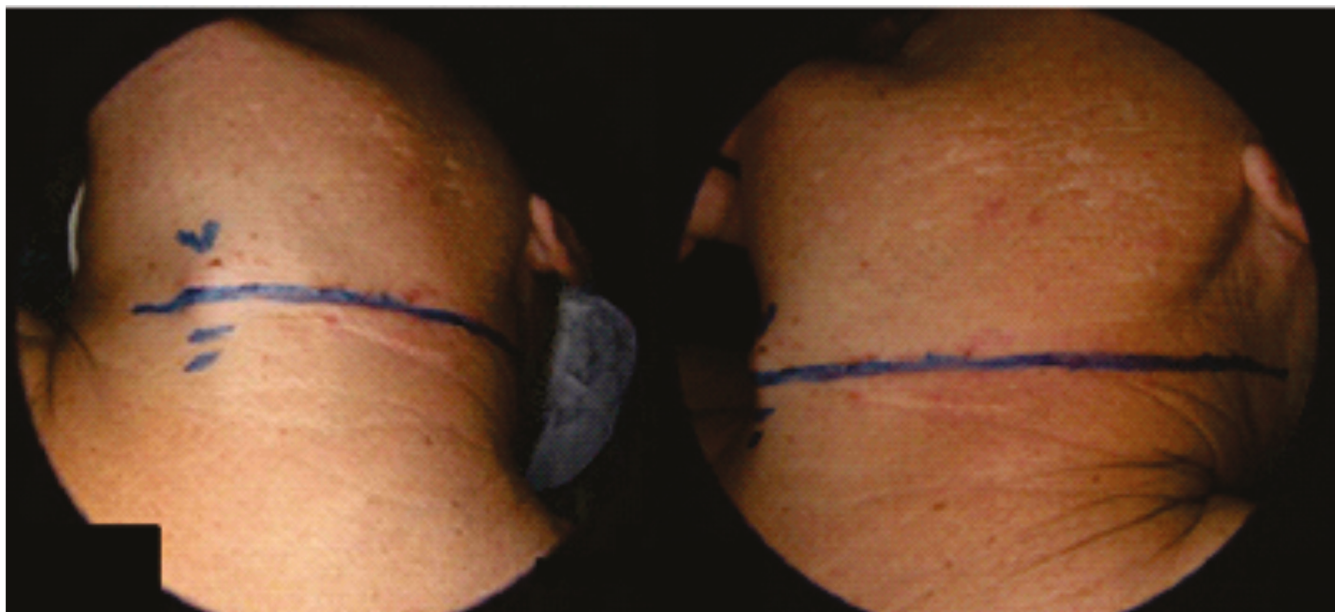
The neck dissection is a risky procedure due to its performance in an anatomically complex region, with multiple key structures involved in lymph node dissection, beyond the extent of detachment of the flaps and the frequent combination with extensive surgery for resection of the primary tumor. Complications range from dehiscence of cervical suture flap to serious complications such as rupture of large vessels.

The patient's nutritional status, concomitant diseases such as diabetes, anemia and cardiovascular disease, the extent of resection and previous treatments such as radiotherapy and chemotherapy tend to increase the risk of systemic or local complications, the latter being mainly related to the cervical flap<sup>1</sup>.

Traditionally, surgeons perform neck dissections through two or more associated cervical incisions, to expose widely and easily all levels of the cervical lymph nodes. This reduces the technical difficulty, which could

influence the complete resection of the cervical lymph nodes, leading to regional recurrence and worse prognosis. These often combine a transverse incision with a vertical one, which usually intersect at the level of the carotid bulb. Due to the necessity of decoupling the skin flap from the mandible to the clavicle radical dissections, there is a great possibility of interference with vascularization of these flaps, and consequently increased risk of dehiscence of the suture and exposure of large vessels at risk of rupture by dehydration of their walls and damage to the *vasa vasorum*. Thus, a minor complication such as suture dehiscence can become life-threatening for patients, especially those undergoing previous treatments such as radiotherapy and/or chemotherapy. In addition to the wide exposure of the cervical lymph nodes, neck dissection planning must also address the need for an *en bloc* associated resection of the primary lesion, usually when the primary tumor is larger and resection includes communication between the high aero-digestive tract and the neck.

1 - Department of Head and Neck Surgery and Otorhinolaryngology, Heliópolis Hospital, São Paulo, SP, Brazil. 2 - Department of Head and Neck Surgery, Hospital of the Pontifical Catholic University of Campinas, Campinas, SP, Brazil.



**Figure 1.** Single extended transverse incision for cervical dissection, located in the mid third of the neck region and coincident with the skin fold, surpassing the midline and the anterior border of the trapezius muscle.

In addition to the inadequate aesthetic appearance of incisions that run in oppositions to the lines of Langer, ie, the skinfolds in the case of the neck, the other complications from neck dissection are the scar retractions, which can result in chronic pain, besides restricting the movement the muscles of the shoulder girdle and neck. These complications interfere with patients' working capacity and therefore in their quality of life<sup>2</sup>.

In order to reduce such complications, improve the functional aspects and post-surgical aesthetics, and based on our experience with the McFee incision, routinely used for female patients<sup>3</sup>, we introduced the single and extended cervical incision for unilateral or bilateral cervical dissections from a literature time series<sup>4</sup>.

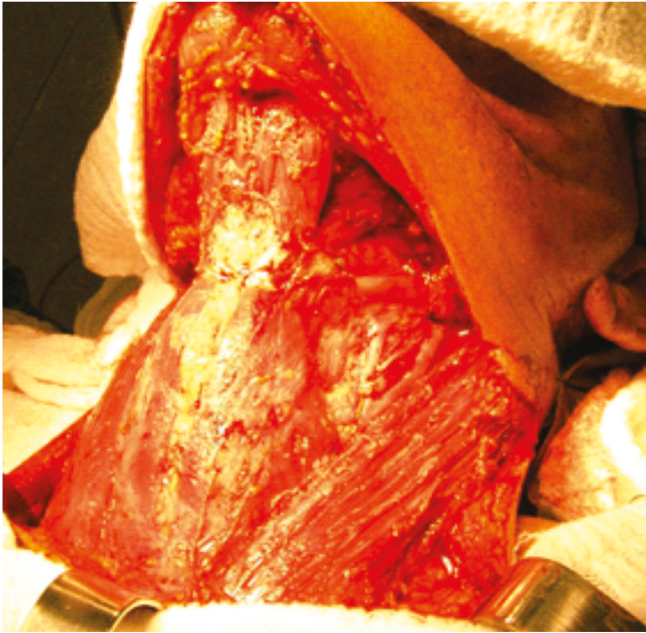
## **METHODS**

We conducted a prospective study to assess the viability of the single extended cervical incision for radical neck dissection, and to analyze its interference in post-operative complications in terms of functional and esthetic aspects. In the Service of Head and Neck Surgery of the Hospital of the Pontifical Catholic University of Campinas and at the Department of Head and Neck Surgery and Otorhinolaryngology, Heliópolis Hospital, 18 consecutive patients with squamous cell carcinoma of the

aerodigestive tract upper underwent surgical treatment from January 2008 to January 2009, with a minimum follow-up period of one year. There were eight patients with primary tumors of the oral cavity, three of the oropharynx, three of the hypopharynx, two of the larynx, one of the maxillary sinus and one hidden primary lesion. With respect to the neck dissections performed, there were 19 cases, eight bilateral and 10 unilateral (26 radical and three supraomo-hyoid). The staging of the primary tumors revealed: Nine T4, one T3, six T2, one T1 and one Tx, and in relation to the cervical lymph nodes, we found five N0, nine N2b, one N2c and three N3, with prior radiation treatment in one case.

The eligibility criterion was the indication of radical or selective neck dissection. All patients underwent neck dissection through a single incision in the middle third of the neck, coinciding with the skin fold and extending about 2 to 3 cm beyond the anterior edge of the trapezius muscle and exceeding 3 to 4 cm from the midline in unilateral dissections (Figure 1). In bilateral dissections, the length of the incision went beyond the front edge of the contralateral trapezius muscle.

The skin flaps were raised under the platysma muscle, to help preserve vascularity, and extended to the limits of neck dissection, ie, the lower edge of the jaw and upper edge of the clavicle unilaterally or bilaterally on



**Figure 2.** Bilateral cervical lymph node emptying with exposure of all lymph node levels.

radical dissections, and lower edge of the jaw and middle third of the neck in supraomohyoid ones (Figure 2). We dissected the neck dissection product, with separation of the lymph nodes by levels and chains, and noted the surgical time.

We monitored patients for at least one year, with quarterly reviews for detection of complications related to the surgical approach, such as cervical pain, dehiscence or skin necrosis, scar retraction, presence of keloids, hypertrophic scar and limited motion of neck and shoulder girdle (Figure 3).

This study was approved by the Ethics in Research Committee of the Pontifícia Universidade Católica de Campinas, under number 108/09.

## RESULTS

Surgical time ranged from two to six hours and the average of dissected lymph nodes was 34.25.

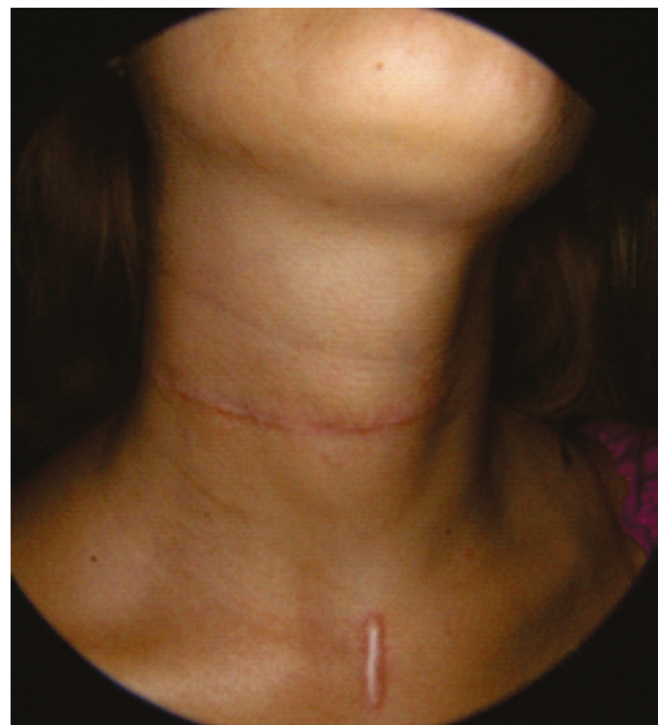The following complications occurred: one lymphatic fistula, one tracheostomy dehiscence, one necrosis of the pectoralis major myocutaneous flap, one cervical abscess, one salivary fistula, one dehiscence of skin suture and scar retraction. The skin dehiscence was treated conservatively and occurred in one patient with prior radiation treatment. The patient who had scar retraction

underwent surgical approach under local anesthesia, in which we evidenced fibrosis and retraction of infrahyoid muscles. The surgical treatment occurred after failure of physical therapy and also due to decrease in cervical movements and severe pain.

## DISCUSSION

Cervical lymph node dissection was first described in 1906<sup>5</sup> and remains the same as the standard treatment for cervical lymph node metastases, with a large number of success reports in medical literature. In addition, morbidity and surgical mortality decreased to very acceptable levels due to advances in anesthesia, antibiotics, blood transfusions and surgical technique. Despite these advantages, there is still some reluctance to accept a surgery considered mutilating or disfiguring, especially in young female patients<sup>7,8</sup>.

Numerous incisions are normally used for the surgical approach, and most of them combine a transverse neck incision with a vertical one<sup>7-9</sup>. The vertical component is in opposition to the skin force lines, which increases the risk of scar contraction or keloid formation. Scarring retractions can lead to limitation of neck move-



**Figure 3.** Late postoperative appearance.

ment and the emergence of pain conditions, ranging from moderate to severe. These complications are able to interfere with labor or leisure activity, reducing patients' quality of life<sup>9,10</sup>.

Another complication that may occur in the post-operative period of neck dissection is the skin flaps necrosis, usually at their intersection, which generally happens at the level of the carotid bulb, leading to its exposure and dryness. This necrosis has a higher incidence in the vertical component of skin incisions, since the blood supply is less, for it reduces the skin flap pedicle<sup>11,12</sup>. The skin incisions with a single component in the shape of "J" or "U" also oppose to the skin force lines, enabling the same functional and aesthetic complications of incisions with two components.

Numerous cervical surgical techniques have been described<sup>13</sup>, none of which fully meeting the criteria for cervical access, thus described: 1) adequate surgical field exposure; 2) adequate blood supply to the resulting flaps; 3) acceptable relation of the incision with large neck vessels; 4) easy conversion or conjunction with other incisions to approach the primary tumor; 5) convenience for preparation of stomas; 6) compatibility with reconstructive techniques; and 7) functional characteristics and acceptable cosmetic. In addition, the technique needs to be easy to learn and to reproduce. Based on these criteria, the ideal surgical approach would be in transverse direction, and which could be associated with pathways for resection of the primary lesion.

The use of two parallel incisions for performing cervical lymph node dissection<sup>3</sup> presents risk of skin necrosis because it interferes with the viability of the cutaneous blood supply, especially in bilateral cases<sup>13</sup>. Thus, the optimal surgical approach is one transverse incision, provided that exposure of all cervical lymph node levels is possible. Based on the experience with the McFee<sup>3</sup> and Altie<sup>4</sup> incisions, we introduced the single and extended incision for neck dissection.

To facilitate the access to the surgical areas of greatest difficulty, such as submentonian lymph nodes (Ia level) and posterior portion of the supraclavicular fossa (Vb level), we extended the incision to 3 to 4 cm from midline and 2 to 3 cm beyond the front edge of the trape-

zius muscle. This allowed the complete exposure of lymph node chains of these areas and facilitated the exposure of the level IV and distal ligation of the internal jugular vein. In longilineal patients, there may also be greater difficulty in dissection of level IIb (junctional lymph nodes), and a small upper curvature of the posterior end of the incision solves this problem.

The advantages of the cervical transverse incisions are evident, since the natural skin folds are in the same direction, which provides quick, firm healing and excellent aesthetics<sup>11,12</sup>. The rational argument for their use is that the blood supply to the neck has vertical sense, running from bottom to top in the lower cervical limits and from top to bottom in upper cervical limits<sup>13-16</sup>. The biggest fear with the single and extended transverse incision approach for cervical lymph node dissection is the possibility of technical difficulty inducing greater lymph node recurrence rate. According to our results of lymph nodes dissected in the surgical specimens (average 34.25), which do not differ from that found in the literature nor from our average in combined incisions, we can confirm the effectiveness of this surgical approach to cervical lymph node dissections.

Another aspect one must consider when planning a surgical approach for cervical lymph node dissection is the possibility of association with other incisions to treat the primary tumor<sup>17</sup>. In patients with primary tumors of the posterior portions of the oral cavity or oropharynx and undergoing unilateral neck dissection, the maneuver used for surgical exposure was to extend the cervical incision in the opposite neck and associate a preauricular access. In this way, we avoid incision through the mentonian region and the lower lip, which provides great aesthetic gain. Extending the incision to the opposite neck side demands more surgical handling and hence could lead to increased surgical time. However, when comparing the surgical time with the surgeries performed with a combination of incisions, we found that it did not happen. Moreover, the aesthetic gain was large, since it avoided a vertical incision in a visible region, as is the submental region.

It was evident to us the good surgical exposure provided by the single transverse neck incision to perform

radical neck dissection, whether classic, modified or selective. Without increasing the surgical time, it provided good surgical exposure, little technical difficulty, the possibility of proper handling of primary lesions associated or not with other incisions, and especially good aesthetic and functional results. This led us to standardize this approach in our service as a routine when handling neck dissections. As for the aesthetic and functional aspect, we could observe the benefit of the transverse incision in the postoperative follow-up, with aesthetic gains in concealing the incision with the natural skin folds. In addition, in the functional aspect, although the follow-up time is still small, there were no complaints of the longer follow-up patients regarding scarring retractions. The dysfunction

of the shoulder girdle does not depend on skin incision, so we did not consider this aspect in our study.

Since the patients studied were consecutive, there were no exclusion criteria for indicating the surgical incision. Due to the low number of complications related to this surgical approach, we consider that the staging had no influence on them.

In conclusion, transverse and extended skin incisions for radical neck dissections provided: (1) good surgical exposure and little technical difficulty; (2) feasibility when dissecting all lymph node levels; (3) no interference with the surgical procedure; (4) the possibility of proper handling of primary lesions, associated or not with other incisions; and (5) good aesthetic and functional results.

## R E S U M O

**Objetivo:** verificar a eficácia da incisão cervical única, transversa e estendida, para o esvaziamento cervical radical. **Método:** estudo prospectivo, de janeiro de 2008 a janeiro de 2009, de 18 pacientes submetidos a tratamento cirúrgico de tumores malignos da via aerodigestiva superior. A lesão primária se situava na cavidade oral em oito casos, na orofaringe em três, no seio piriforme em três, na laringe em dois, no seio maxilar em um e em um caso a lesão primária era oculta. Houve 29 esvaziamentos, sendo oito bilaterais e 10 unilaterais (26 radicais e três seletivos). O estadiamento revelou nove pacientes com tumor T4, um T3, seis T2, um T1 e um Tx. Cinco pacientes eram N0, nove N2b, um N2c e três N3. A média de linfonodos dissecados foi de 34,25. O esvaziamento cervical foi realizado por meio de uma única incisão localizada no terço médio do pescoço, coincidente com dobra cutânea, com extensão de cerca de 2 a 3 cm para trás da borda anterior do músculo trapézio e 3 a 4 cm da linha média para os esvaziamentos cervicais unilaterais. **Resultados:** como complicações houve necrose de retalho miocutâneo em um paciente com radioterapia prévia, uma fistula linfática, uma deiscência do traqueostoma, um abscesso cervical, uma fistula salivar e uma deiscência de sutura. **Conclusões:** a incisão única e estendida proporciona exposição adequada das estruturas do pescoço, sem comprometer o tempo cirúrgico, mesmo em esvaziamentos bilaterais. Não compromete a ressecção de todos os linfonodos cervicais, apresenta excelentes resultados estéticos e funcionais e é facilmente associada com outras abordagens para ressecção do tumor primário.

**Descritores:** Esvaziamento Cervical. Complicações Pós-Operatórias. Carcinoma de Células Escamosas. Estudos Prospectivos

## REFERENCES

- Magrin J, Kowalski LP, Correia LMC. Esvaziamentos cervicais. In: Kowalski LP Afecções cirúrgicas do pescoço. 1ª ed. São Paulo: Atheneu; 2005. p.183-99.
- Becker GD. Extended single transverse incision for composite resections: an update of technique and results. *Laryngoscope*. 1984;94(5 Pt 1):605-7.
- McFee WF. The surgical treatment of carcinoma of the thyroid gland, with special reference to the metastasis. *Surg Clin North Am*. 1953;361-87.
- Attie JN. A single transverse incision for radical neck dissection. *Surgery*. 1957;41(3):498-502.
- Crile G. Excision of cancer of the head and neck, with special reference to the plan of dissection based on 132 patients. *JAMA*. 1906;47:1780-86.
- Chagas JFS, Pascoal MBN, Aquino JLB. Incisão transversa estendida e única para esvaziamento linfonodal cervical radical. *Rev Bras Cir Cabeça Pescoço*. 2006;35(1):45-7.
- Brown JB, McDowell F. Neck dissections for metastatic carcinoma. *Surg Gynec Obst*. 1944;79:115-24.
- Myssiorek D, Becker GD. Extended single transverse neck incision for composite resections: does it work? *J Surg Oncol*. 1991;48(2):101-5.
- Acar A, Dursun G, Aydin O, Akbas Y. J incision in neck dissections. *J Laryngol Otol*. 1998;112(1):55-60.
- Woods JE, Yugueros P. A safe and rapid technique for modified neck dissection. *Ann Plast Surg*. 1999;43(1):90-5.
- Omura S, Bukawa H, Kawabe R, Aoki S, Fujita K. Comparison between hockey stick and reversed

- hockey stick incision: gently curved single linear neck incisions for oral cancer. *Int J Oral Maxillofac Surg.* 1999;28(3):197-202.
12. Dissanayaka L. A modified single flap for neck dissection in oral cancer. *Head Neck.* 1990;12(1):74-6.
  13. Appiani E, Delfino MC. Plastic incisions for facial and neck tumors. *Ann Plast Surg.* 1984;13(4):335-52.
  14. Daniell CH, Fee WE Jr. MacFee incisions: dispelling the myth of cervical flap vascular inadequacy. *Head Neck Surg.* 1987;9(3):167-71.
  15. Doberneck RC. An evaluation of wound complications after neck dissection and composite resection utilizing transverse cervical incisions. *Surgery.* 1973;73(2):261-5.
  16. Kademani D, Dierks EJ. A straight-line incision for neck dissection: technical note. *J Oral Maxillofac Surg.* 2005;63(4):563-5.
  17. Becker GD. The extended single transverse neck incision for composite resections. *Trans Sect Otolaryngol Am Acad Ophthalmol Otolaryngol.* 1977;84(5):816-7.
- Received in: 02/04/2016  
Accepted for publication: 11/07/2016  
Conflict of interest: none.  
Source of funding: none.
- Mailing address:**  
Rogerio Aparecido Dedivitis  
E-mail: dedivitis.hns@uol.com.br / dedivitis@usp.br