

Comparative study of topical green and red propolis in the repair of wounds induced in rats

Estudo comparativo do uso tópico de própolis verde e vermelha na reparação de feridas em ratos

LARA LÍVIA VALENÇA BATISTA, UFAL¹; ELIANE APARECIDA CAMPESATTO²; MARIA LYSETE BASTOS DE ASSIS³; ANA PAULA FERNANDES BARBOSA⁴; LUCIANO APARECIDO MEIRELES GRILLO⁵; CAMILA BRAGA DORNELAS⁵

A B S T R A C T

Objective: To evaluate the healing action of green and red propolis, correlating it with the content of flavonoids. **Methods:** We performed quantification of total flavonoids of green and red propolis ethanol extracts for subsequent incorporation in ointment base to 20%. We used 20 Wistar rats divided into four groups: 0.9% saline (S), ointment base (B), green propolis ointment (G) and red propolis ointment (R). All animals were submitted to excisional lesions in the midian back region. The rats were treated daily for 15 days. During this period we observed weight, body temperature and diameters of the wounds. For histological analysis, samples were collected from wounds. At the end of the experiment we performed blood collection and removal of the kidney and liver for biochemical and histological analyzes. **Results:** The levels of total flavonoids of green (4.50%) and red (5.92%) propolis were high (> 2%), but, while the latter showed a content larger than the former, the evolution of green propolis was better in the repair of wounds, both macroscopically and histologically. There were no nephrotoxicity or hepatotoxicity, a result confirmed by biochemical tests (ALT and albumin). Propolis influenced the reduction of total cholesterol, triglycerides and glucose. **Conclusion:** There was no correlation between total flavonoid contents and the healing action of propolis. This reveals the need for elucidation of the flavonoids found in each class of propolis to unravel which one(s) would be important for the healing process.

Key words: Propolis. Biological agents. Wound healing. Flavonoids. Rats.

INTRODUCTION

Factors such as national biodiversity and lower cost make natural products and their byproducts important therapeutic alternatives. Propolis is a ophoterapeutic agent, with the earliest records of use by man reaching back to 300 BC¹.

Since the 80s this product has been widely used in dietary supplements as a disease preventive, due to its good organoleptic characteristics. Its chemical composition is mainly determined by the phytogeographic characteristics existing around the beehive in which it is produced, but it is also seasonally influenced in a same locality².

More than 200 substances have already been identified in propolis from different locations, including phenolic acids, flavonoids, esters, diterpenes, sesquiterpenes, lignans, aromatic aldehydes, alcohols,

amino acids, fatty acids, vitamins and minerals³. This justifies the range of biological properties obtained as antimicrobial, antioxidant, anti-inflammatory, immunomodulatory, hypotensive, healing, anesthetic, anticancer, anti-HIV, anti-cavity, among others. Its successful use as an anti-inflammatory and healing agent is attributed to its flavonoids content⁴.

Given the importance of flavonoids in propolis, they are considered as a kind of marker, such that a test that proves the quality of propolis is the quantification of total flavonoids. The pharmacological activity of these compounds is mainly due to their structural characteristics as tricyclic compound, and to the presence of radical attached to their rings⁵. However, there being in the Northeast region a great diversity of propolis groups, classified according to their physico-chemical composition, there is also, therefore, a large variance in the content of

Work performed at the Center for Multi-User Research Laboratories, School of Nursing and Pharmacy, Federal University of Alagoas, Maceió, Alagoas State – AL, Brazil.

1. Undergraduate, Faculty of Pharmacy, School of Pharmacy and Nursing, Federal University of Alagoas; 2. Associate Professor, Institute of Biological and Health Sciences, Federal University of Alagoas; 3. Associate Professor, Faculty of Nursing, School of Nursing and Pharmacy, Federal University of Alagoas; 4. Associate Professor, Faculty of Medicine, Federal University of Alagoas; 5. Associate Professor, Faculty of Pharmacy, School of Pharmacy and Nursing, Federal University of Alagoas.

flavonoids, which should then influence healing activity, the object of this research.

Propolis from field-rosemary bush (*Baccharis dracunculifolia*), known as green propolis, is produced in the shoot apices of this plant, which is invasive in several regions of Brazil⁶. The red propolis is ranked as the 13th type of Brazilian propolis, found in beehives located in the stem of mangrove bushes in the states of Alagoas, Paraíba, Pernambuco, Sergipe and Bahia, located in Northeastern Brazil. It was observed that bees collect red exudate from the surface of the holes made by insects in the trunk of *Dalbergia ecastophyllum* (L) Taub., known as "monkey-tail", which is the botanical origin attributed to red propolis⁷.

Thus, this worked sought to compare healing action of green and red propolis, correlating it with the content of flavonoids in each.

METHODS

This project was submitted to the Ethics Committee on Animal Use, Federal University of Alagoas and approved under No. 010200-2011-82,

The evaluation of the content of propolis was carried out by the quantification of total flavonoids. For this, a standard curve was constructed with quercetin dihydrate, taken as reference substance (Figure 1).

A solution was made of aluminum chloride 2.5%; one mL of this solution was drawn and added to 9.1 or 8.8 ml of red and green propolis, and then placed in 25 ml flasks, whose volume was completed with ethanol. The solutions were then submitted to dilution to final concentrations of 0.174 and 0.184 mg/ml of red and green propolis, respectively. After 30 minutes, a spectrophotometry reading was taken from each solution at 425nm in a Shimadzu spectrophotometer.

The ointment base was prepared by mixing melted lanoline and vaseline (3:7). The ethanol extracts of green and red propolis were incorporated into the base at a 20% concentration of for topical application⁵.

In this experiment, we used 20 male Wistar rats (*Rattus norvegicus albinos*), aged three months, with body

weight of 200 + 25 g, from the animal colony of the Federal University of Alagoas. The animals were kept in air-conditioned environment (20-22° C) under artificial lighting with light-dark cycles every 12 hours, housed in individual cages containing wood shavings lining, with free access to food and water.

The first 15 days before surgery were considered the quarantine period, to identify possible variables that could interfere with the results. After this period, the rats were randomly divided into four groups: 0.9% saline (S), ointment base (B), green propolis ointment (G) and red propolis ointment (R).

To perform the surgical procedure, animals were weighed and then anesthetized with sodium thiopental 40mg/kg intraperitoneally. After induction of anesthesia, we proceeded to epilation, followed by site antisepsis with 2% chlorhexidine preparation and the lesions made with the aid of a punch with a 1.2-cm diameter.

In each animal we made four excisional lesions in the midline of the back, with removal of skin tissue, exposing the aponeurosis. Then, the rats were subjected to the respective treatments with the aid of sterile syringes of 1ml of ointment specific to each group. The dressings were performed daily for 15 days; the wounds were washed with 0.9% saline at each new replacement of the medication to remove residues and crusts. During this fortnight, in the second, sixth, 11th and 15th days post-operation we observed: the animal's weight and body temperature and diameter of wounds. We also removed of part of the lesions (n = 1 per group), which were identified and stored in formaldehyde 10% for histology. At the end of the experiment, the animals were weighed, anesthetized (thiopental sodium 40mg/kg) and underwent thoracotomy, followed by cardiac puncture for blood collection (3 ml were collected from each animal); after laparotomy kidneys and liver were removed for biochemical analysis and histology, respectively.

At the macroscopic analysis wounds, we observed the occurrence of inflammation, granulation and epithelialization. In the study of optical microscopy, the following parameters were evaluated: inflammatory cells (macrophages), neovascularization, fibrin network, granulation tissue, collagen fibers, complete vessels and epithelialization. In both evaluations ranks were assigned by the method of crosses: 0 (absent), + (few), ++ (moderate) and +++ (intense)⁸. In biochemical analyzes, we used enzymatic methods for the following parameters: total cholesterol, triglycerides, glucose, albumin and glutamic-pyruvic transaminase (ALT). The results were obtained by spectrophotometric absorbance at 500nm, 505 nm, 630nm and 340nm.

RESULTS

Table 1 shows the results of spectrophotometric assays performed with green and red propolis to determine

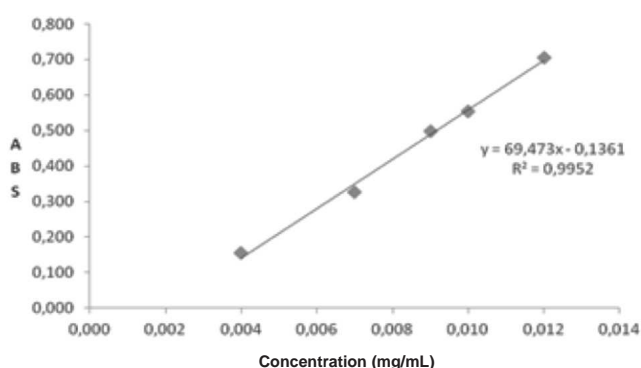


Figure 1 - Standard curve of quercetin dihydrate.

the levels of total flavonoids, expressed as quercetin equivalents. It is observed that the total flavonoid content of propolis (5.92%) is higher than that of the green one (4.50%).

Figure 2 shows curves of measurements obtained after evaluating the diameter of the lesions (A), the weight of the animals (2B) and the average temperature (2C).

In figure 2A it can be observed the reduced average diameters of the lesions during the treatment of groups and that the differences found were not statistically significant. However, in no groups we observed a complete re-epithelialization of wounds.

In figure 2B, which shows the average weights of the animals in each group throughout the experiment, it is observed that the weight decreased but, as the respective treatments were done, it was gradually restored. The behavior was the same in all groups.

Temperature was a factor that varied according to group, because its values were stable throughout the

experiment when treatment was saline or ointment base, but elevation was observed in treatment with propolis after surgery, which was restored with time (Figure 2C).

Table 2 lists the phases of healing. Inflammation was present in all groups by the end of the experiment. The granulation was absent at day 11 post-surgery in the groups treated with green and red propolis, since a moderate epithelialization was already installed. On the 15th day post-operation a complete epithelialization was observed in animals treated with the ointment of green propolis.

The analysis of group using green propolis ointment showed that the macroscopic data (lesion diameter, weight and average temperatures of animals) corroborate the histological ones, with the presence of macrophages, neovascularization, fibrin network and granulation tissue, complete vessels, epithelialization and collagen fibers. Histological analysis of liver and kidney were in the normal range, showing no toxicity.

Table 1 - Quantification of total flavonoid content.

Propolis type	Absorbance	Mean ±Standard deviation	Concentration (mg/ml)	Content (%)
Red	0,632	0,580 ± 0,106	0,174	5,92
	0,676			
	0,431			
Green	0,413	0,440 ± 0,029	0,184	4,5
	0,426			
	0,480			

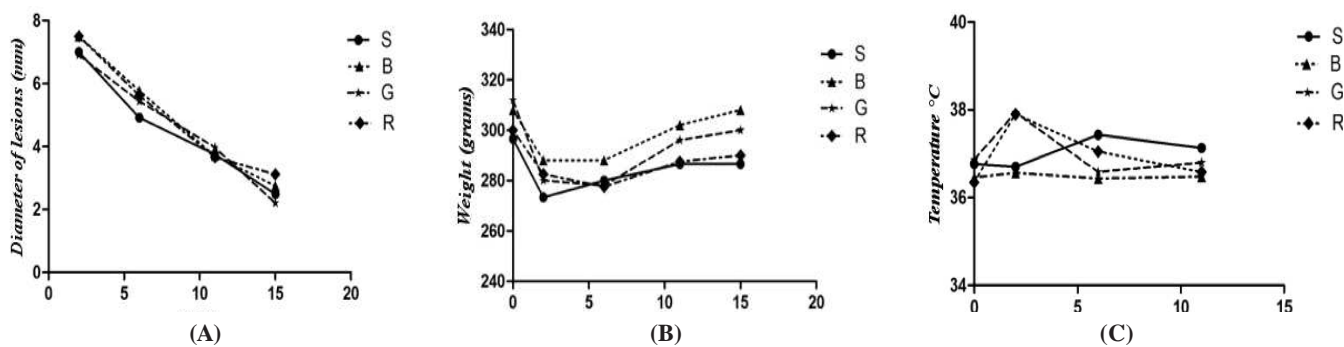


Figure 2 - Mean curves of observed parameters: A- diameter of lesions, B- weight; C- temperature. Groups: S = saline 0.9%; B = base ointment; G = green propolis ointment; R = red propolis ointment.

Table 2 - Stages healing observed with the use of 0.9% saline (S), ointment base (B), propolis ointment green (G) and from propolis ointment (R) on two, six, 11 and 15 days of treatment.

Phases of Healing	2 days				6 days				11 days				15 days			
	S	B	G	R	S	B	G	R	S	B	G	R	S	B	G	R
Inflamation	+	+	0	+	++	+	++	++	+++	+++	+	++	+	++	+	+
Granulation	0	0	0	+	+	++	+	+	+	++	0	0	0	+	0	0
Epithelialization	0	0	0	0	0	0	0	0	+	+	++	++	++	++	+++	++

Grades: Missing: 0; little: +; moderate: ++ or intense: +++

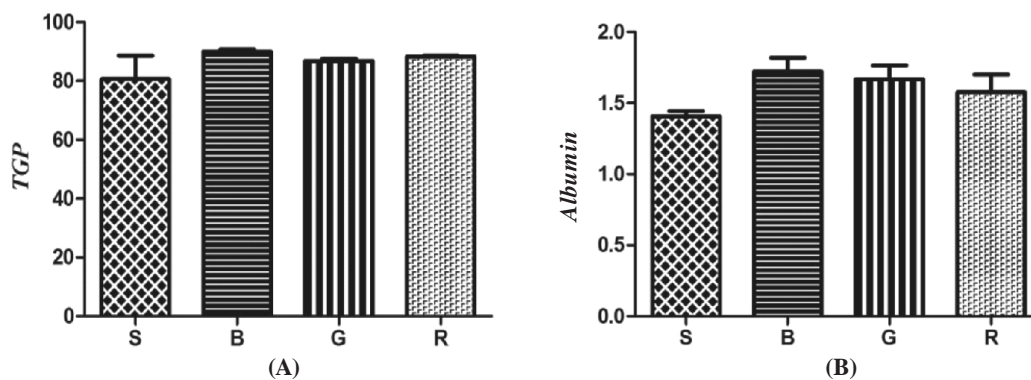


Figure 3 - Glutamic-pyruvic transaminase (A) and serum albumin (B) observed on the last day of the experiment. Groups: S = saline 0.9%; B = base ointment; G = green propolis ointment; R = red propolis ointment.

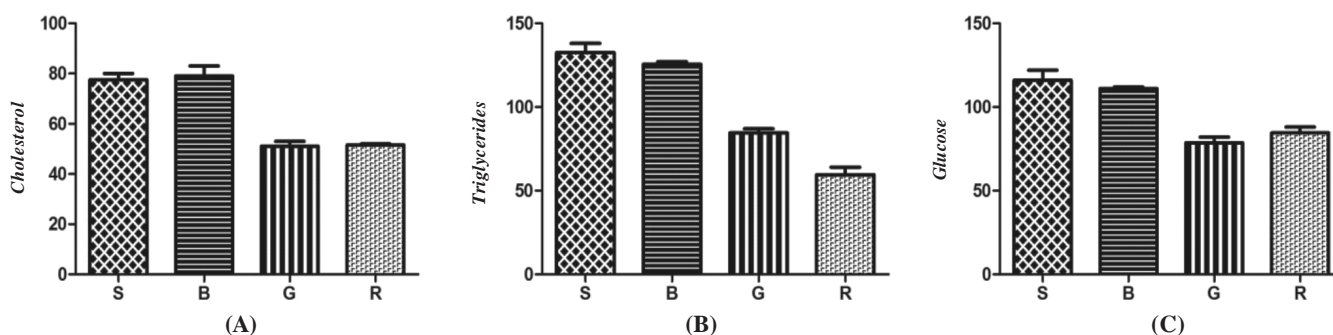


Figure 4 - Levels of total cholesterol (A), triglyceride (B) and glucose (C) recorded on the last day of the experiment. Groups: S = saline 0.9%; B = base ointment; G = green propolis ointment; R = red propolis ointment.

Tests for albumin and glutamic-pyruvic transaminase (ALT), figure 3A, and serum albumin, Figure 3B, confirm this result, since there was no involvement of liver function.

When we assessed the action of green and red propolis ointments on the lipid profile of the animals, it was found that they were able to decrease both total cholesterol levels (Figure 4A) and triglycerides' (Figure 4B). There was also observed a hypoglycemic action with these treatments, which is depicted in figure 4C.

DISCUSSION

In this study, values of total flavonoids found for the red and green propolis were superior to those already described in the literature, as reported for the sample of propolis from Cabreúva – São Paulo State (2.641%)³, a sample of propolis derived from Maceió – Alagoas State (3.291%) and another from a region of caatinga (Brazilian savanna) in Cabo Verde – Bahia State (3.148%)⁹. These results suffer interference from the numerous variables that can be involved, either in relation to natural factors, such as seasonality and the flora of each region, or in respect to extractive process and the conditions used⁶.

The first parameter evaluated the *in vivo* study was the diameter of the lesions of animals during treatment groups. Despite the reduction of the average diameters of the lesions with time, resulting from wound healing, in either group was observed complete epithelialization of wounds. This experiment rendered results different from those found in the literature^{5,10}. The Rahal group, which conducted a study on mice with clean wounds with ointment of green propolis (no mentioning the concentration), showed a more significant result in reducing injuries treated with propolis when compared to lesions treated with saline 0.9%. The treatment also led to complete epithelialization on day 14 of the experiment.

A study in rats with clean wounds treated with cream base containing 20% propolis and base cream containing green tea at a concentration of 20% showed no significant differences between the compounds evaluated (saline, base cream, 20% propolis cream and 20% green tea cream), but total healing was observed on the 15th day of the experiment in all groups⁵. An interesting and already well known feature is the importance of maintaining the wound clean in the healing process, since the lesions treated with 0.9% saline healed in the same proportion as lesions treated with the ointments tested.

The behavior of the average weight of the animals was also the same in all groups. The weight reduction in the first days is probably attributed to the surgical procedure, being restored during the experiment.

Another study reports that, in the first 48 hours postoperatively, a rise in temperature up to 38° C can be observed, consequent of the increase metabolism and surgical trauma¹¹. But as the temperatures rose only in the groups treated with propolis, this result can relate to their immunostimulatory activity. Propolis promotes macrophage activation, playing a fundamental role in the body's defense by phagocytosis, production of free radicals, mediating inflammatory processes and secretion of a variety of different biochemical substances such as enzymes, cytokines, and complement components; the increase in cellular and humoral immune responses can also be observed¹².

According macroscopical and histological evaluations, the group of animals treated with green propolis stood out. And despite histopathological analyzes indicating that propolis showed no renal or hepatic toxicity (corroborated by biochemical), it resulted in some systemic effects.

As for the effect on lipid profile of animals, some studies show that antioxidants have properties that reverse endothelial dysfunction caused by excessive cholesterol and also reduce the number of coronary events. The antioxidant property is justified by the presence of flavonoids, which has no known mechanism of action, but it is proposed that there is a relationship with the inhibition of oxidation of low density lipoproteins (LDL) and consequent protection from atherosclerosis¹³⁻¹⁵. Another mechanism would be pointed to the inhibitory activity on the enzyme

hydroxymethylglutaryl CoA reductase (HMG-CoA reductase), blocking the conversion of substrate hydroxymethylglutaryl-CoA (HMG-CoA) to mevalonic acid by inhibiting the biosynthesis of cholesterol, the same action as other drugs', i.e., statins¹⁶.

The hypoglycemic action of propolis observed can be attributed to flavonoids for their effects on chronic degenerative diseases, since these secondary metabolites have properties against free radicals, generators of oxidative stress¹⁷, interfering, both in increased release of insulin by Langherans' islets, and improvement of receptors in and increased recognition of insulin.

The in vivo results showed no significant differences on the healing process, although the group treated with 20% green propolis ointment has shown slightly better evolution. The fact seems to contradict the relationship between flavonoid content and healing action, reported in literature, but it is noteworthy that total flavonoids were quantified. It is then clear that this correlation is not, and that the elucidation of the flavonoids found in each propolis group would probably be more important to unravel which flavonoid(s) would be representative in the healing process.

Finally, we emphasize the importance of the work by the possibility of it social impact, with the possibility to render access to medicines for the less favored population and bring benefits to society, expanding their knowledge on propolis and its applications.

In conclusion, it was not possible to correlate the total flavonoid content with the healing action of propolis. This reveals the need for elucidation of flavonoids found in each class of propolis to unravel which flavonoid would be representative in the healing process.

R E S U M O

Objetivo: Avaliar a ação cicatrizante de própolis verde e vermelha, correlacionando ao teor de flavonoides. **Métodos:** Foi realizada a quantificação de flavonoides totais dos extratos etanólicos de própolis verde e vermelha para posterior incorporação em pomada base a 20%. Utilizou-se 20 ratos Wistar distribuídos em quatro grupos: solução salina a 0,9% (S), pomada base (B), pomada própolis verde (G), pomada própolis vermelha (R), todos submetidos à confecção de lesões excisivas na região mediana do dorso. Os ratos foram tratados diariamente durante 15 dias. Neste período foram observados peso; temperatura corporal; diâmetro das feridas. Para análise histológica, amostras das feridas foram coletadas. Ao fim do experimento foram realizadas coleta sanguínea e remoção do rim e fígado para análises bioquímica e histológica. **Resultados:** Os teores de flavonoides totais das própolis verde (4,50 %) e vermelha (5,92 %) foram elevados (>2 %), mas, embora a segunda apresente teor maior que a primeira, a evolução da própolis verde, macro e histologicamente, foi melhor na reparação das feridas. Não foram observadas nefro ou hepatotoxicidade, resultado corroborado pelos ensaios bioquímicos (TGP e albumina). A própolis influenciou na redução de colesterol total, triglicerídeos e glicemia. **Conclusão:** Não foi possível correlacionar o teor de flavonoides totais com a ação cicatrizante da própolis. O dado revela a necessidade da elucidação dos flavonoides encontrados em cada classe de própolis para desvendar qual (ou quais) flavonoide(s) seria(m) representativo(s) no processo cicatricial.

Descritores: Própolis. Agentes biológicos. Cicatrização. Flavonoides. Ratos.

REFERENCES

1. Lustosa SR, Galindo AB, Nunes LCC, Randau KP, Rolim Neto PJ. Própolis: atualizações sobre a química e a farmacologia. Rev bras farmacogn. 2008;18(3):447-54.
2. Sousa JPB, Furtado NAJC, Jorge R, Soares AEE, Bastos JK. Perfis físico-químico e cromatográfico de amostras de própolis produzidas nas microrregiões de Franca (SP) e Passos (MG), Brasil. Rev bras farmacogn. 2007;17(1):85-93.

3. Funari CS, Ferro VO. Análise de própolis. *Ciênc tecnol aliment*. 2006;26(1):171-8.
4. Barbosa MH, Zuffi FB, Maruxo HB, Jorge LLR. Ação terapêutica da própolis em lesões cutâneas. *Acta Paulista de Enfermagem*. 2009;22(3):318-22.
5. Vieira AP, Santos NR, Borge JHS, Vicenzi MPA, Schmitz WO. Ação dos flavonoides na cicatrização por segunda intenção em feridas limpas induzidas cirurgicamente em ratos Wistar. *Sem Ciências Biológicas e da Saúde*. 2008;29(1):65-74.
6. Nascimento EA, Chang R, Morais SAL, Piló-Veloso D, Reis DC. Um marcador químico de fácil detecção para a própolis de *Alecrim-do-Campo* (*Baccharis dracunculifolia*). *Rev bras farmacogn*. 2008;18(3):379-86.
7. Dausch A, Moraes CS, Fort P, Pacheco E, Lima IB, Abreu JA, et al. Própolis vermelha e sua origem botânica. *Mensagem Doce* [Internet]. 2006 [citado 2011 Dez 20];89:2-8. Disponível em: <http://www.apacame.org.br/mensagemdoce/89/artigo.htm>
8. Coelho JM, Antonioli AB, Silva DN, Carvalho TMMB, Pontes ERJC, Odashiro AN. O efeito da sulfadiazina de prata, extrato de ipê-roxo e extrato de barbatimão na cicatrização de feridas cutâneas em ratos. *Rev Col Bras Cir*. 2010;37(1):45-51.
9. Righi AA, Alves TR, Negri G, Marques LM, Breyer H, Salatino A. Brazilian red propolis: unreported substances, antioxidant and antimicrobial activities. *J Sci Food Agric*. 2011;91(13):2363-70.
10. Alves DFS, Cabral Júnior FC, Cabral PPAC, Oliveira Júnior RM, Rego ACM, Medeiros AC. Efeitos da aplicação tópica do mel de *Melipona subnitida* em feridas infectadas de ratos. *Rev Col Bras Cir*. 2008;35(3):188-93.
11. Stracieri LDS. Cuidados e complicações pós-operatórias. *Medicina (Ribeirão Preto)*. 2008;41(4):465-8.
12. Fischer G, Hübner SO, Vargas GD, Vidor T. Imunomodulação pela própolis. *Arq Inst Biol São Paulo*. 2008;75(2):247-53.
13. César TB, Rodrigues LU, Araújo MP, Aptekmann NP. Suco de laranja reduz o colesterol em indivíduos normolipidêmicos. *Rev Nutr*. 2010;23(5):779-89.
14. Oliveira TT, Silva RR, Dornas WC, Nagem TJ. Flavonoides e aterosclerose. *RBAC*. 2010;42(1):49-54.
15. Giehl MR, Dal Bosco SM, Laflor CM, Weber B. Eficácia das flavonoides de uva, vinho tinto e suco de uva tinto na prevenção e no tratamento secundário da aterosclerose. *Sci med*. 2007;17(3):145-55.
16. Campo VL, Carvalho I. Estatinas hipolipêmicas e novas tendências terapêuticas. *Química Nova*. 2007;30(2):425-30.
17. Dornas WC, Oliveira TT, Rodrigues-das-Dores RG, Santos AF, Nagem TJ. Flavonoides: potencial terapêutico no estresse oxidativo. *Rev Ciênc Farm Básica Apl*. 2007;28(3):241-9.

Received on 20/05/2012

Accepted for publication 23/07/2012

Conflict of interest: none

Source of funding: no

How to cite this article:

Batista LLV, Mella EAC, Assis MLB, Barbosa APF, Grillo LAM, Dornelas CB. Estudo comparativo do uso tópico de própolis verde e vermelha na reparação de feridas em ratos. *Rev Col Bras Cir*. [periódico na Internet] 2012; 39(6). Disponível em URL: <http://www.scielo.br/rcbc>

Address for correspondence:

Camila Braga Dornelas

E-mail: dornelascb@yahoo.com.br