

Advances in the management of early esophageal carcinoma

Avanços na abordagem do carcinoma precoce de esôfago

VITOR ARANTES, MD, MSc, PhD¹; ELIAS ALFONSO FORERO PIÑEROS, MD²; KEN YOSHIMURA³; TAKASHI TOYONAGA, MD³

A B S T R A C T

In Western countries, the squamous cell carcinoma of the esophagus (SCC) is usually detected at an advanced stage, when the chances of cure are remote and the prognosis poor. However, in recent years, there has been a series of advances in the management of esophageal SCC, such as: identification of risk groups for the development of this tumor; the use of high-resolution endoscopy and chromoendoscopy with Lugol, favoring the diagnosis of SCC at early stages; and the development of endoscopic techniques for *en bloc* endoluminal tumor resection, named endoscopic submucosal dissection (ESD). This progress has enabled the application of minimally invasive endoscopic treatment with curative potential in selected patients with superficial esophageal SCC. The present review article, written by a multicenter, international group, has as primary objective to contribute to the understanding of the major recent advances in the management of early esophageal SCC. As a secondary objective, it aims to provide a thorough and detailed review of the ESD technique developed by Japanese experts in order to contribute to the diffusion of this concept and the incorporation of these technologies in Brazilian and Latin American medicine.

Key words: Carcinoma. Carcinoma, squamous cell. Esophagus. Prognosis. Therapeutics.

INTRODUCTION

Esophageal cancer is the third leading cause of digestive cancer death¹. The prognosis is poor, with a survival rate at five years only 15%². In Brazil, 10,420 new cases of cancer of the esophagus are estimated to occur in 2012, 7770 in men and 2650 in women³. Squamous cell carcinoma (SCC) of the esophagus predominates in men (3.6:1) between the fifth and seventh decades of life⁴, and the mortality rate in southern Brazil is 14.3 men and 4.2 women per 100,000⁵. When the diagnosis of esophageal SCC is done early, the prognosis is significantly better, with survival rates of 95% in five years⁶.

This review aimed to describe the major recent advances occurred in the management of early esophageal neoplasia, with emphasis on the current role of high resolution endoscopy and chromoendoscopy for the diagnosis of early forms of the disease and the importance of new techniques for minimally invasive endoscopic endoluminal resection, called endoscopic submucosal dissection (ESD).

METHODS

We performed a literature review in MEDLINE (PubMed) and Google Science major publications circulated in English, since 1990, with the descriptors "esophageal squamous cell carcinoma", "endoscopic submucosal dissection", "management" and "lugol chromoscopy". In the selection of articles, we included original articles and publications by Brazilian authors. Regarding the technical description of the ESD procedure, we prioritized articles published by one of the authors (TT), which has one of the world's largest series of ESD (4000 cases performed until 2012) and a line of research dedicated to the development of ESD equipment and technique.

Diagnosis

The big challenge in Brazil and other Western countries is to establish the diagnosis of esophageal cancer at an early stage, when patients are asymptomatic and endoscopic changes are subtle and difficult to recognize, sometimes manifesting just as an epithelium discolouration (redder or paler), roughness, unevenness of the microvascular pattern, slight elevation or depression of the

Work done at the Department of Surgery, Division of Endoscopic Surgery, Alfa Institute of Gastroenterology, Faculty of Medicine, Universidade Federal de Minas Gerais, Belo Horizonte - Brazil, Department of Gastroenterology, Hospital Central de la Police, Bogotá - Colombia, Department of Endoscopy, Kobe University Hospital, Kobe - Japan.

1. Associate Professor, Department of Surgery, Faculty of Medicine, UFMG - MG-BR; 2. Director of Gastroenterology and Endoscopy Service of the Hospital de la Police; 3. Associate Professor, Department of Gastroenterology, Kobe University Hospital.

surface. The best method for screening of esophageal cancer is endoscopy, especially when combined with chromoendoscopy techniques^{7,8}. The application of endoscopy in the general population for screening of esophageal SCC is not justifiable due to the costs of the procedure. Nevertheless, in a high-risk population a screening program can be cost-effective. There is an association of esophageal SCC with the following factors: family history of cancer; male gender; exposure to nitrosamines; thermal injury by hot drinks, such as tea; micronutrient deficiency (riboflavin, retinol, ascorbic acid, alpha-tocopherol, selenium, magnesium, zinc); diet poor in fresh fruits and vegetables; radiation; alcohol and tobacco; history of upper aerodigestive (UAD) SCC; caustic lesions of the esophagus; achalasia; tylosis and Plummer-Vinson syndrome; infection with human papilloma virus^{7,8}. Among all these factors, the history of UAD SCC is what keeps the most consistent relationship with synchronous or metachronous cancer of the esophagus and therefore recommends endoscopy for screening of this population^{7,8}.

The chromoendoscopy using Lugol's solution is considered the method of choice for diagnosis of esophageal SCC⁴. The Lugol is a reaction dye, in which iodine strongly stains the squamous cells of the esophagus, which are rich in glycogen, not staining the dysplastic or neoplastic cells, poor in that carbohydrate. An important, recently described, aspect of chromoendoscopy with Lugol, often not valued by endoscopists, is called the "pink color sign"^{9,10}. This signal consists of a color change of the neoplastic lesion (Lugol negative) from yellow to pinkish about two to five minutes after application of Lugol (Figures 1 and 2). This transformation is due to low glycogen levels existing in the neoplastic cells of the esophagus, and its occurrence indicates, with high specificity, the existence of high-grade dysplasia or squamous cell carcinoma^{9,10}. From 2009 on, the principal author (VA) conducted a program of tracking of esophageal neoplasia in patients with UAD SCC by transnasal endoscopy without sedation associated with digital and Lugol chromoendoscopy. Among 106 patients examined, there were 13 cases of esophageal SCC (12.3%), and in 77% of patients the cancer was at an early stage, enabling treatment by endoscopy in eight cases¹¹. This high incidence illustrates the importance of tracking these high-risk patients also in Brazil.

Classification and Staging of Superficial Esophageal Neoplasia

According to the endoscopic classification published in the Paris Consensus¹², superficial neoplasia is an injury whose morphological aspects suggest involvement of the mucosa and submucosa layers, without infiltration of *muscularis propria*. In Japan superficial lesions are conventionally called the types 0 in reference to the classification of Borrmann advanced gastric tumors¹². There are three subtypes of superficial lesions: protruded (type-I 0), flat (type II-0) and excavated (type III-0). The lesions are

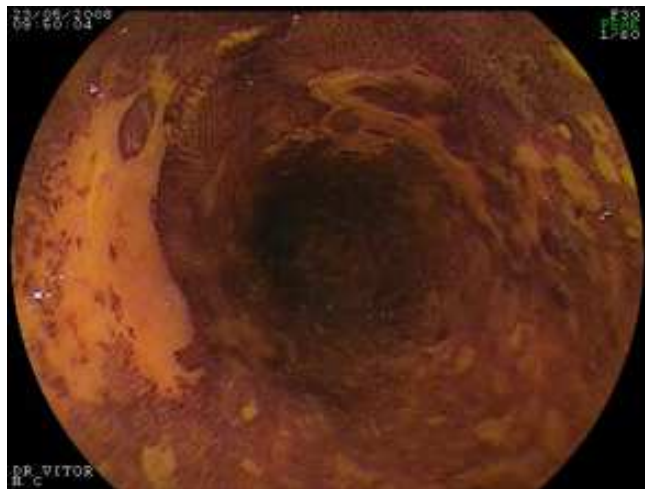


Figure 1 - Endoscopic image of the esophagus after chromoendoscopy with Lugol. The normal mucosa is brown and a flat, yellowish lesion that does not stain with Lugol stands out.

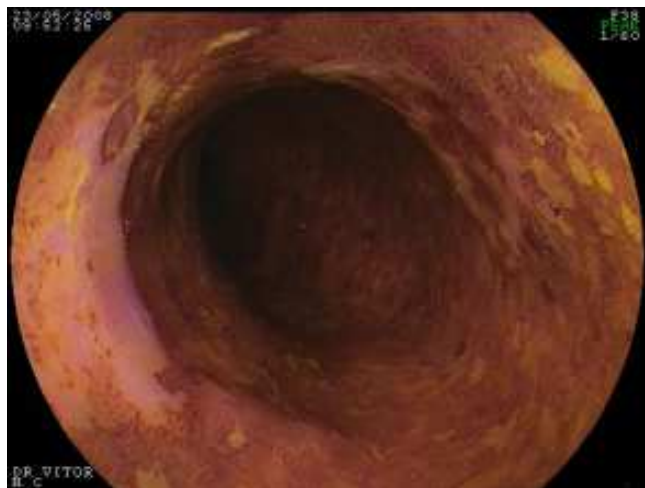


Figure 2 - Picture of the same lesion two minutes later appears pinkish, featuring the pink color sign, which has a high predictive value for malignancy.

subclassified into protruding pedunculated (0-Ip), subpedunculated (0-Isp) and sessile (0-Is). Esophageal superficial neoplasms are more frequently flat, which are subdivided into superficially protruded compared to the adjacent mucosa (IIA), flat (IIB) and excavated (IIC), the forms protruding and excavated being rare¹². The superficial neoplasias are further subdivided according to the degree of transmural penetration. M1 corresponds to the epithelium and the basal layer, M2 the *lamina propria* or chorion, and M3 the muscular mucosa. The involvement of the submucosa is also subdivided into SM1 (upper third), SM2 (middle third) and SM3 (lower third).

Regarding the designation of histopathological superficial tumors, the current recommendation is that it be adopted to standardize terminology proposed by the Vienna Classification¹³, and the tumor classified according to the TNM classification-p ("p" for pathology). In the

absence of invasion of the *lamina propria*, the lesion is called intraepithelial neoplasia of low or high grade, being also employed the term carcinoma in situ (pTis). Occurring the invasion of the *lamina propria*, there esophageal neoplasia or microinvasive intramucosal carcinoma (pT1m). When there is infiltration of the submucosal layer, the cancer is considered invasive (pT1sm).

The importance of these subdivisions comes from the fact that the risk of lymph node metastases in superficial neoplasms has close relation with the depth of invasion of the lesion in the wall of the organ. This criterion is crucial for selection of patients to endoscopic treatment with curative purposes. When the affection is limited to the epithelium (M1) and the *lamina propria* of the esophagus (M2), the risk of lymph node spread is close to zero and the local excision is sufficient to complete cure^{12,14}.

When cancer invades the *muscularis mucosa* (M3) and the upper portion of the submucosa to a depth of 200 μ m (SM1), conceptually this risk can achieve 9% to 19%, respectively. In these cases that straddle the boundary of the curative endoscopic treatment, it is essential to deepen the evaluation and carefully observe the following parameters: tumor size; presence of lymphatic or vascular invasion; and horizontal extent (width) of the invasion of the *muscularis mucosa*.

In the study by multivariate analysis of Choi *et al.*¹⁵, evaluating 190 esophagectomy specimens, the authors observed that in tumors affecting focally layers M3/SM1 when neoplastic lesion size is less than 3cm, there is no lymphovascular invasion and involvement of the lamina *muscularis mucosa* is less than 3mm wide, the risk of lymph node metastasis is very low (one in 63 cases - 1.5%). In the presence of massive infiltration of the submucosa (SM2 and SM3), lymph node metastases occur in approximately 40% of cases.

In addition to the detailed evaluation of morphological endoscopy, the staging of early esophageal neoplasia can be done with endoscopic ultrasonography. The radial or sectorial echoendoscope operates at low frequencies (5 to 12MHz), which allows to split the wall of the gastrointestinal tract in five layers. By having greater penetration, the echoendoscope enables evaluating the mediastinum and the celiac trunk in search of suspicious lymph nodes. The high-resolution miniprobe operates at high frequencies, between 15 and 30MHz, which allows to split the wall of the gastrointestinal tract in seven or nine layers, facilitating accurate assessment of the vertical extent of invasion of the tumor.

Buskens *et al.*¹⁶ analyzed the accuracy of endoscopic ultrasound in the staging of 77 patients with early esophageal cancer undergoing esophagectomy. Histological analysis of the surgical specimen was the gold standard. The authors found that endoscopic ultrasound correctly demonstrated the absence of lymph nodes in 93% of cases. The negative predictive value of endoscopic ultrasound to detect the absence of submucosal invasion was 95%.

To maximize the accuracy of endoscopic ultrasonography in esophageal SCC, the authors recommend combining the use of high-frequency miniprobe for T stage and dedicated echoendoscopes for lymph node tracking. The presence of metastatic lymph nodes suggests that neoplastic lesion is not curable only with local resection. The main limiting factor of endoscopic ultrasonography in patients with early esophageal neoplasia is the overstaging caused by inflammatory or desmoplastic reaction adjacent to malignancy, a factor that can result in incorrect routing of patients to other forms of treatment other than endoscopy.

The absence of definite signs of neoplastic invasion of the submucosal layer and malignant lymphadenopathy substantiates the indication of endoscopic resection. The final conduct will be dictated by the systematic analysis of the resected specimen's histology. If this assessment identifies invasion of M3 or SM, lymphovascular invasion or involvement of the deep margin of the tumor resection, treatment should be redirected (chemotherapy and radiotherapy or surgery).

Whereas the histological evaluation will be the deciding factor in defining the ultimate approach, every effort should be made to produce a quality specimen and prevent the lesions from being fragmented, as in piece-meal mucosectomy, since this method impairs proper margin analysis and characterization of endoscopic resection as R0 (complete removal of the tumor).

Indications for Endoscopic Treatment of Superficial Esophageal Neoplasia

The classically accepted criteria for indication of endoscopic resection for the treatment of superficial esophageal neoplasia¹⁷ include: in-depth involvement restricted to M1 and M2 layers (epithelium and *lamina propria*); maximum length of 3cm; lateral extent less than $\frac{1}{3}$ of the circumference; and a maximum of four lesions.

With improving techniques of endoscopic resection, especially after the advent of ESD, these criteria tend to expand, accepting endoscopic treatment of lesions larger than 3cm, occupying the entire circumference of the esophagus and no limit to the number of lesions, provided that all are restricted to the mucosa.

Endoscopic treatment modalities for esophageal cancer include resection (mucosectomy or ESD) and ablation techniques. The ablation methods include photodynamic therapy, argon plasma coagulation, YAG-laser, multipolar electrocoagulation and, more recently, radiofrequency ablation. The ablative modalities preclude histopathological analysis of the eradicated neoplastic lesion, which is crucial to define whether the endoscopic intervention was curative. Therefore, ablative methods should not be indicated for the endoscopic treatment of esophageal SCC. In this review we thoroughly discuss the role of mucosectomy and ESD in the management of superficial esophageal cancer.

Technical Principles of Endoscopic Mucosal Resection

The wall of the gastrointestinal tract is comprised of two main components: the mucosa and *muscularis propria*. These elements are united by a layer of loose connective tissue (submucosa). The wall of the esophagus has a thickness between 3.5 and 4mm. Therefore, when resecting a superficial neoplastic lesion, there is a risk of inadvertent grasping of the *muscularis propria* and consequent visceral perforation.

In order to prevent perforation, it is necessary to inject fluids into the submucosal layer to lift the target lesion and keep the *muscularis propria* separated. The most commonly used solution is the 0.9% saline. However, saline dissipates quickly, which hinders the removal of lesions larger than 1cm. For these cases, viscous solutions, which promote the "bubble" effect for a prolonged period¹⁸, have been developed. The more commonly employed viscous solutions are sodium hyaluronate, glycerol and hydroxypropylmethylcellulose¹⁸. The elevation of the neoplastic lesion after infiltration of the submucosa virtually ensures that there is no invasion of the deep planes by the neoplasia. After injection of sufficient volume of solution in the submucosa, the elevated target lesion can be hooked by the diathermic handle and resected with safety margins, this procedure being called endoscopic mucosal resection, or mucosectomy.

There are variations in the described mucosectomy techniques: injection and hooking; injection, grasping and lifting of the lesions with tweezers and hooking (strip biopsy); mucosectomy with the aid of cap and suction; mucosectomy after application of elastic bands. The mucosectomy with the aid of cap is the most recommended method for application in the esophagus^{17,19}.

Results of Mucosectomy in the Esophagus

The most consistent results about the use of endoscopic mucosal resection for esophageal malignancies are derived from the Japanese experience. Inoue¹⁹ published a series of 142 patients with early esophageal cancer who underwent mucosectomy with late follow-up of nine years. When all the selection criteria were respected, there were no cases of local recurrence or metastases. The survival rate at five years was 95% and no deaths occurred due to cancer.

Endo *et al.*²⁰ reported mucosectomy results in intramucosal esophageal cancer less than 2cm and occupying less than one third of the organ circumference. The survival rate at five years was 100%, relapse occurred in 7% and was managed with local retreatment. Yoshida *et al.*²¹ found no difference between the five-year survival rates of patients with esophageal cancer with involvement of M1 and M2 treated by endoscopic mucosal resection (86%) or esophagectomy (83.2%).

The efficacy of endoscopic mucosal resection for curative treatment when all the criteria are met is well

established; there is no benefit of esophagectomy in this subgroup²¹. Nevertheless, even when certain criteria are violated, some authors have proposed alternative treatments to surgical resection. Shimizu *et al.*²² reported a series of 16 patients who underwent endoscopic mucosal resection for lesions that showed invasion of the *muscularis mucosa* and submucosa and refused to undergo esophagectomy. These patients received adjuvant chemotherapy and radiotherapy after mucosectomy. The author compared the outcomes of these patients with 39 other individuals with early SCC who underwent esophagectomy. No patient in the mucosectomy and chemoradiotherapy group had tumor recurrence or metastasis. The five-year survival of the endoscopically treated group was 100%, and of the operated patients, 87.5%. Although not a randomized, controlled study, these findings suggest that even when the criteria for curative endoscopic resection is incomplete, complementation with chemotherapy and radiotherapy appears to be an equally effective alternative to esophagectomy. Currently there is an ongoing Japanese multicenter study aiming to evaluate the therapeutic efficacy of ESD associated to adjuvant chemoradiotherapy in patients with M3 or SM1 neoplasia.

Endoscopic Submucosal Dissection

The ESD technique was developed in Japan for about ten years, in order to allow *en bloc* resection of neoplastic lesions larger than 2cm²³⁻²⁵. The main advantages of ESD are the production of adequate specimens for histological evaluation and, from the clinical standpoint, obtaining a resection site of greatest healing potential and low recurrence rates²⁶. This technique was initially designed for use in the stomach. Its employment in the esophagus occurred more slowly, because it is a more complex procedure, with more difficult technical implementation when compared to the stomach. Refinement and standardization of ESD, as well as the development of new accessories, has enabled the spread of this modality in the management of esophageal SCC. The increased detection of early stage cancer by endoscopy, together with the mortality associated with esophagectomy, constitute stimulating factors for the improvement of endoluminal therapeutic interventions that preserve the organ and the quality of life of patients. Currently, ESD is the method of choice for the treatment of early esophageal neoplasia in Japan, and this procedure has been incorporated in Brazil and in other Western countries.

Equipment and Accessories

For realization of ESD the following equipment is recommended: high-resolution endoscope with magnification for demarcation of the resection margins and specific water channel irrigation (waterjet function). A therapeutic working channel is desirable. Dual channel endoscope is not recommended; Infusion Pump with adjustable water pressure; CO2 insufflator, especially for

esophagus and colon ESD; electro-surgical unit specific for use in endoscopy. Currently the only models validated for use in ESD are the ERBE cauteries (ICC 200, VIO 200 VIO and 300), which have pulsed cut mode endocut, besides the softwares dry-cut, soft coagulation, forced coagulation, spray coagulation and swift coagulation. Every operator willing to perform ESD must deeply know electro-surgical properties and the parameters indicated for each step of the procedure.

Among the accessories used in ESD, there is a series of products developed by Japanese experts, highlighting: Knives: Flush-Knife (straight and ball-tipped), IT-Knife, Hook-Knife, Flex-Knife, Dual-Knife, Hybrid-Knife, Safe-Knife and Swan-Blade; Catheters for submucosal injection of 25 Gauge; Hemostasis: hot biopsy forceps or coagulation forceps; Disposable Endoclips for management of perforations; plastic fixation devices at the tip of endoscopes (caps), foreign body forceps with and handles with nets for retrieval of the specimens; overtube with air exhaustion control valve; solutions for submucosal injection: sodium hyaluronate 0.4%, hydroxypropyl methylcellulose 0.4%, 20% mannitol, 0.9% saline.

Techniques of Endoscopic Submucosal Dissection

Every patient should be referred to the preoperative evaluation and surgical risk, pointing out that the majority of patients with esophageal SCC are consumers of alcohol and tobacco. The treatment should be done under hospital stay. In Japan, the procedures are routinely performed under sedation. For beginners in the art, or when the estimated execution time exceeds two hours, general anesthesia with endotracheal intubation is recommended²⁷. Cardiopulmonary monitoring and pulse oximetry are mandatory in all cases, as well as use of indwelling urinary catheters in prolonged procedures. Although there is no scientific evidence to justify the use of antibiotic prophylaxis for esophagus ESD, this practice is widespread in Japanese centers. At Kobe University the intravenous use of second-generation cephalosporins for three days is recommended.

There are several technical strategies for ESD. In this review, we briefly describe the technique proposed by one of the authors (TT), developed at Kobe University and previously reported²⁸⁻³¹ (Figures 2-7).

Initially the extent of the lesion should be thoroughly inspected using endoscopes with optical magnification and digital chromoendoscopy, containing a coupled, fixed plastic device (cap) with 4mm in length at its distal end.

Then one must proceed to chromoscopy with 0.8% Iugol for accurate delineation of the limits of the lesion. In the esophagus the procedure is performed with a short, 1.5 mm-long knife with rounded tip, designed by one of the authors (TT), which allows to perform all the steps of ESD: marking, incision, submucosal dissection, simultaneous injection of saline and hemostasis of blood

vessels (Flush-knife Ball-tipped 1.5)²⁹. It is recommended to use the VIO electro-surgical unit 200D or 300D (ERBE).

Table 1 shows the electrocautery surgical parameters used for esophagus ESD at Kobe University. After chromoscopy, there is marking of the limits of resection with Flush-Knife (FK), respecting the minimum margins of 2mm to 5mm (parameters: Soft Coagulation, Effect 5, 100 Watts). The proximal and distal esophagus margins must be large (5mm) while the lateral margins may be more conservative (2mm), to minimize the risk of esophageal

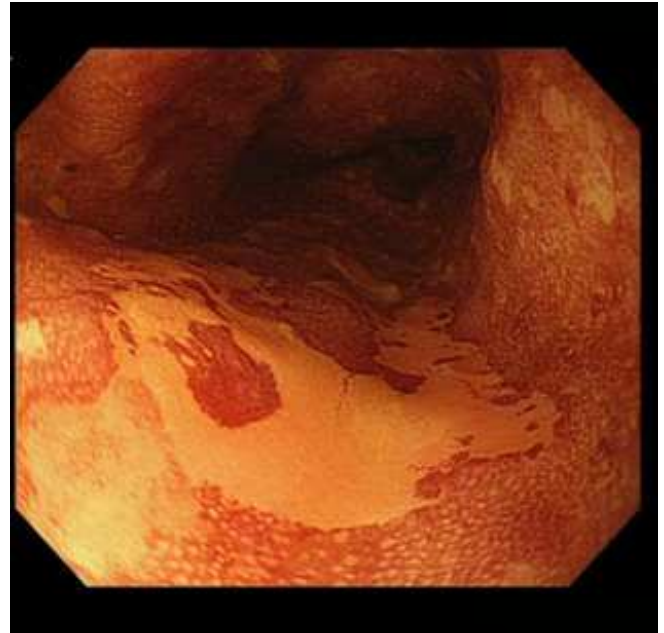

Figure 3 - Flat, lugol-negative, type 01IB esophageal lesion.

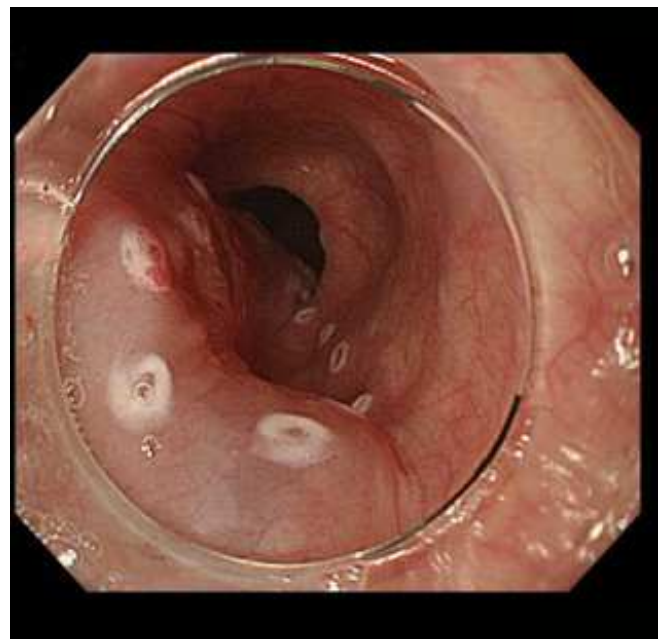


Figure 4 - Submucosal injection showing elevation of the lesion. Note the marks to delimit the site of resection.

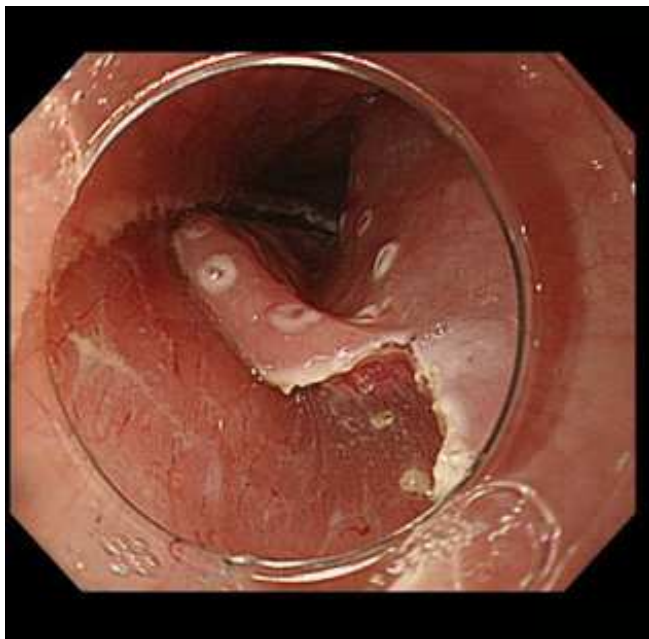


Figure 5 - Semicircular incision of the mucosa with "C" shape, with the opening of proximal, distal and left-lateral margins.

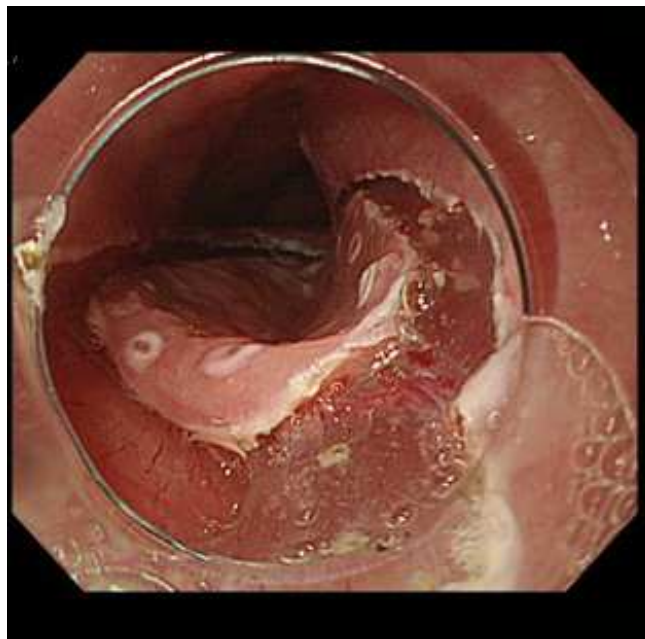


Figure 7 - Mucosal incision of the right-lateral margin.

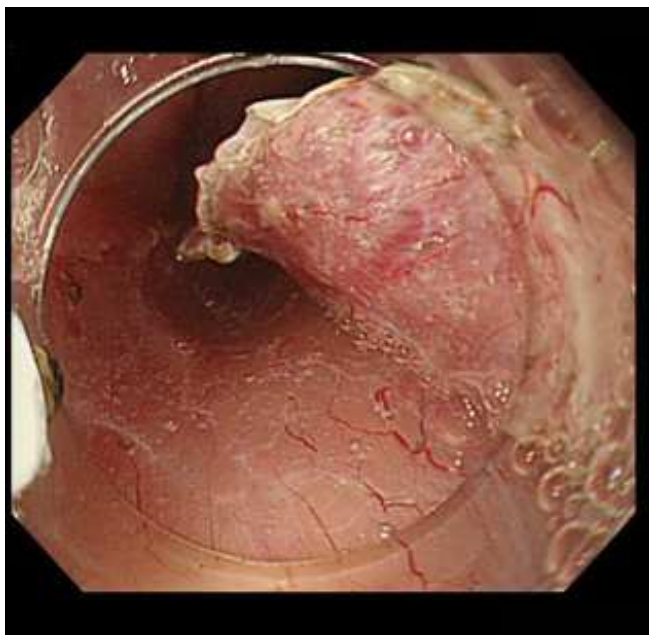


Figure 6 - Dissection of the submucosal layer in oral-anal direction, from the incision towards the center of the lesion, creating a flap.



Figure 8 - Product of endoscopic resection fixed in rubber plate for histological study. Note that the entire lesion and non-colored marks are included in the specimen. Histology confirmed a well-differentiated squamous cell carcinoma restricted to lamina propria (M2), with margins free of tumor and no vascular or lymphatic invasion.

stenosis secondary to circumferential resections. We then proceed to submucosal with 25-Gauge injection catheters.

A first submucosal bubble is made with 0.9% saline and then injected with solution of viscous sodium hyaluronate, which maintains the submucosal elevation for a longer period. The submucosal injection should be initiated at the lesion proximal (oral) margin, continuing with successive injections of 1 to 3ml along one of the lateral margins (left or right), and finally at the distal (anal) margin. A satisfactory elevation of the lesion (lifting-sign) must be observed.

One should avoid injections transfixing the center of neoplastic lesion to minimize the risk of tumor implantation in the *muscularis propria*. One proceeds to the incision of mucosa with FK (Endocut I Effect 4, cutting time 2, cutting interval 3). The incision follows the following

sequence: anal margin - transverse incision, lateral margin - longitudinal incision; oral margin - transverse incision, forming a setting "C". One the proceeds to dissect the submucosal layer with FK in the oral-anal direction (Forced Coagulation Effect 2, 40 Watts), creating a flap from the lateral incision toward the center of the lesion, always applying new injections of saline into the submucosa by the FK before the application of electrical current.

The dissection should be performed in the deep submucosal layer, between the *muscularis propria* and vascular submucosa of the esophagus, making it more efficient and optimizing vascular control. The perfect hemostasis of submucosal vessels is critical for a safe and bloodless field of view, as previously described^{30,31}. The perforating vessels of the esophagus must be identified and isolated, and hemostasis performed with FK applying Soft coagulation Effect 5, 100 watts for three to five seconds, on each side of the vessel, followed by the section of the vessel with forced coagulation. If the hemostat maneuver with FK is not effective, one must proceed with hemostasis forceps (COAG grasper, Olympus Japan Co.). After dissection of 70% to 80% of the lesion from its oral margin until the anal margin, one should proceed to submucosal injection of sodium hyaluronate in the non-approached side margin. A longitudinal incision in the mucosal side margin is then made in the oral-anal direction. The submucosal dissection is completed from the flap created beforehand using the cap to expose the submucosal space. The movement of FK should always be parallel to the axis of the esophageal wall, never perpendicular to the *muscularis propria*.

Once the resection is completed, the specimen must be recovered with foreign body forceps, taking care to capture the specimen for its submucosal aspect, in order not to damage the mucosa. The site of resection should be carefully examined, protruding vessels being coagulated by forceps and lacerations of the *muscularis propria* being mandatorily approximated by clips. If the resection site final extension represents more than 75% of the organ circumference, it is recommended a 4ml injection of triamcinolone acetonide 10mg/ml through an injection catheter, in about 20 punctures with 0.2 ml per puncture, directed both towards the edge and towards the center of the site for resection and applied gently to reach the surface of the *muscularis propria*. This measure aims to minimize the risk of esophageal stricture.

In a recently published comparative study with 41 patients with circumferential esophageal resections divided into two groups (with and without injection of triamcinolone), the treated group had 19% of esophageal stricture against 75% observed in the control group³². In Kobe, triamcinolone injections are repeated at seven and 14 days. Recently the administration of oral corticosteroids has been proposed for the prevention of esophageal stricture, with an initial dose of 30mg of prednisolone, started on the third postoperative day, and the treatment continued for eight weeks, with promising preliminary results³³.

Specimen Preparation and Recovery

This is a crucial step, often overlooked by Western endoscopists, and performed systematically by the Japanese. The recovered specimen should be extended and fixed with needles on a Styrofoam or rubber board and placed in formalin solution. The pathologist should cut the specimen in 2mm-wide parallel fragments, and evaluate it according to the Vienna Classification¹³, stating the degree of tumor differentiation, depth of invasion and the completeness of resection. The proximal, distal, lateral and vertical margins should be studied.

In surgical specimens containing the mucosa, submucosa, *muscularis propria* and adventitia, the semiquantitative analysis of the depth of submucosal invasion is reliable, as one can split the submucosa into three segments of equal thickness (SM1, SM2 and Sm3).

In specimens from endoscopic resection, the submucosa is not always complete and this distinction is less reliable. In these cases we adopt the quantitative micrometric measure in micron (l) of the submucosal invasion from the last layer of *muscularis mucosa*, establishing a cut point from which it is considered a higher risk of lymph node metastasis (SM2), which, in the esophagus, lies below 200 μ ¹².

ESD results in Esophagus Neoplasia

There are few published studies in the literature on the use of ESD in cancers of the esophagus. The summarized results of key publications are described in Table 2. Only five years after the advent of ESD in the stomach appeared the first experiences with the use of ESD in the esophagus and colon. Toyonaga et al. are among the first to report the application of ESD in esophageal tumors in 2005²⁸. The authors reported 20 patients with esophageal

Table 1 - Parameters recommended by Kobe University for esophageal endoscopic submucosal dissection using Flush-Knife Ball-Tipped on VIO electrosurgical unit (ERBE).

Marking	Soft Coag	Eff. 5, 100 W
Mucosal Incision	Endocut I	Eff. 4, Dur 2 Int 3
Submucosal Dissection	Forced Coag/Swift Coag*	Eff. 2, 40 W/Eff. 1, 100 W
Hemostasis	Soft Coag	Eff. 5, 100 W

*Use swift coag in the case of fibrosis

SCC, who underwent ESD with FK, obtaining *en bloc* resection with clear margins in 100% of cases, with an average specimen diameter of 47mm and average time of 65 minutes. In this series there was only one complication, a mediastinal emphysema, clinically managed. Fujishiro *et al.*²⁶ showed similar results in 43 patients, yielding 100% of *en bloc* resection, but in 22% of cases endoscopic resection was not curative due to compromised margins. There were four cases of perforation treated conservatively. Ishihara *et al.*³⁴ published a comparative analysis of the ESD in relation to mucosal resection in patients with esophageal cancer of less than 20mm. The rates of *en bloc* and curative resections of ESD (100% and 97%) were superior to the techniques of endoscopic mucosal resection with cap (87% and 71%) and by strip biopsy (71% and 46%). There were no differences in complications between the three groups, indicating that, when the endoscopist is sufficiently trained, the complication rate of ESD is similar to the mucosectomy's.

The first experiments with ESD for esophageal cancer in European countries³⁵ and Brazil³⁶ emerged only recently (Table 2). In our institution in Belo Horizonte, Minas Gerais State, Brazil, ESD procedures in the esophagus started in 2009, from training obtained by service members in referral centers in Asia. Until now there were 25 ESDs for esophageal cancer in the Alfa Institute of Gastroenterology, reaching rates of *en bloc* resection of

92% and curative resection of 80%, consistent with the results of the literature^{26,35,37,38}. There were two complications in this series, one patient with mediastinal and subcutaneous emphysema treated conservatively and one esophageal perforation treated by application of clips and clinical management. There were two cases of local recurrence (8%) during follow-up, which ranged from three months to three years.

FINAL CONSIDERATIONS

The ESD is a reality in Asia and considered the treatment of choice in early esophageal SCC. The experience is still insufficient to conclude whether it is feasible to apply the ESD for the treatment of superficial esophageal neoplasia in large scale in Western centers, as occurs routinely nowadays in Japan and South Korea. In Brazil and Latin America, the biggest challenge remains to promote early diagnosis of esophageal cancer by training the endoscopists and performing screening programs in high-risk patients. Additionally, it is vital to establish centers with trained and skilled human resources, supported by complete infrastructure, so that expansion of ESD may occur in these countries, with obvious benefits in quality of life and decrease in morbidity and mortality of patients with esophageal SCC.

Table 2 - Results of endoscopic submucosal dissection in superficial esophageal cancer.

Author, year (Ref.)	Number of cases	Main device	Rate of <i>en bloc</i>	Rate of resection	Acute complications
Toyonaga, 2005 (26)	20	Flush-Knife	100%	100%	EM: 5%
Fujishiro, 2006 (24)	43	Flex-Knife	100%	78%	Perf. – 6.9%
Ishihara, 2008 (32)	31	Hook-Knife	100%	97%	Perf. – 3.3%
Repici, 2010 (35)	20	Hook-Knife	90%	90%	EM – 10%
Ishi, 2010 (37)	35	Flex-Knife	100%	89%	0%
Lee, 2012 (38)	22	IT-Knife 2	97.8%	77.3%	EM – 4.5% Perf – 4.5% Hemor – 4.5%

Ref. – reference, EM – mediastinal emphysema, Perf. – perforation, Hemor – hemorrhage

R E S U M O

Nos países ocidentais, o carcinoma de células escamosas de esôfago (CCE) geralmente é detectado em estágio avançado, quando as possibilidades de cura são remotas e o prognóstico reservado. Entretanto, nos anos recentes, ocorreu uma série de avanços na abordagem do CCE de esôfago, tais como a identificação dos grupos de risco para o surgimento desta neoplasia; o uso da endoscopia de alta resolução e cromoendoscopia com lugol favorecendo o diagnóstico do CCE em estágios iniciais; e o desenvolvimento de técnicas endoscópicas de ressecção tumoral endoluminal em monobloco denominada dissecação endoscópica de submucosa. Este progresso tem possibilitado a aplicação do tratamento endoscópico minimamente invasivo com potencial curativo em pacientes selecionados com CCE superficial de esôfago. O presente artigo de revisão, elaborado por um grupo multicêntrico internacional, tem como objetivo primário contribuir para o entendimento dos principais avanços recentes ocorridos no manejo do CCE precoce de esôfago. Como objetivo secundário, pretende propiciar uma revisão detalhada e minuciosa da estratégia técnica de DES desenvolvida pelos experts japoneses, de forma a colaborar para a difusão deste conceito e a incorporação destas tecnologias na Medicina Brasileira e Latino-americana.

Descritores: Carcinoma. Carcinoma de células escamosas. Esôfago. Prognóstico. Terapêutica.

REFERENCES

- Blot WJ. Esophageal cancer trends and risk factors. *Semin Oncol*. 1994;21(4):403-10.
- Remontet L, Estève J, Bouvier AM, Grosclaude P, Launoy G, Menegoz F, et al. Cancer incidence and mortality in France over the period 1978-2000. *Rev Epidemiol Sante Publique*. 2003;51(1 Pt 1):3-30.
- Ministério da Saúde. Instituto Nacional de Câncer José Alencar Gomes da Silva (INCA). Estimativa 2012. Incidência de câncer no Brasil. Rio de Janeiro, RJ. 2011. [acessado em 2012 Fev 12]. Disponível em <http://www.inca.gov.br/estimativa/2012/index.asp?id=5>
- Yokoyama A, Ohmori T, Makuuchi H, Maruyama K, Okuyama K, Takahashi H, et al. Successful screening for early esophageal cancer in alcoholics using endoscopy and mucosa iodine staining. *Cancer*. 1995;76(6):928-34.
- Fagundes RB, de Barros SG, Pütten AC, Mello ES, Wagner M, Bassi LA, et al. Occult dysplasia is disclosed by Lugol chromoendoscopy in alcoholics at high risk for squamous cell carcinoma of the esophagus. *Endoscopy*. 1999;31(4):281-5.
- Moreira EF, Carvalho SD, Coelho JCCGP. Cromoscopia com lugol na detecção do câncer de esôfago. Projeto Diretrizes (SOBED) [online]. Rio de Janeiro, Brasil; 2008. Disponível em: http://www.sobed.org.br/web/arquivos_antigos/pdf/diretrizes/Cromoscopia.pdf
- Hirota WK, Zuckerman MJ, Adler DG, Davila RE, Egan J, Leighton JA, et al. ASGE guideline: the role of endoscopy in the surveillance of premalignant conditions of the upper GI tract. *Gastrointest Endosc*. 2006;63(4):570-80
- Dubuc J, Legoux J-, Winnock M, Seyrig J-, Barbier J-, Barrioz T, et al. Endoscopic screening for esophageal squamous-cell carcinoma in high-risk patients: a prospective study conducted in 62 French endoscopy centers. *Endoscopy*. 2006;38(7):690-5.
- Shimizu Y, Omori T, Yokoyama A, Yoshida T, Hirota J, Ono Y, et al. Endoscopic diagnosis of early squamous neoplasia of the esophagus with iodine staining: high-grade intra-epithelial neoplasia turns pink within a few minutes. *J Gastroenterol Hepatol*. 2008;23(4):546-50.
- Ishihara R, Yamada T, Iishi H, Kato M, Yamamoto S, Yamamoto S, et al. Quantitative analysis of the color change after iodine staining for diagnosing esophageal high-grade intraepithelial neoplasia and invasive cancer. *Gastrointest Endosc*. 2009;69(2):213-8.
- The Paris endoscopic classification of superficial neoplastic lesions: esophagus, stomach, and colon: November 30 to December 1, 2002. *Gastrointest Endosc*. 2003;58(6 Suppl):S3-43.
- Schlemper RJ, Riddell RH, Kato Y, Borchard F, Cooper HS, Dawsey SM, et al. The Vienna classification of gastrointestinal epithelial neoplasia. *Gut*. 2000;47(2):251-5.
- Inoue H, Fukami N, Yoshida T, Kudo SE. Endoscopic mucosal resection for esophageal and gastric cancers. *J Gastroenterol Hepatol*. 2002;17(4):382-8.
- Choi JY, Park YS, Jung HY, Ahn JY, Kim MY, Lee JH, et al. Feasibility of endoscopic resection in superficial esophageal squamous carcinoma. *Gastrointest Endosc*. 2011;73(5):881-9, 889.e1-2.
- Buskens CJ, Westertep M, Lagarde SM, Bergman JJ, ten Kate FJ, van Lanschot JJ. Prediction of appropriateness of local endoscopic treatment for high-grade dysplasia and early adenocarcinoma by EUS and histopathologic features. *Gastrointest Endosc*. 2004;60(5):703-10.
- Arantes V, Albuquerque W, Benfca E, Duarte DL, Lima D, Vilela S, et al. Submucosal injection of 0.4% hydroxypropyl methylcellulose facilitates endoscopic mucosal resection of early gastrointestinal tumors. *J Clin Gastroenterol*. 2010;44(9):615-9.
- Inoue H. Endoscopic mucosal resection for esophageal and gastric mucosal cancers. *Can J Gastroenterol*. 1998;12(5):355-9.
- Endo M, Takeshita K, Inoue H. Endoscopic mucosal resection of esophageal cancer. *Gan To Kagaku Ryoho*. 1995;22(2):192-5.
- Yoshida M, Hanashi T, Momma K, Yamada Y, Sakaki N, Koike M, et al. Endoscopic mucosal resection for radical treatment of esophageal cancer. *Gan To Kagaku Ryoho*. 1995;22(7):847-54.
- Shimizu Y, Kato M, Yamamoto J, Nakagawa S, Tsukagoshi H, Fujita M, et al. EMR combined with chemoradiotherapy: a novel treatment for superficial esophageal squamous-cell carcinoma. *Gastrointest Endosc*. 2004;59(2):199-204.
- Ono H, Kondo H, Gotoda T, Shirao K, Yamaguchi H, Saito D, et al. Endoscopic mucosal resection for treatment of early gastric cancer. *Gut*. 2001;48:225-9.
- Ohkuwa M, Hosokawa K, Boku N, Ohtu A, Tajiri H, Yoshida S. New endoscopic treatment for intramucosal gastric tumors using an insulated-tip diathermic knife. *Endoscopy*. 2001;33(3):221-6.
- Yamamoto H, Kawata H, Sunada K, Satoh K, Kaneko Y, Ido K, et al. Success rate of curative endoscopic mucosal resection with circumferential mucosal incision assisted by submucosal injection of sodium hyaluronate. *Gastrointest Endosc*. 2002;56(4):507-12.
- Fujishiro M, Yahagi N, Kakushima N, Kodashima S, Muraki Y, Ono S, et al. Endoscopic submucosal dissection of esophageal squamous cell neoplasms. *Clin Gastroenterol Hepatol*. 2006;4(6):688-94.
- Fujishiro M, Kodashima S, Goto O, Ono S, Niimi K, Yamamichi N, et al. Endoscopic submucosal dissection for esophageal squamous cell neoplasms. *Dig Endosc*. 2009;21(2):109-15.
- Toyonaga T, Nishino E, Hirooka T, Dozaiku R, Sugiyama T, Iwata Y, et al. Use of short needle knife for esophageal endoscopic submucosal dissection. *Dig Endosc*. 2005;17(3):246-52.
- Toyonaga T, Man-I M, Fujita T, Nishino E, Ono W, Morita Y, et al. The performance of a novel ball-tipped Flush knife for endoscopic submucosal dissection: a case-control study. *Aliment Pharmacol Ther*. 2010;32(7):908-15.
- Toyonaga T, Nishino E, Hirooka T, Ueda C, Noda K. Intraoperative bleeding in endoscopic submucosal dissection in the stomach and strategy for prevention and treatment. *Dig Endosc*. 2006;18(Suppl s1):S123-7.
- Toyonaga T, Nishino E, Dozaiku T, Ueda C, Hirooka T. Management to prevent bleeding during endoscopic submucosal dissection using the flush knife for gastric tumors. *Dig Endosc*. 2007;19(Suppl s1):S14-8.
- Hashimoto S, Kobayashi M, Takeuchi M, Sato Y, Narisawa R, Aoyagi Y. The efficacy of endoscopic triamcinolone injection for the prevention of esophageal stricture after endoscopic submucosal dissection. *Gastrointest Endosc*. 2011;74(6):1389-93.
- Isomoto H, Yamaguchi N, Nakayama T, Hayashi T, Nishiyama H, Ohnita K, et al. Management of esophageal stricture after complete circular endoscopic submucosal dissection for superficial esophageal squamous cell carcinoma. *BMC Gastroenterol*. 2011;11:46.
- Ishihara R, Iishi H, Uedo N, Takeuchi Y, Yamamoto S, Yamada T, et al. Comparison of EMR and endoscopic submucosal dissection for en bloc resection of early esophageal cancers in Japan. *Gastrointest Endosc*. 2008;68(6):1066-72.
- Repici A, Hassan C, Carlino A, Pagano N, Zullo A, Rando G, et al. Endoscopic submucosal dissection in patients with early esophageal squamous cell carcinoma: results from a prospective Western series. *Gastrointest Endosc*. 2010;71(4):715-21.
- Chaves DM, Maluf Filho F, de Moura EG, Santos ME, Arrais LR, Kawaguti F, et al. Endoscopic submucosal dissection for the treatment of early esophageal and gastric cancer—initial experience of a western center. *Clinics (Sao Paulo)*. 2010;65(4):377-82.
- Ishii N, Horiki N, Itoh T, Uemura M, Maryama M, Suzuki S, et al. Endoscopic submucosal dissection with a combination of small-caliber-tip transparent hood and flex knife is a safe and effective treatment for superficial esophageal neoplasias. *Surg Endosc*. 2010;24(2):335-42.
- Lee CT, Chang CY, Tai CM, Wang WL, Tseng CH, Hwang JC, et al. Endoscopic submucosal dissection for early esophageal neoplasia: a single center experience in South Taiwan. *J Formos Med Assoc*. 2012;111(3):132-9.

Received on 06/04/2012

Accepted for publication 20/06/2012

Conflict of interest: none

Source of funding: no

How to cite this article:

Arantes V, Piñeros EAF, Yoshimura K, Toyonaga T. Avanços na abordagem do carcinoma precoce de esôfago. Rev Col Bras Cir. [periódi-

co na Internet] 2012; 39(6). Disponível em URL: <http://www.scielo.br/rcbc>

Address for correspondence:

Vitor Arantes

E-mail: arantesvitor@hotmail.com