

# Negative pressure wound therapy in complex trauma of perineum

## *Terapia por pressão negativa na ferida traumática complexa do períneo*

DIMAS ANDRÉ MILCHESKI<sup>1</sup>; FELIPE MUNIZ DE CASTRO ZAMPIERI<sup>2</sup>; HUGO ALBERTO NAKAMOTO<sup>1</sup>; PAULO TUMA JÚNIOR<sup>1</sup>; MARCUS CASTRO FERREIRA, ECBC-SP<sup>3</sup>

### A B S T R A C T

**Objective:** To review the experience (2011 and 2012) of Wound Center of Plastic Surgery Service, Clinics Hospital, Faculty of Medicine, University of São Paulo, with treatment of complex traumatic wounds in the perineal region with the association of negative pressure wound therapy followed by a surgical skin coverage procedure. **Methods:** This was retrospective analysis of ten patients with complex wound in the perineum resulting from trauma assisted by the Department of Plastic Surgery in HC-USP. Negative pressure was used as an alternative for improving local conditions, seeking definitive treatment with skin grafts or flaps. **Results:** Negative pressure was used to prepare the wound bed. In patients, the mean time of use of negative pressure system was 25.9 days, with dressing changes every 4.6 days. After negative pressure therapy, 11 local flaps were performed in nine patients, with fasciocutaneous anterolateral thigh flap used in four of these. Mean hospital stay was 58.2 days and accompaniment in Plastic Surgery was 40.5 days. **Conclusion:** The use of negative pressure therapy led to improvement of local wound conditions faster than traditional dressings, without significant complications, proving to be the current best alternative as an adjunct for the treatment of this type of injury, always followed by surgical reconstruction with grafts and flaps.

**Key words:** Wounds and injuries. Wounds and injuries/surgery. Wound closure techniques. Surgery, plastic. Perineum/surgery.

### INTRODUCTION

The presence of a wound is the break in continuity of the cutaneous tegument, with disruption of normal dermal structures and functions<sup>1</sup>. It can be simple when closing just by biological healing, or complex when not. In 2006, Ferreira *et al.* proposed criteria for defining the complex wound<sup>2</sup>. These wounds' resolution present a challenge to the plastic surgeon, as they have characteristics that prevent biological healing and require expert surgical treatment, such as coverage with skin grafts or flaps, whether local or distant.

Trauma is the leading cause of preventable death, primarily affecting economically active adults and causing major social impact. The lesions in soft tissues have varying severity, and when severe, require specialized treatment that keeps patients hospitalized for prolonged periods<sup>3</sup>.

The perineum is the area of the opening of the lower pelvic ring, limited by the projection of the pubic

symphysis, the branches of the pubis and ischium, ischial tuberosities, sacro-tuberal ligaments and coccyx. A line drawn between the projections of the ischial tuberosities divides the perineum into anterior (or urogenital triangle) and posterior (or anorectal triangle). In the anterior perineum there are urogenital structures (penis, testicles and the urethra in men and the urethra and external genitals in women). In the posterior perineum there are the anorectal structures (anus, internal and external anal sphincters and rectum) and their skin coverings.

Perineal trauma is often present as wounds of greater complexity. Complex perineal wounds are considered those with extensive tissue loss, deep wounds with exposure of specialized structures (bone, urethra, testicles) or presence of necrosis and important local infection (as occurs, for example, in Fournier's necrotizing fasciitis).

The pathophysiology of these losses in substance explains why conventional treatment (dressings and wound care) renders no appropriate closing in reasonable time, which may cause important sequelae. Surgical treatment

Study conducted at the Clinics Hospital of the Faculty of Medicine, University of São Paulo –USP, São Paulo City, São Paulo State – SP, Brazil.

1. Assistant Physician, Discipline of Plastic Surgery, Faculty of Medicine, USP; 2. Resident Physician in the Discipline of Plastic Surgery, Faculty of Medicine, USP; 3. Professor, Discipline of Plastic Surgery, Faculty of Medicine, USP.

by a plastic surgeon allows a proper resolution, but there is still need to promptly prepare the affected areas for surgery. The subatmospheric pressure therapy has been used already for two decades in the treatment of complex lesions as a resource for improving the condition of the wound bed, allowing surgical reconstruction of the wound in less time <sup>4,5</sup>.

The reconstruction of the perineal region aims to restore function, for which is necessary the adequate coverage, the most similar to the original anatomy as possible <sup>6</sup>. Among the options for repair are the primary closure, skin grafts<sup>7</sup>, local flaps and distant flaps. Among the most used locoregional flaps in this region are the anterolateral fasciocutaneous of the thigh and tensor fascia lata and musculocutaneous of the gluteus maximus <sup>8</sup>, gracile <sup>9</sup> and rectus abdominis <sup>10</sup>.

We present the experience of the Wound Center of the Plastic Surgery Service, Clinics Hospital, Faculty of Medicine, University of São Paulo (HC - USP) for the last two years in the treatment of complex perineal traumatic wounds, by association of negative pressure wound therapy followed by surgical procedure to restore skin coverage.

## METHODS

We conducted a retrospective analysis of medical records of patients with complex wounds caused by trauma to the perineum treated between January 2011 to December 2012 in the Department of Plastic Surgery (HC - USP).

We considered complex traumatic wounds of the perineum the ones that presented with extensive losses of perineal cutaneous coverage in association with one or more of the following findings: fractures in the pelvis, bone exposure, injury to the urethra, and anorectal or genital lesions (penile or vaginal injury, or exposure of testis).

Ten patients in these conditions required treatment by the Wound Center of the Plastic Surgery Service, HCFMUSP, the referral made by the team of Trauma Surgery of the ER-HC. Were computed data on the cause of trauma, on the association with other lesions in other tissues besides the skin tegument, the use of negative pressure therapy, the method of cutaneous reconstruction and duration of hospitalization. All patients were treated according to the protocol of care for complex perineal trauma (Figure 1).

The negative pressure therapy, popularly known as the vacuum system, comprises the use of a sponge of polyurethane applied on the wound connected to a pump (vacuum) generating sub-atmospheric pressure, continuously or intermittently (VAC- KCI®, San Antonio, Texas, USA). The pressure is generally set at 125 mmHg and is distributed uniformly over the entire wound through the pores of the sponge. A plastic adhesive is applied to the sponge to allow the sealing of the wound.

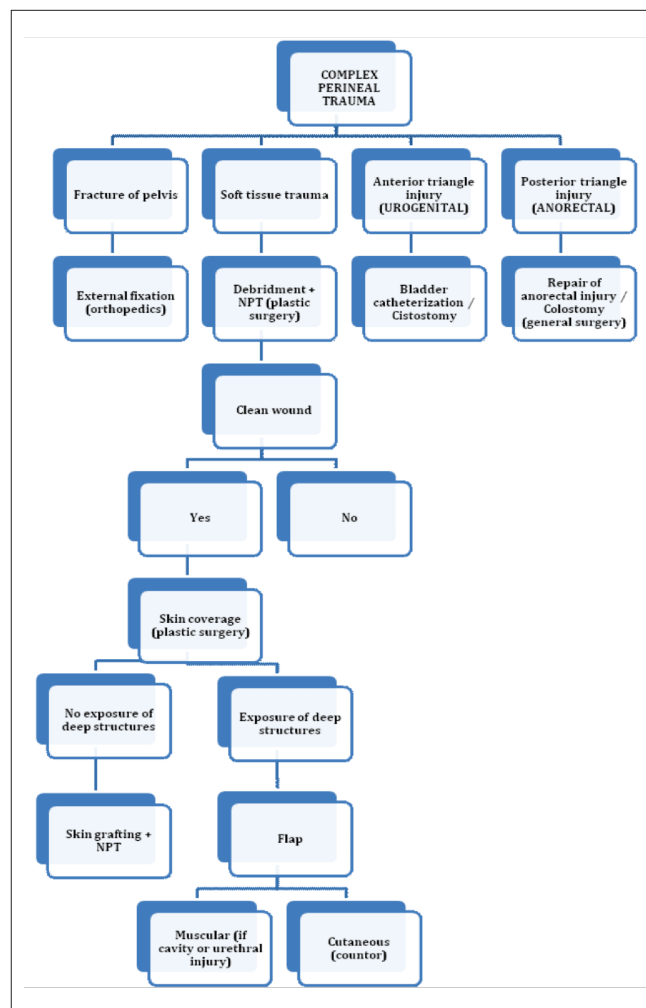


Figure 1 - Protocol of attendance of complex perineal trauma HC-FMUSP.

NPT: negative pressure therapy.

## RESULTS

All patients were male and the age ranged between 17 and 68 years (mean 34.7). The data obtained from patients with complex cutaneous perineal wounds are summarized in table 1. In all patients wound was resolved, achieving stable skin coverage.

The most frequent cause of pelvic trauma was motorcycle accident (4 cases). All patients had associated trauma in the pelvic region: orthopedic, urological or anorectal (Table 1).

The average use of negative pressure system was 25.9 days. Dressing changes were performed every 4.6 days. After use of negative pressure therapy, 11 local flaps were made in nine patients, the fasciocutaneous anterolateral thigh flap being used in four of these patients (Figures 1 and 2, A, B, C, D).

The mean hospital stay was 58.2 days and accompaniment in the Plastic Surgery clinic was 40.5 days.

## DISCUSSION

In accordance with the literature, in which males are more affected by trauma, all patients in this sample were men. The mean age was 34.7 years, and only one of them had more than 60 years, reflecting the trauma reach of more young patients. The mean hospital stay was 58.2 days, related both to the complexity of the lesions and to the associated injuries. The follow-up of patients, considered from the moment we began monitoring the patient until wound healing, was 40.5 days. Although we have no comparative data, previous experience without the participation of the Plastic Surgery Service showed longer treatment and more severe sequelae. There were no deaths in this series.

The presence of extensive tissue loss and lack of appropriate conditions in the wound bed to allow its permanent closure demanded the use of negative pressure therapy to improve local conditions and preparation of the wound bed prior to the final coverage. The subatmospheric pressure therapy reduces tissue edema and assists in controlling bacterial colonization and in the visualization of any devitalized tissue, facilitating the achievement of a clean wound. Before the advent of vacuum therapy, there was use of dressings that had to be changed quite often, requiring more time and being uncomfortable to patients.

The negative pressure was used to prepare the wound bed only as a bridge to definitive treatment and should not be used alone. The number of dressing changes was determined by the medical staff, according to the assessment of local conditions, but in general a sponge

can remain in contact with the wound bed for up to seven days, the change being held between three and seven days. In the attended patients, the mean time of use of the negative pressure system was 25.9 days, with changes every 4.6 days on average.

We know that among the advantages of this type of therapy are: the reduction of local edema, maintenance of a moist environment and free of debris, increase of local blood vasculature and decreased bacterial colonization<sup>11-13</sup>. It is a comfortable material for the patient, which decreases wound pain between dressing changes. There is currently no other therapy to properly prepare the wound bed in a short time for the subsequent coverage with grafts and flaps.

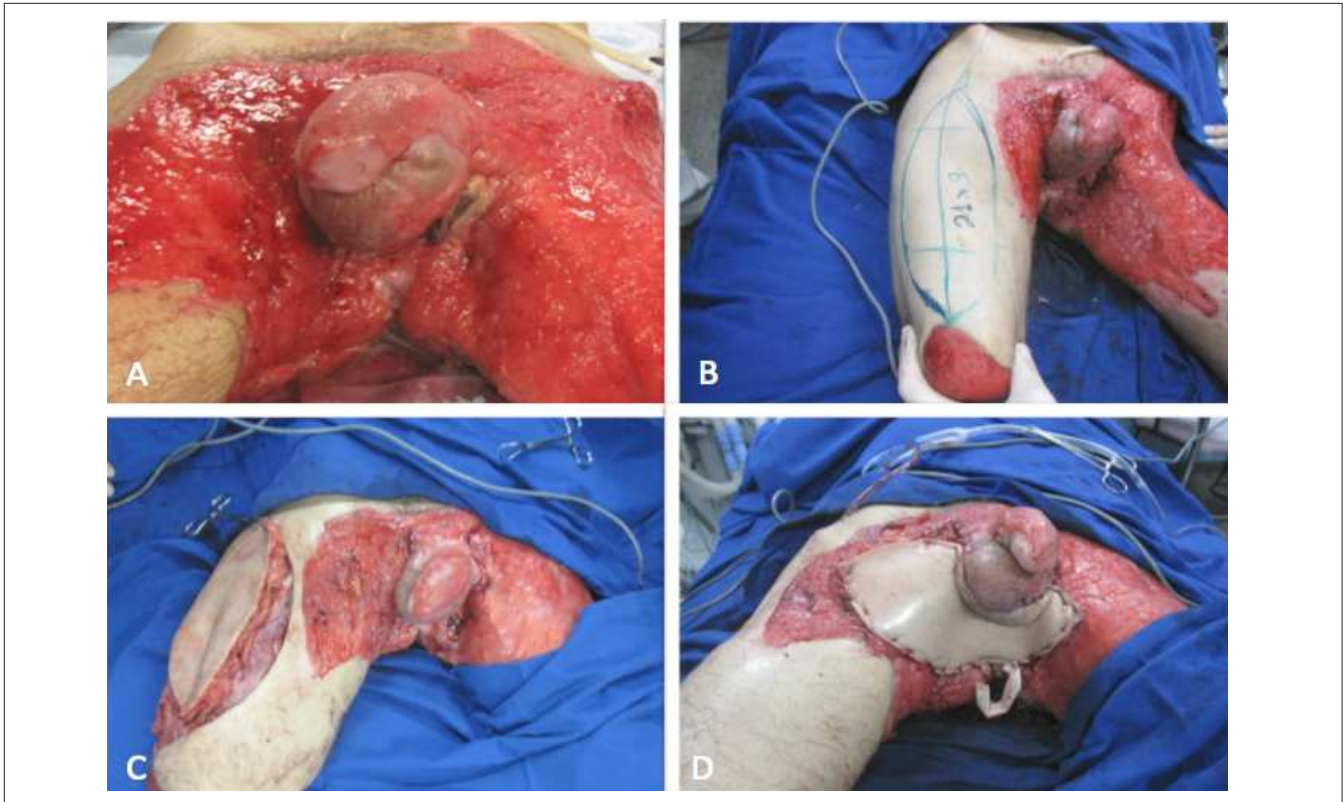
After negative pressure therapy, 11 local flaps were performed in nine patients, the fasciocutaneous anterolateral thigh flap being used in four of these patients. This flap has the advantage of proximity to the wound, has a long vascular pedicle, allows rotation to the area of skin defect, provides significant amount of tissue and is easy and safe to dissect. If necessary, the skin flap can be transferred with a segment of the vastus lateralis muscle to fill the cavity and closure of any subsequent urethral fistulae. The donor area of the flap can be closed directly, but sometimes it requires skin grafts.

The other flaps performed were fasciocutaneous medial thigh (three cases), myocutaneous gracilis muscle (two cases), the myocutaneous rectus (one case) and fasciocutaneous tensor fascia lata (one case) flaps. The choice of a particular flap for covering the skin defect depends on the geometry of the defect, the proximity of

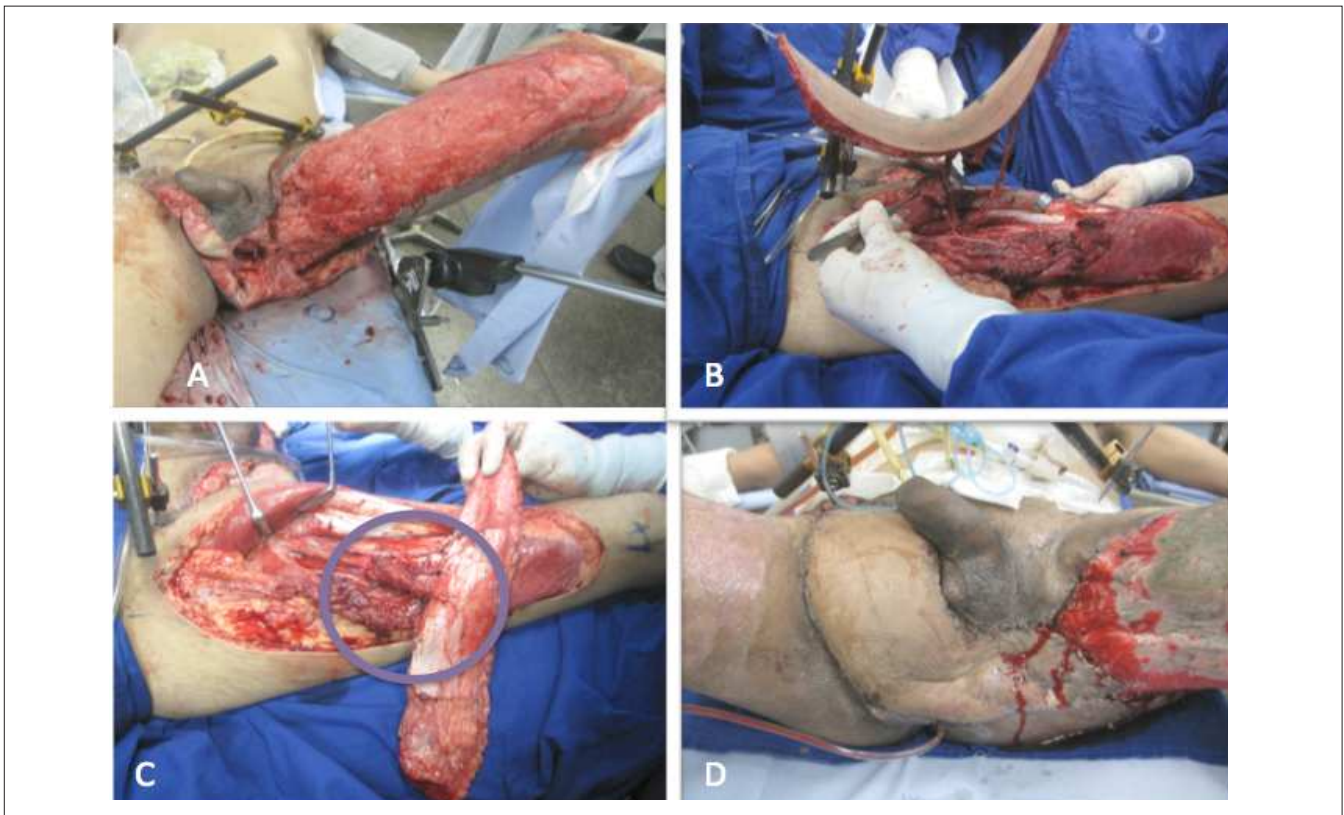
**Table 1** - Results of the cases presented.

Case	Cause	Associated Injuries	NPT (Days)	NPT (Changes)	Reconstruction	Treatment PS (Days)	Admission (Days)
1	Motorcycle accident	Fracture of pelvis. urethral injury	63	10	ALT e and gracile muscle flaps + skin grafting	14	63
2	Motorcycle accident	Fracture of pelvis. urethral injury	20	4	ALT flap + skin grafting	50	70
3	Electric Shock	Exposed bone (ischium)	15	3	ALT flap + skin grafting	93	107
4	Tramplng	Fracture of pelvis	28	4	TFL flap+ skin grafting	34	65
5	Motorcycle accident	Exposure of testicles	5	1	Medial thigh FC flap	68	75
6	Automobile accident	Fracture of pelvis	7	2	Medial thigh FC flap	18	30
7	Burying	Anorectal injury. fracture of pelvis	29	6	Medial thigh FC flap	36	41
8	Motorcycle accident	Fracture of pelvis. amputation of LLL	23	4	MC graçcile muscle flap + skin grafting	10	36
9	Bicycle accident	Fracture of pelvis	49	8	VRAM flap + skin grafting	57	60
10	Burying	Fracture of pelvis and spine fracture	20	4	ALT flap	25	35
<b>MEAN</b>	-	-	25.9	4.6		40.5	58.2

NPT: negative pressure therapy. PS: Plastic Surgery. MC: musculocutaneous. FC: fasciocutaneous. NPT: negative pressure therapy. ALT: anterolateral thigh flap. TFL: tensor fascia lata flap. VRAM: vertical rectus abdominis myocutaneous flap; LLL: Left lower limb.



**Figure 2** - Electric trauma. A) clean wound after three debridements + VAC; B) marking of the fasciocutaneous anterolateral thigh flap; C) Dissection of the flap, D) postoperative result (seventh postoperative day).



**Figure 3** - Complex perineal trauma. A) clean wound after four debridements VAC +; B) Dissection of fasciocutaneous flap anterolateral thigh; C) muscle segment for urethral fistula closure; D) postoperative result (14<sup>th</sup> postoperative day).

the flap in relation to the wound, the characteristics of the flap (or skin and muscle pedicle size) and experience of the surgeon.

The wounds of the perineum usually extend to other regions, mainly the lower limbs (thighs) and back, requiring skin coverage of large areas. As there is usually no exposure of deep structures in the thigh and back, the best option is the skin grafts in association with the flap used for the perineal wound. Skin grafts were used in six patients in this sample.

The Wound Center of the Plastic Surgery Service HCFMUSP currently attends complex perineum trauma patients through a treatment protocol developed in order to optimize and rationalize surgical treatment

(Figure 3). Although traditionally Plastic Surgery was not part of the team that receives the trauma patients in the emergency room, in the HC-USP, an expert team has been on duty since 2006 to allow assessment as early as possible.

Trauma to the perineum is a serious and difficult to solve condition for the medical staff that mostly affects young adults. It demands long hospitalization time, regardless of the type of skin coverage, as in general it is associated with complications and other serious injuries. The use of negative pressure therapy improved local wound conditions quickly, proving to be an adjuvant suitable for treating this type of injury, with earlier closure and less severe sequelae.

## R E S U M O

**Objetivo:** rever a experiência (2011 e 2012) do Centro de Feridas da Cirurgia Plástica do Hospital das Clínicas da Faculdade de Medicina da Universidade de São Paulo com tratamento de feridas traumáticas complexas na região perineal, pela associação da terapia com pressão negativa seguida de procedimento cirúrgico para cobertura cutânea. **Métodos:** análise retrospectiva de dez pacientes com ferida complexa no perineo consequente a traumatismo atendidas pelo Serviço de Cirurgia Plástica no HC-FMUSP. A terapia por pressão negativa foi utilizada como alternativa para melhoria das condições locais visando o tratamento definitivo com enxertos de pele ou retalhos. **Resultados:** a terapia por pressão negativa foi empregada para o preparo do leito da ferida. Nos pacientes atendidos, o tempo médio de utilização do sistema de pressão negativa foi 25,9 dias, com trocas de curativos a cada 4,6 dias. Após a terapia por pressão negativa, foram realizados 11 retalhos locais em nove pacientes, com o retalho fásquio-cutâneo antero-lateral da coxa utilizado em quatro destes pacientes. O tempo médio de internação hospitalar foi 58,2 dias e de acompanhamento no Serviço de Cirurgia Plástica foi 40,5 dias. **Conclusão:** a utilização da terapia por pressão negativa levou à melhoria das condições locais da ferida mais rapidamente do que curativos tradicionais, sem complicações significativas, demonstrando ser a melhor alternativa adjuvante atualmente para o tratamento deste tipo de lesão, seguida sempre por reconstrução cirúrgica com enxertos e retalhos.

**Descritores:** Ferimentos e lesões. Ferimentos e lesões/cirurgia. Técnicas de fechamento de ferimentos. Cirurgia plástica. Perineo/cirurgia.

## REFERENCES

- Rippon M, Davies P, White R. Taking the trauma out of wound care: the importance of undisturbed healing. *J Wound Care*. 2012;21(8):359-60.
- Ferreira MC, Tuma P Jr, Carvalho VF, Kamamoto F. Complex wounds. *Clinics*. 2006;61(6):571-8.
- Coltro PS, Ferreira MC, Batista BPSN, Nakamoto HA, Milcheski DA, Tuma Júnior P. Atuação da Cirurgia Plástica no tratamento de feridas complexas. *Rev Col bras Cir*. 2011;38(6):381-6.
- Ferreira MC, Carvalho VF, Kamamoto F, Tuma Júnior P, Paggiaro AO. Negative pressure therapy (vacuum) for wound bed preparation among diabetic patients: case series. *Sao Paulo Med J*. 2009;127(3):166-70.
- Barreiro GC, Millan LS, Nakamoto H, Montag E, Tuma Júnior P, Ferreira MC. Reconstruções pelveperineais com uso de retalhos cutâneos baseados em vasos perfurantes: experiência clínica com 22 casos. *Rev bras cir plást*. 2011;26(4):680-4.
- Hollenbeck ST, Toranto JD, Taylor BJ, Ho TQ, Zenn MR, Erdmann D, et al. Perineal and lower extremity reconstruction. *Plast Reconstr Surg*. 2011;128(5):551e-63e.
- Zhao JC, Xian CJ, Yu JA, Shi K. Reconstruction of infected and denuded scrotum and penis by combined application of negative pressure wound therapy and split-thickness skin grafting. *Int Wound J*. 2012; Jun 4. [Epub].
- Schmidt VJ, Horch RE, Dragu A, Weber K, Göhl J, Mehlhorn G, et al. Perineal and vaginal wall reconstruction using a combined inferior gluteal and pudendal artery perforator flap: a case report. *J Plast Reconstr Aesthet Surg*. 2012;65(12):1734-7.
- Hamvas B, Mucs M, Varga I, Szilágyi A, Altorjay A. Reconstruction of large tissue loss of the anus and perineum with bilateral inferior gluteal and right gracilis myocutaneous flaps. *Magy Seb*. 2011;64(5):249-53.
- McMenamin DM, Clements D, Edwards TJ, Fitton AR, Douie WJ. Rectus abdominis myocutaneous flaps for perineal reconstruction: modifications to the technique based on a large single-center experience. *Ann R Coll Surg Engl*. 2011;93(5):375-81.
- Morykwas MJ, Argenta LC, Shelton-Brown EI, McGuirt W. Vacuum-assisted closure: a new method for wound control and treatment: animal studies and basic foundation. *Ann Plast Surg*. 1997;38(6):553-62.
- Argenta LC, Morykwas MJ. Vacuum-assisted closure: a new method for wound control and treatment: clinical experience. *Ann Plast Surg*. 1997;38(6):563-76.

13. Mouës CM, van Toorenenbergen AW, Heule F, Hop WC, Hovius SE. The role of topical negative pressure in wound repair: expression of biochemical markers in wound fluid during wound healing. *Wound Repair Regen.* 2008;16(4):488-94.

Received on 10/08/2012

Accepted for publication 15/10/2012

Conflict of interest: none

Source of funding: none

**Como citar este artigo:**

Milcheski DA, Zampieri FMC, Nakamoto HA, Tuma Júnior P, Ferreira MC. Negative pressure therapy for perineal complex trauma wound. *Rev Col Bras Cir.* [periódico na Internet] 2013;40(4). Disponível em URL: <http://www.scielo.br/rcbc>

**Address correspondence to:**

Dimas André Milcheski

E-mail: [drdimasandre@gmail.com](mailto:drdimasandre@gmail.com)