

New technique for dynamic closure of the abdominal wall

Nova técnica para o fechamento dinâmico da parede abdominal

FABIO KAMAMOTO¹; BERNARDO NOGUEIRA BATISTA²; FLAVIO TOKESHI³

A B S T R A C T

Advances in care of trauma patients and severe abdominal infections are responsible for an increasing number of laparostomies. The management of this entity is complex and several techniques have been described for its treatment. Recently the concept of dynamic closure of the abdominal wall was introduced in the literature with high success rates. The objective of this report is to serve as a foreword for a new approach for the treatment of laparostomy developed at the University Hospital of the University of São Paulo. This is a simple and low cost method, easily performed by a general surgeon. The procedure was also used prophylactically as reinforcement in tight abdominal closures. It is described in detail as well as the results in the first patients. Although promising, refinements and further studies are needed to validate the technique.

Key words: Laparostomy. Abdominal hernia. Abdominal compartment syndrome.

INTRODUCTION

Advances in the treatment of abdominal compartment syndrome as well as the techniques of damage control have contributed to significant gains in survival of patients victims of trauma and severe abdominal infections¹⁻³. They created, however, a difficult management problem: by reducing the mortality of these patients, laparostomy appears as increasingly frequent, and its appropriate closure is a challenge for surgeons. We present a new proposal for the management of this entity developed at the University Hospital of the University of São Paulo, São Paulo, Brazil.

METHODS

The technique is aimed at primary closure of the abdominal cavity, covering all layers of the abdominal wall. For that it begins by isolating the abdominal contents through the suture of a protective film (open bag of saline) to the healthy parietal peritoneum. Following this, punctures are made bilaterally, along the wound's longitudinal axis, transfixing all layers of the abdominal wall. We adopt the distances of 2.5 cm between the holes and approximately 4 cm from the edge of the wound. We then pass a 14F NELATON catheter through each pair of holes (to the right and to the left of the wound), connecting its two edges, in

a "U" fashion, so that each catheter stays perpendicular to the wound axis and its extremities come out of the skin. The catheters' ends are fixed with plastic clamps, applying some tension to the wound (Figure 1).

Six patients underwent abdominal wall closure using the described technique. In four the primary closure of the abdominal cavity was possible, with big tension on the suture line. We then decided to apply the technique to prevent complications by distributing the tension across the wall thickness and around the wound's craniocaudal axis. The other two patients had already been submitted to laparostomy resulting from a complication of previous laparotomies. In these cases, every two or three days the catheters were tensioned and the clamps repositioned until proper tension was reached or the patient referred pain (whichever occurred first). The procedure was repeated until proper rapprochement of the wound was achieved, this way aiming for the dynamic closure of the defect. After about three weeks we carried out the final tension-free closing of the wall and retrieved the catheters.

RESULTS

In the four patients who underwent primary closure with the application of the technique as prophylaxis of dehiscence there were no complications in the surgical

Work done at the University Hospital of the University of São Paulo – São Paulo – Brazil.

1. M.D., Surgery Department, University Hospital, University of São Paulo, São Paulo, Brazil; 2. Resident, Plastic Surgery, Hospital das Clínicas, University of São Paulo Medical School, São Paulo, Brazil; 3. M.D., Surgery Department, University Hospital, University of São Paulo, São Paulo, Brazil.

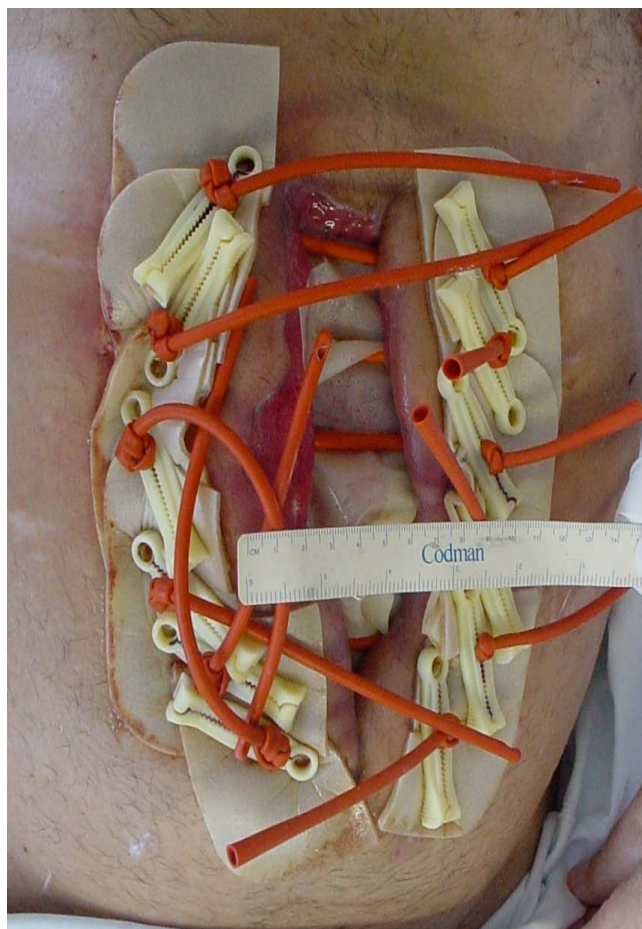


Figure 1 - Photo showing the appearance of the final procedure in which 14F NELATON catheters are passed through punctures in the abdominal wall, allowing the distribution of tensile strength throughout the wound.

wound. In both cases in which we sought closure of an open abdomen, it was successfully achieved in one patient. The other patient presented with rupture of the wall at the insertion points of three of the six catheters installed due to excessive tension applied postoperatively.

DISCUSSION

The technique of dynamic closure appears to be a promising tool in closing the abdominal wall after laparostomy, as well as effective prophylaxis in sutures that have apply tension in the abdominal wall.

Usually, when faced with a tense suture, the general surgeon makes use of stiches with an unabsorbable, thick, suture in total plan. Although data have not been measured objectively, it was observed that patients undergoing the described procedure reported less pain after surgery, with more effective drug therapy.

With regard to the definitive treatment of laparostomy, this technique allows complete closure of the abdominal wall, covering all of its plans, restoring its normal anatomy and all the functions of containment and resistance of the muscle wall, without generating new morbidity factors for the patient, facts that make it superior to the techniques of closure with autologous, xenologous or synthetic substitutes (meshes and flaps)⁴. Other studies in the literature reinforce the idea that the progressive (dynamic) closure techniques of the abdominal wall are effective in obtaining a continent abdominal wall^{1,5}.

RESUMO

Os avanços nos cuidados com o paciente traumatizado e com infecções abdominais graves são responsáveis por um número crescente de peritoneostomias. O manejo desta entidade é complexo e várias técnicas foram descritas para seu tratamento. Recentemente foi introduzido na literatura o conceito de fechamento dinâmico da parede abdominal, com elevadas taxas de sucesso. O objetivo deste trabalho é de servir como nota prévia de uma nova abordagem para o tratamento das peritoneostomias, desenvolvida no Hospital Universitário da Universidade de São Paulo. Trata-se de um procedimento simples e de baixo custo, facilmente realizado por cirurgião geral. O procedimento também foi utilizado como reforço em fechamentos abdominais tensos, de maneira profilática. O procedimento é descrito em detalhes, assim como os resultados nos primeiros pacientes. Apesar de promissora, refinamentos técnicos e estudos complementares são necessários para a validação da técnica.

Descritores: Peritoneostomia. Hernia abdominal. Síndrome compartimental abdominal.

REFERENCES

1. Cothren CC, Moore EE, Johnson JL, et al. One hundred percent fascial approximation with sequential abdominal closure of the open abdomen. *Am J Surg* 2006; 192: 238-242.
2. Costa A. Making a virtue of necessity: managing the open abdomen. *Anz J Surg* 2006; 76: 356-363.
3. Hultman CS, Pratt B, Cairns BA, et al. Multidisciplinary Approach to Abdominal Wall Reconstruction After Decompressive Laparotomy for Abdominal Compartment Syndrome. *Ann Plast Surg* 2005; 54 (3): 269-275.
4. Management of the Patient with an Open Abdomen: Techniques in Temporary and Definitive Closure. *Curr Probl Surg* 2004; 41: 821-876.

5. Jernigan TW, Fabian TC, Croce MA, et al. Staged Management of Giant Abdominal Wall Defects Acute and Long-Term Results. *Ann Surg* 2003; 238: 349-357.

Received in 20/05/2010

Accepted for publication in 20/07/2010

Conflict of interest: none

Source of funding: none

How to cite this article:

Kamamoto F, Batista BN, Tokeshi F. New technique for dynamic closure of the abdominal wall. *Rev Col Bras Cir.* [periódico na Internet] 2010; 37(5). Disponível em URL: <http://www.scielo.br/rcbc>

Correspondence address:

Bernardo Nogueira Batista

E-mail: bernardonb@uol.com.br