

Expanding indications and results for the use of resuscitative endovascular balloon occlusion of the aorta - REBOA.

Indicações e resultados para o uso expandido da oclusão ressuscitativa por balão endovascular da aorta - REBOA.

MARCELO AUGUSTO FONTENELLE RIBEIRO JÚNIOR^{1,2}; ANDRESSA DANIEL MAURÍCIO³; CASSIA TIENI KAWASE COSTA³; PAOLA REZENDE NÉDER³; SAMARA DE SOUZA AUGUSTO³; SALOMONE DI-SAVERIO⁴; MEGAN BRENNER⁵

ABSTRACT

Currently, resuscitative endovascular balloon occlusion of the aorta (REBOA) is used in trauma surgery for controlling non-compressible torso hemorrhages, as a less invasive option and with fewer physiologic disturbances compared with an invasive emergent thoracotomy for aortic cross-clamping. This can allow improvements in hemodynamic parameters until definitive surgery is performed. REBOA is also used in trauma to prevent hemodynamic collapse in patients who are in severe hemorrhagic shock, as a method to maintain perfusion of the brain and heart while decreasing distal bleeding until hemorrhage control can take place. The major complications reported are acute kidney injury, lower leg amputations, and even death. As experience with REBOA in emergency surgery grows, new indications have been described in the literature. The aim of this study was to assess the expansion of the use of REBOA in other areas of medicine, as well as evaluating the current published series. We performed an online search of PubMed, Medline and SciELO with the term "REBOA" in the last five years, and the articles included were the 14 specifically describing the use of REBOA for non-traumatic conditions. The results suggest that the use of REBOA led to improved bleeding control and increased arterial pressure, reducing blood transfusion requirements and allowing patients to survive to definitive treatment of injuries. In conclusion, the expanded use of REBOA for non-traumatic emergencies appears to be effective. However, prospective studies and well-established protocols for specific indications should be developed to maximize patient outcomes.

Keywords: Hemorrhage. Hypovolemia. Gastrointestinal Hemorrhage. Postpartum Hemorrhage. Minimally Invasive Surgical Procedures.

INTRODUCTION

The use of Resuscitative Endovascular Balloon Occlusion of the Aorta (REBOA) was first described by Hughes, during the Korean war, in 1954, with the aim of controlling traumatic hemorrhage¹. Case series and studies from the following decades described its use for non-traumatic hemorrhage, as well as the development and implementation of aortic balloon occlusion for temporization of hemorrhage in ruptured abdominal aortic aneurism (AAA)²⁻⁴. The conflicts in Iraq and Afghanistan increased interest in the development of endovascular approaches for hemorrhage control, considering that non-compressible bleeding is responsible for high

rates of mortality in torso injuries. Since that time, the use of the procedure has increased in civilian settings for traumatic hemorrhage⁵⁻⁷. The results obtained with the use of the balloon stimulated the development of training models for trauma surgeons in collaboration with military surgeons, which allowed the development of growing experience in the use of REBOA and increasing availability of preliminary outcomes. With the renewed interest in the use of REBOA for trauma management, newer catheters were developed that reduced the number of steps and devices needed for aortic occlusion. This, along with standardization of the technique and training platforms, helped to make adoption and implementation more widespread⁸.

1 - Moriah Hospital, Service of Trauma Surgery, São Paulo, SP, Brasil. 2 - Institute of Medical Assistance to the State Public Server of São Paulo (IAMSPE), Postgraduate Program *Stricto sensu* on Health Sciences, São Paulo, SP, Brasil. 3 - Santo Amaro University (UNISA), Course of Medicine, São Paulo, SP, Brasil. 4 - Cambridge University NHS Foundation Trust, Cambridge Biomedical Campus, Department of Surgery, Cambridge, UK, England. 5 - Riverside University Health System, Surgical Research, Moreno Valley, CA, United States of America.

In summary, the technique consists of the insertion of a balloon catheter into the aorta through a small sheath in the common femoral artery (CFA). The balloon is inflated in the abdominal aorta above the estimated origin of the bleeding⁷. Zone I inflation (between the left subclavian artery and the celiac trunk) is indicated for intra-abdominal hemorrhage and zone III (between the renal arteries and the aortic bifurcation) inflation,

for pelvic, junctional, or high extremity hemorrhage (Figure 1)⁷⁻⁹. The insertion of the balloon catheter into the common femoral artery can be guided by anatomical markers using needle puncture, surgical dissection or ultrasonography for access, while device confirmation and positioning can be performed through imaging examinations, such as radiography or fluoroscopy, or by manual palpation in the case of exploratory laparotomy^{5,6}.

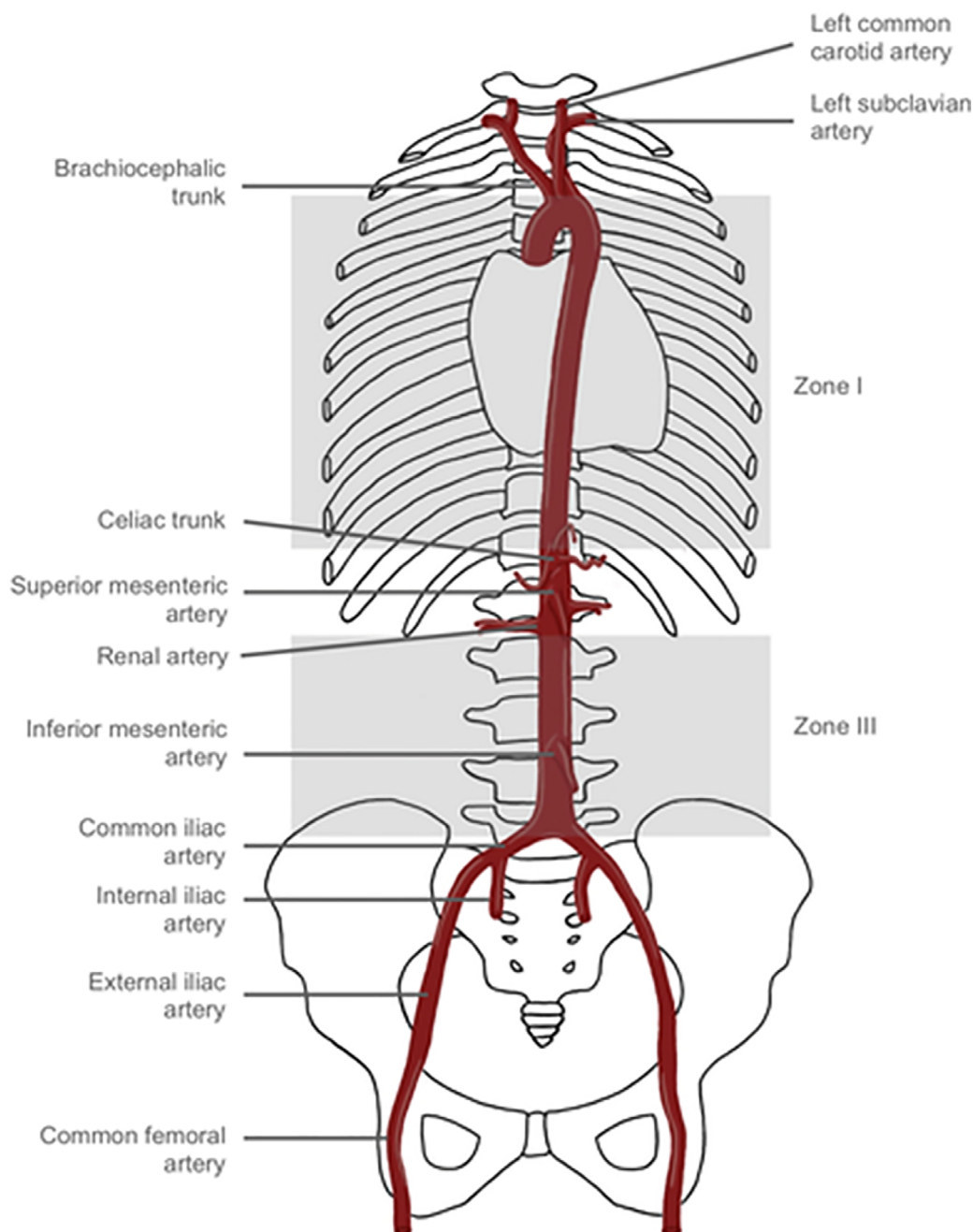


Figure 1. Zones of aortic occlusion.

Extended from the conventional use of REBOA with complete aortic occlusion, a number of variations have been developed, which consist of partial or intermittent occlusion. The goal of partial or intermittent occlusion is to reduce the physiologic burden associated with ischemia to distal tissue beds^{7,9}. Russo *et al.* compared partial and full aortic occlusion in a swine model of hemorrhagic shock, and found that partial REBOA is capable of reducing the deleterious effects of total occlusion of the aorta, allowing a longer duration of the procedure. The study demonstrated that partial REBOA maintains mean arterial pressure closer to the physiological values during and after the intervention, avoiding the hemodynamic extremes associated with complete occlusion and, consequently, resulting in less damage to the vital organs and less exacerbation of pre-existing injuries. Furthermore, partial REBOA reduced the systemic metabolic load of ischemia and inflammation and its impact on organ dysfunctions when compared with complete occlusion^{10,11}. Intermittent REBOA consists of sequential periods of fully inflation, deflation and re-inflation of the balloon, all at pre-determined time points¹²⁻¹⁴. Translational studies with swine report lower mortality, longer survival and fewer complications in the groups submitted to intermittent REBOA when compared with continuous REBOA¹².

Complications can occur at all times of the procedure and have recently been described⁹. Complications related to arterial access include inability to obtain access, bleeding, puncture in the incorrect location, venous puncture, as well as iatrogenic vascular injury, such as aortic dissection, rupture and perforation leading to embolization, air embolisms and peripheral ischemia^{6,8,9}.

During the insertion of the balloon catheter, the main complications that can occur are technical inability to gain CFA access or to insert the catheter up to its intended level. During the inflation of the balloon, the risks are balloon rupture and arterial injury. Throughout occlusion, the possible complications include exacerbation of proximal traumatic lesions, migration or prolapse of the balloon, increase in ischemia distal to the balloon, increase in proximal arterial pressure above the balloon, thrombosis, aortic dissection and or rupture. In balloon deflation, cardiovascular collapse can occur, as well as hypotension, thrombosis, clot rupture, resumed hemorrhage, hyperkalemia and acidosis. Finally, during catheter removal, there is the possible development of hematomas, pseudoaneurysm, thromboembolism, arterial dissection, and ischemia of limbs leading to amputation^{3,6,9}. Joseph *et al.* evaluated the complications and mortality from REBOA in a case-control, retrospective study, with 420 patients allocated between the REBOA group (n=140) and the no-REBOA group (n=280), and concluded that the use of REBOA did not show significant difference in blood transfusion in the 4-hour and 24-hour periods, and was associated with higher rates of complications, such as acute kidney injury and lower leg amputations, and a higher mortality¹⁵. Due to all of the complications described, adequate training of teams is critical to carry out the procedure safely, identify and manage complications, and select appropriate patients that may benefit from REBOA^{2,5,15}.

Considering the increasing number of indications for the use of REBOA not only in trauma as well as in other surgical conditions, the aim of this study is to identify other areas where the REBOA use can cause an impact, reducing mortality related to major bleedings.

METHODS

We performed an online search in PubMed, Medline and SciELO with the term "REBOA", in the last five years, resulting in 373 articles. Of these, after excluding the duplicated articles, we selected the ones with the title with unusual indications, resulting in 17 articles. After the evaluation of the complete texts, we excluded three articles because of the type of study (experimental) or the indication for chest penetrating trauma (a current contraindication).

The articles included were the 14 specifically describing the use of REBOA for non-traumatic conditions.

RESULTS

We grouped the articles according to indication, into patients with non-traumatic abdominal hemorrhages, which were mostly case reports, the main indications being gastrointestinal bleeding, aneurism, iatrogenic bleeding and bleeding of unknown origin (Table 1)¹⁶⁻²².

Table 1. Non-traumatic abdominal hemorrhage.

Author	Year of publication	Study type	Indication	Number of patients	Outcome
Weltz <i>et al.</i> ¹⁶	2015	Case report	Bleeding from a left intercostal artery during video-assisted retroperitoneal debridement of infected necrotizing pancreatitis.	1	No procedural complications occurred. After an 18-day hospital stay, the patient was discharged home.
Sano <i>et al.</i> ¹⁷	2016	Retrospective study and review	Gastric ulcer, duodenum ulcer, anastomotic bleeding, left gastric artery aneurism, esophageal cancer.	8 (retrospective study) and 4 (review)	Systolic blood pressure significantly increased after REBOA. Strong positive correlations found between REBOA total occlusion time and high lactate concentration, clinical Rockwall score, and age, respectively.
Lee <i>et al.</i> ¹⁸	2016	Case report	Bleeding source unknown in a patient with alcohol-induced liver cirrhosis presenting hematochezia.	1	Systolic blood pressure abruptly increased from 57 to 108 mmHg. The patient died of massive rebleeding 24 hours after admission.

continue...

...continuation

Author	Year of publication	Study type	Indication	Number of patients	Outcome
Ologun <i>et al.</i> ¹⁹	2017	Case report	Spontaneous splenic artery aneurysm rupture.	1	The patient's postoperative course was complicated by pneumonia, acute respiratory failure, requiring prolonged mechanical ventilation, and acute renal injury.
Matsumura <i>et al.</i> ²⁰	2017	Retrospective study	Gastrointestinal bleeding, visceral aneurysm, abdominal aortic aneurysm, post-abdominal surgery, and others.	31	REBOA contributed to the salvage of refractory hemorrhagic shock in both non-trauma and trauma patients. Nontraumatic subdiaphragmatic hemorrhagic shock was often caused by bleeding at a single site and 24-h survival was better than that for traumatic hemorrhage among a Japanese population undergoing REBOA. However, hospital mortality in the non-trauma REBOA group increased gradually over a prolonged period for non-hemorrhagic causes.
Hoehn <i>et al.</i> ²¹	2018	Brief report	Ruptured visceral aneurysm, gastrointestinal bleeding, hemorrhagic necrotizing pancreatitis, iatrogenic liver laceration, renal artery bleed, right Iliac artery hemorrhage.	11	Definitive surgical control of bleeding source obtained by open surgical approach (n=6) and combined surgical and endovascular approach (n=4). In-hospital survival was 64%. There were no procedural complications.

continue...

...continuation

Author	Year of publication	Study type	Indication	Number of patients	Outcome
Goodenough <i>et al.</i> ²²	2018	Case report	Ruptured iatrogenic dissection of the celiac trunk after attempting for revascularization of chronic mesenteric ischemia.	1	Early intervention with REBOA stabilized the patient and allowed time to transport the patient to the OR for definitive management.

For obstetric causes, the main indication arose from morbid adherent placenta (MAP), where REBOA was used in elective cesarean sections as a prophylaxis to reduce intraoperative bleeding. Also in relation to MAP, REBOA was used in pregnant patients with hemorrhagic shock already occurring during the cesarean.

Another indication was for postpartum hemorrhage (Table 2)^{20,23-28}.

Among the studies described, the main benefits of REBOA use were hemorrhage control and elevation of arterial pressure, reducing blood transfusion requirements and allowing patients to reach definitive treatment of injuries^{16-20,22-24,26,27,29}.

Table 2. Obstetric hemorrhage.

Author	Year of publication	Study type	Indication	Number of patients	Outcome
Matsumura <i>et al.</i> ²⁰	2017	Retrospective study	Obstetric and gynecology-derived events	5	REBOA contributed to the salvage of refractory hemorrhagic shock in both non-trauma and trauma patients. Nontraumatic subdiaphragmatic hemorrhagic shock was often caused by bleeding at a single site and 24-h survival was better than that for traumatic hemorrhage among a Japanese population undergoing REBOA. However, hospital mortality in the non-trauma REBOA group increased gradually over a prolonged period for non-hemorrhagic causes.
Stensaeth <i>et al.</i> ²³	2017	Retrospective study	Life threatening postpartum hemorrhage.	36	Technical success rate was 100%, no REBOA-related deaths.

continue...

...continuation

Author	Year of publication	Study type	Indication	Number of patients	Outcome
Okada <i>et al.</i> ²⁴	2017	Case report	Hemorrhagic shock due to uterine rupture with placenta accrete.	1	REBOA may be useful for maternal hemodynamic support, to prevent cardiac arrest and to contribute to a dry surgical field.
Manzano-Nunez <i>et al.</i> ²⁵	2018	Systematic review	Morbid adherent placenta (MAP).	336	The preoperative placement of a REBOA resulted in lower volumes of estimated blood loss in comparison with traditional cesarean delivery. Arterial access complications occurred in two patients and there were no maternal deaths.
Ordoñez <i>et al.</i> ²⁶	2018	Therapeutic study (systematic review, meta-analysis and case series)	Elective cesarean delivery in pregnant women with MAP.	12 (case series) and 441 (systematic review and meta-analysis)	The meta-analysis found that the use of REBOA as prophylaxis for the prevention of major hemorrhage was associated with a lower amount of intraoperative hemorrhage and lower requirements of blood products transfusions.
Greer <i>et al.</i> ²⁷	2018	Case report	Placenta accrete.	1	External iliac artery occlusion proximal to catheter insertion after REBOA use.
Manzano-Nunez <i>et al.</i> ²⁸	2018	Review	Adherent placenta.	-	REBOA is a viable and safe surgical intervention that is effective in reducing the volume of blood loss and transfusions in pregnant women with placental morbid adhesion in cesarean section. Reduction of maternal mortality.

DISCUSSION

Non-traumatic abdominal hemorrhage

Matsumura *et al.* compared the outcomes of the use of REBOA in traumatic and non-traumatic hemorrhages in their recent review

(n=36), among them a range of indications. We carried out the analysis of this study in a segmented way, considering two large groups: non-traumatic abdominal hemorrhage (n=31) and obstetric hemorrhage (n=5)²⁰. Among the studies reporting the use of REBOA for non-traumatic abdominal bleeding, we found 58 cases.

REBOA was effective in the containment of bleeding and hemodynamic stabilization, with an increase in systolic arterial pressure and preservation of myocardial and cerebral perfusion. This stabilization allowed some patients to undergo further examination and appropriate, definitive surgery^{16-20,22}. In addition, Goodenough *et al.* reported that REBOA permitted the reduction in the use of noradrenaline after insufflation of the balloon²².

Regarding the reported systemic complications, in the case of Ologun *et al.*, the patient presented with pneumonia, acute respiratory failure, with prolonged mechanical ventilation, acute kidney injury (attributed to severe prolonged hypotension during the pre and perioperative phases). The patient underwent a tracheotomy, and was finally waiting for transferal to a long stay institution¹⁹. Hoehn *et al.* reported no technical complications related to the use of REBOA, but six of the 11 patients experienced systemic complications: four patients with acute kidney injury requiring hemodialysis, one case of intestinal ischemia and one of pneumonia. It is unclear how much REBOA contributed to these systemic complications, as the rates of acute kidney injury and respiratory failure are high in patients with similar episodes of hemorrhagic shock and prolonged critical illness²¹.

Sano *et al.* registered one death among the four cases reported and two among the eight cases of their retrospective study failed definitive treatment¹⁷. In the case report from Lee *et al.*, the patient died following massive rebleeding 24 hours after admission¹⁸. In the study from Matsumura *et al.*, in the group of patients with non-traumatic abdominal hemorrhage, there was a total mortality of 23 patients, seven in the first 24 hours.

The causes were: multiple organ failure (n=13); hemorrhage (n=4); other causes or unknown causes (n=4); and encephalopathy by hypoxia (n=2). The higher mortality rate in the long term of these patients compared to patients with traumatic hemorrhage was likely due to factors such as advanced age, presence of comorbidities, postoperative events, among others²⁰. Hoehn *et al.* reported, among 11 patients assessed, a hospital mortality rate of 36% (n=4), with one death caused by uncontrollable hemorrhage (prior to undergoing REBOA) and one death by intolerance of balloon deflation²¹. The other studies did not report mortalities^{16,19,22}.

Currently, the use of REBOA in non-traumatic abdominal hemorrhages is principally based on case reports, with a lack of high level evidence in the literature for its indication in these settings^{16,18,19,21,22}. Prospective studies should be carried out to clarify the role of REBOA in these cases^{17,20}. Many authors suggest that, despite possible complications and the absence of strong evidence, REBOA could be useful as a step towards definitive treatment, if used in appropriate clinical settings, when the other options for bleeding control are unviable, morbid, or not immediately available^{16,18}. Matsumura *et al.* suggest that cases of sub-diaphragmatic hemorrhagic shock appear to be more controllable with REBOA and that, despite the limitations of the study, REBOA may improve clinical outcomes for non-traumatic patients²⁰.

In another study, total time of occlusion of the aorta, previous conditions of the patient such as the Rockall scores (estimate of repeated bleeding risk and death in a patient with a hemorrhagic peptic ulcer), and the serum lactate concentration during occlusion were correlated with outcomes in patients who received REBOA¹⁷.

Obstetric hemorrhage

The main indication for the use of REBOA in pregnant women with MAP is severe hypotension as a result of intra-operative hemorrhage. Two systematic reviews and case series describe the use of REBOA as a prophylactic measure in women with MAP during elective cesarean sections (n=787), to reduce blood loss and the volume transfused^{25,26}. It was also used to control hemorrhagic shock in pregnant women with MAP (n=4) and control postpartum hemorrhage (n=36)^{23-25,27}. REBOA was effective in the stabilization of bleeding and in the elevation of systolic arterial pressure^{23,24,26,27}.

Studies in this area have also demonstrated that the use of REBOA during cesarean section births in women with MAP result in lower blood loss, as well as in a reduction in the volume of blood transfused^{20,21,23}.

The consequences of REBOA to the fetus and newborn have not been extensively reported. Ordoñez *et al.* described no significant difference in the Apgar index between the control group and the REBOA group, with no Apgar recorded <4 (in one and five minutes)²⁶. However, Okada *et al.* report in their case that the Apgar was 1 (1 minute) and 5 (5 minutes). Further studies on the use of REBOA in pregnant women with MAP should be carried out to analyze the repercussions on the newborn²⁴.

Procedural complications relating to the insertion of REBOA occurred in 0,6% of patients in Ordoñez *et al.* cohort²⁶. Regarding postoperative complications, Greer *et al.* reported thrombotic occlusion of the external iliac artery and Stensaeth *et al.* reported thrombotic occlusion of the femoral artery.

There were no other complications related to REBOA or maternal mortalities^{23,27}.

Case series on use of REBOA for MAP and peri- or post-partum hemorrhage suggest it is a viable, safe and effective transitory intervention^{25,28}.

Future perspectives

Some of the new perspectives in the use of REBOA are related to its application for thoracic hemorrhage from penetrating trauma and non-traumatic cardiac arrest²⁹⁻³¹. In a study by Ordoñez *et al.*²⁶, seven hemodynamically unstable patients with thoracic hemorrhage from penetrating trauma underwent REBOA and median sternotomy performed simultaneously, which permitted immediate proximal control of hemorrhage above the level of aortic occlusion. Of the seven patients, four had sustained gunshot wounds, and three, stab wounds. Six of the patients suffered intrathoracic vascular hemorrhage from the subclavian arteries (2), internal mammary arteries (2) and aortic arch (2), and five, from the major central veins: innominate vein (1), internal jugular vein (1), subclavian vein (1), mammary vein (1) and subclavian vein (1). Four patients had associated pulmonary lesions²⁹.

The use of REBOA for control of intrathoracic vascular injury has not been widely recommended, as immediate control of proximal hemorrhage may be required to prevent worsening of injury. One case report demonstrates that REBOA performed simultaneously with median sternotomy is a viable and effective means of controlling hemorrhage proximal to the occlusion and improved perfusion of the heart and brain.

Of the seven patients studied, only one died of exsanguination, which could not be attributed solely to the use of REBOA. One complication after the use of REBOA was upper gastrointestinal bleeding. Despite the number of cases being small, the results suggest that in specific situations (ability to gain concurrent proximal control of hemorrhage via sternotomy or thoracotomy), REBOA for penetrating thoracic trauma may be a viable option in resource-rich settings with providers experienced in both REBOA and emergent thoracic procedures²⁹.

Two studies related to non-traumatic cardiac arrest were analyzed. One was a review evaluating experimental studies and case reports, and the other, an experimental study in porcine models^{30,31}. Daley *et al.*²⁹, evaluating a number of animal models, demonstrated that REBOA is capable of improving cerebral and coronary perfusion during resuscitation, leading to higher rates of return to spontaneous circulation and lower mortality.

In a case report of two individuals, there was an increase in the coronary perfusion pressure. In a case of a 74-year-old woman in asystolic cardiac arrest from myocardial infarction, after 30 seconds of aortic occlusion there was a spontaneous return of respiration and pulse, and the patient was discharged from hospital without neurological impairment. Furthermore, selective aortic arch perfusion (SAAP), which allows the infusion of substances like purified hemoglobin or vasopressin directly above the area occluded by the balloon, improves the coronary perfusion pressure and survival rates, without having an effect on the cerebral blood flow. Regarding the feasibility of REBOA, the main technical aspect that complicates its use is access to the femoral artery, which can be facilitated by ultrasound. Despite the benefits described, identifying those patients who could possibly benefit from the procedure is critical:

cardiac arrest with reversible etiology eligible for immediate treatment, after 20 minutes of failure of traditional resuscitation procedures, or if the patient displays signs of life.

Regardless of the available experimental studies demonstrating that REBOA represents a promising technology in life support during non-traumatic cardiac arrest, more clinical studies are necessary before widespread adoption³⁰.

Dogan *et al.*³⁰ carried out an experimental study in 27 pigs to assess the effectiveness of REBOA during resuscitation, comparing different levels of aortic occlusion. For this, a subdivision in zone I was proposed above the superior cardiac margin (Ia), behind the cardiac contour (Ib), and under the inferior cardiac margin (Ic). After evaluating the criteria such as systolic arterial pressure, diastolic arterial pressure, and arterial lactate, occlusion of subzone Ic during cardiac arrest was more effective than subzone Ib based on arterial pressure and lactate. Both subzones Ib and Ic were associated with an acid-base equilibrium that was better than the control group. Therefore, the level of occlusion could be an important criterion in the use of REBOA for non-traumatic cardiac arrest³¹.

In both articles describing use of REBOA for cardiac arrest, it was capable of improving mean arterial pressure, cerebral and myocardial perfusion, and the hemodynamic profile of the patient during resuscitation. However, both suggest further research and randomized controlled trials are required to determine the benefits of REBOA as an auxiliary tool in these situations^{30,31}.

CONCLUSION

The use of REBOA in non-traumatic emergencies may be safe and effective. Prospective studies and protocols for its implementation must be developed in order to include REBOA as a modality for treatment of patients in hemorrhagic shock.

R E S U M O

A oclusão resuscitativa por balão endovascular da aorta (REBOA) é utilizada para controlar hemorragias não compressíveis do tronco como uma opção menos invasiva e com menos distúrbios fisiológicos quando comparado à toracotomia de emergência com clameamento da aorta. Isso permite a melhora dos parâmetros hemodinâmicos até que a cirurgia definitiva seja realizada. É utilizada no trauma como uma medida para prevenir o colapso hemodinâmico em pacientes que estão em choque hemorrágico grave, mantendo a perfusão do cérebro e do coração enquanto diminui o sangramento distal até que o controle da hemorragia possa ser realizado. As principais complicações relatadas são insuficiência renal aguda, amputações de membros inferiores e óbitos. O objetivo desse estudo foi avaliar a expansão do uso do REBOA em situações não traumáticas de outras áreas da medicina, assim como, avaliar os resultados obtidos até o momento. Uma pesquisa online do PubMed, Medline e SciELO foi realizada com o termo "REBOA" nos últimos cinco anos, e os artigos incluídos foram os 14 que descrevem especificamente o uso do REBOA para condições não traumáticas. Os resultados sugerem que o uso do REBOA levou a um melhor controle do sangramento e aumento da pressão arterial, reduzindo a necessidade de transfusão de sangue e permitindo que os pacientes sobrevivam ao tratamento definitivo das lesões. Concluindo, o uso expandido do REBOA para emergências não traumáticas parece ser eficaz, mas estudos prospectivos e protocolos bem estabelecidos devem ser desenvolvidos para maximizar os resultados.

Descritores: Hemorragia. Hipovolemia. Hemorragia Gastrointestinal. Hemorragia Uterina. Procedimentos Cirúrgicos Minimamente Invasivos.

REFERENCES

- Hughes CW. Use of an intra-aortic balloon catheter tamponade for controlling intra-abdominal hemorrhage in man. *Surgery*. 1954;36(1):65-8.
- Malina M, Veith F, Ivancev K, Sonesson B. Balloon occlusion of the aorta during endovascular repair of ruptured abdominal aortic aneurysm. *J Endovasc Ther*. 2005;12(5):556-9.
- Greenberg RK, Srivastava SD, Ouriel K, Waldman D, Ivancev K, Illig KA, et al. An endoluminal method of hemorrhage control and repair of ruptured abdominal aortic aneurysms. *J Endovasc Ther*. 2000;7(1):1-7.
- Veith FJ, Lachat M, Mayer D, Malina M, Holst J, Mehta M, Verhoeven EL, Larzon T, Gennai S, Coppi G, Lipsitz EC, Gargiulo NJ, van der Vliet JA, Blankensteijn J, Buth J, Lee WA, Biasi G, Deleo G, Kasirajan K, Moore R, Soong CV, Cayne NS, Farber MA, Raithel D, Greenberg RK, van Sambeek MR, Brunkwall JS, Rockman CB, Hinchliffe RJ; RAAA Investigators. Collected world and single center experience with endovascular treatment of ruptured abdominal aortic aneurysms. *Ann Surg*. 2009;250(5):818-24.
- DuBose JJ, Scalea TM, Brenner M, Skiada D, Inaba K, Cannon J, Moore L, Holcomb J, Turay D, Arbabi CN, Kirkpatrick A, Xiao J, Skarupa D, Poulin N; AAST AORTA Study Group. The AAST prospective Aortic Occlusion for Resuscitation in Trauma and Acute Care Surgery (AORTA) registry: data on contemporary utilization and outcomes of aortic occlusion and resuscitative balloon occlusion of the aorta (REBOA). *J Trauma Acute Care Surg*. 2016;81(3):409-19.
- Davidson AJ, Russo RM, Reva VA, Brenner ML, Moore LJ, Ball C, Bulger E, Fox CJ, DuBose JJ, Moore EE, Rasmussen TE; BEST Study Group. The pitfalls of resuscitative endovascular balloon occlusion of the aorta: risk factors and mitigation strategies. *J Trauma Acute Care Surg*. 2018;84(1):192-202. Erratum in: *J Trauma Acute Care Surg*. 2018;84(3):544.
- Ribeiro Jr MAF, Brenner ML, Nguyen ATM, Feng CYD, De-Moura RR, Rodrigues VC, et al. Resuscitative endovascular balloon occlusion of the aorta (REBOA): an updated review. *Rev Col Bras Cir*. 2018;45(1):e1709.
- Osborn LA, Brenner ML, Prater SJ, Moore LJ. Resuscitative endovascular balloon occlusion of the aorta: current evidence. *Open Access Emerg Med*. 2019;11:29-38.
- Ribeiro Junior MAF, Feng CYD, Nguyen ATM, Rodrigues VC, Bechara GEK, de-Moura RR, et al. The complications associated with Resuscitative Endovascular Balloon Occlusion of the Aorta (REBOA). *World J Emerg Surg*. 2018;13:20.
- Russo RM, Williams TK, Grayson JK, Lamb CM, Cannon JW, Clement NF, et al. Extending the golden hour: partial resuscitative endovascular balloon occlusion of the aorta in a highly lethal swine liver injury model. *J Trauma Acute Care Surg*. 2016;80(3):372-8; discussion 378-80.

11. Sadeghi M, Hörer TM, Forsman D, Dogan EM, Jansson K, Kindler C, et al. Blood pressure targeting by partial REBOA is possible in severe hemorrhagic shock in pigs and produces less circulatory, metabolic and inflammatory sequelae than total REBOA. *Injury*. 2018;49(12):2132-41.
12. Morrison JJ, Ross JD, Houston R 4th, Watson JD, Sokol KK, Rasmussen TE. Use of resuscitative endovascular balloon occlusion of the aorta in a highly lethal model of noncompressible torso hemorrhage. *Shock*. 2014;41(2):130-7.
13. Kuckelman J, Barron M, Moe D, Derickson M, Phillips C, Kononchik J, et al. Extending the golden hour for Zone 1 REBOA: improved survival and reperfusion injury with intermittent versus continuous REBOA in a porcine severe truncal hemorrhage model. *J Trauma Acute Care Surg*. 2018;85(2):318-26.
14. Borger van der Burg BLS, Van Schaik J, Brouwers JJWM, Wong CY, Rasmussen TE, Hamming JF, et al. Migration of aortic occlusion balloons in an in vitro model of the human circulation. *Injury*. 2019;50(2):286-91.
15. Joseph B, Zeeshan M, Sakran JV, Hamidi M, Kulvatunyou N, Khan M, et al. Nationwide analysis of resuscitative endovascular balloon occlusion of the aorta in civilian trauma. *JAMA Surg*. 2019;154(6):500-8.
16. Weltz AS, Harris DG, O'Neill NA, O'Meara LB, Brenner ML, Diaz JJ. The use of resuscitative endovascular balloon occlusion of the aorta to control hemorrhagic shock during video-assisted retroperitoneal debridement or infected necrotizing pancreatitis. *Int J Surg Case Rep*. 2015;13:15-8.
17. Sano H, Tsurukiri J, Hoshiai A, Oomura T, Tanaka Y, Ohta S. Resuscitative endovascular balloon occlusion of the aorta for uncontrollable nonvariceal upper gastrointestinal bleeding. *World J Emerg Surg*. 2016;11:20.
18. Lee J, Kim K, Jo YH, Lee JH, Kim J, Chung H, et al. Use of resuscitative endovascular balloon occlusion of the aorta in a patient with gastrointestinal bleeding. *Clin Exp Emerg Med*. 2016;3(1):55-8.
19. Ologun G, Sharpton K, Granet P. Successful use of resuscitative endovascular balloon occlusion of the aorta in the treatment of ruptured 8.5-cm splenic artery aneurysm. *J Vasc Surg*. 2017;66(6):1873-5.
20. Matsumura Y, Matsumoto J, Idoguchi K, Kondo H, Ishida T, Kon Y, Tomita K, Ishida K, Hirose T, Umakoshi K, Funabiki T; DIRECT-IABO investigators. Non-traumatic hemorrhage is controlled with REBOA in acute phase then mortality increases gradually by non-hemorrhagic causes: DIRECT-IABO registry in Japan. *Eur J Trauma Emerg Surg*. 2017;44(4):503-9.
21. Hoehn MR, Hansraj NZ, Pasley AM, Brenner M, Cox SR, Pasley JD, et al. Resuscitative endovascular balloon occlusion of the aorta for non-traumatic intra-abdominal hemorrhage. *Eur J Trauma Emerg Surg*. 2018;45(4):713-8.
22. Goodenough CJ, Cobb TA, Holcomb JB. Use of REBOA to stabilize in-hospital iatrogenic intra-abdominal hemorrhage. *Trauma Surg Acute Care Open*. 2018;3(1):e000165.
23. Stensaeth KH, Sovik E, Haig IN, Skomedal E, Jorgensen A. Fluoroscopy-free Resuscitative Endovascular Balloon Occlusion of the Aorta (REBOA) for controlling life threatening postpartum hemorrhage. *PLoS One*. 2017;12(3):e0174520.
24. Okada A, Nakamoto O, Komori M, Arimoto H, Rinka H, Nakamura H. Resuscitative endovascular balloon occlusion of the aorta as an adjunct for hemorrhagic shock due to uterine rupture: a case report. *Clin Case Rep*. 2017;5(10):1565-8.
25. Manzano-Nunez R, Escobar-Vidarte MF, Naranjo MP, Rodriguez F, Ferrada P, Casallas JD, et al. Expanding the field of acute care surgery: a systematic review of the use of resuscitative endovascular balloon occlusion of the aorta (REBOA) in cases of morbidly adherent placenta. *Eur J Trauma Emerg Surg*. 2018;44(4):519-26.
26. Ordoñez CA, Manzano-Nunez R, Parra MW, Rasmussen TE, Nieto AJ, Herrera-Escobar JP, et al. Prophylactic use of resuscitative endovascular balloon occlusion of the aorta in women with abnormal placentation: a systematic review, meta-analysis, and case series. *J Trauma Acute Care Surg*. 2018;84(5):809-18.
27. Greer JW, Flanagan C, Bhavaraju A, Davis B, Kimbrough MK, Privratsky A, et al. Right external iliac artery thrombus following the use of resuscitative endovascular balloon occlusion of the aorta for placenta accreta. *J Surg Case Rep*. 2018;2018(11):rjy313.

28. Manzano-Nunez R, Escobar-Vidarte MF, Orlas CP, Herrera-Escobar JP, Galvagno SM, Melendez JJ, et al. Resuscitative endovascular balloon occlusion of the aorta deployed by acute care surgeons in patients with morbidly adherent placenta: a feasible solution for two lives in peril. *World J Emerg Surg.* 2018;13:44.
29. Daley J, Morrison JJ, Sather J, Hile L. The role of resuscitative endovascular balloon occlusion of the aorta (REBOA) as an adjunct to ACLS in non-traumatic cardiac arrest. *Am J Emerg Med.* 2017;35(5):731-6.
30. Dogan EM, Beskow L, Calais F, Hörer TM, Axelsson B, Nilsson KF. Resuscitative Endovascular Balloon Occlusion of the Aorta in experimental cardiopulmonary resuscitation: aortic occlusion level matters. *Shock.* 2019;52(1):67-74.
31. Ordoñez CA, Parra MW, Manzano-Nunes R, Herrera-Escobar JP, Serna JJ, Rodriguez Ossa P, et al. Intraoperative combination of resuscitative endovascular balloon occlusion of the aorta and a median sternotomy in hemodynamically unstable patients with penetrating chest trauma: is this feasible? *J Trauma Acute Care Surg.* 2018;84(5):752-7.

Received in: 08/22/2019

Accepted for publication: 09/01/2019

Conflict of interest: none.

Source of funding: none.

Mailing address:

Marcelo Augusto Fontenelle Ribeiro Júnior

E-mail: drmribeiro@gmail.com

