

# Amyand's hernia

## *Hérnia de Amyand*

HÉRCIO AZEVEDO DE VASCONCELOS CUNHA, TCBC-SP<sup>1</sup>; RICARDO DUTRA SUGAHARA, ACBC-SP<sup>2</sup>; MICHEL VICTOR CASTILHO<sup>3</sup>

### INTRODUCTION

In 1735, Claudius Amyand described the presence of the vermiform appendix inside an inguinal hernial sac, and the condition has been known by his name ever since<sup>1</sup>.

According to the literature, the incidence of a normal appendix within the hernial sac is estimated to be approximately one percent<sup>2</sup>. Acute appendicitis in the inguinal hernia is an even less common event, which accounts for 0.1% of all cases of acute appendicitis<sup>3</sup>.

We present the case of a patient whose appendix was found adherent to the hernial sac during an elective inguinal herniorrhaphy.

### CASE REPORT

A 22-year-old male, a production line assistant from Campinas, SP, presented to the general surgery clinic with the complaint of a right inguinal bulge for the last seven years, and a 3-month history of local pain on exertion. Physical examination showed an inguinal bulge to the right side during Valsalva's maneuver, and the cough test revealed an indirect hernia.

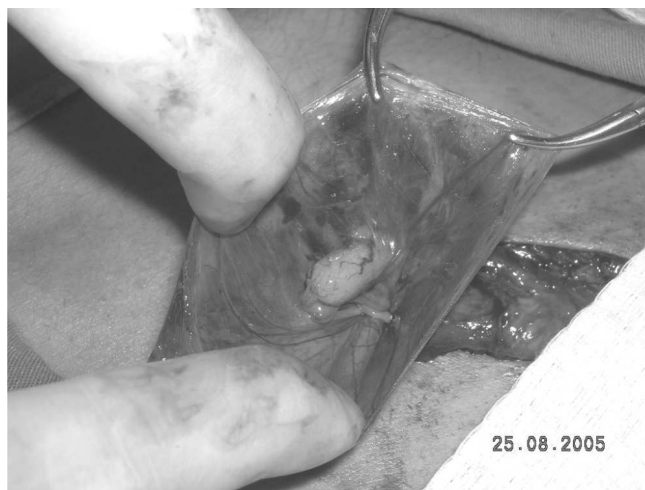After an inguinal herniotomy for herniorrhaphy, during the dissection and opening of the hernial sac protruding through the deep inguinal ring, the vermiform appendix was found inside the sac (Figure 1 and 2), adhering to it.

The closure of the hernial sac was performed following reduction of the appendix into the abdominal cavity. Barker's technique was used, and herniorrhaphy was performed by the Bassini repair technique.

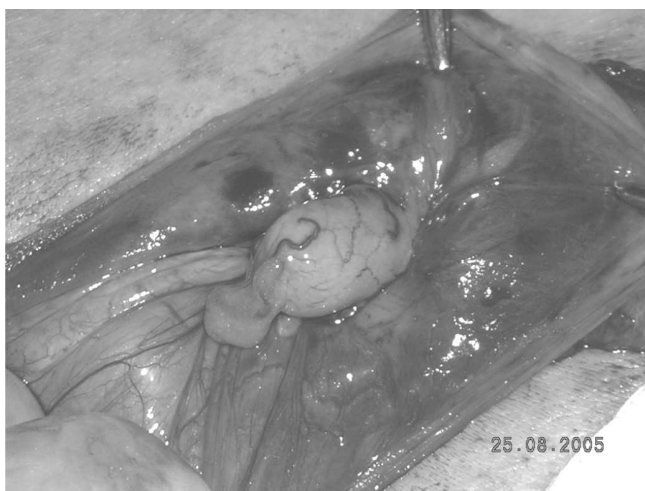
The patient presented satisfactory clinical evolution, and was discharged on the first postoperative day. Currently on outpatient follow-up, the patient has no complaints or complications.

### DISCUSSION

The presence of the vermiform appendix (without complications) inside a hernial sac is a rare event. The literature reports that the incidence is around one percent<sup>2</sup>. More rare and exceptional is the occurrence of a



**Figure 1** – Open hernial sac with the appendix inside.



**Figure 2** – Open hernial sac with the appendix inside (detail).

complicated appendix with acute appendicitis within the hernial sac. In the literature, it is reported with an incidence between 0.13% and 0.1%<sup>3-5</sup>.

Cases of acute appendicitis within the hernial sac have been described in patients with ages ranging from 3 weeks to 88 years.

The diagnosis of this affection is always made intraoperatively.

In cases complicated with acute appendicitis, the patient presents with acute abdomen and

From the Hospital and Maternity Unit Celso Pierro, PUC, Campinas, SP, Brazil.

1. Residency Preceptor of General Surgery at the Hospital and Maternity Unit Celso Pierro, PUC, Campinas, SP, Brazil; 2. Full Member of the Brazilian Society of Coloproctology; 3. Attending physician at the Gastric Surgery Service of the Hospital and Maternity Unit Celso Pierro, PUC, Campinas, SP, Brazil.

differential diagnosis is an incarcerated and/or strangulated hernia<sup>3</sup>.

When a normal appendix is found, appendectomy is not recommended, only reduction of the viscera and treatment of the hernial sac as in the case

described herein. If acute appendicitis is present, on the other hand, the literature advises appendectomy through a herniotomy and, in the absence of intracavitary contamination, the repair of the hernia defect should be undertaken<sup>2-5</sup> at the same time.

---

## A B S T R A C T

We present the finding of a vermiform appendix within an inguinal hernial sac, a rare condition known as Amyand's hernia. We report on the incidence as found in the literature and the recommended management.

**Key-words** : Hernia. Appendix. Appendicitis. Acute diseases.

---

## REFERENCES

1. Hiatt JR, Hiatt N. Amyand's hernia. *N Engl J Med* 1988; 318(21):1402.
2. Franko J, Raftopoulos I, Sulkowski R. A rare variation of Amyand's hernia. *Am J Gastroenterol.* 2002; 97(10):2684-5.
3. Logan MT, Nottingham JM. Amyand's hernia: a case report of an incarcerated and perforated appendix within an inguinal hernia and review of the literature. *Am Surg.* 2001; 67(7):628-9.
4. Ellis H. Appendix. In: Schwartz SI, Ellis H, editors. *Maingot's abdominal operations.* 9<sup>th</sup> ed. Norwalk: Appleton & Lange; 1990. p. 955-77.
5. Luchs JS, Halpern D, Katz DS. Amyand's hernia: prospective CT diagnosis. *J Comput Assist Tomogr.* 2000; 24(6):884-6.

Received 20/03/2006

Accepted for publication 30/05/2006

Conflict of interest: none

Financial source: none

### How to cite:

Cunha HAV, Sugahara RD, Castilho MV. Amyand's hernia. *Rev Col Bras Cir.* [periódico na Internet] 2009; 36(3). Disponível em URL: <http://www.scielo.br/rcbc>

### Correspondence address:

Dr. Michel Victor Castilho

E-mail: [michelcastilho@hotmail.com](mailto:michelcastilho@hotmail.com)