

## Review articles

# The effects of lingual frenotomy on breastfeeding: an integrative review

**Hellen Kalina Medeiros Porto de Souza Santos<sup>1</sup>**<https://orcid.org/0000-0001-7610-8411>**Daniele Andrade da Cunha<sup>1</sup>**<https://orcid.org/0000-0002-3987-9740>**Rodrigo Alves de Andrade<sup>1</sup>**<https://orcid.org/0000-0002-2810-750X>**Gilberto de Souza Santos<sup>1</sup>**<https://orcid.org/0000-0002-1319-7936>**Hilton Justino da Silva<sup>1</sup>**<https://orcid.org/0000-0002-6852-3233>

<sup>1</sup> Universidade Federal de Pernambuco – UFPE, Recife, Pernambuco, Brasil.

Research support source: Coordenação de Aperfeiçoamento de Pessoal de Nível Superior, Brasil (CAPES) – código de financiamento 001.

Conflict of interests: Nonexistent



## ABSTRACT

**Purpose:** to investigate what effects lingual frenotomy has on breastfeeding.

**Methods:** based on the research question – “Is there a relationship between the improvement in breastfeeding and the lingual frenotomy?” –, a bibliographical survey was carried out in three databases, using the following descriptors: ankyloglossia, lingual frenum, breastfeeding and frenotomy. Frenotomy is a free term. Original articles with babies up to 6 months old who had difficulties breastfeeding due to ankyloglossia and who had been submitted to lingual frenotomy were chosen. An instrument was developed, containing the following information: name of the authors, year of publication, country of origin, the objective of the study, type of study, sample, main results, and conclusion.

**Literature Review:** of the 243 articles screened, four met the inclusion criteria for this study. It was observed that, after lingual frenotomy, some changes may take place in breastfeeding patterns, such as an increase in the number of suctions and a decrease in the time of pause in between series of suctions.

**Conclusion:** the lingual frenotomy can be an important procedure in the treatment of babies with ankyloglossia, possibly helping improve the latch and breastfeeding.

**Keywords:** Lingual Frenum; Ankyloglossia; Breast Feeding; Speech, Language and Hearing Sciences.

Received on: October 22, 2021  
Accepted on: November 23, 2021

**Corresponding address:**

Rodrigo Alves de Andrade  
Universidade Federal de Pernambuco -  
Departamento de Fonoaudiologia  
Rua Professor Artur de Sá, s/n -  
Cidade Universitária  
CEP: 50674-420 - Recife, Pernambuco,  
Brazil  
E-mail: [rodrigoandrade10@gmail.com](mailto:rodrigoandrade10@gmail.com)

## INTRODUCTION

Ankyloglossia, popularly known as tongue-tie, is a congenital anomaly characterized by a short, thick frenum, resulting in limited tongue movements<sup>1</sup>. The main symptoms associated with ankyloglossia in breastfeeding are the mother's nipple pain and the baby's difficulty in sucking, leading to early weaning and weight loss<sup>1</sup>. To determine whether an abnormal frenum is impairing the orofacial functions, it is important to evaluate its anatomical variations, as well as the tongue movements when performing these functions<sup>2</sup> – i.e., a set of characteristics that leads to the diagnosis. Surgery is indicated only in the cases when these functions are impaired<sup>2,3</sup>.

Lingual frenotomy is the most used of the various types of procedures. It is a considerably simple and safe procedure, with a low rate of complications, and it possibly influences aspects of the baby's breastfeeding<sup>4,5</sup>. Contrary to what has been described in the literature, the lingual frenum does not change in one's lifetime in terms of thickness, attachment to the tongue, and attachment to the floor of the mouth<sup>6</sup>. Therefore, as soon as tongue movement restrictions are diagnosed, frenotomy may be performed to avoid early weaning – since the frenum's histological composition prevents it from ripping or being stretched with exercises<sup>6</sup>.

Changes in the lingual frenum, the subject's age, and the different types of surgical procedures are known to potentially influence the final results. Therefore, it is important to perform frenotomy as early as possible<sup>3</sup>. Diagnosing ankyloglossia in the first months of life can minimize the impairments of oral function development and performance<sup>7</sup>. To this end, the cooperation between the speech-language-hearing therapist and dental surgeon is extremely important. Once infants are diagnosed with the change, they are referred for therapy to receive intervention and be submitted to lingual frenotomy. This can improve the quality of breastfeeding, avoid future anatomo-functional changes, and prevent psychological and social constraints related to this limitation<sup>6</sup>.

Most studies point to changes in breastfeeding and the mothers' nipple pain after performing lingual frenotomy, which does not cause important postoperative complications<sup>7</sup>. However, they do not make clear the possible relationship between the changes observed in breastfeeding and the frenotomy.

## OBJECTIVE

The objective of this research was to investigate what are the effects of lingual frenotomy on breastfeeding.

## METHODS

### Research Strategy

The research question was: Is there a relationship between the improvement in breastfeeding and the lingual frenotomy?

Studies with babies up to 6 months old who had difficulty breastfeeding due to ankyloglossia and studies that approached the effects of lingual frenotomy on breastfeeding were included. Literature reviews, books, reviews, scientific event material, and editorials were excluded.

The bibliographical survey was carried out in February and March 2019 in the following databases: SciELO, MEDLINE, and Cochrane Library – which was consulted for its Central Register of Controlled Trials. The terms were selected based on the conceptual block macrostructure, in which each term represents a field to be investigated in relation to another one. The Medical Subject Headings (MeSH) were used to validate the research terms for the said databases. After validation, the search was pillar-shaped by the descriptors, establishing the synonyms and the relationships to be made. Hence, the search followed the method: Lingual Frenum AND Ankyloglossia AND Breastfeeding AND Frenotomy. Frenotomy is a free term. No year and/or language restriction was applied to this research.

The search was conducted by two independent authors, following a previously developed protocol. Whenever there was a disagreement, a third author was consulted. Both authors concluded all the stages of the integrative review.

### Selection Criteria

The article selection process was conducted in a blind, paired, and independent manner and was divided into three stages: identification, screening, and inclusion of studies. In the initial stage, all the references retrieved in the database search were identified, with independent consultation by two reviewers. The Mendeley software (<https://www.mendeley.com/>) was used to manage, store, analyze, and remove duplicate references.

The screening consisted of reading titles and abstracts to dismiss studies that did not meet the preestablished selection criteria while maintaining

the possibly eligible ones. This stage was conducted by two reviewers, and disagreements were solved by consensus. Afterward, the manuscripts were read in full to verify whether the selected references answered the research question and met the eligibility criteria. Hence, the articles had to be focused on the effects of frenotomy on breastfeeding. Two independent, blind, and paired reviewers assessed the full texts. Judgment disagreements were solved by a discussion with a third

reviewer experienced in breastfeeding and literature reviews.

## Data Analysis

The studies were descriptively and comparatively analyzed. Criteria were established to group them, namely: author, year of publication, country of origin, the purpose of the study, type of study, sample, main results, and conclusion (Table 1).

**Table 1.** Detailed methodological aspects

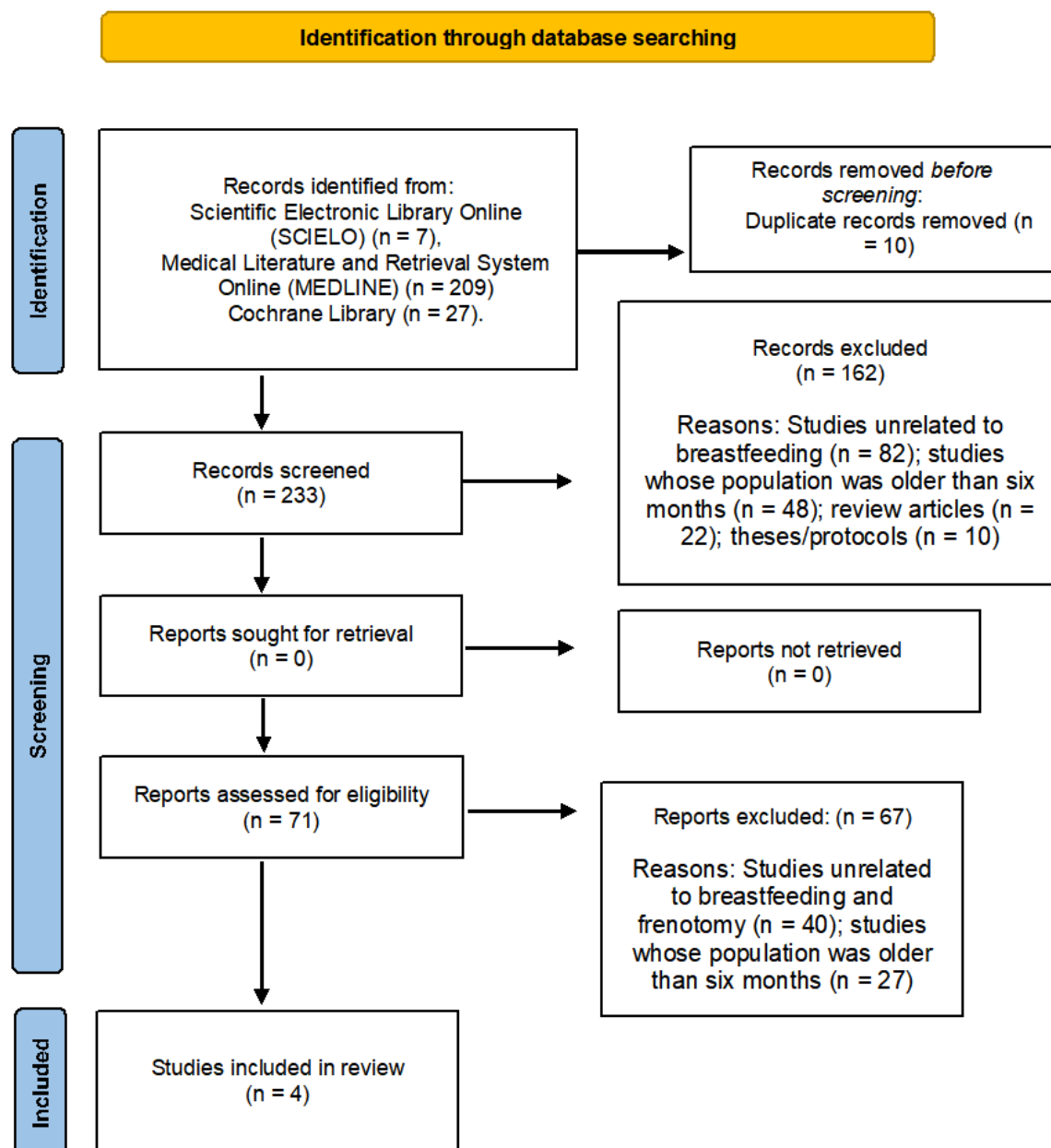
Author/Year	Country	Purpose	Type of study	Sample	Main results	Conclusion
Martinelli et al., 2015	Brazil	To observe the changes in breastfeeding patterns after frenotomy, the number of suctions, pause in between sequences of sucking, and mother's complaints.	Prospective longitudinal study	14 – 30 days 10 M 4 F	After frenotomy, the number of suctions increased, the pauses in between suctions during breastfeeding were shorter, and there was an improvement in the symptoms related to breastfeeding and coordinated sucking/swallowing/breathing. The control group kept the same pattern.	Changes in the breastfeeding patterns were observed, as well as in the following symptoms reported by the mothers: short time in between breastfeeds (less than one hour), reduced breastfeeding time, infant fatigue when breastfeeding, and inefficient milk transfer and sleep.
Ferrés-Amat et al., 2016	Spain	To present a case of ankyloglossia with difficulties in sucking.	Case report	1 – 17 days M	Relieved nipple pain, reduced breastfeeding time, and reached ideal weight for the baby's age para, these were the results observed after the frenotomy, associated with orofacial stimulation.	The frenotomy is necessary once the interference of ankyloglossia in breastfeeding is diagnosed. Orofacial stimulation is recommended before and after the intervention.
Ghaheiri et al., 2017	United States	To determine the impact of the frenotomy in breastfeeding impairment.	Prospective cohort study	237 – 0-12 weeks 133 M 104 F	Improvement in the breastfeeding results that have an impact on the quality of life of the pair: mother's self-confidence, nipple pain, symptoms of infant reflux, and rate of milk transfer	The frenotomy resulted in improved quality and duration of breastfeeding, taking place precociously (one week after the surgery) and continuing to progress one month after the surgery.
Almeida et al., 2018	Brazil	To describe a clinical case with diagnosis and frenotomy in a newborn with difficulty breastfeeding, with a 6-month follow-up.	Case report	1 – 5 days F	Improved assessment protocol scores immediately and 24 hours after performing frenotomy. Infant formula was removed, and the adequate weight for the age was reached, maintaining exclusive breastfeeding.	The frenotomy contributed to improve the latch, as well as to maintain the newborn's exclusive breastfeeding.

Caption: M - Male, F - Feminine

## LITERATURE REVIEW

A total of 243 articles were screened with a database search, 10 of which were excluded for being duplicates. The title/abstract screening analyzed 233 articles, and the full-text screening, 71 articles.

However, 67 were excluded for being unrelated to breastfeeding and having a population different from the established in the eligibility criteria. Thus, only four articles addressed the effects of frenotomy on breastfeeding (Figure 1).



**Figure 1.** Flowchart of the search and selection phases of the integrative literature review regarding the effects of lingual frenotomy on breastfeeding

Despite the methodological heterogeneity of the articles analyzed, the authors report that breastfeeding may be impaired by ankyloglossia-related suction difficulties<sup>8-11</sup>. Ankyloglossia in newborns is related to breastfeeding difficulties – infants with such a change have signs of suction difficulties 36.07 times greater than those without this change<sup>12</sup>.

Breastfeeding is directly related to coordinating the functions of sucking, swallowing, and breathing. Given the importance of free tongue movement for these functions to be performed, any restrictions to it can impair them, contributing to early weaning, low weight,

and impairment of the baby's healthy development<sup>10</sup>. Moreover, there are the mother's symptoms, such as engorged breasts and painful and/or cracked nipples<sup>13</sup>.

As for the country of origin, two were conducted in Brazil<sup>8,10</sup>, one in the United States<sup>9</sup>, and one in Spain<sup>11</sup>. In Brazil, law no. 13.002, of June 20, 2014, makes it mandatory for every hospital and maternity to use a lingual frenum assessment protocol – popularly known as the “tongue-tie test” – in the babies born in their premises<sup>14</sup>. This protocol is a great advance for the early diagnosis of the interference of the lingual frenum in breastfeeding.

The sample size varied widely from one article to the other. There were two case reports with only one participant<sup>10,11</sup>, one study with 14 participants<sup>9</sup>, and another one with 237 participants<sup>9</sup>. The participants' age when included in the studies also varied, ranging from five days<sup>10</sup> to 12 weeks old<sup>9</sup>. This demonstrates the heterogeneity in making such research, which can be associated with the specific demands of each service where the studies were carried out. It is important to highlight that, to reduce the risks of early weaning and provide a better quality of life for mother and baby, the lingual frenum must be assessed, preferably in the baby's first month of life<sup>15</sup>.

As for the instruments, two studies used the assessment tool for lingual frenulum function (ATLFF)<sup>9</sup>, another two used the "tongue-tie test"<sup>8,10</sup>, and only one article used the Coryllos classification<sup>11</sup>.

In summary, the difference between the instruments is in how they define the interference of the frenum in the tongue movements. The ATLFF assesses the tongue/frenum function and its appearance, in which zero means the worst condition. The perfect score is 14, in which no surgical treatment is indicated, regardless of the score given in appearance; a score of 11 means an acceptable function, only if the appearance has a score of 10; function is impaired when the score is below 11, in which case surgery is indicated if the appearance has a score lower than eight. The "tongue-tied test" has a scale, in which zero means normal, progressively increasing with the degrees of change, considering both the clinical history and examination. In the final score, the best result is zero and the worst is 25, with an indication for surgical treatment when the two examinations add up to 13 or more. The Coryllos classification, in its turn, establishes four types of ankyloglossia: type 1, when the frenum is attached to the floor of the mouth and the tip of the tongue; type 2, when the frenum is thick and short, restricting the tongue's lifting; type 3, when tongue mobility is impaired due to the frenum being inserted between the middle third and the floor of the mouth, and type 4, when movement is impaired due to a shorter and more fibrous frenum<sup>16</sup>.

In four of the articles, the surgical technique used was frenotomy<sup>(6-11)</sup>. This technique is a simple procedure, unlikely to have postoperative complications. Frenotomy consists of the linear anteroposterior incision of the lingual frenum, without removing the tissue<sup>17</sup>.

When verifying the frequency of participants by sex, it was observed that in the study with 237 participants,

133 were males and 104, females<sup>9</sup>; in the study with 14 participants, 10 were males and four, females<sup>8</sup>; one case reports described female patients<sup>10</sup>, and the other one, a male patient<sup>11</sup>. According to a bibliographical survey carried out in 2016<sup>18</sup>, lingual frenum changes have an incidence of 4% to 22.5% in newborns, with a higher frequency among males. However, other studies<sup>2,18,19</sup> observed a similar sample between the sexes.

The studies analyzed reveal that, after frenotomy, the number of suction increases, the time of pause in between suction in breastfeeding decreased, and the symptoms related to breastfeeding and the suction/swallowing/breathing coordination improved. They also showed that the nipple pain was eased, the breastfeeding time decreased, and the infant's ideal weight-for-age was reached after the frenotomy, associated with orofacial stimulation. Although they demonstrated descriptive results based on observing the breastfeeding mothers, quantitative methods must also be used to analyze the impacts of frenotomy on the electrical activity of the muscles involved in suction during breastfeeding and the breastfeeding biomechanics.

Considering that the review comprised only four studies – two of which were cases studies with just one participant each, and one study had only 14 participants –, the evidence is limited. The studies are few, the samples are small, and the methodologies used are inconsistent.

## CONCLUSION

The articles analyzed in this study show that babies with ankyloglossia may have difficulties in breastfeeding, and suggest that lingual frenotomy can be an eligible procedure to treat these cases, potentially contributing to a better latch and to maintain breastfeeding.

## REFERENCES

1. Braga LAS, Silva J, Pantuzzo CL, Motta AR. Prevalência de alteração no frênulo lingual e suas implicações na fala de escolares. *Rev. CEFAC*. 2009;11(Supl 3):378-90. <https://dx.doi.org/10.1590/S1516-18462009000700014>

2. Susanibar F, Santos R, Marchesan I. Dia Mundial da Motricidade Orofacial. "Língua presa, funções orofaciais prejudicadas". Rev. CEFAC. 2017;19(1):1-4. <https://dx.doi.org/10.1590/1982-02162017191ed2>
3. Marchesan IQ, Martinelli RLC, Gusmão RJ. Frênulo lingual: modificações após frenectomia. J Soc Bras Fonoaudiol. 2012;24(4):409-12. <https://dx.doi.org/10.1590/S2179-64912012000400020>
4. Marchesan IQ, Oliveira LR, Martinelli RLC. Frênulo da língua - Controvérsias e evidências. In: Marchesan IQ, Silva HJ, Tomé MC, editors. Tratado das Especialidades em Fonoaudiologia. São Paulo: Roca; 2014. p.283-301.
5. Webb AN, Hao W, Hong P. The effect of tongue-tie division on breastfeeding and speech articulation: a systematic review. Int J Pediatr Otorhinolaryngol. 2013;77(5):635-46. <https://doi.org/10.1016/j.ijporl.2013.03.008>
6. Martinelli RLC, Marchesan IQ, Berretin-Felix G. Estudo longitudinal das características anatômicas do frênulo lingual comparado com afirmações da literatura. Rev. CEFAC. 2014;16(4):1202-7. <https://dx.doi.org/10.1590/1982-021620149913>
7. Procópio IMS, Costa VPP, Lia EN. Frenotomia lingual em lactentes. RFO UFP. 2012;22(1):114-9. <https://doi.org/10.5335/rfo.v22i1.6849>
8. Martinelli RLC, Marchesan IQ, Gusmão RJ, Honório HM, Berretin-Felix G. The effects of frenotomy on breastfeeding. J. Appl. Oral Sci. 2015;23(2):153-7. <https://dx.doi.org/10.1590/1678-775720140339>
9. Ghaheri BA, Cole M, Fausel SC, Chuop M, Mace JC. Breastfeeding improvement following tongue-tie and lip-tie release: A prospective cohort study. Laryngoscope. 2017;127(5):1217-23. <https://doi.org/10.1002/lary.26306>
10. Almeida KR, Leal TP, Kubo H, Castro TES, Ortolani CFL. Frenotomia lingual em recém-nascido, do diagnóstico à cirurgia: relato de caso. Rev. CEFAC. 2018;20(2):258-62. <https://dx.doi.org/10.1590/1982-0216201820212917>
11. Ferrés-Amat E, Pastor-Vera T, Rodriguez-Alessi P, Ferrés-Amat E, Mareque-Bruno J, Ferrés-Padró E. Management of ankyloglossia and breastfeeding difficulties in the newborn: breastfeeding sessions, myofunctional therapy, and frenotomy. Case reports in pediatrics. 2016;2016:1-5. <http://dx.doi.org/10.1155/2016/3010594>
12. Campanha SMA, Martinelli RLC, Palhares DB. Association between ankyloglossia and breastfeeding. CoDAS. 2019;31(1):e20170264. <https://dx.doi.org/10.1590/2317-1782/20182018264>
13. Emond A, Ingram J, Johnson D, Blair P, Whitelaw A, Copeland M et al. Randomised controlled trial of early frenotomy in breastfed infants with mild-moderate tongue-tie. Arch Dis Child Fetal Neonatal. 2014;99(3):F189-95. <https://doi.org/10.1136/archdischild-2013-305031>
14. Martinelli RLC, Marchesan IQ, Berretin-Felix G. Protocolo de avaliação do frênulo lingual para bebês: relação entre aspectos anatômicos e funcionais. Rev. CEFAC. 2013;15(3):599-610. <https://dx.doi.org/10.1590/S1516-18462013005000032>
15. Oliveira MTP, Montenegro NC, Silva RDA, Carvalho FM, Rebouças PD, Lobo PLD. Frenotomia lingual em bebês diagnosticados com anquiloglossia pelo Teste da Linguinha: série de casos clínicos. RFO. 2019;24(1):73-1. <https://doi.org/10.5335/rfo.v24i1.8934>
16. Ripplinger T. Protocolo para avaliação de frênulo lingual na primeira infância [thesis]. Pelotas (RS): Universidade Federal de Pelotas; 2017.
17. Procópio IMS. Tratamento cirúrgico da anquiloglossia [monography]. Brasília (DF): Universidade de Brasília; 2015. Available at: [http://bdm.unb.br/bitstream/10483/9476/1/2014\\_IryanaMarquesSenaProcopio.pdf](http://bdm.unb.br/bitstream/10483/9476/1/2014_IryanaMarquesSenaProcopio.pdf)
18. Marcione ESS, Coelho FG, Souza CB, França ECL. Anatomical classification of lingual frenulum in babies. Rev. CEFAC. 2016;18(5):1042-49. <https://dx.doi.org/10.1590/1982-0216201618522915>
19. de Lima C, Maranhão V, Botelho K, Junior V. Avaliação da anquiloglossia em neonatos por meio do teste da linguinha: um estudo de prevalência. RFO. 12jun.2018;22(3). <http://seer.upf.br/index.php/rfo/article/view/7657>