

Implications of anatomical variation of the sphenoid sinus for orthognathic surgery: a case report in cone beam computed tomography

Implicações da variação anatômica do seio esfenooidal para cirurgia ortognática: um relato de caso em tomografia computadorizada de feixe cônico

Rafaela FERLIN¹  0000-0003-1559-2232

Otávio PAGIN¹  0000-0002-3189-898X

Bruna Stuchi Centurion PAGIN¹  0000-0002-8597-8299

Marina de Almeida Barbosa MELLO¹  0000-0001-7135-2474

Renato Yassutaka Faria YAEDÚ^{1,2}  0000-0002-2576-7887

ABSTRACT

The Sphenoid Sinus is considered the paranasal sinus with more variation to the degree of pneumatization. Thus, this work aimed report to the first case on the interference of this anatomical variation for orthognathic surgery. A 18 year-old woman, with isolated cleft palate repaired, was submitted to orthognathic surgery to correct the maxillomandibular skeletal discrepancy. The cone beam computed tomography (CBCT) exam performed for preoperative planning showed a great extension for the adjacent structures, with proximity to the posterior wall of the maxillary sinus and pterygomaxillary fissure bilaterally. The postoperative CBCT image evidenced the compromise of the sinus floor due to the factors related to the transoperative period. This case, along with literature review, highlighted the importance of identifying sphenoid sinus variation in CBCT exams prior to orthognathic surgery, in order to avoid serious complications for the patient, such as sinus infections; hemorrhages; mucocele formation or intracranial involvement.

Indexing terms: Anatomic variation. Cleft palate. Cone-beam computed tomography. Orthognathic surgery. Sphenoid sinus.

RESUMO

O Seio Esfenooidal é considerado o seio paranasal com maior variação quanto ao grau de pneumatização. Assim, este trabalho objetivou relatar o primeiro caso sobre a interferência dessa variação anatômica para a cirurgia ortognática. Mulher, 18 anos, com fissura de palato isolada reparada, foi submetida à cirurgia ortognática para correção da discrepância esquelética maxilomandibular. O exame

▼▼▼▼▼

¹ Hospital de Reabilitação de Anomalias Craniofaciais da Universidade de São Paulo, Seção de Diagnóstico Bucal. Rua Sílvio Marchione, 03-20, 17012-900, Bauru, SP, Brasil. Correspondence to: R Ferlin. E-mail: <rafaferlin@usp.br>.

² Universidade de São Paulo, Faculdade de Odontologia de Bauru. Departamento de Cirurgia. Bauru, SP, Brasil.

▼▼▼▼▼

How to cite this article

Ferlin RF, Pagin O, Pagin BSC, Mello MAB, Yaedú RYF. Implications of anatomical variation of the sphenoid sinus for orthognathic surgery: a case report in cone beam computed tomography. RGO, Rev Gaúch Odontol. 2023;71:e20230030. <http://dx.doi.org/10.1590/1981-86372023003020220100>

de tomografia computadorizada de feixe cônico (TCFC), realizado para planejamento pré-operatório, mostrou grande extensão para as estruturas adjacentes, e com proximidade da parede posterior do seio maxilar e fissura pterigomaxilar bilateralmente. A imagem de TCFC pós-operatória evidenciou o comprometimento do assoalho do seio devido aos fatores relacionados ao transoperatório. Este caso, juntamente com a revisão da literatura, destacou a importância de identificar a variação do seio esfenoidal nos exames de TCFC prévios à cirurgia ortognática, a fim de evitar complicações graves para o paciente, tais como sinusite, hemorragias, formação de mucocelos ou, até mesmo, envolvimento intracraniano.

Termos de indexação: Variação anatômica. Fissura palatina. Tomografia computadorizada de feixe-cônico. Cirurgia ortognática. Seio esfenoidal.

INTRODUCTION

The sphenoid sinus (SS) is located in the body of the sphenoid bone, at the central base of the skull [1]. Also, it is related to the carotid artery; optic nerve; maxillary nerve and vidian nerve [2]. It is the paranasal sinus that has the most variation in relation to the degree of pneumatization [3]. There are many classifications in the literature for the degree of SS'variation to facilitate access to the sellar region and endoscopic surgeries [3,4]. A recent study classified the SS into conchal, pressellar, incomplete sellar and complete sellar; also, to the clivus region: subdorsal, dorsal, occipital, and combined (dorsal + occipital) [3]. Finally, they are classified in relation to the lateral extension: pterygoid; greater wing of sphenoid; full lateral and lesser wing [3]. These variations can be identified in the cone-beam computed tomography (CBCT) [5-7].

The greater the degree of SS'pneumatization, the closer it will be to the adjacent anatomical structures [1,7]. If this SS extension occurs near the pterigomaxillary region, it should be taken into consideration during orthognathic surgery, because it is common to perform Le fort I osteotomy and pterygomaxillary disjunction to correct anteroposterior, vertical and transversal alterations of the maxila [8]. According to the literature, the maneuver of separation of the pterygomaxillary junction is the most critical moment and favorable to iatrogenies, because the surgeon does not have a direct view of this region [8-10]. Thus, it is important to evaluate in CBCT scans the size, location, and integrity of the walls of the SS, as well as the condition of the surrounding structures and the presence of any spatial invasion prior to surgeries performed near this region [7].

Therefore, the cleft lip and palate (CLP) is the most common craniofacial anomaly [11]. These individuals have more anatomical variations close to the cleft region and perform different surgeries during the rehabilitation process, like orthognathic, made to correct the maxillomandibular discrepancy [11]. A recent systematic review showed that the occurrence rate of orthognathic surgery was 38.1% in individuals with bilateral cleft lip and palate (BCLP), 30.2% for unilateral cleft lip and palate (UCLP) 4.4% for isolated cleft palate (ICP), and 1.8% for patients with isolated cleft lip (ICL), after the orofacial cleft repair [12]. The identification of SS'pneumatization in individuals with and without CLP is important to avoid complications in surgical procedures, including hemorrhages, sinus infections, formation of mucocelos and can be from a surgical approach with inadequate planning [8,13]. Also, infections can occur for the intracranial region, representing a higher risk for the individual, such as: subdural abscess; extradural abscess; brain abscess; meningitis; thrombophlebitis or osteomyelitis [14].

Thus, the purpose of this case report is to show the relationship between SS'variation and orthognathic surgery in patient with ICP (without associated syndrome). In addition, it will be highlighted the complications that may arise from this relationship.

CASE REPORT

A 18year-old woman, with ICP repaired, was submitted to orthognathic surgery to correct the maxillomandibular skeletal discrepancy. A Le Fort I osteotomy was performed for maxillary advancement as the patient had a Class III skeletal pattern. The patient was submitted to CBCT for preoperative planning and immediate postoperative evaluation. The CT scanner used was the i-CAT Next Generation® (Imaging Sciences International, Hatfield, PA, USA). All the images were obtained with the parameter of 120 kVp, field of view of 17 cm and voxel of 0.4 mm. The exams obtained were analyzed using the I-Cat Vision® software (Imaging Sciences International, Hatfield, PA, USA). The CBCT images, stored in DICOM

format (Digital Imaging and Communications in Medicine) were used for virtual planning in the software Dolphin 3D (Dolphin Imaging & Management Solutions, Chatsworth, California, version 11.8).

In the preoperative CBCT image (figure 1a-c), the SS hypodense with pneumatization was found. It was observed the proximity to the posterior wall of the maxillary sinus and pterygomaxillary fissure bilaterally (figure 1a). This extension was classified as full lateral type (figure 1b) with bilateral anterior clinoid process involvement (Figure 1b-C). Also, reached to the greater and lesser wings (figure 1b-B) as well to the pterygoid process of the sphenoid bone (figure 1b-A). In the sagittal reconstruction of the CBCT is possible to identify the SS'variation as being of the sellar type (figure 1c).

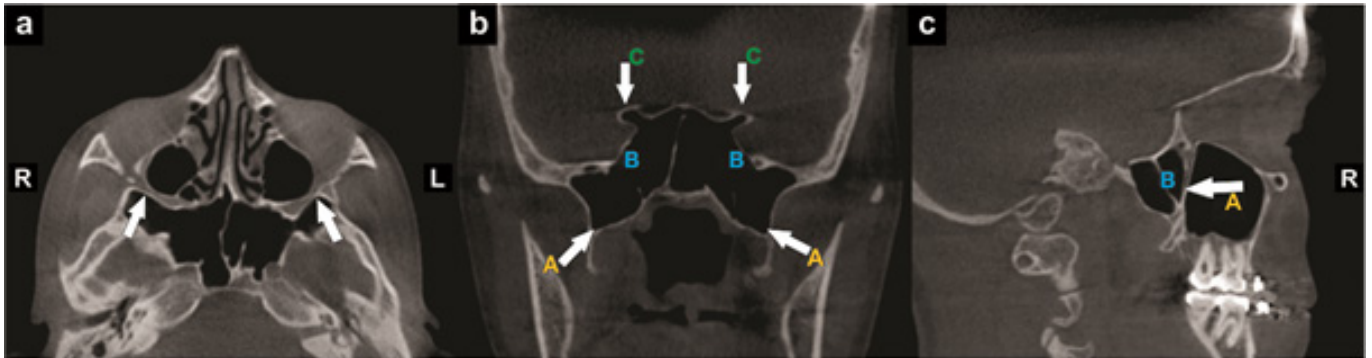


Figure 1. Preoperative CBCT exam for orthognathic surgery: a- axial reconstruction showing the lateral SS'extension, approaching the posterior wall of the maxillary sinus and pterygomaxillary fissure bilaterally; b- coronal reconstruction showing the SS'extension of the full lateral type, involving: (A) pterygoid processes, (B) greater and lesser wings of the sphenoid bone bilaterally + (C) extension to bilateral anterior clinoid process and; c- sagittal reconstruction, showing the SS'pneumatization of the type sellar and (A) approximation of the posterior wall of the maxillary sinus (A) and (B) SS septation of right side.

In the immediate postoperative CBCT image (figures 2a-c), it was found a hyperdense image of the SS only on the right side with compromise of the floor, due to the factors related to the transoperative period. Among these, can be the greater force applied in the right side associated with greater resistance at the moment of pterygomaxillary disjunction, because individuals with CLP have scarring fibrosis areas and bone more sclerotic. In addition, the fixing and immobilizing the plates (forcing the right side more) or the chisel positioning at different heights can also justify this harm. The hyperdense image of the SS is horizontally level and suggests an extravasation liquid content inside (figure 2c-A). On the left side, the procedure was performed with no sphenoid sinus walls involved.

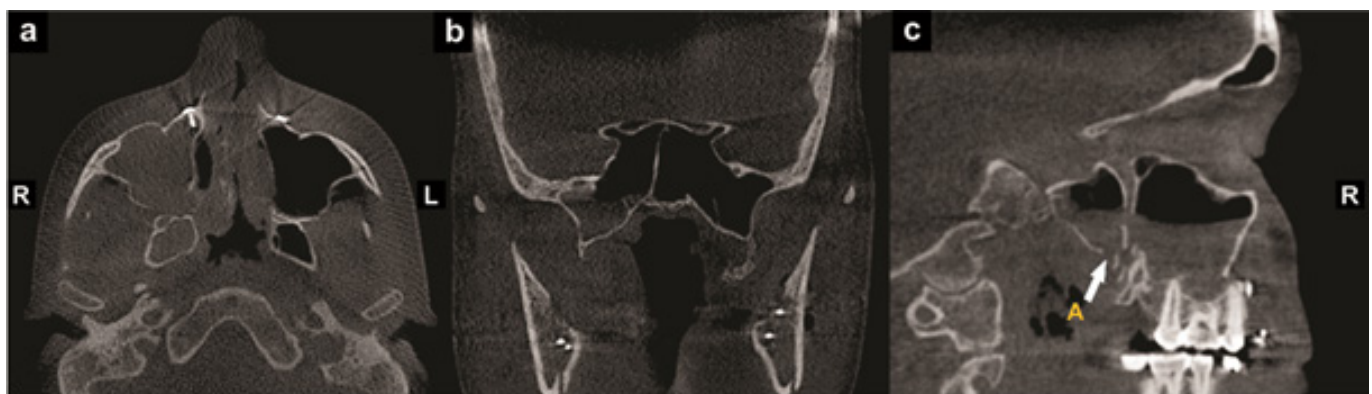

Figure 2. Postoperative CBCT exam for orthognathic surgery, showing the SS'opacification on the right side in multiplanar (a) axial, (b) coronal and (c) sagittal reconstructions. The fracture in the floor of the SS is observed in sagittal reconstruction (c-A).

After a year of clinical follow-up, the patient had no major complications arising from this involvement on the right side of her SS. This case was approved by the Ethical Committee of Hospital for Rehabilitation of Craniofacial Anomalies, Brazil (process number 4.519.255). The Helsinki declaration were followed. The patient signed an informed consent form authorizing the publication of the CBCT exams, as well as the clinical details.

DISCUSSION

This is the first case reported in the literature that makes a connection between orthognathic surgery and SS'variation. As already mentioned, the greater the degree of pneumatization, the closer it is to the adjacent structures and the greater the risk of transoperative complications [1,6]. The first peculiarity of this case was to find the proximity of this variation with the posterior wall of the maxillary sinus and pterygomaxillary fissure bilaterally. This region is targeted by the maxillofacial surgeon during orthognathic surgery, being the pterygomaxillary disjunction and mobilization of the maxila two important steps. This surgery involves the separation of important structures such as: the pyramidal process of the palatine bone, pterygoid plates and the descending palatine artery (in palatine canal) [9]. It is a procedure performed "blindly" and very close to this artery, facilitating an iatrogenesis and the occurrence of hemorrhage [8-10]. As in the present case that the SS is close to the region of the pterygomaxillary disjunction, this hemorrhage can lead to blood leakage into this sinus, generating other complications, such as sinus infections, mucocèles and, even, future intracranial and intravascular complications [13,14].

The second particularity of this case is to involves a patient with ICP. These individuals undergo many surgeries during their rehabilitation process, such as palatoplasty [15]. This is done in childhood and can lead to the formation of scarring fibrosis [15]. Therefore, a study showed that the region of the pterygomaxillary junction may be more sclerotic in these individuals, requiring greater strength at the time of disjunction [16]. If the force exceeds its threshold during this separation, it can lead to a fracture line at the skull-base [16]. This fractures are associated with several critical complications such as intracranial and orbital injuries, cerebrospinal fluid leakage, cranial nerve palsy and vascular injuries [17].

The fact that it is the first reported case that presents complications with orthognathic surgery, becomes a limitation of the present study. However, some authors have already been concerned with researching the SS'variation in patients with CLP. One study found that the group with this anomaly had a lower prevalence of SS'pneumatization for the pterygoid process and greater wings of the sphenoid bone [18]. However, another study found no significant difference between the types of SS'variations for CLP individuals [19]. Recently, a study found the most prevalent presellar classification for individuals with CLP and postsellar and clival without CLP [20]. For the lateral extension, as well the patient in the present case, they found no significant difference in the comparison between the groups [20].

Thus, the identification of these classifications in individuals with and without CLP is very important prior to surgeries that cover your region. The SS drains through a single ostium, called the sphenoethmoidal recess [21]. In case of ostium obliteration, due to local trauma or the presence of blood (as in the present case report), it may cause an impediment to its drainage, leading to the sinus infections. The literature shows some other complications resulting from the involvement of the SS, regardless of being patient with or without CLP. A systematic review showed that the most prevalent pathologies of SS'opacification identified in CBCT were: chronic rhinosinusitis without nasal polyps (28.3%), mucocèles (20.3%), fungal sinusitis (12.5%), malignant neoplasms (7.7%), intracranial lesions (7.0%), benign neoplasms (5.7%), chronic rhinosinusitis with nasal polyps (3.4%), other injuries (4.7%) and cranial neuropathies were present in 16.3% of a total of 1.133 patients [22].

The CBCT was an excellent exam for identifying the SS'pneumatization, as well as for the pre-surgical planning of the present case, as other authors agreed [7]. Although the patient in this case report did not have these serious complications introduced, this could have happened. The maxillofacial surgeon performed a good pre-surgical planning through the CBCT exam and the left side of the SS was not compromised. The aim of this discussion was to alert professionals about the possible complications from the involvement of the SS during a surgical approach close to it.

Thus, the CBCT should be used as a diagnostic tool for this paranasal sinus. It is important to check for the presence of pneumatization, any hyper or hypodense material inside, and its relationship with the structures involved during orthognathic surgery.

CONCLUSION

The SS' pneumatization to the sphenoid bone pterygoid plates, as in the case reported, can lead to transoperative complications resulting from orthognathic surgery, such as: lack of prior planning, fractures and hemorrhages (during surgery), and infections. Therefore, the use of CBCT in the pre-surgical planning of individuals with and without CLP is essential. However, we emphasize that in individuals with CLP, this planning must consider the areas of scar fibrosis and bone sclerosis, because they make the surgical stages more difficult, further compromising the SS and bringing consequences to the patients.

Acknowledgments

This study was financed by the Coordenação de Aperfeiçoamento de Pessoal de Nível Superior - Brazil (CAPES) - Finance Code 001

Collaborators

R Ferlin, BSC Pagin and O Pagin, case report development, manuscript writing/editing, final review. MAB Mello, case report development, final review. RYF Yaedú, selection of the case, development, manuscript editing, final review.

REFERENCES

1. von Arx T, Lozanoff S, Bornstein MM. Extraoral anatomy in CBCT - a literature review. Part 3: retromaxillary region. *Swiss Dent J*. 2020;130(3):216-228.
2. Anusha B, Baharudin A, Philip R, Harvinder S, Shaffie BM. Anatomical variations of the sphenoid sinus and its adjacent structures: a review of existing literature. *Surg Radiol Anat*. 2014;36(5):419-427. <http://dx.doi.org/10.1007/s00276-013-1214-1>
3. Hiremath SB, Gautam AA, Sheeja K, Benjamin G. Assessment of variations in sphenoid sinus pneumatization in Indian population: A multidetector computed tomography study. *Indian J Radiol Imag*. 2018;28(3):273-279. http://dx.doi.org/10.4103/ijri.IJRI_70_18
4. Wang J, Bidari S, Inoue K, Yang H, Rhoton A. Extensions of the sphenoid sinus: a new classification. *Neurosurgery*. 2010;66(4):797-816. <http://dx.doi.org/10.1227/01.NEU.0000367619.24800.B1>
5. Güldner C, Pistorius SM, Diogo I, Bien S, Sesterhenn A, Werner JA. Analysis of pneumatization and neurovascular structures of the sphenoid sinus using cone-beam tomography (CBT). *Acta Radiol*. 2012;53(2):214-219. <http://dx.doi.org/10.1258/ar.2011.110381>
6. Rahmati A, Ghafari R, AnjomShoa M. Normal Variations of Sphenoid Sinus and the Adjacent Structures Detected in Cone Beam Computed Tomography. *J Dent (Shiraz)*. 2016;17(1):32-37.
7. Movahhedian N, Paknahad M, Abbasinia F, Khojatepour L. Cone Beam Computed Tomography Analysis of Sphenoid Sinus Pneumatization and Relationship with Neurovascular Structures. *J Maxillofac Oral Surg* 2021;20(1):105-114. <http://dx.doi.org/10.1007/s12663-020-01326-x>
8. Lanigan DT, Hey JH, West RA. Major vascular complications of orthognathic surgery: hemorrhage associated with Le Fort I osteotomies. *J Oral Maxillofac Surg*. 1990;48(6):561-573. [http://dx.doi.org/10.1016/s0278-2391\(10\)80468-9](http://dx.doi.org/10.1016/s0278-2391(10)80468-9)
9. O'Regan B, Bharadwaj G. Prospective study of the incidence of serious posterior maxillary haemorrhage during a tuberosity osteotomy in low level Le Fort I operations. *Br J Oral Maxillofac Surg*. 2007;45(7):538-542. <http://dx.doi.org/10.1016/j.bjoms.2007.03.006>
10. Ueki K, Hashiba Y, Marukawa K, Nakagawa K, Okabe K, Yamamoto E. Determining the anatomy of the descending palatine artery and pterygoid plates with computed tomography in Class III patients. *J Craniomaxillofac Surg*. 2009;37(8):469-473. <http://dx.doi.org/10.1016/j.jcms.2009.03.010>
11. Lim JT, C., Kogo M, Yamashiro T. Determination of prognostic factors for orthognathic surgery in children with cleft lip and/or palate. *Orthod Craniofac Res*. 2021;24(Suppl 2):153-162. <http://dx.doi.org/10.1111/ocr.12477>

12. Choi KJ, Wlodarczyk JR, Nagengast ES, Wolfswinkel E, Munabi NCO, Yao C, et al. The Likelihood of orthognathic surgery after orofacial cleft repair: a systematic review and meta-analysis. *J Craniofac Surg.* 2021;32(3):902-906. <http://dx.doi.org/10.1097/SCS.00000000000007262>
13. Djambazov KB, Kitov BD, Zhelyazkov CB, Davarski AN, Topalova AR. Mucocele of the Sphenoid Sinus. *Folia Med (Plovdiv).* 2017;59(4):481-485. <http://dx.doi.org/10.1515/folmed-2017-0049>
14. Sadineni RT, Velicheti S, Kondragunta CS, Bellap NC. Multiple Cerebrovascular Complications due to Sphenoid Sinusitis. *J Clin Diagn Res.* 2016;10(11):TD03-TD05. <http://dx.doi.org/10.7860/JCDR/2016/23899.8905>
15. Fudalej P, Katsaros C, Dudkiewicz Z, Offert B, Piwowar W, Kuijpers M, Kuijpers-Jagtman AM. Dental arch relationships following palatoplasty for cleft lip and palate repair. *J Dent Res.* 2012;91(1):47-51. <http://dx.doi.org/10.1177/0022034511425674>
16. Kim JW, Chin BR, Park HS, Lee SH, Kwon TG. Cranial nerve injury after Le Fort I osteotomy. *Int J Oral Maxillofac Surg.* 2011;40(3):327-329. <http://dx.doi.org/10.1016/j.ijom.2010.09.008>
17. Bagnon KL, Hudgins PA. Skull base fractures and their complications. *Neuroimaging Clin N Am.* 2014;24(3):439-465, vii-viii. <http://dx.doi.org/10.1016/j.nic.2014.03.001>
18. Dedeoglu N, Altun O, Kucuk EB, Altindis S, Hatunoglu E. Evaluation of the anatomical variation in the nasal cavity and paranasal sinuses of patients with cleft lip and palate using cone beam computed tomography. *Bratisl Lek Listy.* 2016;117(12):691-696. http://dx.doi.org/10.4149/BLL_2016_133
19. Gümrükçü Z, Bilgir E, Bayrak S, Bayrakdar İ. Evaluation of sphenoid sinus variations by using cone beam computed tomography in patients with cleft lip/palate. *Oral Radiol.* 2020;36(3):248-253. <http://dx.doi.org/10.1007/s11282-019-00401-5>
20. Yalcin ED. Assessment of sphenoid sinus types in patients with cleft lip and palate on cone-beam CT. *Eur Arch Otorhinolaryngol.* 2020;277(4):1101-1108. <http://dx.doi.org/10.1007/s00405-020-05810-5>
21. Yilmaz N, Kose E, Dedeoglu N, Colak C, Ozbag D, Durak MA. Detailed anatomical analysis of the sphenoid sinus and sphenoid sinus ostium by cone-beam computed tomography. *J Craniofac Surg.* 2016;27(6):e549-552. <http://dx.doi.org/10.1097/SCS.0000000000002861>
22. Moss WJ, Finegersh A, Jafari A, Panuganti B, Coffey CS, DeConde A, Husseman J. Isolated sphenoid sinus opacifications: a systematic review and meta-analysis. *Int Forum Allergy Rhinol.* 2017;7(12):1201-1206. <http://dx.doi.org/10.1002/alr.22023>

Received on: 29/11/2022

Approved on: 20/12/2022

Assistant editor: Luciana Butini Oliveira

ERRATA

No artigo <Implications of anatomical variation of the sphenoid sinus for orthognathic surgery: a case report in cone beam computed tomography>, com número de DOI: <<https://doi.org/10.1590/1981-86372023003020220100>> publicado no periódico <RGO, Revista Gaúcha de Odontologia>, <71>:<e20230030>, na página <1>:

Onde se lia:

Pereira JLSH, Silva DFB, Souza RCV, Silva Filho TJ, Dias IJ, Gomes DQC. Implications of anatomical variation of the sphenoid sinus for orthognathic surgery: a case report in cone beam computed tomography. RGO, Rev Gaúch Odontol. 2023;71:e20230030.<http://dx.doi.org/10.1590/1981-86372023003020220100>

Leia-se:

Ferlin RF, Pagin O, Pagin BSC, Mello MAB, Yaedú RYF. Implications of anatomical variation of the sphenoid sinus for orthognathic surgery: a case report in cone beam computed tomography. RGO, Rev Gaúch Odontol. 2023;71:e20230030.<http://dx.doi.org/10.1590/1981-86372023003020220100>