

Microneurorrhaphy of the mentonian nerve during the removal of a giant odontoma

Microneurorrafia do nervo mentoniano durante a remoção de um odontoma gigante

André Lustosa de **SOUZA**¹  0000-0003-2793-2118

Emerson Filipe de Carvalho **NOGUEIRA**²  0000-0002-4560-7733

Paulo Alexandre da **SILVA**³ 

Ricardo José de Holanda **VASCONCELLOS**²  0000-0002-7934-5743

Airton Vieira Leite **SEGUNDO**⁴  0000-0002-6105-4753

ABSTRACT

The aim of this article is to describe a surgical technique of option in the treatment of large tumors in jaw whose risk of accidental rupture of the mental nerve presents increased by the report of a patient with mandibular giant case of odontoma. The option for intraoral access, intentional sectioning of the mentonian nerve, followed by resection of the tumor and the installation of fixation material, which in turn was followed by microneurorrhaphy. A surgical microscope was used to perform microneurorrhaphy of the mentonian nerve with Nylon 8-0 wire. The evolution of the patient was satisfactory, with no complaints or complications. A mechanical assessment for torque and pressure was conducted using wire with a diameter of 1.0mm and 2.5mm, respectively. The sensitivity of the patient's lower lip returned to normal within 120 days of the surgery. Significant enucleations or resections in the mandible involves a great risk of accidental nervous rupture, with permanent sequelae. In these cases, the intentional section of the mentonian nerve, followed by microneurorrhaphy, is a viable option, particularly in young patients. The results of this procedure tend to be more predictable than accidental nervous ruptures.

Indexing terms: Mandibular osteotomy. Neurosurgical procedures. Odontoma.

RESUMO

O objetivo deste artigo é descrever uma técnica cirúrgica de opção no tratamento de grandes tumores na mandíbula cujo risco de ruptura acidental do nervo mental apresenta aumento pelo relato de uma paciente com extenso odontoma complexo em corpo mandibular. A opção foi pelo o acesso intraoral, corte intencional do nervo mentoniano, seguida da ressecção do tumor e da instalação de material de fixação, que por sua vez foi seguida pela microneurorrafia do nervo mentoniano. Um microscópio cirúrgico foi utilizado para realizar

▼ ▼ ▼ ▼ ▼

¹ Hospital Regional do Agreste, Residência em Cirurgia e Traumatologia Bucomaxilofacial. Rod. BR-232, Km 130, s/n., 55002-970, Indianópolis, PE, Brasil. Correspondência para / Correspondence to: AL SOUZA. E-mail: <andrelustosa19@hotmail.com>.

² Universidade de Pernambuco, Cirurgia e Traumatologia Bucomaxilofacial. Recife, PE, Brasil.

³ Faculdade São Leopoldo Mandic, Instituto de Pesquisas São Leopoldo Mandic, Dor Orofacial. Campinas, SP, Brasil.

⁴ Universidade Federal da Paraíba, Departamento de Estomatologia. João Pessoa, PB, Brasil.

▼ ▼ ▼ ▼ ▼

How to cite this article

Souza AL, Nogueira EFC, Silva PA, Vasconcellos RJH, Segundo AVL. Microneurorrhaphy of the mentonian nerve during the removal of a giant odontoma. RGO, Rev Gaúch Odontol. 2019;67: e20190019. <http://dx.doi.org/10.1590/1981-86372019000193518>

microneurrafia do nervo mentoniano com fio Nylon 8-0. A evolução do paciente foi satisfatória, sem queixas ou complicações. Uma avaliação mecânica para torque e pressão foi realizada usando fio com um diâmetro de 1,0 mm e 2,5 mm, respectivamente. A sensibilidade do lábio inferior do paciente voltou ao normal dentro dos 120 dias da cirurgia. Enucleações significativas ou ressecções na mandíbula envolvem um grande risco de ruptura nervosa acidental, com seqüelas permanentes. Nestes casos, a seção intencional do nervo mentoniano, seguida de microneurrafia, é uma opção viável, particularmente em pacientes jovens. Os resultados deste procedimento tendem a ser mais previsíveis do que as rupturas nervosas acidentais.

Termos de indexação: Odontoma. Osteotomia mandibular. Procedimentos neurocirúrgicos.

INTRODUCTION

According to the World Health Organization, odontomas are benign, mixed, odontogenic tumors, which are composed of mineralized dental tissue that can be epithelial or mesenchymal [1]. According to the literature, they are very common, representing approximately 22% of all odontogenic tumors [2]. This anomaly appears as a result of early disorders that affect the tooth germ. It has been accepted that an odontoma is more closely linked to a hamartomatous malformation than a neoplasia [1].

Odontomas are usually asymptomatic and are almost always discovered during routine radiographs or radiographs to determine the reason for a failed tooth eruption [3,4]. Occasionally, signs and symptoms appear as a result of their presence. In general, these include the retention of deciduous teeth, the non-eruption of permanent teeth, pain, the expansion of the cortical bone and dental displacement [5]. Odontomas are relatively small and rarely exceed the size of a tooth. Consequently, most odontomas are asymptomatic and are only detected in routine panoramic radiographs [6]. However, large odontomas can measure up to 6 cm or more and cause maxillary expansion, although reports of these are scarce in the literature [7].

The treatment of odontomas involves their surgical removal, which generally leads to a favorable prognosis. Recurring cases are rare, and bone repair is relatively easy to perform [4]. Small and medium-sized odontomas can usually be removed without great difficulty, depending on their proximity to adjacent structures. However, access to large odontomas can be problematic, particularly in cases involving thick or dense bone [8] that is close to important structures.

Damage to the lower alveolar nerve can occur during the surgical removal of tumors, if the pathological process is located in the path of the nerve [9]. Patients who experience these nervous injuries often complain of sensory disorders that affect their speech, chewing abilities, swallowing and social interaction [10].

One method of correcting nervous damage is through microneurraphy, which involves the careful passage of three independent sutures with micro-instruments, which are used in the epineurium of the sectioned extremities of the nerve, promoting the tension-free approximation of stumps [11]. Sensory recovery is dependent on several factors, including the extent of the injury, the quality of axonal growth, the orientation of nerve growth and the reorganization process of the cerebral cortex [8].

The aim of this study was to present an atypical clinical case of a complex odontoma, with extensive involvement of the mandibular body, which was removed through intraoral access, in association with neurorraphy of the mentonian nerve.

CASE REPORT

A 14-year old female patient was sent to the Oral and Maxillofacial Surgery Department for an assessment of a jaw injury. Her medical history confirmed a previous hospital stay due to an odontogenic infection. During this period, radiographic examinations were requested and an extensive injury was found on the left mandibular body. In the physical examination, it was possible to confirm a discreet increase in volume in the region of the left mandibular body, with a clear bulging of the cortical bone on palpation, as well as intact mucosa, with a normal coloration.

The image examinations confirmed a well-defined radiopaque image in the region of the left mandibular body, without signs of infiltration in the adjacent bone, associated with an impacted molar (figure 1). Based on the clinical and radiographic results, an initial diagnosis of complex odontoma was made.

The surgical planning involved intraoral access, section of the mentonian nerve (to enable the installation of the reconstruction plate) and the removal of the injury through neurorraphy of the nerve. Initially, the patient was prototyped to model the reconstruction plate while

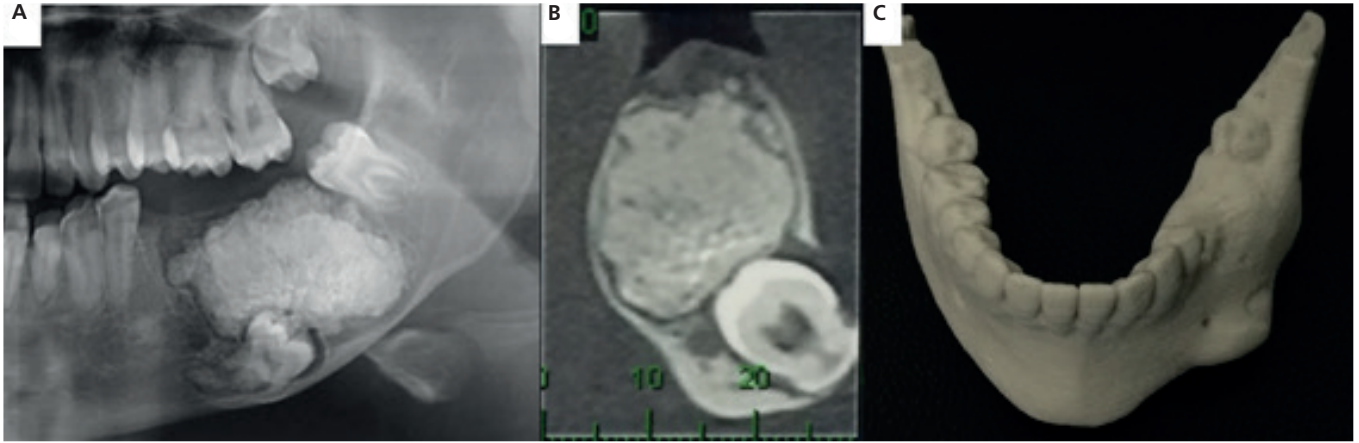


Figure 1. Panoramic radiography and cone beam tomography, respectively. Note the extensive injury in the left mandibular body, associated with the impacted tooth, and the relationship of the tooth with the foundation of the mandible and the mandibular canal.

reducing the surgical time. The procedure was carried out under general anesthetic, starting with an incision in the vestibular mucosa, which extended from the left ramus to the parasymphysis on the right side, followed by displacement, isolation of the mentonian nerve and sectioning. The vestibular cortex in the body of the mandible and the injury were removed (figure 2). Subsequently, the reconstruction plate (2.4 locking) was installed to prevent pathological fractures. A surgical microscope was used to perform microneurorrhaphy of the mentonian nerve with Nylon 8-0 wire (Ethicon®, São Paulo, Brazil) (figure 3). Finally, the operative wound was sutured using Vicryl 3-0 wire (Ethicon®, São Paulo, Brazil).

The evolution of the patient was satisfactory, with no complaints or complications. A mechanical assessment for torque and pressure was conducted using wire with a diameter of 1.0mm and 2.5mm, respectively. The sensitivity of the patient’s lower lip returned to normal within 120 days of the surgery.

DISCUSSION

Odontomas are the most common form of odontogenic tumors, representing 22% of all recorded cases [2]. They are classified as mixed as they develop from the epithelium and the odontogenic ectomesenchyme [5].

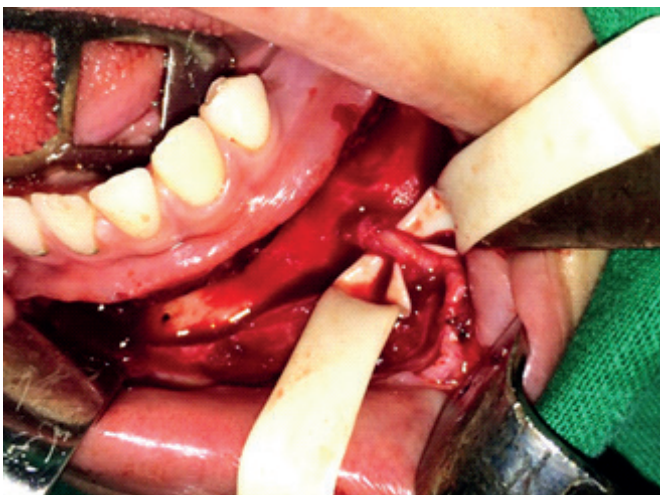

Figure 2. Dissection of the mentonian nerve (intentional section) to enable the intraoral installation of the reconstruction plate.

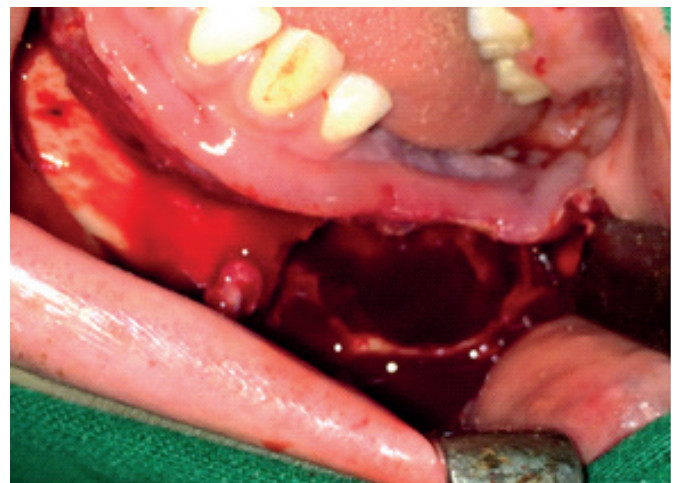


Figure 3. Trans-surgical appearance after the complete removal of the injury.

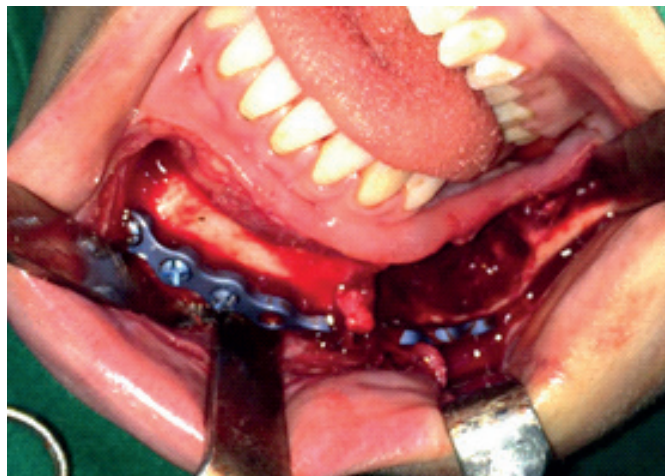


Figure 4. Intraoral installation of the pre-molded reconstruction plate.

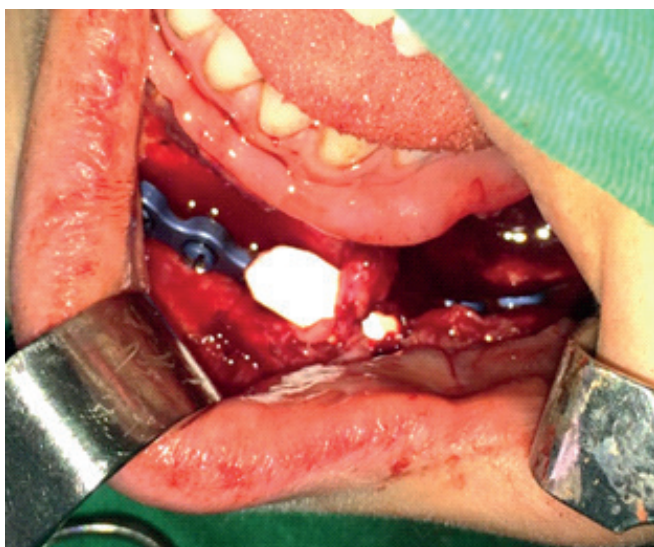


Figure 5. Microneurotomy of the mentonian nerve.

Depending on their characteristics, odontomas can be classified as complex or compound. Compound odontomas are formed by multiple calcified structures, similar to rudimentary or miniature teeth. Complex odontomas involve an amorphous mass of mineralized tissue, with no anatomical similarities to teeth. [2].

Regardless of the sub-type, most cases involving this type of tumor occur before the third decade of an individual's life, and the most common form is the complex odontoma in the posterior region of the mandible [12]. The present study corroborates these results, given that the patient was 14 years old and the tumor was located

in the mandibular body, while there was also an impacted tooth in the vicinity of the complex odontoma. This relationship with impacted teeth was also demonstrated in a retrospective study by Seo-Young Na [13] in which 61.6% of the 73 cases of odontoma studied involved the impaction of adjacent permanent teeth.

This type of odontogenic tumor is usually asymptomatic [5]. However, in the case report presented herein, the patient exhibited diffuse edema in the left sub-mandibular and sub-mentonian spaces, associated with trismus. These symptoms may have been caused by the odontogenic infection of the tumor by dental element 35, which was extensively decayed. Perumal et al. [14] reported a similar case of extensive mandibular odontoma with similar symptoms, as well as facial asymmetry, cellulite and extraoral exposure.

Large complex odontoma of the mandible are rare, but they can be removed through intra- or extraoral access, or through exposure via buccal, lingual or sagittal osteotomy [5]. Adequate surgical exposure is required in order to perform the resection and reconstruction of pathological injuries [15]. Extraoral access to the posterior region of the mandible can damage the branches of facial nerves and cause scarring [5]. The greatest disadvantage of an intraoral approach is the reduced access and visibility, although it does reduce scarring and avoid facial nerve injuries [10]. Therefore, we opted for intraoral access, in association with the intentional transection of the ipsilateral mentonian nerve, in an attempt to establish a predictable prognosis, when compared with the accidental rupture of the nerve. When this happens during the removal of a tumor or the placement of fixation material, it can hinder the treatment, due to the fact that nerve sectioning may occur in an unfavourable location, or the irregular disruption of nerve fibers may take place, thereby worsening the prognosis. In younger patients (the patient analyzed herein was only 14), nervous recovery tends to be fast, with a favorable prognosis.

In order to avoid facial scarring and preserve both the facial structure and the mandibular function, Lehman et al. [16] performed conservative intraoral enucleation on a seven year old child who had a giant odontoma in the mandible. Unlike the case presented herein, these authors confirmed that the patient exhibited adequate remaining lingual bone. A similar case was described by Perumal et al. [14], who reported the successful intraoral treatment of an odontoma of a similar size and justified the absence

of fixation material in the patient's infection, despite the relatively small amount of bone remaining.

After the removal of an intra osseous pathology, the resulting increase in mandibular frailty, as well as the risk of pathological fracture, has led several authors to use a maxillo-mandibular block for a period of four weeks [5]. Others prefer load-bearing fixation using a reconstruction plate with at least three screws on each side of the bone defect [15]. When seeking to minimize the risk of fracture and discomfort caused by the maxillo-mandibular block, the treatment of choice in the abovementioned case involved the use of a reconstruction plate.

Nerve trauma is a common pathology. Since 1873, when neurorrhaphy was first introduced by Hueter, great advances have been achieved in the repair of this type of injury [17].

End-to-end neurorrhaphy is a technique that involves the careful passage of three independent sutures through the epineurium of the sectioned nerve ends using micro-instruments, promoting the tension-free approximation of stumps [18]. In a study by Bagheri [10], the epineurium of the injured lingual nerves was sealed with monofilament wire (8-0 or 10-0), similar to the current study, in which Nylon 8-0 (Ethicon, São Paulo, Brazil) was used in the neurorrhaphy of the mentonian nerve, after the removal of the odontogenic tumor. The microsutures are distributed circumferentially, beginning in the 12 o'clock position. This is followed by further sutures four and eight hours later [19]. Flaws of less than 1 cm can be corrected in this manner [20]. Immediate repair through microrrhaphy is recommended when a nervous transection (neurotmesis) is observed [19]. This occurred intentionally in the present case report and was followed by transection of the mentonian nerve, which facilitated the intraoral removal of the tumor and the insertion of the fixation material.

Studies with animals have confirmed that nerve cells can regenerate and reestablish functional bonds with distal nerves after microneurosurgery [9]. Zuninga et al. [21] analyzed a group of five rats that were submitted to the bilateral intentional section of mental nerves. After 28 days of microneurorrhaphy, the recovery of sensitivity in the regions innervated by these nerves was satisfactory. Although the literature concerning the repair of the lower alveolar nerve is limited, a number of recent studies have shown that patients respond well to surgical treatment [10].

A study conducted by Pogrel [22] reported that more than 50% of patients that were submitted to microneurorrhaphy of the lower alveolar nerve and the lingual nerve (traumatized during extractions of third lower molars) experienced a sensory improvement after the operation. Lam et al. [23] reported that more than 55% of the patients treated for the surgical repair of the lower alveolar nerve responded positively (good to excellent) in the post-operative period.

Bagheri et al. [10] analyzed a group of 167 patients who were submitted to the microsurgical repair of the lower alveolar nerve after trauma caused by the extraction of impacted teeth from the mandible. The authors found that 81.7% of the participants reported a satisfactory improvement in their neurosensory function within 12 months of the operation. In another study, Leung et al. [24] performed microneurosurgery on moderate and severe injuries of the lower alveolar and lingual nerves, and obtained a 100% success rate for sensory recovery within six months of the procedure.

The patient from the case presented herein is currently in the advanced stage of the resolution of postoperative paresthesia, similar to an earlier study [19], in which the inferior alveolar nerve, with complete transection after osteotomies of the mandible, exhibited excellent results one year after being repaired by neurorrhaphy.

CONCLUSION

In conclusion, although the treatment of odontomas generally leads to a satisfactory prognosis, extensive injuries can be a challenge for oral and maxillofacial surgeons. Significant enucleations or resections in the mandible, followed by the intraoral installation of reconstruction plates often involves a great risk of accidental nervous rupture, with permanent sequelae. In these cases, the intentional section of the mentonian nerve, followed by microneurorrhaphy, is a viable option, particularly in young patients. The results of this procedure tend to be more predictable than accidental nervous ruptures.

Collaborators

AL SOUZA participated in the study contributing in the writing-original draft and visualization. EFC NOGUEIRA and RJH VASCONCELLOS contributed in the writing-review & editing. PA SILVA and AVL SEGUNDO participated in the conceptualization, supervision and writing-review & editing

REFERENCES

1. Bagewadi SB, Kukreja R, Suma GN, et al. Unusually large erupted complex odontoma: A rare case report. *Imaging Sci Dent*. 2015;45(1):49-54. doi: 10.5624/isd.2015.45.1.49
2. Reddy GS, Reddy GV, Sidhartha B, Sriharsha K, Koshy J, Sultana R. Large complex odontoma of mandible in a young boy: a rare and unusual case report. *Case Rep Dent*. 2014;2014:854986. doi: 10.1155/2014/854986.
3. Vengal M, Arora H, Ghosh S, Pai KM. Large erupting complex odontoma: a case report. *J Can Dent Assoc*. 2007;73(2):169-73.
4. Serra-Serra G, Berini-Aytés L, Gay-Escoda C. Erupted odontomas: A report of three cases and review of the literature. *Med Oral Patol Oral Cir Bucal*. 2009;14(6):E299-303.
5. Chrcanovic BR, Jaeger F, Freire-Maia B. Two-stage surgical removal of large complex odontoma. *Oral Maxillofac Surg*. 2010;14(4):247-52. doi: 10.1007/s10006-010-0206-0.
6. Philipsen HP, Reichart PA, Praetorius F. Mixed odontogenic tumours and odontomas. considerations on interrelationship. Review of the Literature and Presentation of 134 New Cases of Odontomas. *Oral Oncol*. 1997;33(2):86-99.
7. Neville BW, Damm DD, Allen CM, Bouquot J. Odontogenic cysts and tumors. In: Neville BW, Damm DD, Allen CM, Bouquot J. *Oral and maxillofacial pathology*. 2a ed. Philadelphia - EUA: WB Saunders; 2002. p. 631–632.
8. Korpi JT, Kainulainen VT, Sándor GKB, et al. Removal of large complex odontoma using the Le Fort I osteotomy. *J Oral Maxillofac Surg*. 2009;67(9):2018-21. doi: 10.1016/j.joms.2009.04.105.
9. Strauss ER, Zicarrardi VB, Janal MN. Outcome assessment of inferior alveolar inferior nerve microsurgery: A retrospective Review. *J Oral Maxillofac Surg*. 2006 Dec;64(12):1767-70.
10. Bagheri SC, Meyer RA, Cho SH, Thoppay J, Khan HA, Steed MB. Microsurgical repair of the inferior alveolar nerve: success rate and factors that adversely affect outcome. *J Oral Maxillofac Surg*. 2012;70(8):1978-90. doi: 10.1016/j.joms.2011.08.030.
11. Curtis NJ, Owen E, Walker DM, et al. Comparison of microsuture, interpositional nerve graft, and laser solder weld repair of the rat inferior alveolar nerve. *J Oral Maxillofac Surg*. 2011;69(6):e246-55. doi: 10.1016/j.joms.2011.02.007.
12. Oliveira BH, Campos V, Marçal S. Compound odontoma-diagnosis and treatment: three case reports. *Pediatr Dent*. 2001;23(2):151-7.
13. An SY, An CH, Choi KS. Odontoma: a retrospective study of 73 cases. *Imaging Sci Dent*. 2012;42(2):77-81. doi: 10.5624/isd.2012.42.2.77.
14. Perumal CJ, Mohamed A, Singh A, Noffke CE. Sequestering giant complex odontoma: a case report and review of the literature. *J Maxillofac Oral Surg*. 2013;12(4):480-4. doi: 10.1007/s12663-010-0148-y.
15. Haggerty CJ, Laughlin RM. *Atlas of operative oral and maxillofacial surgery*. Hoboken: John Wiley & Sons, Inc. 2015.
16. Lehman H, Lustrmann J, Regev E. Removal of an extensive mandibular odontoma using an intraoral approach. *Quintessence Int*. 2013;44(6):425-8. doi: 10.3290/j.qi.a29181.
17. Castaldo JE, Ochoa JL. Mechanical injury of peripheral nerves: fine structure and dysfunction. *Clin Plast Surg*. 1984;11(1):9-16.
18. Curtis NJ, Owen E, Walker DM, Zoellner H. Comparison of microsuture, interpositional nerve graft, and laser solder weld repair of the rat inferior alveolar nerve. *J Oral Maxillofac Surg*. 2011;69(6):e246-55. doi: 10.1016/j.joms.2011.02.007.
19. Tay ABG, Poon CY, Teh LY. Immediate repair of transected inferior alveolar nerves in sagittal split osteotomies. *J Oral Maxillofac Surg*. 2008;66(12):2476-81. doi: 10.1016/j.joms.2008.06.062.
20. Coulthard P, Kushnerev E, Yates JM, Walsh T, Patel N, Bailey E. Interventions for iatrogenic inferior alveolar and lingual nerve injury. *Cochrane Database Syst Rev*. 2014;(4):CD005293. doi: 10.1002/14651858.CD005293.
21. Zuniga JR, O' Connor B. Primary and secondary microneuroanastomotic repair of the mental nerve in the rat. *Int J Oral Maxillofac Surg*. 1987;16(4):465-72.
22. Pogrel MA. The results of microneurosurgery of the inferior alveolar and lingual nerve. *J Oral Maxillofac Surg*. 2002;60(5):485-9.
23. Lam NP, Donoff RB, Kaban LB, Dodson TB. Patient satisfaction after trigeminal nerve repair. *Oral Surg Oral Med Oral Pathol Oral Radiol Endod*. 2003;95(5):538-43.
24. Leung YY, Cheung LK. Longitudinal treatment outcomes of microsurgical treatment of neurosensory deficit after lower third molar surgery: a prospective case series. *PLoS One*. 2016;11(3):e0150149. doi: 10.1371/journal.pone.0150149.

Received on: 24/9/2018

Final version resubmitted on: 6/11/2018

Approved on: 21/12/2018