

Evaluation of the cephalometric centroid point in individuals before and after the pubertal growth peak

Avaliação do comportamento do ponto cefalométrico centróide em pacientes antes e após o pico de crescimento da puberdade

Joana Seung Ae LEE¹  0000-0003-4661-8992

Hideo SUZUKI¹  0000-0002-7045-7095

Alana Binda Silva COSTA¹  0000-0001-7726-1311

Aguinaldo Silva GARCEZ¹  0000-0003-2037-7211

Selly Sayuri SUZUKI¹  0000-0001-7493-746X

ABSTRACT

Objective: The purpose of this study was to evaluate the behavior of the Centroid point, known as the geometric center of the face, before and after the growth peak using lateral cephalometric x-ray. **Methods:** Sample consisted of 40 patients before and after pubertal peak of growth selected from the archive of the São Leopoldo Mandic Institute and Research Center, Campinas, Brazil. Anatomical structures, reference points, lines and planes were traced, and posteriorly a superimposition was performed using the palatal plane and a line perpendicular to this passage through the most posterior point of the pterygomaxillary fossa as reference. Later, the distance between the two centroid points (before and after the peak of puberty) was measured using the digital caliper, both horizontally and vertically. The palatal plane (x-axis) and a line perpendicular to this passage through the most posterior point of the pterygomaxillary fossa (y-axis) were chosen because they undergo minimal changes during growth. **Results:** No significant difference on the location of Centroid points on both X and Y axis ($p > 0.05$) were observed between before and after the growth peak cephalometric tracings, showing an average change in positioning of 0.36mm on the X axis and 0.37mm on the Y axis. **Conclusion:** For this reason, this point can be indicated to be used clinically as a stable reference to evaluate craniofacial growth while performing superimposition methods.

Indexing terms: Cephalometry. Growth. Orthodontics.

RESUMO

Objetivo: O objetivo deste estudo foi utilizar telerradiografias laterais de pacientes antes e depois do pico de crescimento, e realizar sobreposições de desenhos cefalométricos para avaliar o comportamento do ponto Centróide, o centro geométrico da face. **Métodos:** Foram selecionadas telerradiografias de norma lateral de 40 pacientes tomadas antes e depois de seu pico de puberdade do acervo de Ortodontia do Centro de Pesquisas Odontológicas São Leopoldo Mandic, na cidade de Campinas. As estruturas e traçados cefalométricos devidamente desenhados, foram sobrepostos tendo como referência estável o plano palatal e a linha perpendicular a esta que passe pelo ponto mais posterior da fossa pterigomaxilar. Em seguida foi medida a distância entre os dois pontos centróides

▼ ▼ ▼ ▼ ▼

¹ Faculdade São Leopoldo Mandic, Instituto de Pesquisas São Leopoldo Mandic, Departamento de Ortodontia. Rua Dr. José Rocha Junqueira 13, 13045-755, Swift, Campinas, SP, Brasil. Correspondence to: JSA LEE. E-mail: <leejoanasa@gmail.com>.

▼ ▼ ▼ ▼ ▼

How to cite this article

Lee JSA, Suzuki H, Costa ABS, Garcez AS, Suzuki SS. Evaluation of the cephalometric centroid point in individuals before and after the pubertal growth peak. RGO, Rev Gaúch Odontol. 2022;70:e20220002. <http://dx.doi.org/10.1590/1981-86372022000220190144>

(antes e após o pico de puberdade) por meio de paquímetro digital tanto no sentido horizontal quanto no vertical. O plano palatal (eixo x) e a linha perpendicular a esta que passe pelo ponto mais posterior da fossa pterigomaxilar (eixo y) foram escolhidos por sofrerem mínimas alterações nas suas direções durante o crescimento. **Resultados:** Não foi observada diferença estatisticamente significativa na localização dos pontos Centróides em ambos os eixos X e Y ($p>0,05$) quando comparou-se os traçados antes e depois do pico de crescimento, mostrando uma alteração, em média, no posicionamento de 0,36mm no Eixo X e 0,37mm no Eixo Y. **Conclusão:** Assim, este ponto pode ser utilizado como referência estável para avaliação do crescimento craniofacial nas sobreposições.

Termos de indexação: Cefalometria. Crescimento. Ortodontia.

INTRODUCTION

The radiographic cephalometric method represented a major technological advance in Orthodontics, not only enhancing orthodontic diagnostic but also treatment planning allowing the study of changes on facial structures due to the growth and development of the patient. Cephalometric tracings of the same patient can be superimposed on areas of the skull base that do not suffer any or has minimal change on different time points, therefore serving as a stable reference to assess and perform measurements on teeth, maxilla and mandible, and facial structures [1]. To obtain quantitative and qualitative analyzes of the results of orthodontic treatment, which was previously done only through plaster models or non-standard radiographs [2].

The emergence of cephalometric analyzes allowed clinicians to better understand the craniofacial growth, pattern, and direction of the growth, to identify the individual's facial pattern, to study growth and development of distinct bone components at the skull and face, to analyze facial bone structures, relating it to basal bone and tooth position, to assess the soft tissue profile, as well as to help clinicians to determine the possibilities and limitations of orthodontic treatment [3].

For the cephalograms to be correctly superimposed, it is necessary to choose a certain orientation method based on points or areas located in regions with no growth, many methods indicate the use of skull basal bone as a reference [4]. In addition, anatomical structures that are easily visualized and show accuracy on the x-ray should be chosen [5].

The Centroid point, known as the geometric center of the face, is found by transforming the facial structure into a geometric figure such as a triangle or polygon and has been recommended for individual assessment of the face [6], since the Centroid point tend to show minimal changes during an increase of the shape or sides of the triangle or polygon, i.e, minimal changes during facial growth of the patient [7]. Thus, this method allows cephalomorphic and cephalometric evaluation of skeletal discrepancies without susceptibility of changes in the patient's head position during radiographic taking or variation in intracranial reference points [8].

To find the Centroid point, facial bone structure needs to be redefined into a polygon shape as so the Sella-Nasion line establishes the upper limit of the face; the posterior facial height (Sella-Gonion) represents the posterior limit of the face; the mandibular plane (Gonion-Gnathion) determines the lower limit and the facial height and lastly Nasion-Gnathion line sets the anterior limit of the face, in order to form the three-dimensional polygon. The geometric center of the polygon, thus the Centroid point, is found by connecting two lines draw from the midpoints of each side of the polygon (anterior to posterior and upper to lower) and their intersection determines the point called Centroid [9].

By drawing a horizontal line from the Centroid point to Subnasal point (both center of the face, hard and soft tissue) and later, a vertical perpendicular line in front of the profile, it is possible to use this vertical line, based on Centroid point, to estimate head position similar to the natural and reproducible rest head position of the individual [9]. The natural position of the head (NHP) obtained in photographs has been advocated as a reliable extracranial reference to avoid traditional craniofacial references which can lead to misinterpretation, particularly to the maxillomandibular relationship [10]. For this reason, a standardized method to obtain a correct position of the head is essential to accurately assess and diagnose the craniofacial structures and for longitudinal comparisons [11].

Cephalometric superimposition is a technique that aims to provide information on the changes that resulted from the craniofacial growth and/or progression of orthodontic/orthopedic treatment. For a method to be reliable the

use of points or regions considered stable is essential. Thus, since previous studies have recommended using the Centroid point for cephalometric analyzes [7], the purpose of this study was to evaluate the location of Centroid point, based on the method described above, by using lateral cephalograms of individuals taken before and after the pubertal peak of growth, in order to validate its use a reliable reference for superimposition method in growing patients.

METHODS

Sample selection

This prospective study was conducted after the approval of the Ethical Committee Board from Sao Leopoldo Mandic Research Center and Institute (No. 1.005.929). Eighty lateral digital radiographs of 40 individuals were selected from the archive of the Orthodontic Department at the same Institute taken before and after the pubertal peak of growth. The mean age before growth peak was 10.5 years old and the mean age after growth peak, 13 years old. In addition, in the first x-ray, patients were at Stage II of cervical vertebral maturation and in the second x-ray, at Stage IV [12]. All radiographs must have had high quality and a good contrast to be included in this study. Exclusion criteria were patients undergone any orthodontic and/or orthopedic intervention that will reduce or correct sagittal problems, patients with multiple dental absences, and patients with moderate or severe asymmetries.

Elaboration of the cephalometric tracing

The following anatomical structures were drawn by the same evaluator: sphenoid bone contour, occipital bone, frontal bone, nasal bone, soft tissue profile, maxilla, most anteriorly positioned upper and lower central incisor and first molar, symphyseal bone, mandible. Lines and Plans are described on table 1.

Table 1. The lines and plans used in this study.

Me-Goc plane	Represents the mandibular plane that passes through the mentonian point and touches the lower edge of the mandible, in the gonion region
S-N Line	Represents the anterior base of the skull, determined by the union of the points Sela and Nasion
S-Goc Line	Represents posterior facial height, determined by the union of the points Sela and Gonius Constructed
N-Gnc Line	Represents the anterior facial height, determined by the union of the points Nasio and Gnatus Constructed
Palatal Plane	Determined by the union of the points Anterior Nasal Spine and Posterior Nasal Spine

After drawing the planes and lines as described on Table 1, an irregular polygon formed by the S-N and N-Gnc lines and Gnc-Goc and S-Goc planes was obtained. This polygon represents three-dimensionally the limits of the face. Later, four midpoints of the polygon were determined, and by connecting the upper to lower and anterior to posterior midpoints, the intersection is where Centroid point was found (figure 1) [9,10,13,14].

Method for locating the centroid points

Cephalograms from the two time-points were superimposed using the palatal plane and a line perpendicular to it passing through the most posterior point of the pterygomaxillary fossa was used as a stable reference. Both palatal plane and the line perpendicular to it that passed through the most posterior point of the pterygomaxillary fossa were chosen due to their proximity to the location of the centroid points and are considered stable [15].

The distance between the two Centroid points (before and after the pubertal peak, called C1 and C2 respectively) was calculated using a digital caliper (Mitutoyo Co., Miyazaki, Japan) on both on the X and Y-axis (figure 2). The distances from point 0 to C1 and from point 0 to C2 were measured, and their difference was calculated.

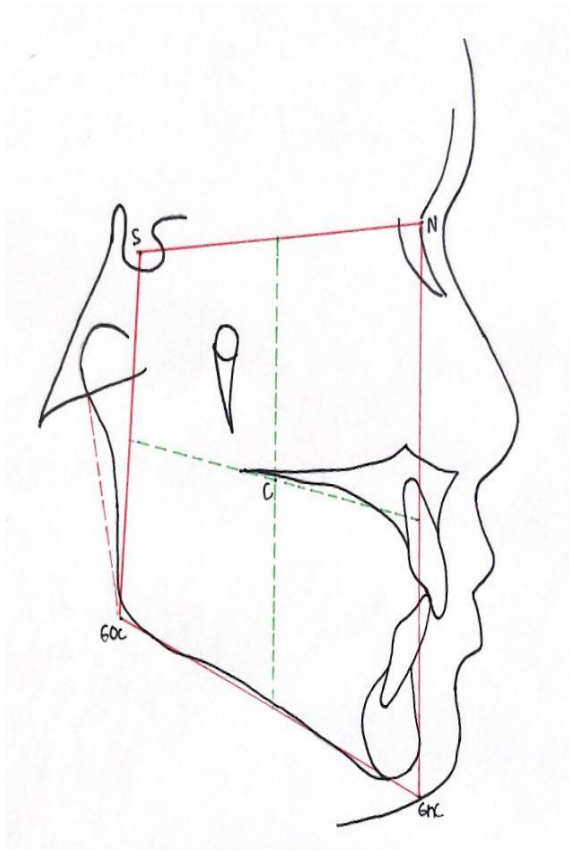


Figure 1. Structures, points, lines and plans drawn forming an irregular polygon to determine the spatial position of the Centroid Point.

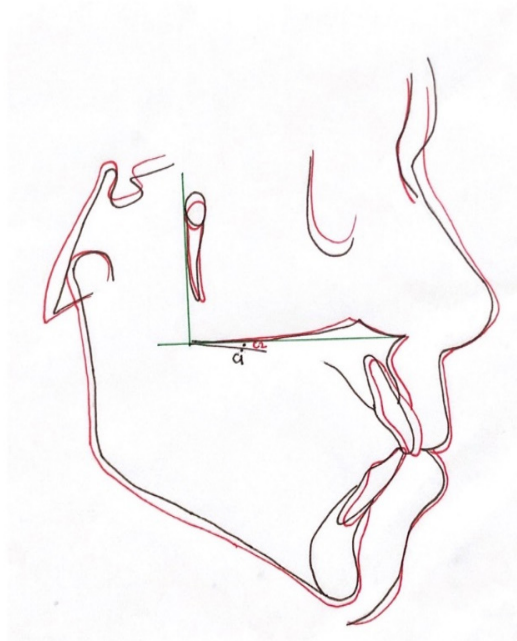


Figure 2. Superimposition. Black: Cephalometric tracing 1 and C1 (Centroid point); Red: Cephalometric tracing and Point C2 (Centroid point); Green: Stable references used to evaluate Centroid points

Measurements were repeated four times at different intervals to evaluate method error. Statistical tests were performed using Graphpad Prism 8 software (GraphPad Software, San Diego, CA, USA). The Smirnov-Kolmogorov test was used to investigate the normal distribution. As the assumptions of normality were not violated, a paired t-test was used. The level of significance adopted for all comparisons was 5%.

RESULTS

The characteristics of the study population are provided in table 2. Sagittal skeletal and facial type were determined based on previous studies [16,17].

To assess intra-examiner reliability, the intraclass correlation coefficient was used. Values between 0.8 and 1.0 mean excellent reliability. In this study, all measurements resulted in a value >0.999 , so the test indicated the accuracy of the measurements taken by the same operator (figure 3).

The results of location of the Centroid point obtained on tracings 1 and 2 referring to the lateral x-rays before and after the pubertal peak of growth, on X and Y axis are shown in table 3 and figures 3 and 4. There was no significant difference in the location of the centroid points on both the X and Y axis ($p < 0.05$) when comparing both traces, showing an average change in the position of 0.36mm on the X Axis and 0.37mm on the Y Axis.

Table 2. Characteristics of the sample included in the present study.

Mean Age (years)	Before Growth Peak	10.5
	After Growth Peak	13
Gender (n)	Female	20
	Male	20
Sagittal Skeletal Classification (n)	Class I	18
	Class II	14
	Class III	8
Facial Type(n)	Dolichofacial	14
	Mesofacial	17
	Brachyfacial	9

Table 3. Mean and standard deviation values in millimeters related to the location of the Centroid point on the X-axis found in tracings before and after pubertal growth peak.

	<i>Before Peak Tracing 1</i>	<i>After Peak Tracing 2</i>	<i>Difference</i>	<i>p-value</i>
X-axis	11.77 A (2.54)	12.13 A (3.06)	0.36 (0.52)	0.06
Y-axis	-0,63 A (1,44)	-1,00 A (1,60)	-0,37 (-0,16)	0,60

DISCUSSION

Cephalometric analysis aims to evaluate facial morphology by dividing the craniofacial complex in order to study how the skeletal parts are related to each other [18]. Most cephalometric methods use intracranial references from a normal population (no skeletal discrepancy) or extracranial references based on the natural position of the head. According to Lundström et al. [19], the intracranial method based on anatomical references can often be unreliable, as

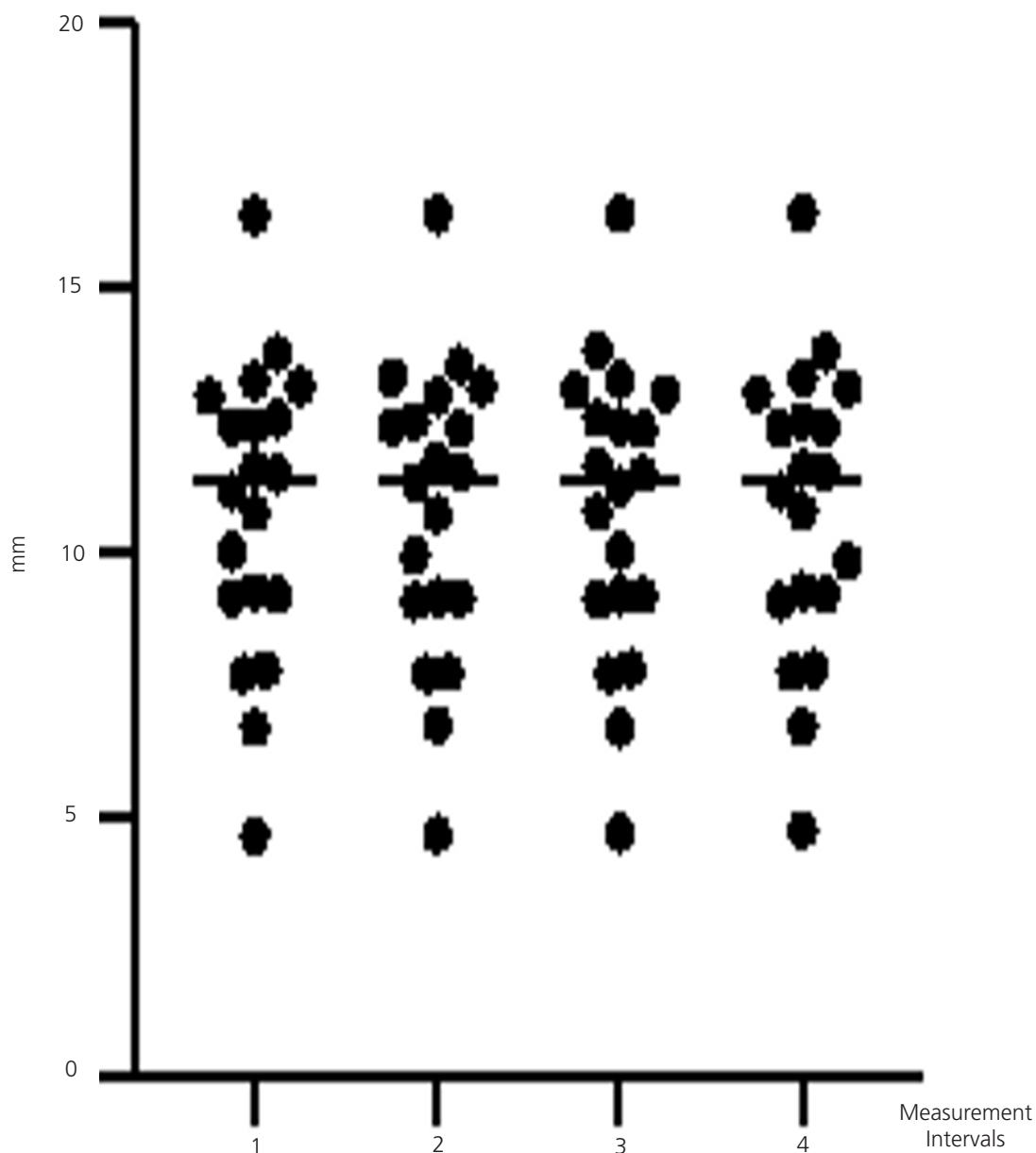


Figure 3. Intraclass Correlation test. Each group represents the measurements made at different time point.

some landmarks can be difficult to identify, therefore affecting directly the interpretation of craniofacial morphology and skeletal discrepancy. When properly performed, cephalometric superimposition allows clinicians to analyze changes resulted from skeletal growth and dental arch development and orthodontic treatment progress [20].

Many studies support the use of the cranium base as a registration area for superimposition. Although several authors agree that the base of the skull, during the period when most orthodontic cases are treated (9 to 14 years old), is relatively stable and considered a satisfactory reference in the superposition of serial cephalograms [1,4,5,21-27], Bjork [28] considers that this structure continues to change during adolescence. In addition, Melsen [29] reported that Sella turcica undergoes remodeling during adolescence and can move back and downwards a few millimeters, but it continues to be widely accepted as a stable area for superimposition techniques.

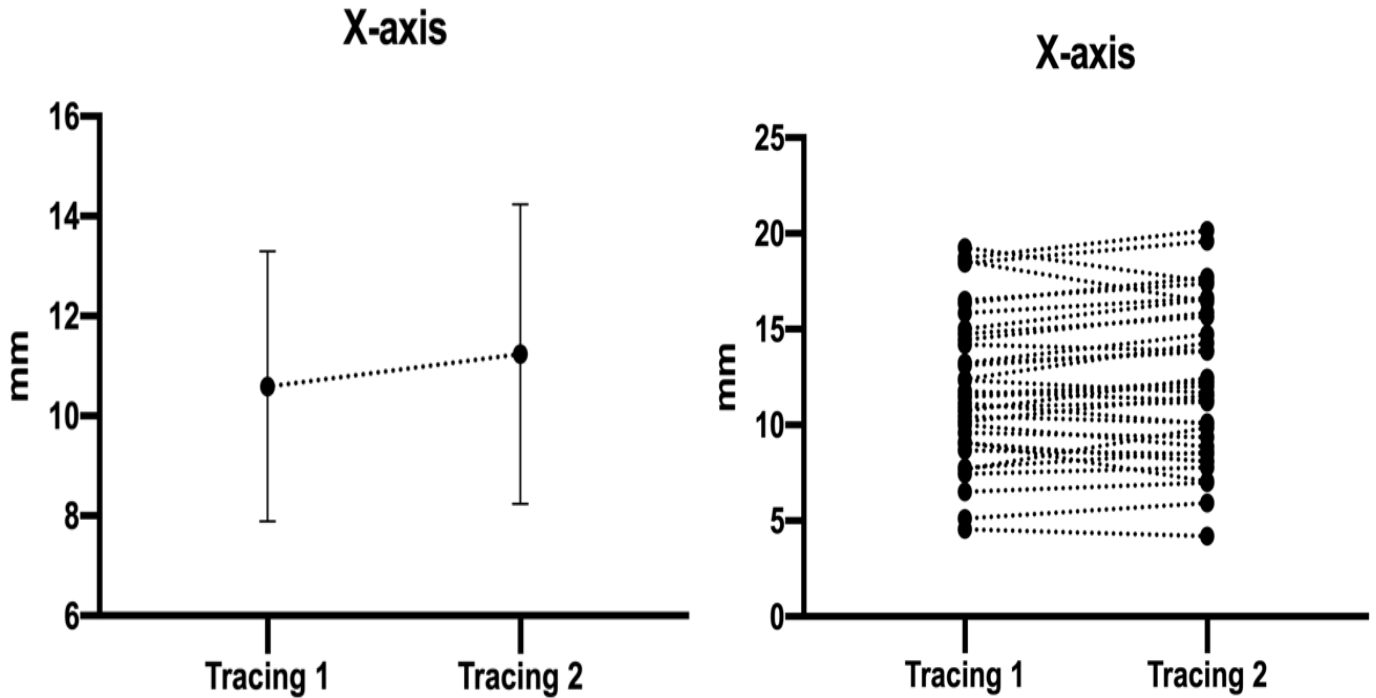


Figure 4. Graphical representation of the mean values and standard deviation and individual change of the Centroid point location on X axis on before and after growth peak tracings.

According to McWilliam [30] there is relatively good accuracy when performing superimposition using the skull base as a reference in different time intervals in adults, however greater variation can be observed when using it on individuals during growth spurt, the period when bone remodeling activity has a strong influence at the base of the skull. Baumrind et al. [31] reported that the identification of relatively stable structures is not simple, since almost all bones of the craniofacial complex undergo continuous changes during craniofacial development. Even in areas where the bone shape seems to remain relatively constant over time, growth can occur not by proportional expansion in all directions, but as a result of reabsorption and apposition of bone surfaces, which may produce different results depending on the area of evaluation. Thus, it becomes interesting to analyze whether the differences may or may not lead to significantly different interpretations.

Enlow [32] explained that no stable or fixed reference point allows accurate superimposition of cephalograms during growth, as all parts of all bone structures are subjected to greater or lesser amounts of remodeling. For this reason, better references for superimposition do not include reference points, but natural registration areas. On the other hand, as mentioned by Mathews and Payne [33], in the absence of growth or observing in a short time between x-rays, conventional superimposition methods can be used. However, the authors mention that they are not reliable for use during the adolescent growth spurt. They recommended caution when using natural landmarks for superimposition during longer periods of growth.

As for the Centroid point, Johnson and Hubbard [7] emphasized its application to assess craniofacial structures, recognizing the relative stability with traditional cephalometric analysis and described morphological changes during the growth period. They concluded that the points and lines to find Centroid tend to show less variation than anatomical points and lines such as mandibular or Frankfurt plane, or lines relating maxilla to mandible. Thus, the present study aimed to evaluate the Centroid behavior by using stable and easy-to-locate structures as well as intracranial points [9], in a simpler manner for superimposition.

According to Fishman [8] conventional cephalometric analysis evaluates facial form using numerical method comparing averages derived from pre-selected samples as "normal" and mentions the fact that there is an individual unique craniofacial development pattern and this could lead to a wide skeletal, dental, and soft tissue variation. The author was able to define and identify facial morphological features using an orientation pattern for skeletal, dental, and soft-tissue based on the Centroid point. For the author, the Centroid point represents the geometrical center of mass or gravity of a two-dimensional area or a three-dimensional volume, with minimally change in position as the geometric form increases in size, and therefore being a helpful tool to assess clinically maxillomandibular discrepancies.

By using metallic implants (pins) as reference points in longitudinal cephalometric investigations, Björk et al. [28] provided basic information about the craniofacial growth pattern in humans. Unfortunately, there have been few studies on the results of orthodontic treatment that have used the proposed tantalum implant insertion, presumably because it is an invasive method to be indicated for research purposes only. Since metallic implants are not an option, even though it is considered the gold standard for superimposition, several structures suggesting stable regions have been proposed on superimposition methods for craniofacial assessment. Gu & McNamara demonstrated that the superimposition method recommended by the American Board of Orthodontics (ABO) can underestimate the vertical displacement of the maxilla by 3mm and overestimate the anterior displacement of the maxilla by 1.5 mm when compared to the metallic implant method, measured from superimposed cephalograms of individuals with the mean age of 8.9 years and 15.3 years. In the same study superimposing cephalograms of patients from 10 to 13 years, the mean variation of the maxilla on the X-axis was found between 0.5 and 0.6 mm at the region of the posterior nasal spine [3].

The relevance of this study is the fact that the Centroid point represents a simple and objective way to assess the complex craniofacial alteration during individual development before and after the growth spurt. The results of this study showed that there was no statistically significant difference in the location of the Centroid points on both X and Y-axis ($p > 0.05$) when comparing the tracings 1 and 2, showing a change, on average, of 0.36mm on the X-Axis and 0.37mm on the Y-Axis. Thus, Centroid points behaved moving slightly forward and downward direction during growth of these individuals. The little amount of change during the peak of growth spurt found in the present study suggests that the proposed Centroid point can be used as a stable reference for cephalometric superimposition.

In the orthodontic daily practice, the application of the Centroid point on consecutive cephalometric tracings at different moments, can help clinicians to assess the growth of the maxilla and mandible (or results of therapy) by using it as a reference landmark and by measuring the distance from the Centroid point relative to basal bone structures, such as point A and ENA (anterior nasal spine) at the maxilla or Point B and Pogonion on the mandible point. Another way of assessing the growth or outcome of the therapy would be by superimposing two cephalograms registering on the Centroid point and by measuring the distance between each landmark on both cephalograms in order to quantify the amount of change, and also by drawing lines/plans to assess the direction of growth/change of the basal bone. Further studies should be carried out to find which method would be best indicated for assessing maxilla and mandible position, using the Centroid point as a reference.

CONCLUSION

The results of the present study demonstrated that there is no significant change from the Centroid point before and after the pubertal growth peak and suggest that Centroid point can be used as a stable reference for assessing craniofacial growth for superimposition method.

Coollaborators

JSA Lee, conducting the research, data collection and writing the manuscript. H Suzuki, idea and development of method. ABS Costa, sample gathering for the experiment. AS Garcez, reviewing the manuscript. SS Suzuki, advisor, application of statistical analysis and reviewing and editing the manuscript.

REFERENCES

- Arat ZM, Türkahraman H, English JD, Gallerano RL, Boley JC. Longitudinal growth changes of the cranial base from puberty to adulthood. A comparison of different superimposition methods. *Angle Orthod.* 2010;80(4):537-544. <https://doi.org/10.2319/080709-447.1>
- Gu Y, McNamara JA Jr. Cephalometric superimpositions: a comparison of anatomical and metallic implant methods. *Angle Orthod.* 2008 Nov;78(6):967-976. <https://doi.org/10.2319/070107-301.1>
- Tollazi AL. A influência do controle de qualidade em telerradiografias em norma lateral e na obtenção de pontos cefalométricos [tese]. São Paulo: Faculdade de Odontologia da Universidade de São Paulo, 2005.
- Higley LB. Lateral head roentgenograms and their relation to the orthodontic problem. *Am J Orthod Oral Surg.* 1940;26(8):768-778.
- De Coster L. A new line of reference for the study of lateral facial telerradiographs. *Am J Orthod.* 1953;39(4):304-306.
- Johnson JS. A new approach to cephalometric analysis of the dental base relationship. *Angle Orthod.* 1978;48(1):23-32. [https://doi.org/10.1043/0003-3219\(1978\)048<0023:ANATCA>2.0.CO;2](https://doi.org/10.1043/0003-3219(1978)048<0023:ANATCA>2.0.CO;2)
- Johnson JS, Hubbard RJ. An introduction to centroids cephalometrics. *Br J Orthod.* 1982 Jan;9(1):32-6. <https://doi.org/10.1179/bjo.9.1.32>
- Fishman LS. Individualized evaluation of facial form. *Am J Orthod Dentofac Orthop.* 1997 May;111(5):510-7. [https://doi.org/10.1016/s0889-5406\(97\)70288-9](https://doi.org/10.1016/s0889-5406(97)70288-9)
- Suzuki H. Avaliação de três métodos de traçados cefalométricos em telerradiografias para estimar a posição natural da cabeça. [tese]. Campinas: Faculdade São Leopoldo Mandic; 2009.
- Liu Y, Wang S, Wang C, Liu C. Relationships of vertical facial pattern, natural head position and craniocervical posture in young Chinese children. *Cranio.* 2018;36(5):311-317. <https://doi.org/10.1080/08869634.2017.1345461>
- Cassi D, DeBiase C, Tonni I, Gandolfi M, DiBlasio A, Piacino MG. Natural position of the head: review of two dimensional and three dimensional methods of recording. *Br J Oral Maxillofac Surg.* 2016 Apr;54(3):233-40. <https://doi.org/10.1016/j.bjoms.2016.01.025>
- Baccetti T, Franchi L, MacNamara JR JA. An improved version of cervical vertebral maturation (CVM) method for the assessment of mandibular growth. *Angle Orthod.* 2002 Aug;72(4):316-323.
- Fonseca RC. Análise cefalométrica: diagnóstico e planejamento ortodôntico. São Paulo: Santos; 2001.
- Cooke MS, Wei SH. A summary five-factor cephalometric analysis based on natural head posture and the true horizontal. *Am J Orthod Dentofacial Orthop.* 1988;93(3):213-223. [https://doi.org/10.1016/S0889-5406\(88\)80006-4](https://doi.org/10.1016/S0889-5406(88)80006-4)
- Moore AW. Observations on facial growth and its clinical significance. *Am J Orthod.* 1959;45(6):399-423. [https://doi.org/10.1016/S0002-9416\(59\)80002-6](https://doi.org/10.1016/S0002-9416(59)80002-6)
- Siriwat PP, Jarabak JR. Malocclusion and facial morphology is there relationship? An epidemiologic study. *Angle Orthod.* 1985 Mar;55(2):127-38. [https://doi.org/10.1043/0003-3219\(1985\)055<0127:MAFMIT>2.0.CO;2](https://doi.org/10.1043/0003-3219(1985)055<0127:MAFMIT>2.0.CO;2)
- Björk A. Prediction of mandibular growth rotation. *Am J Orthod.* 1969 Jun;55(6):585-99. [https://doi.org/10.1016/0002-9416\(69\)90036-0](https://doi.org/10.1016/0002-9416(69)90036-0)
- Jarabak JR, Fizzel JA. Technique and treatment with light wire edgewise appliances. 2a ed. Mosby: Saint Louis; 1972.
- Ludström A, Ludström F, Le Bret LM, Moorrees CF. Natural head position and natural head orientation: basic considerations in cephalometric analysis and research. *Eur J Orthod.* 1995 Apr;17(2):111-111. <https://doi.org/10.1093/ejo/17.2.111>
- Zampieri RF, Henriques JFC, Freitas MR, Janson GRP. Estudo comparativo entre técnicas de superposições cefalométricas totais. *Rev Dental Press.* 2005;10(6):141-156.
- Broadbent BH. The face of the normal child. *Angle Orthod.* 1937 Oct;7(4):183-208. [https://doi.org/10.1043/0003-3219\(1937\)007<0183:TFOTNC>2.0.CO;2](https://doi.org/10.1043/0003-3219(1937)007<0183:TFOTNC>2.0.CO;2)
- Caufield PW. Tracing technique and identification of landmarks. In: Jacobson A. Radiographic cephalometry: from basics to video imaging. Batavia, IL: Quintessence Pub Co.; 1995. p. 53-63.
- Coben SE. Growth and Class II treatment. *Am J Orthod.* 1966 Jan;52(1):5-26. [https://doi.org/10.1016/0002-9416\(66\)90093-5](https://doi.org/10.1016/0002-9416(66)90093-5)
- Ford EHR. Growth of the human cranial base. *Am J Orthod.* 1958 Jul;44(7):498-506. [https://doi.org/10.1016/0002-9416\(58\)90082-4](https://doi.org/10.1016/0002-9416(58)90082-4)
- Ghafari J, Engel FE, Laster LL. Cephalometric superimposition on the cranial base: a review and a comparison of four methods. *Am J Orthod Dentofacial Orthop.* 1987;91(5):403-413. [https://doi.org/10.1016/0889-5406\(87\)90393-3](https://doi.org/10.1016/0889-5406(87)90393-3)
- Moorrees CFA, Efstratiadis SS, Kent Junior RL. The complexity of facial growth analysis. In: Jacobson. A Radiographic cephalometry: from basics to videoimaging. Batavia, IL: Quintessence Pub Co.; 1995. p. 137-163.
- Wieslander L. The effect of orthodontic treatment on the concurrent development of the craniofacial complex. *Am J Orthod.* 1963 Jan;49(1):15-27. [https://doi.org/10.1016/0002-9416\(63\)90063-0](https://doi.org/10.1016/0002-9416(63)90063-0)
- Björk A. Cranial base development: a follow-up x-ray study of the individual variation in growth occurring between the ages of 12 and 20 years and its relation to brain case and face development. *Am J Orthod.* 1955 Mar;41(3):198-225. [https://doi.org/10.1016/0002-9416\(55\)90005-1](https://doi.org/10.1016/0002-9416(55)90005-1)
- Melsen B. The cranial base: The postnatal development of the cranial base studied histologically on human autopsy material. *Acta Odont Scand.* 1974 Dec;66(6):689-691. [https://doi.org/10.1016/0002-9416\(82\)90467-5](https://doi.org/10.1016/0002-9416(82)90467-5)

30. McWilliam JS. The effect of growth on the precision of subtraction superimposition. *Dentomaxillofac Radiol.* 1983;12(1):61-69. <https://doi.org/10.1259/dmfr.1983.0012>
31. Baumrind S, Ben-Bassat Y, Bravo LA, Curry S, Korn EL. Partitioning the components of maxillary tooth displacement by the comparison of data from three cephalometric superimpositions. *Angle Orthod.* 1966;66(2):111-124. [https://doi.org/10.1043/0003-3219\(1996\)066<0111:PTCOMT>2.3.CO;2](https://doi.org/10.1043/0003-3219(1996)066<0111:PTCOMT>2.3.CO;2)
32. Enlow DH. A morphogenetic analysis of facial growth. *Am J Orthod.* 1966 Apr;52(4):283-99. [https://doi.org/10.1016/0002-9416\(66\)90169-2](https://doi.org/10.1016/0002-9416(66)90169-2)
33. Mathews JR, Payne GS. Quantitative computerized analysis of lower incisor changes: a longitudinal implant study in man. *Angle Orthod.* 1980;50(3):218-229. [https://doi.org/10.1043/0003-3219\(1980\)050<0218:QCAOLI>2.0.CO;2](https://doi.org/10.1043/0003-3219(1980)050<0218:QCAOLI>2.0.CO;2)

Received on: 14/10/2019

Final version resubmitted on: 31/7/2020

Approved on: 1/9/2020

Assistant editor: Marcelo Sperandio